

Frontal Cranioplasty with Vascularized Split-iliac Crest Bone Flap

Morgan E. Baudoin, BS*
Patrick A. Palines, MD†
Mark W. Stalder, MD†‡

Summary: Defects of the frontal bone require thoughtful consideration of reconstructive material to satisfy the aesthetic and functional demands of the region, as well as the anatomic adjacency to the frontal sinus. Some cases may be further complicated by a suboptimal operative field due to prior radiation, reconstructive procedures, or infection. Vascularized bone offers an ideal option to successfully reconstruct bony defects in harsh wound beds. Here, we report the case of a 47-year-old man with adenoid cystic carcinoma who underwent secondary reconstruction of the frontal bone with a split-iliac crest bone flap based on the deep circumflex iliac artery. The patient's course following an initial ablative procedure was complicated by recurrent periorbital cellulitis, radiation, and eventual recurrence of the malignancy. Reconstructive requirements included restoration of the superior orbital rim, cranialization of the frontal sinus, and reconstruction of a sizeable frontal bone defect. In this setting, the iliac crest served as an excellent reconstructive option owing to its natural curvature and large surface area. The split-iliac crest deep circumflex iliac artery bone flap offers a robust and valuable reconstructive option for calvarial defects in hostile surgical fields. (*Plast Reconstr Surg Glob Open* 2021;9:e3934; doi: [10.1097/GOX.0000000000003934](https://doi.org/10.1097/GOX.0000000000003934); Published online 16 November 2021.)

Successful reconstruction of calvarial defects requires thoughtful selection of the substrate best suited for individual defects. With a myriad of options ranging from autogenous bone to custom alloplastic materials, the surgeon must consider size, shape, and location of the defect as well as the condition of the wound bed and adjacent soft tissue. Infection, previous surgery, history of radiation and other factors that might compromise the operative field increase the risk of bone graft resorption and failure of alloplastic implants.¹ Vascularized tissue transfer can mitigate many of these complicating factors and is potentially the most reliable option in such cases.¹ Flap choice is guided by aesthetic, functional, and individual anatomic considerations involving the calvarial defect in question.

Defects of the frontal bone warrant special attention owing to its conspicuous location and potential for deleterious complications that may result from inadequate partitioning of the intracranial space from the sinuses.^{2,3} Conventional treatment of uncomplicated frontal sinus/frontal bone defects most often involve obliteration or cranialization, with outflow tract partitioning using bone graft, fat, and/or a pericranial flap or graft, and frontal bone reconstruction with bone graft or vascularized fibula flaps for complex cases.² Here we present the case of a patient with a history of multiple extensive oncologic resections, radiation, and recurrent malignancy of the frontal sinus treated with resection and a deep circumflex iliac artery (DCIA) split-iliac crest bone flap.

CASE PRESENTATION

A 47-year-old man was initially treated by our reconstructive team following oncologic ablation of the right maxilla, medial orbital wall, and nasal sidewall for an adenoid cystic carcinoma. Primary reconstruction was achieved using an anterolateral thigh flap for skin coverage and to obliterate the maxillary sinus defect, and a titanium mesh plate to reconstruct the medial orbital wall and orbital floor. The patient's recovery was initially uneventful, and he subsequently underwent radiation of the operative field.

From the *Louisiana State University Health Sciences Center School of Medicine New Orleans, La.; †Division of Plastic and Reconstructive Surgery, Louisiana State University Health Sciences Center, New Orleans, La.; and ‡University Medical Center – LCMC Health, New Orleans, La.

Received for publication May 28, 2021; accepted September 15, 2021.

Copyright © 2021 The Authors. Published by Wolters Kluwer Health, Inc. on behalf of The American Society of Plastic Surgeons. This is an open-access article distributed under the terms of the [Creative Commons Attribution-Non Commercial-No Derivatives License 4.0 \(CCBY-NC-ND\)](https://creativecommons.org/licenses/by-nc-nd/4.0/), where it is permissible to download and share the work provided it is properly cited. The work cannot be changed in any way or used commercially without permission from the journal.

DOI: [10.1097/GOX.0000000000003934](https://doi.org/10.1097/GOX.0000000000003934)

Disclosure: The authors have no financial interest to declare in relation to content of this article. This study did not receive any funding.

The patient subsequently re-presented with diplopia and several bouts of periorbital cellulitis treated with intravenous antibiotics, followed by eventual sinusostomy with stent placement to re-establish the nasofrontal outflow tract. Biopsies revealed recurrent disease involving the right frontal bone and posterior table mucosa of the frontal sinus, and a secondary ablative procedure was planned to include the anterior and posterior tables of the right frontal sinus and superior orbital rim (Fig. 1). Reconstructive requirements included restoration of the orbital rim, cranialization of the frontal sinus, and reconstruction of the frontal bone defect. Due to the prior radiation of the operative site, the decision was made that vascularized tissue would optimize healing and integration of the bony component of our reconstruction.

Following initial resection by neurosurgery and otolaryngology, our team began the harvest of a vascularized iliac crest bone flap based on the DCIA. Using a template of the defect, the inner table of the iliac crest was split through the cancellous core with hand-held osteotomes, and a reciprocating saw was used to complete the harvest of the flap with the vasculature, periosteum, and a thin layer of muscle still intact. The bone flap was shaped to fit the defect, and inset such that the cortical portion of bone was facing the dura so as to make use of its inherent curvature. Microvascular anastomosis was performed using the left superficial temporal artery and vein, with the addition of the left descending lateral circumflex femoral system as a 10 cm interpositional composite vascular graft to accommodate the inadequate length of the DCIA pedicle. Obliteration of the nasofrontal outflow tract was performed using additional bone graft from the iliac crest and a pericranial patch. The bone flap was positioned and fixed using miniplates and 5 mm screws. Demineralized bone matrix was applied to smooth the contour of the construct. The patient was discharged on postoperative day 6 after an uncomplicated hospital course. Computed tomography imaging 3 months after the operation revealed an intact bone flap with evidence of osseointegration.

DISCUSSION

First introduced by Taylor et al in 1979, the DCIA-based iliac crest free flap is among the most frequently used flaps for mandibular reconstruction.⁴⁻⁶ Although nonvascularized iliac crest bone grafting has been widely used for frontal sinus obliteration, to our knowledge, this is the first report of a vascularized split-iliac crest flap used for frontal bone cranioplasty. There exist numerous reports of complex frontal sinus defects successfully managed with free fibula flaps and osseocutaneous radial forearm flaps^{2,3,7}; however, the narrow width of these bone flaps often requires a multi-segmented approach or additional alloplastic material to fill defects encompassing a greater surface area.^{2,3,7} The DCIA provides a potentially broad bony segment with substantially greater surface area, making it an ideal alternative for frontal bone reconstruction.⁵ Additionally, the natural curvature of the iliac crest allows for a construct well-suited to reconstruct these defects, avoiding step-offs and contour deformities from multiple bony segments or the high infection rates associated with alloplastic implants.^{5,6}

Critics of the traditional DCIA flap cite the relatively thick skin paddle and additional bulk of the muscle cuff as limitations for use, although the muscle can be de-bulked, if needed, to reduce soft tissue volume and improve maneuverability.^{6,8} However, the soft tissue capacity of the DCIA may also provide a means of dead space obliteration in frontal sinus reconstruction in certain instances. Rare but notable donor site complications include inguinal hernia and abnormal gait resulting from disturbance of hip and pelvic biomechanics.^{5,9} Risk of injury to the lateral femoral cutaneous nerve may be reduced with experience and modified surgical approaches.⁶ Although comparative analyses of fibula and DCIA flap donor sites have reported greater postoperative pain after DCIA harvest,¹⁰ the degree of pain reported is correlated with length of iliac bone harvested⁹ and subsides entirely in most patients over time.¹⁰ Ultimately, the split-iliac crest DCIA bone flap is a reliable and well-tolerated reconstructive option with comparable rates of flap and donor

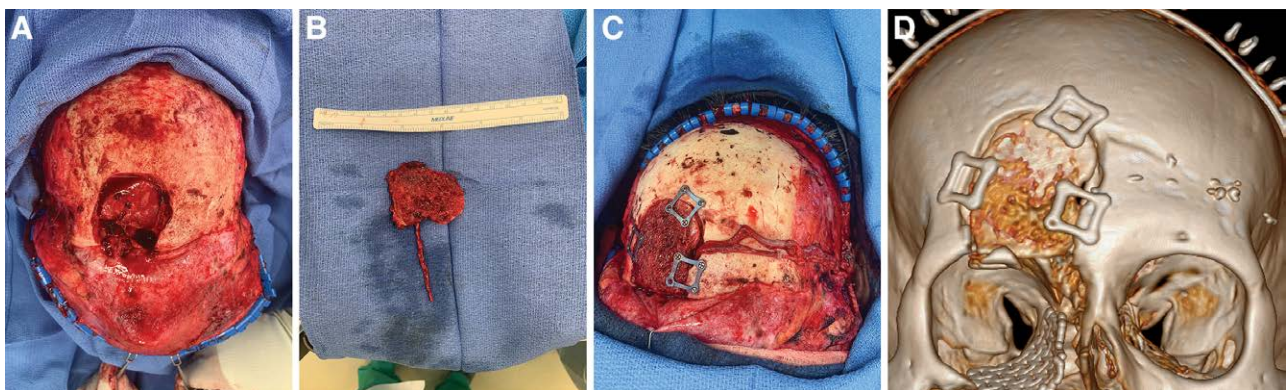


Fig. 1. Vascularized iliac crest cranioplasty in a 47-year old man with recurrent adenoid cystic carcinoma. A, Frontal bone and sinus defect after resection of recurrent adenoid cystic carcinoma in the setting of prior radiation, surgery, and infection. B, DCIA split-iliac crest bone flap after trimming to fit the bony defect. C, The DCIA bone flap was inset using titanium miniplates, and microvascular anastomosis was performed to the contralateral superficial temporal vessels using a composite arterial/venous vascular graft from the descending branch of the lateral femoral circumflex system. D, Postoperative CT scan demonstrating inset of vascularized iliac crest bone flap.

site morbidity to other alternatives,^{9,10} offering an additional option for reconstruction of calvarial defects in hostile surgical fields.

Mark W. Stalder, MD

Division of Plastic and Reconstructive Surgery
Louisiana State University Health Sciences Center School of
Medicine
1542 Tulane Ave, Room 734
New Orleans, LA 70112
E-mail: mstald@lsuhsc.edu

ACKNOWLEDGMENT

Our institutional review board approved all content and procedures described in this study.

REFERENCES

1. Fong AJ, Lemelman BT, Lam S, et al. Reconstructive approach to hostile cranioplasty: a review of the University of Chicago experience. *J Plast Reconstr Aesthet Surg*. 2015;68:1036–1043.
2. Rodriguez ED, Stanwix MG, Nam AJ, et al. Definitive treatment of persistent frontal sinus infections: elimination of dead space and sinonasal communication. *Plast Reconstr Surg*. 2009;123:957–967.
3. Sinno S, Rodriguez ED. Definitive management of persistent frontal sinus infections and mucocele with a vascularized free fibula flap. *Plast Reconstr Surg*. 2017;139:170–175.
4. Taylor GI, Townsend P, Corlett R. Superiority of the deep circumflex iliac vessels as the supply for free groin flaps. Clinical work. *Plast Reconstr Surg*. 1979;64:745–759.
5. Navarro Cuellar C, Caicoya SJ, Acero Sanz JJ, et al. Mandibular reconstruction with iliac crest free flap, nasolabial flap, and osseointegrated implants. *J Oral Maxillofac Surg*. 2014;72:1226.e1–1226.15.
6. Liu J, Song D, Li J, et al. Modified osteomyocutaneous iliac crest flaps transplantation. *J Plast Surg Hand Surg*. 2015;49:102–106.
7. Vargo JD, Przylecki W, Camarata PJ, et al. Classification and microvascular flap selection for anterior cranial fossa reconstruction. *J Reconstr Microsurg*. 2018;34:590–600.
8. Safak T, Klebuc MJ, Mavili E, et al. A new design of the iliac crest microsurgical free flap without including the “obligatory” muscle cuff. *Plast Reconstr Surg*. 1997;100:1703–1709.
9. Liu Q, Shao Z, Shang Z. Mandibular reconstruction using the deep circumflex iliac artery free flap: effect of the length of bone harvested on donor site morbidity. *Br J Oral Maxillofac Surg*. 2019;57:778–781.
10. Schardt C, Schmid A, Bodem J, et al. Donor site morbidity and quality of life after microvascular head and neck reconstruction with free fibula and deep-circumflex iliac artery flaps. *J Craniomaxillofac Surg*. 2017;45:304–311.