

A Rare Case of Drug-Induced Liver Injury Caused by Levetiracetam

Abstract

Levetiracetam (LEV) is one of the newest antiepileptic drugs available on the market and is frequently used in neurosurgical patients requiring antiepileptic assistance. LEV is mainly excreted by the kidney with minimal hepatic metabolism, so it is considered to have a low liver toxicity. Drug-induced liver injury (DILI) associated with LEV administration is extremely rare, with only eight reported cases. In this report, we describe the case of a 44-year-old man who was admitted because of generalized convulsion, and LEV administration at a dose of 3000 mg/day was started following a diagnosis of status epilepticus. Laboratory values before LEV administration were as follows: alanine aminotransferase (ALT), 17 IU/L; aspartate transaminase (AST), 41 IU/L; and total bilirubin, 0.59 mg/dL. Viral serology tests for hepatitis B and hepatitis C yielded negative results. Several hours after LEV administration, the patient developed high-grade fever and his liver enzyme levels were found to be elevated. LEV administration was stopped immediately; the peak laboratory values were as follows: ALT, 1,192 IU/L; AST, 3,150 IU/L; and total bilirubin, 2.02 mg/dL. After conservative treatment, the patient's laboratory values were normalized. A drug-induced lymphocyte stimulation test (DLST) was performed and showed a positive response, indicating that the administration of LEV was responsible for DILI in this patient. Clearly, LEV can provoke DILI despite its low liver metabolism profile. Therefore, readministration of the drug should be avoided in such cases. An *in vitro* examination, such as a DLST, can be useful for ensuring a definitive diagnosis of DILI.

Keywords: Drug metabolism, drug-induced liver injury, drug-induced stimulation test, levetiracetam

Introduction

Status epilepticus (SE) is a neurological emergency disorder that can present associated with common neurosurgical conditions, including intracerebral hemorrhage, cerebral infarction, brain tumors, and head trauma. Because of its high mortality and morbidity,^[1,2] an appropriate treatment is strongly required, and conservative treatment with antiepileptic drugs (AEDs) is usually chosen. Among them, levetiracetam (LEV) is one of the newest drugs available, demonstrating certain pharmacological characteristics such as a low protein-binding property, reduced drug–drug interaction, and minimal hepatic metabolism.^[3,4]

Drug-induced liver injury (DILI) is a frequent adverse reaction, which is the underlying cause in the majority of cases of acute liver failure.^[5-7] The efficiency of drug metabolism in the liver, involving the cytochrome P450 enzyme system, plays a critical role in

determining the degree of toxicity to the patient. In fact, drugs with predominant hepatic metabolism profile are associated with more frequent DILI as compared with those with a low hepatic metabolism profile.^[8,9] Because LEV is predominantly not metabolized in the liver, it is recognized as a safe and reliable drug, and liver injury, including transient asymptomatic liver enzyme elevation, has been reported in <1% of patients following LEV administration.^[4]

To facilitate a diagnosis of DILI, some clinical criteria or scales have developed and the Council for International Organization of Medical Science / the Roussel Uclaf Causality Assessment Method (CIOMS/RUCAM) scale was proposed.^[10] By modifying CIOMS/RUCAM scale, the Digestive Disease Week Japan 2004 (DDW-J) scale, which is highly sensitive and specific, was developed and widely accepted as an objective criterion for the diagnosis of DILI.^[11,12] Despite advances in assessment criteria, it is not easy to achieve correct diagnosis of DILI in appropriate timing. Here, we discuss a rare

Tomohiro Kawaguchi^{1,2},
Teiji Tominaga¹

¹Department of Neurosurgery, Tohoku University Graduate School of Medicine, Sendai, Miyagi, ²Department of Neurosurgery, Shirakawa Kosei General Hospital, Shirakawa, Fukushima, Japan

Address for correspondence:

Dr. Tomohiro Kawaguchi,
Department of Neurosurgery,
Tohoku University Graduate
School of Medicine,
1-1 Seiryō-Machi, Aoba-ku,
Sendai 980-8574, Japan.
E-mail: kawaguchi@nsg.med.
tohoku.ac.jp

Access this article online

Website: www.asianjns.org

DOI: 10.4103/ajns.AJNS_246_17

Quick Response Code:



How to cite this article: Kawaguchi T, Tominaga T. A rare case of drug-induced liver injury caused by levetiracetam. *Asian J Neurosurg* 2019;14:878-82.

This is an open access journal, and articles are distributed under the terms of the Creative Commons Attribution-NonCommercial-ShareAlike 4.0 License, which allows others to remix, tweak, and build upon the work non-commercially, as long as appropriate credit is given and the new creations are licensed under the identical terms.

For reprints contact: reprints@medknow.com

case of acute DILI associated with LEV administration for SE control. As part of this case, we reviewed the available literature and found only eight previously reported cases.^[4,13-19] In neurosurgical patients treated with LEV, the careful observation of serum liver enzyme concentration is recommended because a wide variety of drugs have a potential risk of eliciting DILI, even if they have a low liver metabolism profile.

Case Report

A 44-year-old man was admitted to our hospital because of generalized convulsion. His history included treatment for a brain contusion that occurred due to a traffic accident 20 years ago, and since then, valproic acid has been administered following a diagnosis of symptomatic epilepsy. Head computed tomography on admission showed no newly detected lesions. In the emergency

room, diazepam was intravenously administered but the convulsion was uncontrollable; he was clinically diagnosed with SE, and LEV 3000 mg/day was started. Laboratory values on admission (before LEV administration) were as follows: alanine aminotransferase (ALT), 17 IU/L; aspartate transaminase (AST) 41 IU/L; and total bilirubin, 0.59 mg/dl. Viral serology for hepatitis B and hepatitis C was negative. He had a drinking habit. Within the several hours that followed initial LEV administration, he developed high-grade fever (39.0°C) and his ALT and AST levels were 93 and 459 IU/L, respectively. On the next day, his serum biochemistry results further deteriorated as follows: ALT, 346 IU/L; AST, 1,207 IU/L; and total bilirubin, 1.42 mg/dl. LEV administration was stopped, and he was conservatively treated with monoammonium glycyrrhizinate, glycine L-cysteine hydrochloride hydrate, and intravenous infusion of lactated Ringer's solution. His laboratory values at 12 h

Table 1: Digestive Disease Week Japan 2004 scale score of the present case

Scale	Definition		DDW-J	Present case
	Hepatocellular type	Cholestatic type		
Time to onset				
From the beginning of the drug administration	5-90 days	5-90 days	+2	+1
	<5 days, or >90 days	<5 days, or >90 days	+1	
From cessation of the drug	≤15 days	≤30 days	+1	-
	>15 days	>30 days	0	
Course of the reaction				
Difference between the peak of ALT or ALP and upper limit of normal values	>50% decrease within 8 days	-	+3	+3
	>50% decrease within 30 days	>50% decrease within 180 days	+2	
	-	<50% decrease within 180 days	+1	
	<50% decrease within 30 days	Unchanged or re-elevation	0	
	<50% decrease 30 days after cessation	-	-2	
Risk factor	Alcohol	Alcohol/pregnant	+1	+1
Other causes*	All causes of group 1 and 2 can be excluded		+2	+1
	All causes of group 1 can be excluded		+1	
	4 or 5 causes of group 1 can be excluded		0	
	<3 causes of group 1 can be excluded		-2	
	Causes except for drug is highly suspected		-3	
Previous information on hepatotoxicity	Yes		+1	0
Eosinophilia	Yes		+1	0
DLST	Positive		+2	+2
	False-positive		+1	
	Negative or not examined		0	
Response to occasional re-administration				
Readministration without comedication	Doubled in ALT value	Doubled in ALP value	+3	0
Readministration with comedication	Doubled in ALT value	Doubled in ALP value	+1	
Readministration with/without comedication	Within normal range in ALT value	Within normal range in ALP value	-2	
Total score**				+8

*Group I – HAV, HBV, HCV, biliary obstruction, alcoholism, and acute recent hypotension history, Group II – Cytomegalovirus and Epstein-Barr virus, **Total score – Unlikely; ≤2, possible; 3 or 4, Probable; ≥5. ALP – Alkaline phosphatase, ALT – Alanine aminotransferase, DLST – Drug-induced lymphocyte stimulation test, DDW-J – Digestive Disease Week Japan 2004

after drug withdrawal were as follows: ALT, 1,192 IU/L; AST, 3,150 IU/L; and total bilirubin, 2.02 mg/dl. With additional time, they gradually decreased even further toward the normal range [Figure 1].

At this point, to confirm whether LEV was responsible for the patient's acute liver injury, a drug-induced lymphocyte stimulation test (DLST) (SRL, Inc., Tokyo, Japan) was performed (a stimulation index of 180% or greater is considered to indicate a positive response). The results indicated a positive response with respect to LEV, with a stimulation index of 300%. In light of these findings, it was determined that LEV could not be readministered in this patient, and lacosamide was instead chosen. Based on DDW-J scale, levetiracetam-induced liver injury was highly suspected [Table 1]. He showed no further hematological adverse events or seizure recurrence and was transferred to a rehabilitation center 2 months after admission.

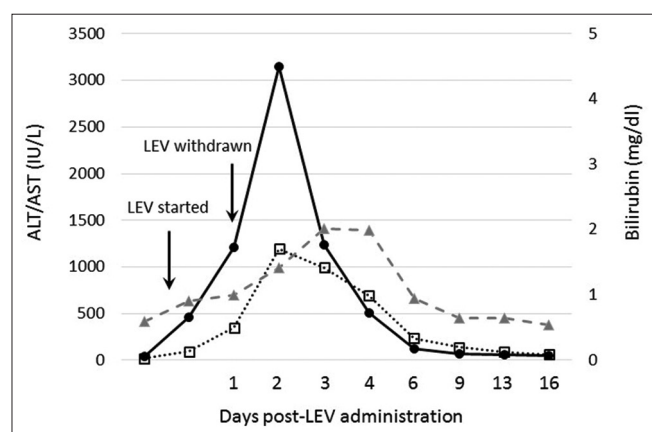


Figure 1: A graphical illustration of alanine aminotransferase and aspartate transaminase (on the left axis) and total bilirubin (on the right axis)

Discussion

LEV-induced DILI is extremely rare; only nine relevant cases, including ours, are summarized in Table 2. Unlike many other AEDs, LEV is mainly excreted by the kidney and is not metabolized in the liver by the cytochrome P450 enzyme system. Thus, liver toxicity due to LEV occurs very infrequently. DILI is classified into two subtypes based on underlying mechanism – namely, an immune-mediated type and nonimmune mediated type.^[20] Immune-mediated DILI is considered to be an allergic reaction occurring within one to 6 weeks of drug administration, and characteristics include the presence of fever, rash, eosinophilia, and rapid recurrence of liver toxicity on reexposure to the drug. In such cases, liver injury can be caused by drugs, even if they have low profile of liver metabolism, so the occurrence of this type of DILI is unpredictable. On the other hand, non-immune mediated type is characterized by the consistent absence of the features of hypersensitivity and a very important feature is the long latency period of many months. So, it is important to differentiate liver injury occurred immediately after drug administration and after long-term usage. Some of the cases listed in Table 2 showed acute liver injury, but in the other cases, DILI was revealed several months after drug administration. Although it is not easy to speculate on the mechanism of DILI, the onset of a sudden high-grade fever and early liver enzyme elevation indicated the presence of immune-mediated DILI in our case.

Recently, serious cases of DILI possibly associated with LEV have been reported.^[4,16,18] Khoury *et al.* discussed one case in which a patient who received a combination therapy of LEV and temozolomide died due to acute fulminant liver failure.^[16] Selvaraj *et al.* reported another case in which the patient demonstrated liver enzyme elevation 8 weeks

Table 2: Summary of reported cases of drug-induced liver injury associated with levetiracetam

	Age (sex)	Duration	Dose of LEV	ALT (IU/L)	AST (IU/L)	Total bilirubin	Others	Treatment
Tan <i>et al.</i> , 2008	21 years (man)	1 month	N/A	1610	N/A	591 mmol/L	-	Liver transplantation
Broli <i>et al.</i> , 2010	58 years (woman)	4 months	1500 mg	33	27	N/A	Gamma GTP 157 U/L	Conservative
Xiong <i>et al.</i> , 2012	10 months (girl)	5 months	27.8 mg/kg	N/A	N/A	N/A	ALP 1613 U/L	Conservative
Sethi <i>et al.</i> , 2013	62 years (woman)	10 days	1000 mg	289	184	N/A	-	Conservative
Gutiérrez-Grobe <i>et al.</i> , 2013	22 years (woman)	2 months	1000 mg	4341	10387	2.14 mg/dL	-	Conservative
Azar and Aune, 2014	25 years (woman)	2 days	3000 mg	1083	1115	2.7 mg/dL	-	Conservative
Selvaraj <i>et al.</i> , 2016	50 years (man)	8 weeks	N/A	4800	7000	20.4 mg/dL	-	Liver transplantation
Khoury <i>et al.</i> , 2017	N/A	N/A	N/A	N/A	N/A	N/A	-	Death
Present case	44 years (man)	1 day	3000 mg	1192	3150	2.02 mg/dL	-	Conservative

ALP – Alkaline phosphatase, ALT – Alanine aminotransferase, AST – Aspartate transaminase, GTP – Glutamyl transferase, LEV – Levetiracetam, N/A – Not available

after LEV initiation. Further aggravation was evident in this individual 12 weeks after starting administration, but LEV was continued. As a result, laboratory work showed an AST of 4800 IU/L, an AST in the range of 7000 IU/L, and a total bilirubin value of 20.4 mg/dl, and finally, liver transplantation was inevitable.^[4] Delayed drug withdrawal can aggravate any existing injury to the liver, resulted in irreversible organ failure. In our case, frequent blood examination led us to identify the presence of liver injury immediately; we were able to stop LEV administration and start salvage therapy within an appropriate time frame, avoiding fulminant liver failure.

For patients with DILI, it is important but not easy to identify the drug responsible for the condition. In fact, the causative drug was determined based on circumstantial evidence in all of the previously reported cases listed in Table 2. In our case, DLST was performed and showed a positive response for LEV. DLST is an *in vitro* immunological examination that measures the proliferation of T lymphocytes in response to a suspected drug. It is safe and specific in comparison with a classical *in vivo* sensitization test, so it has already been considered as a reliable diagnostic modality for drug-induced eruption or liver injury.^[21] Although some concern about its technical sensitivity and specificity still exists, DLST can be helpful for diagnostic purposes.^[22,23] In fact, DLST is included in the diagnostic criteria of DDW-J scale. DDW-J scale was developed by modifying the OIOMS/RUCAM scale. The exclusion of the factor of comedication and inclusion of the factors of DLST findings and eosinophilia are characteristics of DDW-J scale. Although it is not applicable for all cases, DDW-J scale is useful to assess the diagnosis of DILI, because of its high sensitivity and specificity.

Conclusion

We have presented a rare case of DILI associated with LEV administration for SE treatment. Although LEV undergoes minimal hepatic metabolism, neurosurgeons should keep in mind that delayed drug withdrawal can lead to catastrophic liver injury. For such patients, readministration of the drug should be avoided, and an *in vitro* examination such as DLST can be useful to arrive at a definitive diagnosis.

Declaration of patient consent

The authors certify that they have obtained all appropriate patient consent forms. In the form the patient(s) has/have given his/her/their consent for his/her/their images and other clinical information to be reported in the journal. The patients understand that their names and initials will not be published and due efforts will be made to conceal their identity, but anonymity cannot be guaranteed.

Financial support and sponsorship

Nil.

Conflicts of interest

There are no conflicts of interest.

References

1. Logroscino G, Hesdorffer DC, Cascino G, Hauser WA, Coeytaux A, Galobardes B, *et al.* Mortality after a first episode of status epilepticus in the United States and Europe. *Epilepsia* 2005;46 Suppl 11:46-8.
2. Rossetti AO, Logroscino G, Milligan TA, Michaelides C, Ruffieux C, Bromfield EB, *et al.* Status Epilepticus Severity Score (STESS): A tool to orient early treatment strategy. *J Neurol* 2008;255:1561-6.
3. Crepeau AZ, Treiman DM. Levetiracetam: A comprehensive review. *Expert Rev Neurother* 2010;10:159-71.
4. Selvaraj V, Madabushi JS, Gunasekar P, Singh SP. Levetiracetam associated acute hepatic failure requiring liver transplantation: Case report. *J Neurol* 2016;263:814-5.
5. Bernal W, Wendon J. Acute liver failure. *N Engl J Med* 2013;369:2525-34.
6. Lee WM. Acute liver failure in the United States. *Semin Liver Dis* 2003;23:217-26.
7. Ostapowicz G, Fontana RJ, Schiødt FV, Larson A, Davern TJ, Han SH, *et al.* Results of a prospective study of acute liver failure at 17 tertiary care centers in the United States. *Ann Intern Med* 2002;137:947-54.
8. Lammert C, Björnsson E, Niklasson A, Chalasani N. Oral medications with significant hepatic metabolism at higher risk for hepatic adverse events. *Hepatology* 2010;51:615-20.
9. Corsini A, Bortolini M. Drug-induced liver injury: The role of drug metabolism and transport. *J Clin Pharmacol* 2013;53:463-74.
10. Lewis JH, Kleiner DE. Hepatic injury due to drugs chemicals and toxin in MacSween's Pathology of the Liver. In: Burt AD, Portmann BC, Feffel LD, Eds., Churchill Livingstone, Elsevier, 2006. p. 649-759.
11. Hanatani T, Sai K, Tohkin M, Segawa K, Kimura M, Hori K, *et al.* A detection algorithm for drug-induced liver injury in medical information databases using the Japanese diagnostic scale and its comparison with the Council for International Organizations of Medical Sciences/the Roussel Uclaf Causality Assessment Method scale. *Pharmacoepidemiol Drug Saf* 2014;23:984-8.
12. Tajiri K, Shimizu Y. Practical guidelines for diagnosis and early management of drug-induced liver injury. *World J Gastroenterol* 2008;14:6774-85.
13. Azar NJ, Aune P. Acute pancreatitis and elevated liver transaminases after rapid titration of oral levetiracetam. *J Clin Neurosci* 2014;21:1053-4.
14. Broli M, Provini F, Naldi I, Bisulli F, Sama C, Baruzzi A, *et al.* Unexpected gamma glutamyltransferase rise increase during levetiracetam monotherapy. *Epileptic Disord* 2010;12:81-2.
15. Gutiérrez-Grobe Y, Bahena-Gonzalez JA, Herrera-Gomar M, Mendoza-Diaz P, García-López S, González-Chon O, *et al.* Acute liver failure associated with levetiracetam and lacosamide combination treatment for unspecified epileptic disorder. *Case Rep Emerg Med* 2013;2013:634174.
16. Khoury T, Chen S, Abu Rmeileh A, Daher S, Yaari S, Benson AA, *et al.* Acute liver injury induced by levetiracetam and temozolomide co-treatment. *Dig Liver Dis* 2017;49:297-300.
17. Sethi NK, Sethi PK, Torgovnick J, Arsura E, Cukierwar F. Asymptomatic elevation of liver enzymes due to levetiracetam: A case report. *Drug Metabol Drug Interact* 2013;28:123-4.

18. Tan TC, de Boer BW, Mitchell A, Delriviere L, Adams LA, Jeffrey GP, *et al.* Levetiracetam as a possible cause of fulminant liver failure. *Neurology* 2008;71:685-6.
19. Xiong N, Hou L, Lu N, Mohamed AA, Wang T, Huang Y, *et al.* Probable levetiracetam-related serum alkaline phosphatase elevation. *BMC Neurol* 2012;12:97.
20. Katarey D, Verma S. Drug-induced liver injury. *Clin Med (Lond)* 2016;16:s104-9.
21. Pichler WJ, Tilch J. The lymphocyte transformation test in the diagnosis of drug hypersensitivity. *Allergy* 2004;59:809-20.
22. Beers MH, Berkow R. Hypersensitivity to drugs. *The Merck Manual of Diagnosis and Therapy*. 17th ed. Whitehouse Station: Merck & Co., Inc.; 1999. p. 1064-7.
23. Mantani N, Kogure T, Tamura J, Shimada Y, Terasawa K. Lymphocyte transformation test for medicinal herbs yields false-positive results for first-visit patients. *Clin Diagn Lab Immunol* 2003;10:479-80.