

An Unusual Presentation of a Huge Nabothian Cyst of Cervix With Manifestation of Uterine Prolapse: A Case Report

Sushna Maharjan  and Mamata Tiwari

Department of Pathology, Chitwan Medical College Teaching Hospital, Bharatpur, Chitwan, Nepal.

Clinical Medicine Insights: Case Reports

Volume 13: 1–4

© The Author(s) 2020

Article reuse guidelines:

sagepub.com/journals-permissions

DOI: 10.1177/1179547620974676



ABSTRACT

BACKGROUND: Nabothian cysts are common benign cervical lesions in women of reproductive age. They usually occur due to childbirth or minor trauma; mostly are small and asymptomatic. However, huge nabothian cysts may have variable presentation and can even mimic malignancy thus, biopsy is recommended to rule out malignancy. The unusual presentation of nabothian cyst as uterine prolapse makes it a diagnostic challenge for management of the patient similar to the present case.

CASE REPORT: We report a case of a huge nabothian cyst in a perimenopausal, multiparous woman who presented with complaints of something coming out of vagina suddenly after mild heavyweight lifting and pain abdomen. Pelvic examination revealed a second degree uterine prolapse with a large lump protruding outside the vagina. Transvaginal ultrasonography demonstrated a multicystic cervical mass of size 9.5 cm × 8.0 cm arising from the posterior lip of cervix that was protruding through the vaginal canal. After excision of mass, prolapse became first degree. Histopathologic diagnosis was a cervical nabothian cyst. Patient had persisting first degree uterine prolapse along with posterior vaginal wall prolapse on subsequent postoperative follow ups. Hence, vaginal hysterectomy with repair to the vaginal wall was performed later.

CONCLUSION: The present case of nabothian cyst is reported for its unusual presentation as uterine prolapse. The risk factors for pelvic organ prolapse (POP) in the present case are advancing age, multiparity and perimenopausal status. The connective tissue and levator ani muscle became weak and the nabothian cyst unmasked the POP that was latent and asymptomatic by increasing the prolapse from first degree to second degree.

KEYWORDS: Cervical, huge nabothian cysts, uterine prolapse

RECEIVED: May 29, 2020. **ACCEPTED:** October 29, 2020.

TYPE: Case Report

FUNDING: The author(s) received no financial support for the research, authorship, and/or publication of this article.

DECLARATION OF CONFLICTING INTERESTS: The author(s) declared no potential conflicts of interest with respect to the research, authorship, and/or publication of this article.

CORRESPONDING AUTHOR: Sushna Maharjan, Department of Pathology, Chitwan Medical College Teaching Hospital, Bharatpur-10, 44200, P.O. Box: 42, Chitwan, Nepal. Email: sushnamaharjan74@gmail.com

Introduction

A nabothian cyst is a mucus-filled cyst that can be visible as a nodule on the surface of the uterine cervix. It is also called mucinous retention cyst or epithelial cyst. It occurs commonly in reproductive age as a solitary or multiple, translucent to opaque nodule with a rare clinical significance. Nabothian cysts may be identified in 12% of routine pelvic magnetic resonance imaging (MRI) scans.¹ The cysts vary in size from few millimeters to several centimeters.² Most of the cysts are free of symptoms because of their small size (2–10 mm in diameter).^{3,4} They may occasionally reach about 4 cm growing up to 8 cm that can cause a variety of symptoms and may clinically resemble as uterine tumors.⁵

If diagnosis is uncertain, and cysts are deep seated or large causing bothersome symptoms, excision is required for histopathologic evaluation (HPE) to rule out malignancy.^{6,7} Only few cases of nabothian cysts, those presented with uterine prolapse are reported till date. The etiologies of pelvic organ prolapse (POP) are weakness of pelvic muscles, connective tissues, and pelvic fascia. It may even occur due to pelvic masses.⁸ There are various risk factors for POP such as multiparity, increased intra-abdominal pressure (eg, bearing heavyweights,

exerting physical effort), obesity, advanced age, menopause, past hysterectomies, crouching at labor, prolonged labor.^{9,10} POP due to nabothian cyst similar to the present case is a rare condition.^{3,11} The present case is a report of 52-year-old perimenopausal, multiparous woman who presented with symptoms of uterine prolapse due to a large nabothian cyst.

Case Report

A 52-year-old perimenopausal, multiparous woman with gravida 4, para 4 came to an Emergency Department at Chitwan Medical College Teaching Hospital (CMC-TH) with complaints of something coming out of vagina suddenly after mild heavyweight lifting and pain abdomen for 4 hours. Her last menstrual period was 18 days back and menstrual bleeding was lighter. She was having irregular and longer cycles since last 1.5 year. She had Pap smear done 4 months back. The report was negative for intraepithelial lesion or malignancy.

No urinary or bowel complaints, chronic cough, constipation, past medical history and family history of malignancy, and any previous cervical surgery. She had all vaginal deliveries. General physical and systemic examination was unremarkable. Abdomen was soft and non-tender on palpation. Pelvic



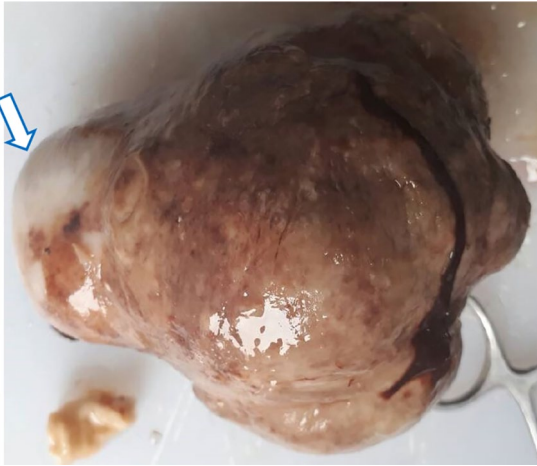


Figure 1. Gross picture of specimen shows a cystic mass with focal epidermidization (arrow).



Figure 2. Cut section of mass revealed multiloculated, cystic spaces of varying size filled with mucinous material.

examination revealed a second-degree cervical prolapse with a mass coming out of introitus. Mass was firm to soft in consistency and slightly reducible. Uterus was parous size, mobile, firm, mildly tender, and the fornices were free. Initial differential diagnosis was uterovaginal prolapse and cervical fibroid. Tumors markers such as, cancer antigen 125, cancer antigen 19-9 and carcinoembryonic antigen were within normal limits. Transvaginal ultrasonography demonstrated a multicystic cervical mass of size 9.5 cm × 8.0 cm arising from the posterior lip of cervix that was protruding through the vaginal canal. The differential diagnosis made after transvaginal ultrasonography was nabothian cyst and cervical leiomyoma with multicystic degeneration causing uterine prolapse. The uncertainty of diagnosis still existed after imaging hence; laparoscopic biopsy was performed before definitive surgery to confirm malignancy. Benign lesion (nabothian cyst) was confirmed on biopsy. Thus, excision of the mass was planned. Per operative finding was a polypoid mass arising from the posterior lip of cervix. After excision of mass, prolapse became first degree. The cystic mass was sent for HPE. The patient was informed and counseled about the possibility of requirement of further surgical intervention if the first degree uterine prolapse progresses, and affects her quality of life.

On gross examination the mass was large; measuring 9.5 cm × 8.0 cm. Focal epidermidization (Figure 1) with an ulcer was observed on external surface. Cut section showed multiloculated, cystic spaces of varying size filled with mucinous material (Figure 2). On microscopy, the outer cyst wall was lined by keratinized stratified squamous epithelium (Figure 3) and the inner cyst wall was lined by single layer of ciliated low columnar epithelium without cellular atypia (Figures 3 and 4). Histopathological diagnosis was a huge cervical nabothian cyst. At postoperative follow up after 1 week, 1 month, 3 months, and 6 months; first-degree cervical prolapse was still persisting along with posterior vaginal wall prolapse (coming up into the introitus). Hence, vaginal hysterectomy with repair to the vaginal wall was performed.

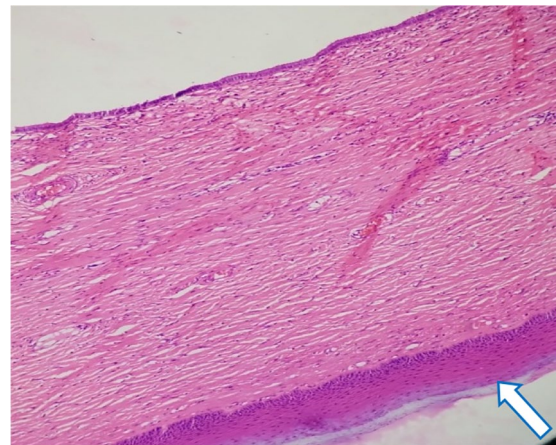


Figure 3. Nabothian cyst; outer cyst wall lined by keratinized stratified squamous epithelium (arrow) [H&E; ×100 magnification].

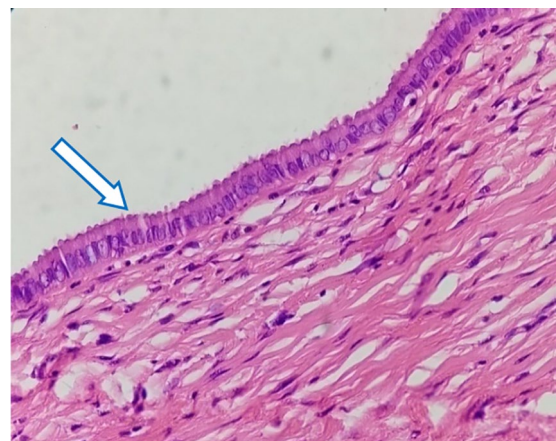

Figure 4. Nabothian cyst; inner cyst wall lined by single layer of ciliated low columnar epithelium (arrow) [H&E; ×400 magnification].

Discussion

In chronic cervicitis and its reparative processes, or as part of the physiologic metaplasia, the squamous epithelium of the uterine cervix proliferates and covers the columnar epithelium

of the endocervical glands which is thought to play role in the pathogenesis of nabothian cysts.¹² Inflammatory process can block an endocervical gland opening that leads to accumulation of mucosal secretion in small subdermal pockets.¹³ The weight of the large nabothian cyst on the cervix might have caused expansion of the vaginal portion of the cervix and it could be the reason for prolapse in the present case.^{3,11,14} Nigam et al³ and Çift et al¹¹ had reported uterine prolapse in nulliparous women due to large nabothian cyst. However, Ulubay et al¹⁴ had discussed a case of large nabothian cyst in a multiparous woman similar to the present case.

POP mostly occurs in postmenopausal and multiparous women. There are many risk factors for POP such as multiparity, increased intra-abdominal pressure (eg, bearing heavy-weights, exerting physical effort), obesity, advanced age, menopause, past hysterectomies, crouching at labor, prolonged labor.^{9,10} POP is rare in nulliparous women. The risk factors for POP in the nulliparous include inherent defect in pelvic supports for example Ehler-Danlos syndrome, congenital shortness of vagina, and deep uterovesical and uterorectal pouches.³ It may also occur due to spina bifida occulta and split pelvis which result in inherent weakness of pelvic floor support. Family history of prolapse also suggests its congenital nature.

Herath et al¹⁵ had reviewed the literature on nonpuerperal uterine inversion (NPUI) by collecting the data of published case reports from 1911 to September 2018. NPUI is a rare gynecological condition with diagnostic and surgical challenges. Leiomyoma is the most common etiology. The other common causes are malignancies and idiopathic. However; POP, fibrosarcoma, epidermoid carcinoma, endometrial sarcoma, carcinosarcoma, rhabdomyosarcoma, endometrial polyp, immature teratoma, and combination of fibroid and a cervical carcinoma are rare causes of NPUI.

Large nabothian cysts may compress a surrounding organ leading to pressure symptoms. When the rectum is compressed, it may cause abnormal defecation and tenesmus.¹ Harou et al¹⁶ had reported a case of primary infertility in a 33-year-old woman due to obstruction of the cervix by multiple nabothian cysts.

Various cervical pathologies should be kept in mind for cystic cervical lesions. The differential diagnoses of a cystic lesion in the cervical stroma are adenoma malignum, deep nabothian cysts, other benign tumors of cervix and well-differentiated adenocarcinoma.^{7,12} Benign tumors of cervix are endocervical polyps, leiomyomas, endometriosis, squamous papilloma, microglandular hyperplasia, and mesonephric duct remnants.⁷

According to Yıldız et al¹⁷ transvaginal ultrasonography and MRI are the most useful imaging techniques for cervical cystic lesions. However, huge nabothian cysts must be sent for HPE to exclude other malignant glandular cervical lesions and adenoma malignum (also called minimal deviation adenocarcinoma, a rare entity), the appearance of which mimic deep and large nabothian cysts. These malignant tumors are

deeply invading into the cervical stroma and a solid component surrounding or separating multiple cysts are regarded as histological clues to distinguish such malignant tumors from nabothian cysts but exact differentiation is not always easy to establish diagnosis. Hence, it is a big challenge for pathologists to make accurate diagnosis. The high suspicion of gynecologist also gives a clue for diagnosis.¹⁸⁻²¹ Thus, preoperative pelvic examination and radiographic imaging are important for huge nabothian cysts to avoid unnecessary hysterectomy.²² In the present case, transvaginal ultrasonography demonstrated a multicystic cervical mass that was protruding through the vaginal canal. Exclusion of malignancy and excision of the causative benign tumor are necessary before repair or surgery of prolapse. Laparoscopic biopsy was performed before definitive surgery to confirm malignancy in the present case. Nabothian cyst was confirmed on biopsy. Thus, excision of the mass was done.

D'Alessandro et al²³ had reported an interesting case of gastric-type mucinous endocervical adenocarcinoma in presence of nabothian cysts. This tumor has aggressive clinical behavior. They had discussed their possible relationship with the nabothian cysts as the transvaginal ultrasound scan of the patient showed multiple nabothian cysts, associated with an uneven appearance and a plentiful vascularization of the uterus. Many benign and malignant endocervical glandular lesions, showing gastric differentiation unrelated to human papillomavirus (HPV) have been mentioned.²⁴ Minimal deviation adenocarcinoma and lobular endocervical glandular hyperplasia have a gastric phenotype and immunophenotype.²⁵

Nabothian cysts usually do not require any treatment unless the patient becomes symptomatic or when the characteristic of lesion is unclear and malignancy cannot be ruled out. Cryocautery, electrocautery, and excision of cyst/cystectomy can be performed whenever required.²⁶ Few patients may require hysterectomy to relieve the symptoms. The cases reported by Temur et al,¹ Yıldız et al,¹⁷ and Yelikar et al²⁶ required hysterectomy to relieve persisting symptoms caused by nabothian cysts due to compression of rectum, chronic pelvic pain, and continuous copious per vaginal thin watery discharge, respectively.

Generally, patients with first degree prolapse are advised to do Kegel's exercise and do not require surgery. However, women with first degree cervical prolapse should be counseled and reviewed on regular follow ups. In some cases the cervix might have only first-degree prolapse, but vaginal wall prolapse is more than cervical prolapse that cause the symptoms. Thus, such cases require vaginal hysterectomy.²⁷ Chhabra et al²⁷ mentioned 2.6% women with first degree cervico-uterine prolapse accompanying varying degrees of anterior/posterior vaginal wall prolapse who underwent vaginal hysterectomy. In the present case, the patient had persisting first-degree cervical prolapse along with posterior vaginal wall prolapse. Hence, vaginal hysterectomy with repair to the vaginal wall was performed.

A case of a spontaneous pregnancy after treatment of obstructive nabothian cyst was reported in the literature.²⁸ Vural et al⁴ had discussed a case of a large nabothian cyst in 38 weeks pregnant woman obstructing labor passage. Simple drainage was performed to allow the spontaneous vaginal delivery and a persisting cystic mass was removed by excision after 2 months of the delivery. Wu et al²² had performed a simple incision for local drainage to reduce size of giant nabothian cyst in a 45-year old woman. Therefore, simple drainage can manage a huge nabothian cyst in the emergency to improve the outcome.

Conclusion

Huge nabothian cysts may have variable presentation that may cause a diagnostic challenge. We reported a case of nabothian cyst for its unusual presentation as uterine prolapse. The risk factors for POP in the present case are advancing age, multiparity, and perimenopausal status. The connective tissue and levator ani muscle became weak and the nabothian cyst unmasked the POP that was latent and asymptomatic by increasing the prolapse from first degree to second degree.

Acknowledgements

We would like to thank Dr. Dibika Khadka for helping us to obtain the pictures. We express sincere gratitude to the patient for giving us consent for publication of this case.

Authors' Contributions

SM: conception of the work, case analysis, and drafting the manuscript. MT: case analysis and revised it critically. Both authors read and approved the final manuscript.

Informed Consent

Written informed consent was obtained from the patient for publication of this case report and any accompanying images.

ORCID iD

Sushna Maharjan  <https://orcid.org/0000-0001-9611-6718>

REFERENCES

1. Temur I, Ulker K, Sulu B, Karaca M, Aydin A, Gurcu B. A giant cervical nabothian cyst compressing the rectum, differential diagnosis & literature review. *Clin Exp Obstet Gynecol.* 2011;38:276-279.
2. Dolan MS, Hill C, Valea FA. Benign gynecologic lesions. In: Lobo RA, Gershenson DM, Lentz GM, eds. *Comprehensive Gynecology.* 7th ed. Elsevier; 2017: 370-422.
3. Nigam A, Choudhary, Raghunandan C. Large nabothian cyst: a rare cause of nulliparous prolapse. *Case Rep Obstet Gynecol.* 2012;2012:Article 192526, 2.
4. Vural F, Sanverdi I, Coskun AD, Kusgöz A, Temel O. Large nabothian cyst obstructing labour passage. *J Clin Diagn Res.* 2015;9:QD06-07.
5. Okamoto Y, Tanaka YO, Nishida M, Tsunoda H, Yoshikawa H, Itai Y. MR imaging of the uterine cervix: imaging-pathologic correlation. *Radiographics.* 2003;23:425-445; quiz 534-535.
6. Casey PM, Long ME, Marnach ML. Abnormal cervical appearance: what to do, when to worry? *Mayo Clin Proc.* 2011;86:147-151.
7. Malpica A, Robboy SJ. Cervical benign and nonneoplastic conditions. In: Mutter G, Robboy S, Prat J, eds. *Robboy's Pathology of Female Reproductive Tract.* 2nd ed. Elsevier; 2009: 141-166.
8. Shrestha B, Onta S, Choulagai B, Paudel R, Petzold M, Krettek A. Uterine prolapse and its impact on quality of life in the Jhaukhel-Duwakot Health Demographic Surveillance Site, Bhaktapur, Nepal. *Glob Health Action.* 2015;8:28771. doi:10.3402/gha.v8.28771
9. Gunasekera P, Sazaki J, Walker G. Pelvic organ prolapse: don't forget developing countries. *Lancet.* 2007;369:1789-1790.
10. Fritel X, Varnoux N, Zins M, Breart G, Ringa V. Symptomatic pelvic organ prolapse at midlife, quality of life, and risk factors. *Obstet Gynecol.* 2009;113: 609-616.
11. Çift T, Korkmaz E, Nizam R, Olgun M, Şenkutlu B. Large nabothian cyst: manifestation with pelvic organ prolapse in a nulliparous patient. *J Clin Anal Med.* 2016;7:262-264.
12. Sosnovski V, Barenboim R, Cohen HI, Bornstein J. Complex nabothian cysts: a diagnostic dilemma. *Arch Gynecol Obstet.* 2009;279:759-761.
13. Torkey HA. Huge nabothian cyst causing hematometra (case report). *Eur J Obstet Gynecol Reprod Biol.* 2016;207:238-240.
14. Ulubay M, Öztürk M, Fidan U, et al. Nabothian cyst mimicking endocervical polyp which prolapsed to the vagen. *Cukurova Med J.* 2015;40:1-4.
15. Herath RP, Patabendige M, Rashid M, Wijesinghe PS. Nonpuerperal Uterine Inversion: what the Gynaecologists Need to Know? *Obstet Gynecol Int.* 2020; 2020:Article ID 8625186, 12.
16. Harou K, Elfarji A, Bassir A, Boukhanni L, Asmouki H, Soummami A. Multiple nabothian cysts: a cause of cervical obstruction. *Open Access Library J.* 2019;6:e5212. doi:10.4236/oalib.1105212
17. Yıldız C, Özsoy AZ, Bahçe S, Sümer D, Çetin A. Multiple and large nabothian cysts: a case report. *Cumhuriyet Med J.* 2009;31:456-459.
18. Yamashita Y, Takahashi M, Katabuchi H, Fukumatsu Y, Miyazaki K, Okamura H. Adenoma malignum: MR appearances mimicking nabothian cysts. *AJR Am J Roentgenol.* 1994;162:649-650.
19. Doi T, Yamashita Y, Yasunaga T, et al. Adenoma malignum: MR imaging and pathologic study. *Radiology.* 1997;204:39-42.
20. Mikami Y, Hata S, Fujiwara K, Imajo Y, Kohno I, Manabe T. Florid endocervical glandular hyperplasia with intestinal and pyloric gland metaplasia: worrisome benign mimic of "adenoma malignum". *Gynecol Oncol.* 1999;74:504-511.
21. Yoden E, Mikami Y, Fujiwara K, Kohno I, Imajo Y. Florid endocervical glandular hyperplasia with pyloric gland metaplasia: a radiologic pitfall. *J Comput Assist Tomogr.* 2001;25:94-97.
22. Wu P-Y, Hsu K-F, Chang C-H, Chang FM. Ultrasonographic diagnosis and treatment of a giant uterine cervical nabothian cyst. *J Med Ultrasound.* 2012; 20:169-172.
23. D'Alessandro P, Giudicepietro A, Della Corte L, et al. A case of gastric-type mucinous endocervical adenocarcinoma in presence of nabothian cysts. *Eur J Obstet Gynecol Reprod Biol.* 2019;236:254-255.
24. Park CM, Koh HM, Park S, Kang HS, Shim SS, Kim SY. Gastric type mucinous endocervical adenocarcinoma of the uterine cervix: very rare and interesting case. *Obstet Gynecol Sci.* 2018;61:165-169.
25. Asaka S, Nakajima T, Momose M, Miyamoto T, Uehara T, Ota H. Trefoil factor family 2 protein: a potential immunohistochemical marker for aiding diagnosis of lobular endocervical glandular hyperplasia and gastric-type adenocarcinoma of the uterine cervix. *Virchows Arch.* 2019;474:79-86.
26. Yelikar KA, Deshpande SS, Deshmukh SF, Pagare SB. An unusual presentation of nabothian cyst: a case report. *Int J Reprod Contracept Obstet Gynecol.* 2015;4:1589-1591.
27. Chhabra S, Ramteke M, Mehta S, Bhole N, Yadav Y. Trends in Hysterectomy for Genital prolapse: rural experience. *Clin Med Insights Reprod Health.* 2013;7:11-16.
28. Turan G, Bahat PY, Çetin BA. Spontaneous pregnancy after obstructive nabothian cyst treatment. *Int J Reprod Contracept Obstet Gynecol.* 2017;6: 2625-2627.