

Case Research

Local recurrence of a parosteal osteosarcoma 21 years after incomplete resection

Andrés Combalia¹, Ernesto Muñoz-Mahamud¹, Antonio Palacín², Jaime Pomés³ and Vicente López¹

Abstract

Parosteal osteosarcoma (POS) is the most common form of surface osteosarcoma. Its symptoms are insidious and its duration prior to diagnosis is considerably longer than that of other types of osteosarcoma. We report a case of POS with a growing mass but no evidence of metastasis. This tumor, which was diagnosed as calcified hematoma with benign characteristics, was incompletely resected in our hospital 21 years before the diagnosis of recurrence. The patient underwent a wide en bloc resection in our hospital and was free of symptoms, with no signs of tumor recurrence or metastasis during a 53-month follow-up.

Key words Parosteal osteosarcoma, surface osteosarcoma, bone tumors, recurrence, juxtacortical osteosarcoma

Parosteal osteosarcoma (POS) is an unusual, slow-growing variant of osteosarcoma that occurs adjacent to the cortex of long bones. Initial diagnosis might be missed due to its similarity to other benign entities such as the myositis ossificans or a calcified hematoma. The natural evolution of POS is relatively benign. Its optimal treatment is wide surgical resection, with an overall survival rate of 80% to 90% [1-5]. Local recurrence is more frequent in POS patients treated with incomplete removal and increased risk of metastasis is associated with incomplete removal of POS.

We present herein a rare case of POS, with long-term follow-up. The patient was a 32-year-old man diagnosed with calcified hematoma with benign characteristics. This patient, who had a growing mass

but no evidence of metastasis, was misdiagnosed with a low-grade POS and underwent incomplete resection 21 years before the diagnosis of recurrence. After receiving a wide en bloc resection in our hospital, the patient was free of symptoms, with no signs of tumor recurrence or metastasis during a 53-month follow-up. It is extremely unusual to find a case of incompletely resected POS with no metastasis during such a long follow-up period. We highlight the importance of suspecting this entity to make a correct initial diagnosis.

Case Report

A 32-year-old Caucasian man, working as a professional welder, was admitted in our hospital in January 2004 after experiencing swelling and vague diffuse pain in his right shoulder for several weeks. The patient denied a history of trauma or previous fracture of the upper extremity in the humerus. His recent medical history was unremarkable and he denied any constitutional symptoms such as weight loss, fever, or malaise. He had been treated at our institution at the age of 11, in December 1982, due to an ossification on the proximal right humerus. The physical examination did not yield any evidence of either a palpable soft tissue mass or axillary adenopathy. The results of motor strength, distal pulses, and sensitive tests were normal. There was

Authors' Affiliations: ¹Department of Orthopaedic Surgery and Traumatology, Orthopaedic Oncology Unit, Hospital Clinic, Faculty of Medicine, University of Barcelona, Barcelona 08036, Spain; ²Department of Pathology, Hospital Clinic, Faculty of Medicine, University of Barcelona, Barcelona 08036, Spain; ³Department of Radiology, Hospital Clinic, Faculty of Medicine, University of Barcelona, Barcelona 08036, Spain.

Corresponding Author: Ernesto Muñoz-Mahamud, Department of Orthopaedic and Trauma Surgery, Hospital Clínic de Barcelona, University of Barcelona, C/ Villarroel 170, Barcelona 08036, Spain. Tel: +0034-932275400; Fax: +0034-932279871; Email: e.munoz.mahamud@gmail.com.

doi: 10.5732/cjc.011.10090

no alteration in the shoulder's range of motion and no other physically relevant findings.

The patient was pathologically diagnosed with a calcified hematoma with benign characteristics in November 1982. Both radiographs (Figure 1A) and xerography (Figure 1B) showed a regular calcified mass in the deltoid area that seemed to adhere to the bone surface but not fixed to the humerus, presenting a precise limit with the bone. According to the operative records, a round mass sized 2 cm × 1 cm was resected, but a small portion of the mass remained unresectable. The patient was followed up for 5 years after the operation, but no evidence of tumor growth or malignant changes were found. Therefore, the follow-up was stopped.

In January 2004, the patient sought a consultation for a growing mass with diffuse pain at the site of the previous surgery. Both plain radiographs and parosteal calcified images showed bony deformation (Figure 2A). Tc-99 Bone scintigraphic imaging showed an increased uptake of technetium-99m-methylene-diphosphonate in the proximal metaphyseal diaphyseal region of the right humerus but not in the rest of the skeleton (Figure 2B). Computerized tomography (CT) and magnetic resonance imaging (MRI) scans of the right upper extremity showed a large cortical lesion in the proximal diaphysis of the humerus with a significant cortical continuity and well-defined borders. No medullary extension was observed (Figure 2C). MRI revealed a hypodense mass

with gadolinium uptake in all sequences. The posterior cortical involvement and a minimal medullary extension were also observed (Figure 2D). The results of further studies including chest radiograph, chest CT, complete blood cell count, and erythrocyte sedimentation rate were normal. The patient's liver and renal functions showed no significant alteration.

Biopsies of the anteromedial and posterior exophytic lesions showed spindle-shaped fibroblastic cells with well-differentiated trabeculae of woven bone with an osteoblastic rim on its surface. The fibroblasts showed minimal cytological pleomorphism and small nucleoli. Focal islands of irregular primitive bone formation were visible between the lamellar trabeculae. No vascular invasion of the tumor was seen, and no dedifferentiated areas were identified (Figure 3A). Regarding the histological features, the lesion was identified as a grade I parosteal osteosarcoma of the humerus^[6].

A pathologist re-reviewed the tissue samples that had been examined in December 1982 and concluded that the initial lesion that had been diagnosed as calcified hematoma with benign characteristics should have been diagnosed as a POS (Figure 3B), which featured a high similarity with the current biopsy. Thus, 21 years after an incomplete resection of a POS, the patient showed a local recurrence with no systemic dissemination.

A wide en bloc resection of the 2/3 proximal parts of the humerus was performed and a proximal humerus prosthesis (GRMS, Stryker®) was then implanted. On

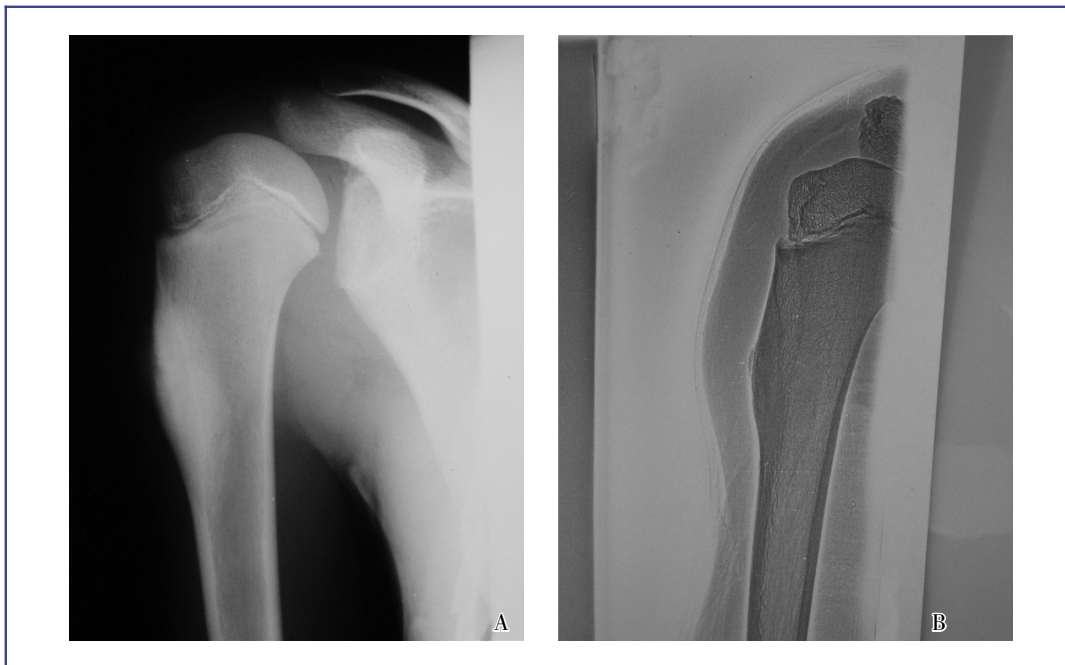

Figure 1. X-ray image and xerograph image of the right shoulder of the 11-year-old patient in November 1982. A, a vague calcified density is shown in the right proximal humerus, seeming to extend down with superficial location and bony attachment. B, xerograph image shows a mass located in the right proximal humerus.

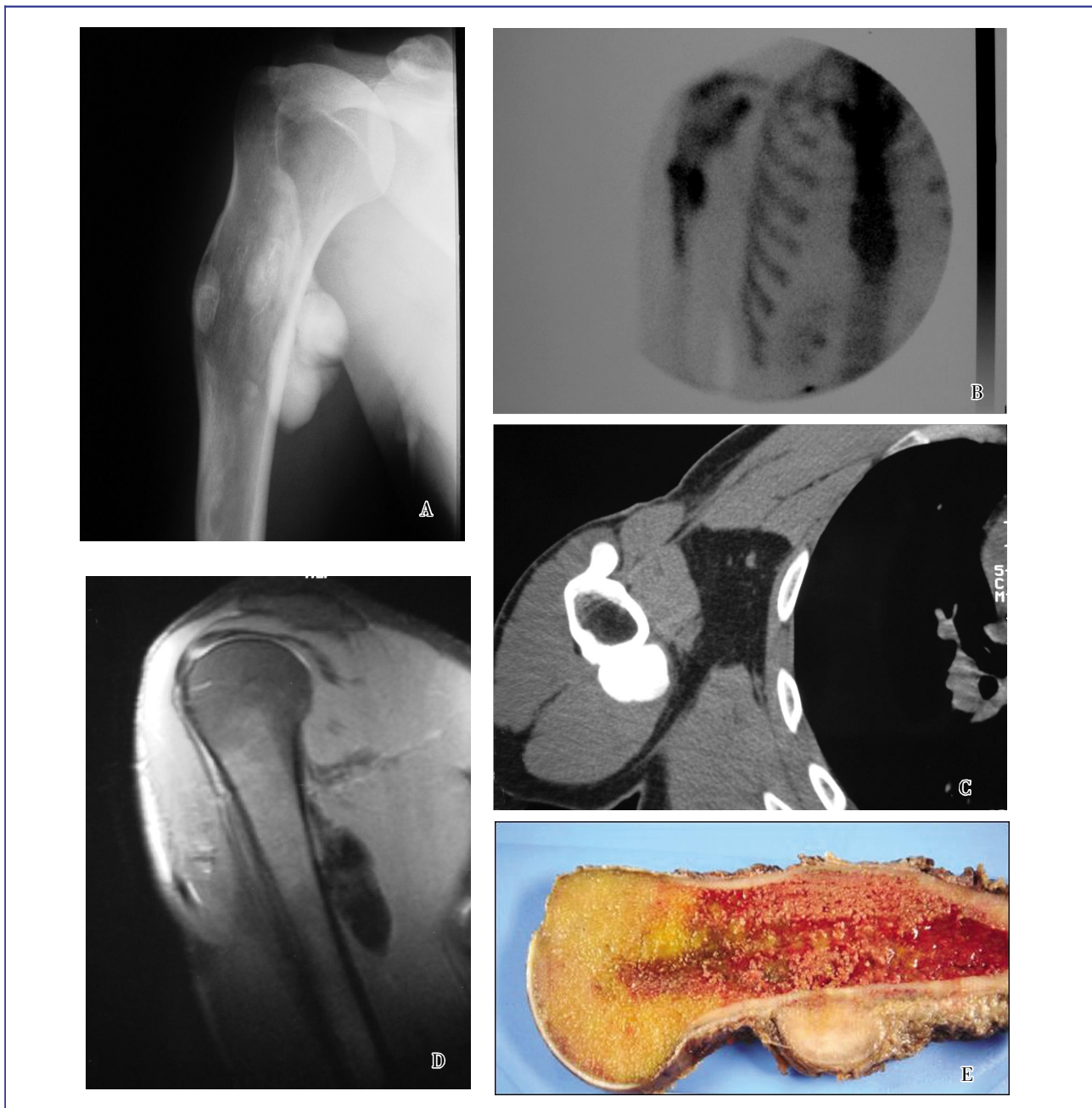


Figure 2. Imaging results of the bone lesion in January 2004. A, anteroposterior view of X-ray image depicts bony deformation and parosteal calcification. B, bone scintigraph shows increased uptake of Tc-99m methyl diphosphonate in the proximal right humerus. Involvement of the posterior cortical portion of the proximal humerus as well as minimal medullary extension are presented. C, axial computed tomography scan shows a large cortical lesion placed in the proximal diaphysis of the humerus with a significant cortical continuity and well-defined borders. The lesion size is 9.0 cm × 2.6 cm × 2.4 cm. No medullary extension is observed. D, magnetic resonance image shows a hypodense mass in the proximal diaphysis of the humerus with an uptake of gadolinium. The posterior cortical involvement and a minimal medullary extension are presented. E, on gross examination, the bone lesion is firm, exophytic and attached by a broad base to the cortex of the humerus.

gross examination, the lesion was a firm exophytic polypoid bony mass attached to the cortex of the humerus by a broad base (Figure 2E). No adjuvant

therapy was given because of the low-grade features of POS. During a 53-month follow-up after the tumor removal, the patient was free of symptoms, with no signs

of tumor recurrences or metastasis (Figure 4), and fully incorporated to a new professional activity. In terms of range of motion, the shoulder showed an abduction of 70° by tilting the scapula, an internal/ external rotation of 75°/35°, and a flexion/extension of 80°/15°.

Discussion

POS, also named juxtacortical sarcoma, is a low-grade neoplasm that grows on the surface of the

bone and accounts for approximately 1% to 6% of all cases of osteosarcoma, with a female-to-male ratio of 2:1. The peak of incidence is later than conventional osteosarcoma, usually in patients within their third and fourth decades of life. The most common location is the distal posterior femur, a site at which POS accounts for 70% to 80% of all disease cases, followed by the proximal part of the tibia or other bones of the appendicular skeleton^[7]. Although no clear etiology has been determined, genes on chromosome 12 have been reported in recent studies to be involved in POS

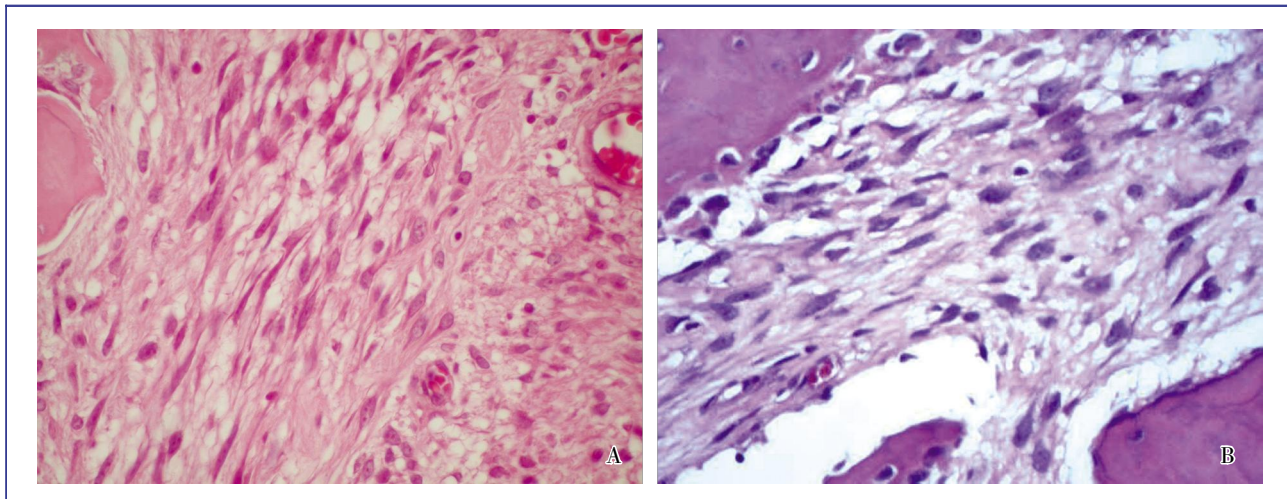


Figure 3. Histological examination of the tumor samples (hematoxylin and eosin stain, ×60). A, in the lesion removed from the patient by an incomplete resection in January 2004, the parosteal osteosarcoma containing mature-appearing bone tissues is surrounded with fibroblastic stroma with minimal cytologic pleomorphism and small nuclei. No vascular invasion of the tumor was observed and no dedifferentiated areas are identified. B, in the tumor tissue removed in December 1982, intertrabecular space is occupied by proliferating spindle cells with minimal cytologic pleomorphism. The two samples show similar histological features.

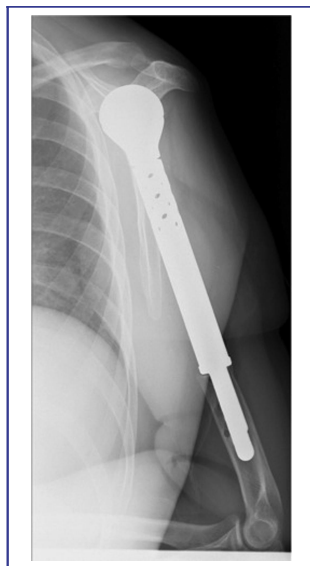


Figure 4. Post-operative X-ray imaging of the right proximal-humerus tumoral prosthesis. After tumor removal, a prosthesis was implanted into the right humerus of the patient in March 2010.

pathogenesis. Radiation exposure has also been linked to POS in a few case reports^[8].

Symptoms of POS are insidious and their duration prior to diagnosis is considerably longer than that in conventional osteosarcoma. The clinical findings usually involve a chronically growing mass that can seldom produce diffuse pain. The misdiagnosis of POS often leads to initial incorrect operative procedures, which may induce transformation of POS into a high-grade osteosarcoma and increase the risk of local recurrence and metastasis^[9].

On plain radiographs, the POS lesion has a characteristic appearance, presenting as an oval, radiodense, lobulated mass that grows on the bone cortex in an exophytic way. Typically, it is attached in a sessile fashion with a plane that separates the tumor from the underlying cortex. The periosteum is not affected because the POS can grow on its surface. The radiodensity decreases from the center towards the periphery and often correlates with the grade of the tumor. The presence of deep intralaminar radiolucencies strongly suggests that the tumor is dedifferentiated^[10].

Cross-sectional CT and MRI are useful tools for diagnosis as they show extension of the tumor into the medullar cavity or help identify areas with a high possibility of dedifferentiation. MRI is required to stage local recurrence or in cases where radiography has failed to confirm clinically suspected recurrence.

POS is composed of proliferating low-grade spindle-shaped fibroblastic cells with well-differentiated trabeculae of bone, constituting a less aggressive form of osteosarcoma. The fibroblasts in these tumors look deceptively benign because they show minimal pleomorphism. Histological grade is the most important factor in predicting clinical behavior, and three grades have been distinguished. Grades I and II, which correspond to the conventional form, have a low level of malignancy, whereas grade III, which corresponds to the dedifferentiated form that manifests atypia and mitoses, has a high level of malignancy^[6]. Unni *et al.*^[11] reported a case in which a tumor was histologically identified as a grade I POS. Histological diagnosis for this tissue proved challenging because of well-differentiated fibroblast features and mature tumor bone. Thus, the tissue could have been classified as a benign reactive lesion and histologically misdiagnosed. Dedifferentiation was observed in 15% of cases at the time of diagnosis or, most often, at the time of recurrence^[11]. This dedifferentiation manifested as osteosarcoma, fibrosarcoma, or malignant histiocytoma^[11]. In the case reported herein, no areas of dedifferentiation were found.

Camargo *et al.*^[12] reported 18 cases of POS in which most recurrences occurred in patients with histological grade II disease. In the presently reported case, the tissue samples were initially misdiagnosed and corresponded to a grade I POS that showed local

recurrence 21 years after partial resection. Bertoni *et al.*^[10] described the data of 120 patients with POS in which dedifferentiation occurred in 24% of patients with conventional osteosarcoma. In their opinion, medullary canal invasion cannot be considered to be a sign of aggressiveness and cannot distinguish dedifferentiated POS from conventional osteosarcoma. Even though medullary involvement alone has been found more frequently with high tumor grades, it has not been associated to a poor prognosis^[7,13], which remains in concordance with the case reported by Unni *et al.*^[12], where a minimal medullary invasion was observed. Okada *et al.*^[3] reported 226 patients with POS in which medullary involvement was found more frequently with higher tumor grades compared to the patients without medullary involvement. Nevertheless, medullary involvement alone was not associated with poor prognosis. Local recurrence has also been reported to occur more frequently with incomplete resection of the tumor^[10,14], and an increased risk of developing metastatic disease is often associated with dedifferentiated tumors. In fact, the prognosis of patients with incomplete resection of POS is similar to that of patients with conventional sarcoma^[15]. The metastasis of the disease may occur in up to 38% of cases a few months or even years after the initial treatment. The lung is the most common site of metastasis, with the abdomen, central nervous system, or myocardium rarely affected^[16].

Treatment of POS includes wide surgical excision. A tumor-free margin is the main factor determining overall survival, and patients with a tumor-free margin have a 5-year survival rate of 80%–90%^[1,3,5]. Incomplete resection increases the risk of recurrence and dedifferentiation. Therefore, the risk of developing metastatic disease is likewise increased. Dedifferentiation induces tumor spread and is associated with a poor prognosis. No adjuvant therapy is necessary in low-grade lesions, but patients presenting with metastases or a high-grade POS should undergo adjuvant chemotherapy^[3,6,10,11,17-22]. Temple *et al.*^[5] reported that 38 patients with previously untreated, predominantly low-grade juxtacortical osteosarcoma who had en bloc tumor resection were alive during a mean follow-up of 6.75 years. The authors concluded that negative margins may be adequate in achieving local disease control and preventing metastases. In a similar series, Ding *et al.*^[9] retrospectively reviewed 48 cases of POS. They concluded that wide surgical excision alone is adequate for POS and that the tumor-free margin is the critical factor affecting overall prognosis. They considered that repeated recurrence probably increases the risk of dedifferentiation and thereby worsens the prognosis.

The case described herein is uncommon because that an incompletely resected, misdiagnosed, low-grade POS would recur 21 years later as a mass growing with no evidence of histological dedifferentiation or metastasis.

Our findings indicate that medullary involvement seems not to be associated with a poor prognosis, that wide surgical excision alone is an adequate treatment, and that the tumor-free margin is a critical factor affecting overall prognosis, as incomplete resection increases the

risk of recurrence and dedifferentiation.

Received: 2011-03-14; revised: 2011-06-24;
accepted: 2011-06-30.

References

- [1] Enneking WF, Springfield D, Gross M. The surgical treatment of parosteal osteosarcoma in long bones [J]. *J Bone Joint Surg Am*, 1985,67(1):125–135.
- [2] Lorentzon R, Larsson SE, Boquist L. Parosteal (juxtacortical) osteosarcoma. A clinical and histopathological study of 11 cases and a review of the literature [J]. *J Bone Joint Surg Br*, 1980,62-B(1):86–92.
- [3] Okada K, Frassica FJ, Sim FH, et al. Parosteal osteosarcoma. A clinicopathological study [J]. *J Bone Joint Surg Am*, 1994,76(3):366–378.
- [4] Ritschl P, Wurnig C, Lechner G, et al. Parosteal osteosarcoma: 2-23-year follow-up of 33 patients [J]. *Acta Orthop Scand*, 1991,62(3):195–200.
- [5] Temple HT, Scully SP, O’Keefe RJ, et al. Clinical outcome of 38 patients with juxtacortical osteosarcoma [J]. *Clin Orthop Relat Res*, 2000,373:208–217.
- [6] Ahuja SC, Villacin AB, Smith J, et al. Juxtacortical (parosteal) osteogenic sarcoma: histological grading and prognosis [J]. *J Bone Joint Surg Am*, 1977,59(5):632–647.
- [7] Alqueza AB, Dicaprio MR, Lindskog DM, et al. Chronic knee pain in a 21-year-old woman [J]. *Clin Orthop Rel Res*, 2005,432:272–278.
- [8] Dorfman HD, Czerniak B. *Bone tumors* [M]. Mosby: St. Louis, 1998:221–233.
- [9] Ding Y, Cai Y, Zhang Q. Parosteal osteosarcoma: a clinical study of 48 cases [J]. *Zhonghua Wai Ke Za Zhi*, 2003,41(11):832–836. [in Chinese]
- [10] Bertoni F, Present D, Hudson T, et al. The meaning of radiolucencies in parosteal osteosarcoma [J]. *J Bone Joint Surg Am*, 1985,67(6):901–910.
- [11] Unni KK, Knuutila S. Parosteal osteosarcoma [M]. In: *World Health Organization Classification of Tumors. Tumors of soft tissue and bone*. Lyon, France: IARC Press, 2002:279–285.
- [12] Camargo PO, Tesconi A, Barbosa NR, et al. Osteossarcoma parostal: avaliação clínico-histopatológica em 18 casos operados [J]. *Rev Bras Orthop*, 1998,33(11):867–875.
- [13] Sheth DS, Yasko AW, Raymond AK, et al. Conventional and dedifferentiated parosteal osteosarcoma. Diagnosis, treatment, and outcome [J]. *Cancer*, 1996,78(10):2136–2145.
- [14] Lau TW, Wong JW, Yip DK, et al. Local recurrence of parosteal osteosarcoma adjacent to a prosthesis after 20 years: a case report [J]. *J Orthop Surg (Hong Kong)*, 2004,12(2):263–266.
- [15] Wold LE, Unni KK, Beabout JW, et al. Dedifferentiated parosteal osteosarcoma [J]. *J Bone Joint Surg Am*, 1984,66(1):53–59.
- [16] Santos-Machado TM, Oliveira CR, Croci AT, et al. Parosteal osteosarcoma with myocardial metastasis 13 years after follow-up [J]. *Rev Hosp Clin Fac Med Sao Paulo*, 2003,58(2):113–118.
- [17] Steenbrugge F, Poffyn B, Uyttendaele D, et al. Parosteal osteosarcoma of the humerus [J]. *Acta Orthop Belg*, 2001,67(4):387–394.
- [18] Campanacci M, Picci P, Gherlinzoni F, et al. Parosteal osteosarcoma [J]. *J Bone Joint Surg Br*, 1984,66(3):313–321.
- [19] Kavanagh TG, Cannon SR, Pringle J, et al. Parosteal osteosarcoma. treatment by wide resection and prosthetic replacement [J]. *J Bone Joint Surg Br*, 1990,72(6):959–965.
- [20] Geschickter CF, Copeland MM. Parosteal osteosarcoma of bone: a new entity [J]. *Ann Surg*, 1951,133(6):790–807.
- [21] Levine E, De Smet AA, Huntrakoon M. Juxtacortical osteosarcoma: a radiologic and histologic spectrum [J]. *Skeletal Radiol*, 1985,14(1):38–46.
- [22] Hoshi M, Matsumoto S, Manabe J. Oncologic outcome of parosteal osteosarcoma [J]. *Int J Clin Oncol*, 2006,11(2):120–126.