

## Efficacy of Wavefront-guided Photorefractive Keratectomy with Iris Registration for Management of Moderate to High Astigmatism by Advanced Personalized Treatment Nomogram

Mehrdad Mohammadpour, MD; Hassan Hashemi, MD; Mahmoud Jabbarvand, MD  
Kamran Rahmatnejad, MD; Fatemeh Alsadat Sabet, MD, MPH

Eye Research Center, Farabi Eye Hospital, Tehran University of Medical Sciences, Tehran, Iran

### Abstract

**Purpose:** To evaluate the efficacy of photorefractive keratectomy (PRK) using the advanced personalized treatment (APT) nomogram for correction of moderate to high astigmatism.

**Methods:** This prospective interventional case series included 60 consecutive eyes of 30 patients undergoing wavefront-guided PRK (Zyoptix 217 Z100 excimer laser, Bausch & Lomb, Munich, Germany) using the APT nomogram and iris registration for myopic astigmatism. Mitomycin-C was applied intraoperatively in all eyes. Ophthalmic examination was performed preoperatively and 1, 3 and 6 months postoperatively.

**Results:** Preoperatively, mean sphere was  $-1.68 \pm 2.08$  diopters (D), mean refractive astigmatism was  $-3.04 \pm 1.05$  D and mean spherical equivalent (SE) was  $-3.12 \pm 1.77$  D. Six months postoperatively, mean sphere was  $+0.60 \pm 0.64$  D ( $P < 0.005$ ), mean cylinder was  $-0.43 \pm 0.46$  D ( $P < 0.005$ ) and mean SE was  $+0.28 \pm 0.48$  D ( $P < 0.005$ ). Hyperopic overcorrection ( $\geq +1.0$  D) occurred in 3 (5%) eyes. Postoperatively, root mean square (RMS) of higher order aberrations (HOAs) was significantly increased ( $P = 0.041$ ). RMS of spherical aberration (Z [4, 0]) showed no significant change after surgery ( $P = 0.972$ ).

**Conclusion:** Considering the acceptable residual refractive error, low rate of hyperopic overcorrection, acceptable uncorrected visual acuity, and low risk of postoperative corneal haze, PRK using the APT nomogram with iris registration and mitomycin-C use is a safe and effective modality for treatment of moderate to high astigmatism.

**Keywords:** Advanced Personalized Treatment; Astigmatism; Iris Registration; Photorefractive Keratectomy

*J Ophthalmic Vis Res* 2016; 11 (2): 136-140.

### Correspondence to:

Mehrdad Mohammadpour MD, Eye Research Center,  
Farabi Eye Hospital, Qazvin Square, Tehran 13366, Iran.  
E-mail: mahammadpour@yahoo.com

Received: 04-02-2015

Accepted: 17-07-2015

### INTRODUCTION

Laser refractive correction is nowadays a procedure of choice for surgical correction of spherical and cylindrical refractive errors; however customized laser ablation

This is an open access article distributed under the terms of the Creative Commons Attribution-NonCommercial-ShareAlike 3.0 License, which allows others to remix, tweak, and build upon the work non-commercially, as long as the author is credited and the new creations are licensed under the identical terms.

For reprints contact: reprints@medknow.com

**How to cite this article:** Mohammadpour M, Hashemi H, Jabbarvand M, Rahmatnejad K, Sabet FA. Efficacy of wavefront-guided photorefractive keratectomy with iris registration for management of moderate to high astigmatism by advanced personalized treatment nomogram. *J Ophthalmic Vis Res* 2016;11:136-40.

### Access this article online

Quick Response Code:



Website:  
[www.jovr.org](http://www.jovr.org)

DOI:  
10.4103/2008-322X.183913

for the treatment of refractive errors especially myopia remains a challenge. Approximately 8% of operated patients who undergo laser refractive surgery for significant astigmatism need retreatment due to residual refractive error which can be caused by cyclotorsion of the eye from sitting position (where the refraction data are measured) to the supine position (where the ablation correction is performed). It is estimated that for each 10-degree misalignment in the astigmatic axis, there is 6% loss in correction effect.<sup>[1-7]</sup>

Recent technological improvements have led to a decrease in complications of laser refractive surgeries performed for correction of astigmatism. The reported results of wavefront and iris registration are encouraging and suggest good visual outcomes achieved with minimal complications.<sup>[4]</sup> However, undercorrection or overcorrection still remain the disadvantages of this method, especially in eyes with significant pre-existing higher-order aberrations (HOA), which can result in postoperative refractive errors.<sup>[4]</sup>

The Advanced Personalized Technology (APT) nomogram, or Rochester nomogram<sup>[4]</sup> is a new method which allows a better postoperative outcome. This method compensates the effect of correcting preoperative HOAs, hence reducing postoperative hyperopia. Lapid-Gortzak et al reported an excellent outcome following photorefractive keratectomy (PRK) using the APT nomogram in myopic eyes with low astigmatism.<sup>[8]</sup>

Herein, we report the outcomes of PRK using the APT nomogram and iris registration for correction of myopia and astigmatism  $\geq 1.25$  diopter (D).

## METHODS

### Patients and Design

This prospective interventional case series was conducted at Farabi Eye Hospital, Tehran, Iran between February and October 2011 and included 60 consecutive eyes of 30 patients (66% female subjects) with the mean age of 27.5 (range, 21-39) years. Written informed consent was obtained from all participants. The study followed the tenets of the declaration of Helsinki, and was approved by the Institutional Review Board of Tehran University of Medical Sciences. Inclusion criteria were age more than 20 years, documented stable refraction for at least 2 years, central corneal thickness  $\geq 480$   $\mu\text{m}$ , spherical equivalent (SE) refraction  $\leq 8$  D, refractive astigmatism more than 1 D but less than 6 D, central keratometry  $< 48$  D, I-S value  $< 1.4$ , and best spectacle-corrected visual acuity  $\geq 20/25$ . Exclusion criteria were a history of prior refractive or cataract surgery, keratoconus, irregular astigmatism, collagen vascular disease and diabetic retinopathy. Soft and rigid gas-permeable contact lenses

were discontinued at least 4 weeks before preoperative examination.

Preoperative ophthalmic examinations included determination of Snellen visual acuity, manifest and cycloplegic refraction, slit lamp biomicroscopy, applanation tonometry, and indirect ophthalmoscopy in all cases. Corneal topography was performed using the Orbscan IIz (Bausch & Lomb, Surrey, United Kingdom) and wavefront measurements were taken using a Hartmann Shack aberrometer (Zywave II, Bausch and Lomb, Munich, Germany). All measurements were performed under mesopic conditions (3 candelas/m<sup>2</sup>). Cycloplegic agents were used to achieve a 6.0-mm pupil. All wavefront maps were standardized for a 6-mm pupil size. Pupil diameter was also measured using the wavefront sensor. All examinations were repeated 1, 3 and 6 months postoperatively.

### Surgical Procedure

All eyes underwent PRK using the APT nomogram and iris registration (Technolas 217z100 excimer laser system, Bausch & Lomb, Munich, Germany). Both eyes were operated in the same session. Topical anesthesia was achieved using 2 drops of tetracaine 0.5%. After sterile preparation and draping, an eyelid speculum was inserted. The surface corneal epithelium was loosened and removed using 20% alcohol solution applied for 20 seconds within an 8.50 mm well. This step was followed by irrigation of the ocular surface with balanced salt solution and drying of the cornea with a surgical sponge. The optical zone was 6.0 mm in all eyes. After laser photoablation, a sponge soaked with mitomycin-C 0.02% was applied for 30 seconds. Copious irrigation of the ocular surface with 50 ml of balanced salt solution was performed. An Acuvue Advance HydraClear soft contact lens with a base curve of 8.40 mm, diameter of 14 mm, DK/t value of 86 and an oxygen flux of 97% (Johnson & Johnson Vision Care, Inc., Jacksonville, FL., USA) was placed over the cornea at the end of the procedure.

### Postoperative Management and Follow-up

Postoperatively, all patients received chloramphenicol eye drops 0.5% 4 times a day for 5 days and diclofenac sodium eye drops 0.5%, 4 times a day for 3 days. Betamethasone eye drops 0.1% were applied 4 times a day for 3 weeks followed by fluorometholone 0.1% drops 4 times per day which was tapered over 8 weeks depending on clinical manifestations and refraction. Preservative free artificial tears (Artelac, Bausch and Lomb, London, England) was prescribed 4 times a day for 3 weeks and then tapered over 8 weeks. Postoperative follow up examinations were performed daily until complete epithelial healing, and then at months 1, 3, 6. Additional examinations were performed if necessary. The contact lens was removed

after the epithelial defects had completely healed (between 3 and 5 days postoperatively).

### Statistical Analysis

Data analysis was performed using SPSS software version 15 (SPSS Inc., Chicago, Illinois, USA). Pre- and postoperative astigmatism was compared using the analysis of variance (ANOVA) test. *P* values less than 0.05 were considered as statistically significant. Surgically induced changes in astigmatism were calculated using vector analysis according to Alpins:

$$\text{Astigmatism Difference} = K^2 + R^2 - 2KR(\cos 2\theta_1 \cos 2\theta_2 + \sin 2\theta_1 \sin 2\theta_2)$$

Where *K* is pre-operative astigmatism,  $\theta_1$  is axis of pre-operative astigmatism, *K**R* is postoperative astigmatism, and  $\theta_2$  is the axis of postoperative astigmatism.

### RESULTS

A total of 60 consecutive eyes of 30 patients with mean age of 27.5 (range, 21-39) years and female to male ratio of 2:1 were operated and followed. Preoperatively, mean sphere was  $-1.68 \pm 2.08$  D, mean refractive astigmatism was  $-3.04 \pm 1.05$  D and mean SE was  $-3.12 \pm 1.77$  D [Table 1]. SE refractive error was  $\leq -2.0$  D in 18 eyes (30%), between  $-2.0$  and  $-4.0$  D in 27 eyes (45%), between  $-4.0$  and  $-6.0$  D in 8 eyes (13.3%) eyes, and  $> -6.0$  D in 7 eyes (11.6%). Refractive astigmatism was between  $-1.0$  D and  $-4.0$  D in 46 eyes (77%), and  $> -4.0$  D in 14 eyes (23%). Best corrected visual acuity (BCVA) was 0.00 LogMAR in 49 (81.7%) eyes, 0.046 LogMAR in 8 eyes (13.3%) and 0.10 LogMAR in 3 eyes (5%) preoperatively. Preoperative mean root mean square (RMS) of higher order aberrations (HOAs) and spherical aberration were  $0.41 \pm 0.27 \mu\text{m}$  and  $0.033 \pm 0.03 \mu\text{m}$ , respectively.

After 3 months, 22 (37%) eyes gained more than one line of visual acuity and no patients lost BCVA. Uncorrected visual acuity (UCVA) in 70% of the eyes was better than or equal to 0.00 LogMAR. Mean sphere and cylinder errors were  $+0.60 \pm 0.64$  D and  $-0.43 \pm 0.46$  D, respectively. Mean SE was  $+0.28 \pm 0.48$  D [Table 1]. Forty-two (72%) eyes were within  $\pm 0.5$  D of target refraction and 51 (85%) eyes were within  $\pm 1$  D of target refraction [Table 2]. At the 6-month follow up, mean postoperative UCVA was  $0.022 \pm 1.00$  LogMAR. UCVA of better than or equal to 0.00 Log MAR was achieved in 46 (76.6%) eyes and 12 (20%) eyes gained more than one line of BCVA. In one eye, BCVA increased from 0.00 LogMAR preoperatively to  $-0.04$  logMAR after the operation [Table 3].

Postoperatively, mean RMS of HOAs was significantly increased to  $0.54 \pm 0.27 \mu\text{m}$  ( $P = 0.041$ ). Mean RMS of spherical aberration was  $0.034 \pm 0.042$  and showed no significant change after surgery ( $P = 0.972$ ). Table 4 shows absolute changes in Zernike coefficients of HOAs.

**Table 1. Pre- and 6 months post-operative refractive error**

Refraction	Preoperative		6 months postoperative	
	Mean $\pm$ SD	Range	Mean $\pm$ SD	Range
Sphere error (D)	$-1.68 \pm 2.08$	$-0.25$ – $-7.00$	$+0.60 \pm 0.64$	$+1.75$ – $-0.25$
Cylinder error (D)	$-3.04 \pm 1.05$	$-1.25$ – $-5.75$	$-0.43 \pm 0.46$	$0$ – $-1.50$
SE (D)	$-3.12 \pm 1.77$	$-0.75$ – $-7.50$	$+0.28 \pm 0.48$	$+1.25$ – $-0.25$

SD, standard deviation; D, diopter; SE, spherical equivalent

**Table 2. Outcome indices 6 months after surgery**

Parameter	Percent%
Safety index	1.02
Efficacy index	0.98
UCVA $\geq 1.0$ (LogMAR)	76.6
Within $\pm 1.0$ (D)	85
Within $\pm 0.5$ (D)	72
Cylinder (0–0.25) (D)	52
Cylinder (0–0.5) (D)	70

D, diopter; UCVA, uncorrected visual acuity; LogMAR, logarithm of the minimal angle of resolution

Safety index, defined as mean postoperative BCVA divided by mean preoperative BCVA, was 1.02. We observed no case of corneal haze postoperatively. Efficacy index defined as mean postoperative UCVA divided by mean preoperative BCVA was 0.98.

### DISCUSSION

Advantages of the APT nomogram with iris registration, are eliminating sources of errors in correction of astigmatism by wavefront examination and registering all data including the operated eye, amount of sphere and cylinder, and the axis of astigmatism by the predicted phoropter refraction (PPR) on wavefront examination; exporting the data with a cable or wireless internet network to the excimer machine; and compensating for cyclotorsion with iris registration before performing the ablation.

In the current series, we performed PRK using the APT nomogram for treatment of myopic astigmatism. Mean preoperative refractive astigmatism was  $-3.04 \pm 1.05$  D which was decreased to  $-0.43 \pm 0.46$  D at six months. The cylinder continuously decreased from the first to sixth months [Figure 1] which is usually seen after surface ablation and can be explained by gradual replacement and remodeling of the epithelial layers.

Another important finding in this study was the lack of corneal haze for at least 6 months after surgery. This may be explained by combined effects of applying mitomycin-C for 30 seconds and the customized ablation profile which can create a smoother surface. Haze formation is usually observed along the axis of minus cylinder treatment with conventional PRK which may

**Table 3. Pre- and post-operative uncorrected visual acuity and best corrected visual acuity**

	Preoperative	1 month postoperatively	3 months postoperatively	6 months postoperatively
UCVA (LogMAR)	0.66±0.92	0.046±0.88	0.018±1.15	0.022±1.00
BCVA (LogMAR)	0.013±1.15	0.004±2.00	0.00±1.30	0.00±1.39

UCVA, uncorrected visual acuity; BCVA, best corrected visual acuity; LogMAR, logarithm of the minimal angle of resolution

**Table 4. Absolute change in magnitude of higher order Zernike coefficients pre- and 6 months post-operatively**

	Preoperative	Postoperative	P
Total HOA	0.41±0.27	0.54±0.27	0.04
Total 3 <sup>rd</sup> order	0.12±0.4	0.15±0.32	0.51
Trefoil x, z (-3, 3)	0.02±0.11	0.01±0.08	0.72
Coma x, z (-1, 3)	0.03±0.13	0.09±0.15	0.03
Coma y, z (1, 3)	0.05±0.16	0.04±0.16	0.91
Trefoil y, z (3, 3)	0±0.12	0±0.13	0.79
Total 4 <sup>th</sup> order	0.16±0.14	0.22±0.18	0.05
Spherical aberration Z (0, 4)	0.0335±0.030	0.0339±0.042	0.97

HOA, higher order aberration

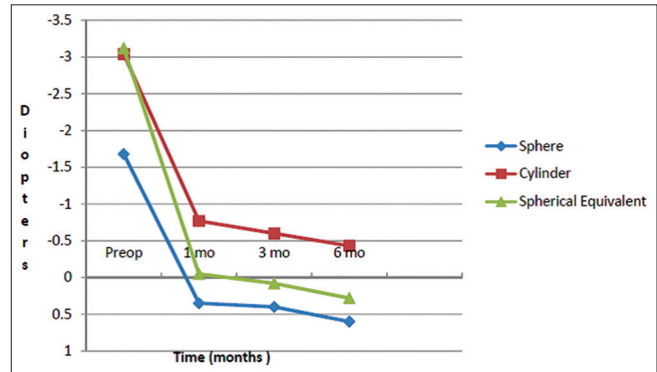
be due to significant change in corneal curvature after excimer laser ablation in patients with high amounts of astigmatism, due to an ellipsoid ablation profile.<sup>[9]</sup>

Another complication following correction of high refractive cylinders is under-correction and regression of astigmatism. Our acceptable outcomes may be explained in part by the fact that customized ablation based on wavefront PPR slightly overcorrects the refractive cylinder and compensates for under-correction and future regression of astigmatism. To avoid overcorrection of the spheric component, we used cycloplegic PPR for laser ablation.

Randleman et al<sup>[2]</sup> compared early visual outcomes after wavefront-optimized advanced surface ablation (ASA) with those after wavefront-optimized LASIK and concluded that visual outcomes after surface ablation are at least equivalent to those after LASIK 3 months postoperatively. In a study on the Rochester nomogram by Gortzak et al,<sup>[8]</sup> 97% of eyes had postoperative UCVA of 1.0 LogMAR (20/20); however, mean preoperative cylinder of the patients was much lower than our patients (-1.06 ± 0.82D [range, 0.00 to -2.75 D] in Gortzak study vs. -3.03 ± 1.07D [range, -1.25 to -5.75D] in our study).

In the current study, 42 eyes (70%) were within ± 0.5 D of the target refraction and 51 eyes (85%) were within ± 1.0 D. In the Synoptic U.S. Food and Drug Administration (FDA) for patients with up to 3 D of astigmatism, 72.6% of eyes were within ± 0.5 D of target refraction and 90.2% were within ± 1.0 D. Gortzak et al,<sup>[8]</sup> showed that 95.2% of eyes were within ± 0.5 D and 98.4% of eyes were within ± 1.0 D of emmetropia. The difference can be attributed to the high.

Amounts of refractive cylinder in our patients which reduced the predictability of postoperative outcomes.



**Figure 1.** Pattern of postoperative decrease in sphere, cylinder and spherical equivalent 1, 3 and 6 months postoperatively. mo, month.

Gortzak et al reported a hyperopic overcorrection ( $\geq +1.0$  D) in 4.1% of eyes<sup>[8]</sup> and Subbaram and Macrae<sup>[4]</sup> had a hyperopic correction rate of 2.8%. Our study showed a higher rate of overcorrection (5%) which may be due to high amounts of astigmatism, as there is a trend for undercorrection in the treatment of eyes with higher amounts of astigmatism.

The APT nomogram somehow overcorrects patients to compensate for this problem. Longer follow up may address whether overcorrection in the early postoperative period (6 months postoperatively) is beneficial for the patients.

Our mean postoperative SE of 0.08 was close to plano which makes the APT nomogram a suitable nomogram for correction of high amounts of astigmatism and avoids hyperopic shift. The FDA-approved limit of astigmatic correction is -3.0 D for Zyoptix 217 Z 100 (Bausch & Lomb). However, 50% of eyes treated in our study had cylinders more than -3.0D. All of these off-label treatments were performed with informed consent of the volunteers. In other study by Thomas et al,<sup>[9]</sup> preoperative astigmatism has been considered as a risk factor for corneal haze and the authors recommended prophylactic application of mitomycin-C during PRK procedures for moderate to high astigmatism ( $\geq 1.25$  D). Thus we used mitomycin-C in all patients who had refractive cylinders greater than -1.25 D and observed no case of corneal haze postoperatively with a minimum follow up of 6 months.

In another report on the outcomes of treatment of myopia with and without astigmatism (mean manifest refraction spherical equivalent [MRSE]:  $-4.13 \pm 1.17$  D; range, -8.00 to -1.50 D and mean cylinder:  $-0.42 \pm 0.32$  D;

range, -1.00 to 0.00 D) using the NIDEK optimized prolate ablation (OPA), El Danasoury et al,<sup>[10]</sup> reported that all 9 eyes were within 1.00D of the intended MRSE postoperatively. At postoperative month 6, RMS of HOAs was 0.75  $\mu$ m in the control group and 0.47  $\mu$ m in the OPA group. There was no change in spherical aberration in the OPA group postoperatively. The limitations of their study were small sample size and inclusion of eyes with no or low astigmatism (<1.00D).

A retrospective study<sup>[11]</sup> reported the outcomes of Epi-LASIK in 67 eyes of 52 patients who underwent Epi-LASIK using the MEL80 (Carl Zeiss Meditec, Jena, Germany) excimer laser for correction of high myopia and myopic astigmatism. Mean preoperative cylinder was  $-2.02 \pm 0.75$  (range, -1.0 to -4.0) D. The index of success of 0.51 is compatible by 49% success in achieving cylinder correction and 7.46% of eyes developed trace haze. In comparison, we achieved a higher efficacy index for cylinder correction and observed no corneal haze following correction of greater amounts of astigmatism.

Subbaram and MacRae<sup>[4]</sup> reported that pharmacological pupil dilation may cause a pupil shift, leading to changes on the wavefront which can be clinically significant. Although the wavefront significantly changes as the pupil dilates and there is an increase in HOAs with larger pupils, the APT nomogram has a feature in which measurements for a pupil with a corresponding wavefront can be mathematically extrapolated to a pupil with 10% larger diameter. This could make it possible to perform wavefront examinations without the need for pupil dilatation.

In our clinic, the protocol requires that we perform both undilated and dilated wavefront examinations; however, we use the pharmacologically dilated wavefront measurements for the actual treatment. The Zywave prediction of phoropter refraction is usually more myopic than subjective refraction, however the effect of instrument myopia is alleviated with cycloplegia. We routinely use cycloplegic wavefront data and this may, in theory, account for the low rate of hyperopic overcorrection in our patients. Long-term stability and the possibility for refinement of the advanced nomogram should also be studied. However, recent studies are in favor of customized ablation in cases with high amounts of astigmatism.<sup>[12-14]</sup>

In summary, we found the advanced wavefront-guided registration as a promising modality in terms nomogram and iris registration as a promising modality in terms of safety, efficacy, predictability and short term stability for management of significant astigmatism. However, extended follow-up is recommended to determine its long-term outcomes.

## Financial Support and Sponsorship

Nil.

## Conflicts of Interest

There are no conflicts of interest.

## REFERENCES

- Vinciguerra P, Camesasca FI, Nizolla G, Epstein D. Treatment of astigmatism. In: Vinciguerra P, Camesasca FI, editors. *Refractive Surface Ablation*. USA: Slack Incorporated; 2008. p. 104-119.
- Randleman JB, Loft ES, Banning CS, Lynn MJ, Stulting RD. Outcomes of wavefront-optimized surface ablation. *Ophthalmology* 2007;114:983-988.
- Netto MV, Dupps W Jr., Wilson SE. Wavefront-guided ablation: Evidence for efficacy compared to traditional ablation. *Am J Ophthalmol* 2006;141:360-368.
- Subbaram MV, MacRae SM. Customized LASIK treatment for myopia based on preoperative manifest refraction and higher order aberrometry: The Rochester nomogram. *J Refract Surg* 2007;23:435-441.
- Kohnen T, Bühren J, Kühne C, Mirshahi A. Wavefront-guided LASIK with the Zyoptix 3.1 system for the correction of myopia and compound myopic astigmatism with 1-year follow-up: Clinical outcome and change in higher order aberrations. *Ophthalmology* 2004;111:2175-2185.
- Lawless MA, Potvin RJ. Fulfilling the promise of laser refractive surgery. *J Refract Surg* 2006;22:S965-S968.
- Bahar I, Levinger S, Kremer I. Wavefront-supported photorefractive keratectomy with the Bausch & Lomb Zyoptix in patients with myopic astigmatism and suspected keratoconus. *J Refract Surg* 2006;22:533-538.
- Lapid-Gortzak R, van der Linden JW, van der Meulen IJ, Nieuwendaal CP. Advanced personalized nomogram for myopic laser surgery: First 100 eyes. *J Cataract Refract Surg* 2008;34:1881-1885.
- Thomas KE, Brunstetter T, Rogers S, Sheridan MV. Astigmatism: Risk factor for postoperative corneal haze in conventional myopic photorefractive keratectomy. *J Cataract Refract Surg* 2008;34:2068-2072.
- El Danasoury AM. NIDEK optimized prolate ablation for the treatment of myopia with and without astigmatism. *J Refract Surg* 2009;25 1 Suppl: S136-S141.
- Gan D, Zhou X, Dai J, Qu X, Yu Z, Zhou H, et al. Outcomes of epi-LASIK for the correction of high myopia and myopic astigmatism after more than 1 year. *Ophthalmologica* 2009;223:102-110.
- Schallhorn SC, Venter JA, Hannan SJ, Hettlinger KA. Wavefront-guided photorefractive keratectomy with the use of a new hartmann-shack aberrometer in patients with myopia and compound myopic astigmatism. *J Ophthalmol* 2015;2015:514837.
- De Rosa G, Boccia R, Santamaria C, Fabozzi L, De Rosa L, Lanza M. Customized photorefractive keratectomy to correct high ametropia after penetrating keratoplasty: A pilot study. *J Optom* 2015;8:174-179.
- Vestergaard AH. Past and present of corneal refractive surgery: A retrospective study of long-term results after photorefractive keratectomy and a prospective study of refractive lenticule extraction. *Acta Ophthalmol* 2014;92:1-21.