

Emphysematous pyelonephritis and cystitis: A case report and literature review

Journal of International Medical Research

2018, Vol. 46(7) 2954–2960

© The Author(s) 2018

Reprints and permissions:

sagepub.co.uk/journalsPermissions.nav

DOI: 10.1177/0300060518770341

journals.sagepub.com/home/imr



Shengxian Li¹, Jixue Wang^{1,2}, Jinghai Hu¹,
Liang He¹  and Chunxi Wang¹

Abstract

This present case report describes a 64-year-old female patient with type 2 diabetes mellitus who also had emphysematous pyelonephritis (EPN) and emphysematous cystitis (EC). Computed tomography revealed well defined emphysematous pyelonephritis and cystitis. Broad-spectrum antibiotic and percutaneous drainage of the right kidney were used as part of a conservative management regimen. The patient achieved clinical recovery and was discharged 12 days after admission. Furthermore, 13 other cases of EPC and EC that were reported between 1962 and 2017 were reviewed and discussed. The overall mortality was 15.4% (two of 13 patients), compared with 25% for EPN alone or 7.4% for EC alone as reported in the literature. The primary pathogen identified in the 13 patients was *Escherichia coli* (53.8%). All 13 patients were treated with antibiotics.

Keywords

Emphysematous pyelonephritis, emphysematous cystitis, conservative management

Date received: 23 January 2018; accepted: 16 March 2018

Introduction

Emphysematous pyelonephritis (EPN) is a type of severe renal infection that results in gas production in the renal parenchyma, collecting system, or perinephric tissue.¹ Almost 60–70% of cases are associated with uncontrolled diabetes mellitus.² EPN complicated by coexisting emphysematous

¹Department of Urology, First Hospital of Jilin University, Changchun, Jilin Province, China

²Key Laboratory of Polymer Ecomaterials, Changchun Institute of Applied Chemistry, Chinese Academy of Sciences, Changchun, Jilin Province, China

Corresponding author:

Chunxi Wang, Department of Urology, No. 3 Building, First Hospital of Jilin University, 71 Xinmin Street, Changchun, Jilin 130021, China.

Email: chunxi_wang@126.com



cystitis (EC) is one category of EPN and if not treated promptly and properly, the clinical progress can be rapid, severe and life-threatening.³

This present case report describes a 64-year-old female patient with type 2 diabetes mellitus with EPN complicated by coexistent EC. Computed tomography (CT) and laboratory evaluations confirmed EPN.

Case report

A 64-year-old female patient with type 2 diabetes mellitus who had been experiencing nausea, vomiting, and right flank pain for 7 days was admitted to the Department of Urology, First Hospital of Jilin University, Changchun, Jilin Province, China in November 2017. She had been suffering from type 2 diabetes mellitus for 20 years without systematic treatment. A physical examination revealed the following: temperature, 37.5°C; heart rate, 90 beats per minute; and blood pressure, 103/42 mmHg. Percussion in the right flank region elicited pain. Routine laboratory studies revealed the following: white cell count, $22.43 \times 10^9/l$; platelets, $15 \times 10^9/l$; fibrinogen, 8.0 g/l; K^+ , 2.9 mmol/l; glucose, 14.80 mmol/l; serum creatinine, 274.4 mmol/l; C-reactive protein, 179.03 mmol/l. The subsequent CT results showed gas in the right renal parenchyma

(Figure 1a) and gas in the urinary bladder wall (Figure 1b).

Empirical antibiotics (1.0 g meropenem intravenously every 8 h for 9 days), fluid resuscitation, control of blood glucose, and platelet transfusion were performed immediately after the diagnosis of EPN complicated by coexistent EC. The blood culture isolated gram-negative bacilli. Urine culture showed *Candida albicans*. After the inflammation was relieved, percutaneous drainage (PCD) of the right kidney was performed. The patient achieved clinical recovery and was discharged 12 days after admission.

Discussion

Emphysematous pyelonephritis is a severe necrotizing renal infection.¹ It was first described in 1898 and ‘emphysematous pyelonephritis’ was defined in 1962.⁴ Mortality rates are reported to be up to 40–50%.⁵ EPN complicated with EC is a rarer form of EPN.³ This current case report describes a rare case of EPN complicated by coexistent EC. To date, there have been less than 15 cases of EPN complicated by coexistent EC reported in the literature as described below.

In order to review the epidemiology, theranostic and treatment strategies for EPN complicated with EC, a search of the

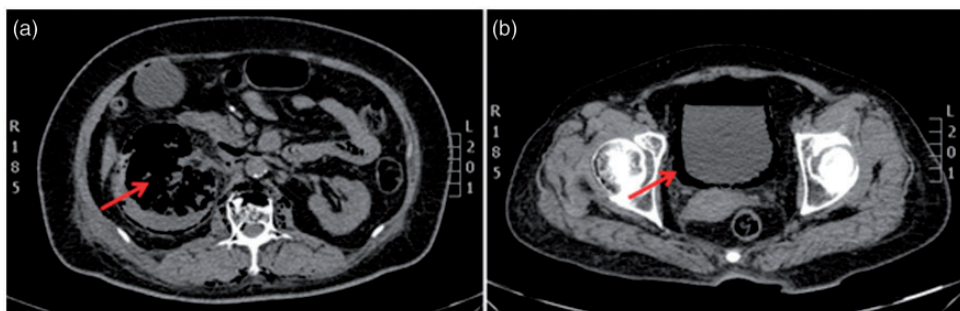


Figure 1. Nonenhanced computed tomography (CT) images showing gas in the right kidney (red arrows) (a) and in the urinary bladder wall (red arrows) (b).

Table 1. Clinical and demographic data from case reports ($n = 13$) of emphysematous pyelonephritis (EPN) complicated by coexistent emphysematous cystitis (EC) published from 1962 to 2017.^{2,3,6-14}

| Author | Age | Sex | Lesion site | History of diabetes mellitus ^a | Urine and blood cultures | Treatment | Outcome |
|--------------------------------|----------|-----|--|---|---|--|----------|
| Hu et al. ⁶ | 60 years | F | Left renal pelvis, bladder and bilateral iliofosas | Diabetes | <i>Enterobacter aerogenes</i> | Antibiotic treatment, percutaneous drainage and surgical debridement | Survived |
| Liao et al. ⁷ | 81 years | F | Right renal pelvis and bladder | Type 2 diabetes for 10 years | NR | Antibiotic treatment | Survived |
| Momin et al. ³ | 58 years | M | Bilateral renal pelvis, bladder and prostatic parenchyma | Diabetes | <i>Enterobacter cloacae</i> | Antibiotic treatment | Survived |
| Yokoyama et al. ⁸ | 67 years | F | Left renal pelvis and bladder | Diabetes | <i>Klebsiella pneumoniae</i> | Antibiotic treatment and pubic catheterization | Survived |
| Egawa et al. ⁹ | 58 years | F | Left renal pelvis, ureter and bladder | Diabetes | <i>Escherichia coli</i> | Antibiotic treatment, percutaneous drainage and left subcapsular nephrectomy | Survived |
| Arun et al. ² | 64 years | M | Bilateral renal pelvis and bladder | Diabetes | <i>E. coli</i> and <i>Staphylococcus aureus</i> | Antibiotic treatment | Survived |
| Evanoff et al. ¹⁰ | 31 years | F | Right renal pelvis and bladder | Diabetes for 20 years | <i>E. coli</i> | Antibiotic treatment | Survived |
| Evanoff et al. ¹⁰ | 54 years | M | Bilateral renal pelvis and bladder | Diabetes | <i>E. coli</i> | Antibiotic treatment and bilateral nephrectomies | Survived |
| McLelland et al. ¹¹ | 53 years | F | Left renal pelvis and bladder | None | NR | Antibiotic treatment and ureteral stent implantation | Died |
| Yeh et al. ¹² | 60 years | F | Bilateral renal pelvis and bladder | None | <i>E. coli</i> and <i>Enterococcus</i> | Antibiotic treatment and bilateral nephrectomy | Survived |

(continued)

Table 1. Continued.

| Author | Age | Sex | Lesion site | History of diabetes mellitus ^a | Urine and blood cultures | Treatment | Outcome |
|--------------------------------|----------|-----|------------------------------------|---|--------------------------|---|----------|
| Althaf et al. ¹³ | 71 years | M | Right renal pelvis and bladder | None | <i>E. coli</i> | Antibiotic treatment | Died |
| Fernandes et al. ¹⁴ | 6 weeks | M | Bilateral renal pelvis and bladder | None | NR | Antibiotic treatment and pyeloplasty | Survived |
| Ahsaini et al. ^b | 60 years | M | Left renal pelvis and bladder | Diabetes for 1 year | <i>E. coli</i> | Antibiotic treatment and public catheterization | Survived |

^aThe type of diabetes mellitus was not always stated.

^bAlthough this article was retracted by the authors, this rare case was still worth analysing (Ahsaini M, Kassogue A, Tazi MF, et al. Emphysematous cystitis and emphysematous pyelitis: a clinically misleading association. *Pan Afr Med J* 2013; 16: 18). F, female; NR, not recorded; M, male.

PubMed®, Embase® and Google Scholar bibliographic databases was undertaken using the following search strategy: emphysematous (all fields), and pyelonephritis (all fields) or pyelonephritis (mesh term), and cystitis (all fields) or cystitis (mesh term). After filtering for unrelated results and duplicates, the data from 13 patients in 12 publications (one retracted) from 1962 to 2017 were collected and analysed (Table 1).^{2,3,6-14}

As shown in Table 2, the mean age of patients that were affected by EPN complicated by coexistent EC was 55 years. The overall mortality rate was 15.4% (two of 13 patients) compared with 25% for EPN alone¹⁵ or 7.4% for EC alone.¹⁶ *Escherichia coli* was the most common causative pathogen (53.8%; seven of 13 patients), compared with *Enterobacter aerogenes* (7.7%; one of 13 patients), *Enterobacter cloacae* (7.7%; one of 13 patients) and *Enterococcus* (7.7%; one of 13 patients). A history of diabetes mellitus was observed in the majority of patients (69.2%; nine of 13 patients). High blood glucose levels in patients with poorly controlled diabetes mellitus can provide gas-forming bacteria with a good environment.³ Almost 95% of patients with EPN suffer from underlying uncontrolled diabetes,¹⁷ 67% patients with EC have diabetes,¹⁶ and urinary tract obstruction has been observed in 29% of EPN patients.¹⁵ However, diabetes mellitus is not related to mortality.^{5,17}

A diagnosis of EPN can be established radiographically. On abdominal radiographs, gas in the renal parenchyma is often mistakenly identified as bowel gas. To demonstrate obstruction, retrograde pyelography is more appropriate than excretory urography because the function of the focal kidney is usually poor.^{18,19} Diagnosis of EPN relies on the reporting of gas patterns on CT scans.¹ CT can be used to estimate the extent of the

Table 2. Summary characteristics for the case reports ($n = 13$) of emphysematous pyelonephritis complicated by coexistent emphysematous cystitis published from 1962 to 2017.^{2,3,6-14}

| Characteristics ^a | |
|------------------------------------|-------------|
| Age, years | 55.0 ± 20.1 |
| Sex | |
| Male | 6 (46.2%) |
| Female | 7 (53.8%) |
| Lesion site | |
| Left renal pelvis and bladder | 5 (38.5%) |
| Right renal pelvis and bladder | 3 (23.1%) |
| Bilateral renal pelvis and bladder | 5 (38.5%) |
| History of diabetes mellitus | |
| Yes | 9 (69.2%) |
| No | 4 (30.8%) |
| Urine and blood cultures | |
| <i>Escherichia coli</i> | 7 (53.8%) |
| <i>Enterobacter aerogenes</i> | 1 (7.7%) |
| <i>Enterobacter cloacae</i> | 1 (7.7%) |
| <i>Enterococcus</i> | 1 (7.7%) |
| <i>Klebsiella pneumoniae</i> | 1 (7.7%) |
| <i>Staphylococcus aureus</i> | 1 (7.7%) |
| Treatment | |
| Antibiotics | 13 (100.0%) |
| Pubic catheterization | 2 (15.4%) |
| Ureteral stent implantation | 1 (7.7%) |
| Percutaneous drainage | 2 (15.4%) |
| Nephrectomy | 3 (23.1%) |
| Surgical debridement | 1 (7.7%) |
| Pyeloplasty | 1 (7.7%) |
| Antibiotic treatment alone | 5 (38.5%) |
| Outcome | |
| Died | 2 (15.4%) |
| Survived | 11 (84.6%) |

Data presented as mean ± SD or n of patients (%).

^aOne article was retracted by the authors, but the rare case was still worth analysing (Ahsaini M, Kassogue A, Tazi MF, et al. Emphysematous cystitis and emphysematous pyelitis: a clinically misleading association. *Pan Afr Med J* 2013; 16: 18).

emphysematous process and to guide disease management.^{18,20}

Choosing the most appropriate treatment for EPN complicated with coexistent EC is very important if a cure is to be achieved. As gram-negative bacteria are the most common causative pathogens,

the initial antibiotic therapy should target them using agents such as quinolones and cephalosporins. Once the results of the microbiological culture is available, then the antibiotics should be adjusted according to the type and individual sensitivities of the identified pathogen.^{16,21,22} The use of antibiotic treatment alone is related to a higher mortality risk when compared with the use of additional interventions such PCD of the abscess.^{15,23,24} As shown in Table 1, four of five (80.0%) patients treated with antibiotic alone survived, while seven of eight (87.5%) patients who received more extensive treatment regimens survived. Delayed elective nephrectomy may be required as a salvage procedure.^{14,25,26}

In summary, this current case report described a rare case of EPN complicated by coexistent EC and presented the findings of a systematic review of the published literature regarding such cases. EPN complicated by coexistent EC is a rare and life-threatening urinary system infection. Diagnosis of EPN complicated by coexistent EC relies on the reporting of gas patterns in the urinary system on CT scans. Antibiotic treatment with additional interventions such as PCD appear to be more effective than the use of antibiotics alone. These findings provide guidance to physicians about how to treat patients with EPN complicated by coexistent EC.


Declarations of conflicting interests

The author(s) declared no potential conflicts of interest with respect to the research, authorship, and/or publication of this article.

Funding

The author(s) disclosed receipt of the following financial support for the research, authorship, and/or publication of this article: This work was financially supported by the Graduate Innovation Fund of Jilin University (Grant No. 2017096).

ORCID iD

Liang He  <http://orcid.org/0000-0003-0966-0526>

References

- Boakes E and Batura D. Deriving a management algorithm for emphysematous pyelonephritis: Can we rely on minimally invasive strategies or should we be opting for earlier nephrectomy? *Int Urol Nephrol* 2017; 49: 2127–2136.
- Arun N, Hussain A, Kapoor MM, et al. Bilateral emphysematous pyelonephritis and emphysematous cystitis with autosomal-dominant polycystic kidney disease: is conservative management justified? *Med Princ Pract* 2007; 16: 155–157.
- Momin UZ, Ahmed Z, Nabir S, et al. Emphysematous prostatitis associated with emphysematous pyelonephritis and cystitis: A case report. *J Clin Urol* 2017; 10: 286–289.
- Tsu JH, Chan CK, Chu RW, et al. Emphysematous pyelonephritis: an 8-year retrospective review across four acute hospitals. *Asian J Surg* 2013; 36: 121–125.
- Dutta P, Bhansali A, Singh SK, et al. Presentation and outcome of emphysematous renal tract disease in patients with diabetes mellitus. *Urol Int* 2007; 78: 13–22.
- Hu SY, Lee BJ, Tsai CA, et al. Concurrent emphysematous pyelonephritis, cystitis, and iliopsoas abscess from discitis in a diabetic woman. *Int J Infect Dis* 2016; 51: 105–106.
- Liao WC and Chou JW. Emphysematous pyelonephritis, ureteritis and cystitis in a diabetic patient. *QJM* 2010; 103: 893–894.
- Yokoyama T, Shinozaki S, Arimura H, et al. Emphysematous pyelonephritis and cystitis: unusual adverse events during concurrent chemoradiotherapy for lung cancer. *Case Rep Oncol* 2017; 10: 239–243.
- Egawa S, Utsunomiya T, Uchida T, et al. Emphysematous pyelonephritis, ureteritis, and cystitis in a diabetic patient. *Urol Int* 1994; 52: 176–178.
- Evanoff GV, Thompson CS, Foley R, et al. Spectrum of gas within the kidney: emphysematous pyelonephritis and emphysematous pyelitis. *Am J Med* 1987; 83: 149–154.
- McLelland R. Ureteritis, pyelitis and pyelonephritis emphysematosa: a case report. *Acta Radiol* 1962; 57: 97–102.
- Yeh CL and Hsu KF. Bilateral emphysematous pyelonephritis and cystitis in an ESRD patient presenting with septic shock. *Acta Clin Belg* 2009; 64: 160–161.
- Althaf MM, Abdelsalam MS, Rashwan M, et al. Emphysematous pyelonephritis and cystitis in a renal transplant recipient. *BMJ Case Rep* 2014; 2014.
- Fernandes LP, Sajwany MJ and Derweesh A. Emphysematous pyelonephritis and cystitis associated with bilateral pelviureteric junction obstruction: a case report. *J Pediatr Surg* 1998; 33: 739–740.
- Falagas ME, Alexiou V, Giannopoulou KP, et al. Risk factors for mortality in patients with emphysematous pyelonephritis: a meta-analysis. *J Urol* 2007; 178: 880–885.
- Thomas AA, Lane BR, Thomas AZ, et al. Emphysematous cystitis: a review of 135 cases. *BJU Int* 2007; 100: 17–20.
- Ubee SS, McGlynn L and Fordham M. Emphysematous pyelonephritis. *BJU Int* 2011; 107: 1474–1478.
- Saxena D, Aggarwal L, Tudu SK, et al. Emphysematous pyelonephritis – a rare surgical emergency presenting to the physician: a case report and literature review. *Indian J Surg* 2013; 75: 272–274.
- Schicho A, Stroszczyński C and Wiggermann P. Emphysematous cystitis: mortality, risk factors, and pathogens of a rare disease. *Clin Pract* 2017; 7: 930.
- Wang HD, Zhu XF, Xu X, et al. Emphysematous pyelonephritis treated with vacuum sealing drainage. *Chin Med J (Engl)* 2017; 130: 247–248.
- Bhat RA, Khan I, Khan I, et al. Emphysematous pyelonephritis: outcome with conservative management. *Indian J Nephrol* 2013; 23: 444–447.
- Saadi A, Ayed H, Bouzouita A, et al. Results of conservative management of emphysematous pyelonephritis. *Nephrol Ther* 2016; 12: 508–515 [in French, English abstract].
- Somani BK, Nabi G, Thorpe P, et al. Is percutaneous drainage the new gold standard in the management of emphysematous

- pyelonephritis? Evidence from a systematic review. *J Urol* 2008; 179: 1844–1849.
24. Khaira A, Gupta A, Rana DS, et al. Retrospective analysis of clinical profile prognostic factors and outcomes of 19 patients of emphysematous pyelonephritis. *Int Urol Nephrol* 2009; 41: 959–966.
 25. Alsharif M, Mohammedkhalil A, Alsaywid B, et al. Emphysematous pyelonephritis: Is nephrectomy warranted? *Urol Ann* 2015; 7: 494–498.
 26. Sokhal AK, Kumar M, Purkait B, et al. Emphysematous pyelonephritis: Changing trend of clinical spectrum, pathogenesis, management and outcome. *Turk J Urol* 2017; 43: 202–209.