

Noncompaction cardiomyopathy: A new mechanism for mitral regurgitation with distinct clinical, echocardiographic features and pathological correlations



Sulafa K.M. Ali ^{a,*}, Riyadh Abu-Sulaiman ^b, Rihab Beshir Agouba ^b

^a Sudan Heart Institute, Khartoum

^b King Abdulaziz Cardiac Center, Riyadh

^a Sudan

^b Saudi Arabia

Noncompaction cardiomyopathy (NCCM) is a primary, genetic cardiomyopathy with variable clinical manifestations that include mitral regurgitation (MR).

Methods: This study comprised patients diagnosed with NCCM and MR in two cardiac centers (King Abdul-Aziz Cardiac Center, Riyadh, Kingdom of Saudi Arabia and Sudan Heart Institute, Khartoum, Sudan), and seen in the period between 2002 and 2013. The study describes follow up, clinical, echocardiographic, and histopathological findings.

Results: Nineteen cases (85% females) were identified. Ten percent of the cases had relapses and remissions of heart failure. Echocardiographic features included leaflet retraction in all patients, characteristic malcoaptation, and a zigzag deformity of anterior leaflet in 57% of patients. Ruptured chordae were found in 15% of the patients. One patient had pathological examination of the mitral valve which showed myxomatous degeneration, and sclerotic and calcific changes.

Conclusion: We describe and discuss a new mechanism for MR caused by NCCM with identifiable clinical and echocardiographic features, and pathological correlations.

© 2014 King Saud University. Production and hosting by Elsevier B.V. All rights reserved.

Keywords: Noncompaction, Mitral regurgitation, Echocardiography, Pathology

Introduction

Noncompaction cardiomyopathy (NCCM) is described as excessive myocardial trabeculation and deep inter-trabecular recesses, and

has recently been designated as a primary genetic cardiomyopathy [1,2]. The disease is increasingly being recognized, and reports suggest that the condition is not rare but under-diagnosed [3].

Disclosure: Authors have nothing to disclose with regard to commercial support.

Received 15 March 2014; revised 9 June 2014; accepted 9 July 2014.
Available online 22 July 2014

* Corresponding author. Address: Sudan Heart Institute and University of Khartoum, PO Box 102, Sudan. Tel.: +249 918075694.
E-mail address: sulafaali2000@gmail.com (S.K.M. Ali).



P.O. Box 2925 Riyadh – 11461KSA
Tel: +966 1 2520088 ext 40151
Fax: +966 1 2520718
Email: sha@sha.org.sa
URL: www.sha.org.sa



1016–7315 © 2014 King Saud University. Production and hosting by Elsevier B.V. All rights reserved.

Peer review under responsibility of King Saud University.
URL: www.ksu.edu.sa
<http://dx.doi.org/10.1016/j.jsha.2014.07.002>



Production and hosting by Elsevier

NCCM, associated with mitral regurgitation (MR) in the presence of preserved left ventricle function, was observed in 2004 [4]. Subsequently, other reports have confirmed this unique association [5,6].

This study describes the mechanism of MR associated with NCCM as a distinct entity with recognizable clinical, echocardiographic and histopathologic characteristics, and emphasizes the need to increase awareness of its distinctive features.

Methodology

This study focused on patients seen by the authors in the period between 2002 and 2013. The patients had been diagnosed with NCCM and MR in two different cardiac centers (the King Abdul-Aziz Cardiac Center, Riyadh, Kingdom of Saudi Arabia and the Sudan Heart Institute, Khartoum, Sudan) and followed up prospectively. Clinical and echocardiographic examinations were performed at presentation and on follow up using standard methods. Echocardiography was performed using Hewlett Packard HP 5000 at King Abdul-Aziz Cardiac Center, and Esaote My Lab 50 at the Sudan Heart Center. Histopathological examination was done where feasible.

Ethical clearance and permission to publish patient information was obtained from the respective hospitals. The authors did not receive any funding for this study.

Inclusion criteria

The study included patients whose NCCM was diagnosed by echocardiographic criteria (see below); patients whose ejection fraction (EF) was >45% at the time of diagnosis or on follow up; where mild or more MR associated with morphological changes in the mitral valve (MV) apparatus; and where there was an absence of a solid alternative cause for MR.

Exclusion criteria

The study excluded patients with NCCM and ejection fraction (EF) less than 45% or with another solid cause for MR.

Diagnosis of NCCM

The diagnosis of NCCM was based on the criteria outlined by Jenni et al. [7] However, we opted to include those with associated congenital heart disease. Diagnostic criteria included:

Abbreviations

EF	ejection fraction
MR	mitral regurgitation
NCCM	noncompaction cardiomyopathy
MV	mitral valve
AML	anterior mitral leaflet
PML	posterior mitral leaflet

1. In the parasternal short axis, the ventricular myocardium has a two-layer appearance (compacted and noncompacted).
2. Noncompacted to compacted layer thickness ratio equals or is more than 2:1, measured at the short axis view at the end of systole distal to papillary muscles.
3. Inter-trabecular recesses were demonstrated by using low scale color flow mapping.

Diagnosis of mitral regurgitation

The mitral valve morphology was examined by 2-D echocardiography. MR was assessed by Color Flow Doppler. A 3–5 mm jet is considered mild, 5–7 mm with left atrial and ventricle dilatation is considered moderate. A jet with vena contracta of >7 mm with left atrial and ventricle dilatation or with swirling jet or reversal of flow in pulmonary veins is considered severe MR.

Results

Nineteen patients were diagnosed with NCCM and MR (four patients from King Abdul-aziz Cardiac Center and 15 patients from the Sudan Heart Center). MV histopathology was done for one patient (Table 3 with other cases from the literature).

Patient ages ranged between five months to 16 years with a mean of 5.7 years, and 85% of the patients were females.

Clinical findings (Table 1)

Improvement of heart failure symptoms associated with improvement of ejection fraction was found in two patients (10%).

Echocardiographic findings (Table 2)

Leaflet retraction was seen in all patients. Abnormal coaptation of the anterior MV leaflet (AML) superior to the posterior (PML) with a zigzag deformity of AML (Fig. 1A and B) were seen in 11 patients (57%). Chordal rupture was observed in two patients (Fig. 2) and chordal elongation in one patient (number 19, Fig. 5).

Table 1. Clinical and echocardiographic features and the outcome of patients with VNC/MR.

No.	Age/sex	Reported by	Clinical	Echo	Outcome
1	18 month/M	Sulafa et al. [6]	Heart failure	Moderate MR Restriction of leaflet motion zigzag deformity and superior coaptation of AML EF 65%	Lost to follow up
2	12 month/F (Twin 1)	Sulafa et al. [6]	Progressive Heart failure	Severe MR Restriction of leaflet motion Thickened MV chordate Superior coaptation of AML EF 65%	MV replacement Follow up at 10 years of age showed mitral stenosis, EF 65%
3	12 month/F (Twin 2)	Sulafa et al. [6]	Severe Heart failure at age of 7 days which improved completely at age 6 months	Initial echo at 7 days: dilated LV, EF 20%, mild MR, restriction of leaflet motion, superior coaptation of AML. Echo at 12 months: EF 70%, mild MR and left ventricle hypertrophy	Followed up till 10 years of age, mild MR, EF 70%
4	5 month/F	Sulafa et al.[6]	Heart failure	Large mid muscular VSD MV: Restriction of leaflet motion, Superior coaptation and zigzag deformity of AML Mild-moderate MR, EF 60%	VSD closure, sudden onset of ventricular fibrillation on first post operative day. Discharged with hypoxic ischemic encephalopathy. Lost to follow up
5	18 month/F	Sulafa Ali [10]	Heart failure	AML coopts superior to the posterior leaflet with zigzag deformity. Severe MR. Ejection fraction is 62%	Follow up for 12 months, still with severe MR
6	12 year/F	Sulafa Ali [10]	Heart failure	AML coopts superior to the posterior leaflet with zigzag deformity. Moderate MR. Ejection fraction is 65%	Follow up for 6 months, still with severe MR
7	8 year/F	Sulafa Ali [10]	Heart failure	Hypertrophic and noncompaction cardiomyopathy. Ejection fraction is 80%. AML coopts superior to the posterior leaflet with moderate MR	No follow up
8	3 year/F	Sulafa Ali [11]	Heart failure	AML coopts superior to the posterior leaflet with zigzag deformity. Severe MR. Ejection fraction is 60%	Follow up 3/12, still with severe MR
9	5 year/F	Sulafa Ali [11]	Heart failure	AML coopts superior to the posterior leaflet with zigzag deformity. Severe MR. Ejection fraction is 62%	No follow up
10	7 year/F	Sulafa Ali [11]	Heart failure	AML coopts superior to the posterior leaflet with zigzag deformity. Severe MR. Ejection fraction is 65%	No follow up
11	12 month/F	New patient (by the authors)	Heart failure	Large VSD, AML coopts superior to the posterior leaflet with zigzag deformity (Fig. 1 A). Moderate MR Ejection fraction is 65%	Surgical VSD closure, Still with moderate MR and normal EF at 8 months follow up
12	4 year/F	New(by the authors)	Heart failure	EF 70%, Severe MR, ruptured – chordate (Fig. 2)	–
13	15 year/F	New(by the authors)	Heart failure	EF 55%, Severe MR, zigzag deformity of AML (Fig. 1B), retracted MV leaflets with extensive papillary muscle involvement (Fig. 3A) central MR jet (Fig. 3B)	–

(continued on next page)

Table 1 (continued)

No.	Age/sex	Reported by	Clinical	Echo	Outcome
14	4 year/M	By the author	Heart failure	EF 60%, severe MR, retracted leaflets, extensive papillary muscle involvement central MR jet	MV Replacement well 3 y after surgery
15	5 year/F	New (by the authors)	A symptomatic, referred because heart murmur	EF 45%, Mild MR, retracted leaflets	–
16	7 year/F	New (by the author)	Heart failure, resolved with treatment.	EF 47%, mild MR, retracted leaflets	–
17	16 year/F	New (by the author)	Heart failure	EF 65%, moderate MR, ruptured chordate	
18	2 year/M	New	Heart failure. dysmorphic with small head, squint and delayed development	EF 56%, Severe MR and TR. Biventricular noncompaction, tricuspid valve deformity. (Fig. 4)	
19	16 year/F	New	Heart failure	Low EF 30%, Moderate MR, Elongated chordate (Fig. 5)	EF improved over 4 months to 60%, moderate MR

Abbreviations: MR, mitral regurgitation; AML, anterior mitral leaflet; EF, ejection fraction; MV, mitral valve; VSD, ventricular septal defect; VNC, ventricular noncompaction; TR, tricuspid regurgitation; LV, left ventricle.

Table 2. Echocardiographic features of VNC/MR association.

Feature	No./Reported cases (%)
Leaflet retraction	19/19 (100)
Anterior leaflet coapts superior to the posterior leaflet (Fig. 1A)	11/19 (57)
Ruptured/elongated chordae	3/19 (15)
In the 4 chamber view the anterior leaflet has a zigzag deformity (Fig. 1A and B)	11/19 (57)
A central MR jet (Fig. 3B)	16/19 (84)
Recovery of myocardial dysfunction	2/19 (10)
Associated congenital heart disease	2/19 (10) :Both with ventricular septal defect (Fig. 1A)

Abbreviations: VNC, ventricular noncompaction; MV, mitral valve; MR, mitral regurgitation.

Table 3. Pathological correlation in patients with VNC-MR association.

Patient No.	Author	Description
1	Ali et al. [4]	Sclerotic and calcific changes
2	Chung et al. [5]	On gross findings of the left ventricle cavity, the anterior mitral leaflet chordae were ruptured and severe noncompacted endomyocardium was observed. Owing to a friable posterior lateral papillary muscle, Myxomatous degeneration and hemorrhage. (Fig. 4)
3	Igarashi et al. [9]	Myxomatous degeneration of the ruptured chordae, mild fibrosis of papillary muscles
4	Curcic et al. [11]	Myocardial tissue represents the basis of a huge left ventricle papillary muscle. Endocardial fibroelastosis, dilated type. Hypocellular fibrous tissue with multiple lamellae of coarse elastic fibres arranged parallel to the luminal surface. The endocardium is extremely thickened extending in the subendocardium

EF was normal in 80% of patients and mildly impaired (45–55%) in 20%. Improvement of EF was associated with left ventricle (LV) hypertrophy in two patients.

Pathological correlations

A pathological study was available for one of our patients (number1), which revealed sclerotic and calcific changes. The pathological features of this

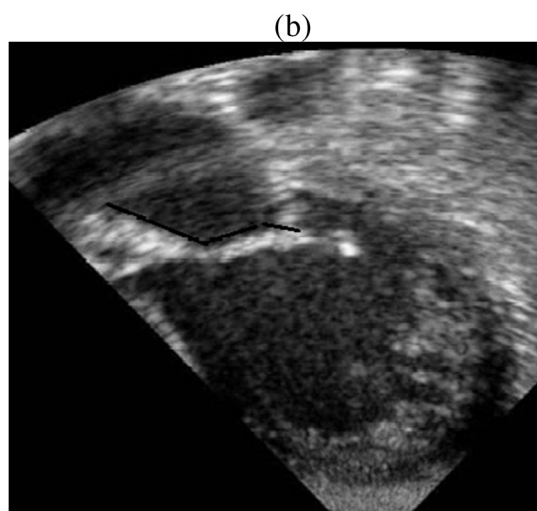
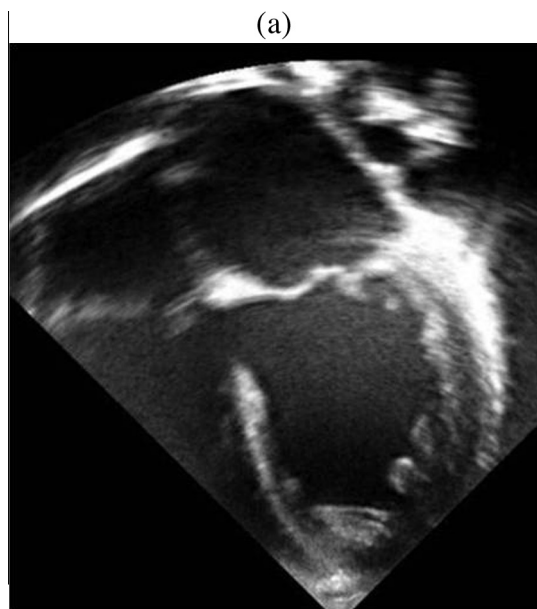


Figure 1. (a) Four-chamber view of patient 11 showing a large VSD, NCCM, and zigzag deformity of AML. (b) Four-chamber with aorta view of patient 13 showing zigzag deformity of AML (black line).

patient and three more patients from the literature are shown in Table 3.

Follow up

Eight patients were followed up for a period of three to 120 months (mean of 36 months). Two had mitral valve replacement with good outcome at three and 10 years of age. In two patients, MR continued to be severe after three to eight months of follow up.

Discussion

Improvement of heart failure symptoms associated with improvement of ejection fraction is one

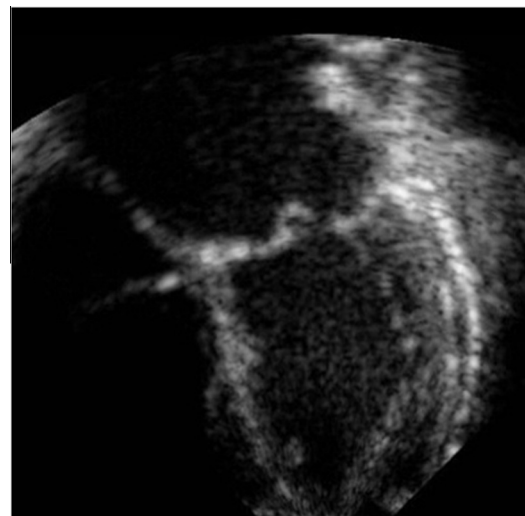


Figure 2. Four-chamber view of patient 12 showing flail anterior MV leaflet due to ruptured chordae.

of the distinctive clinical features of NCCM. Similar observations has been reported in patients without MR [3]. Clinical relapses and remissions distinguish NCCM from all other cardiomyopathies where relapses are not known events. Similar observations were reported by Bhat et al. [8] and Igarashi et al. [9] after MV surgery where ejection fraction significantly improved, a feature rarely occurs in other forms of cardiomyopathy. Another report by Martinez et al. [10] described mild MR with low EF where, on follow up, EF improved while MR worsened, emphasizing that MR is not secondary to myocardial dysfunction.

Echocardiographic findings of abnormal coaptation of the leaflets can be misinterpreted as MV prolapse. This misinterpretation is clear in the report by Martinez, where authors describe the MV in a patient as 'query prolapsed', while the PML had restricted movement (see Potential pitfalls in diagnosis of NCCM-MR association below). Chordal rupture, which was observed in two patients, is an important finding and one that has also been reported by others [5,9]. In addition, we observed chordal elongation which may be the precursor of rupture, and which can be explained by an extensive papillary muscle involvement noted by echocardiography (as in Figs. 3A and 4).

A distinct feature of NCCM-MR association is preservation of myocardial systolic function. This feature helps to differentiate this entity from MR secondary to left ventricle (LV) systolic dysfunction. Recovery of myocardial dysfunction can be associated with improvement of LV dilatation, often with the thickening/hypertrophy of the left ventricle myocardium (so-called undulating phenotype) as in patient numbers 3 and 7.

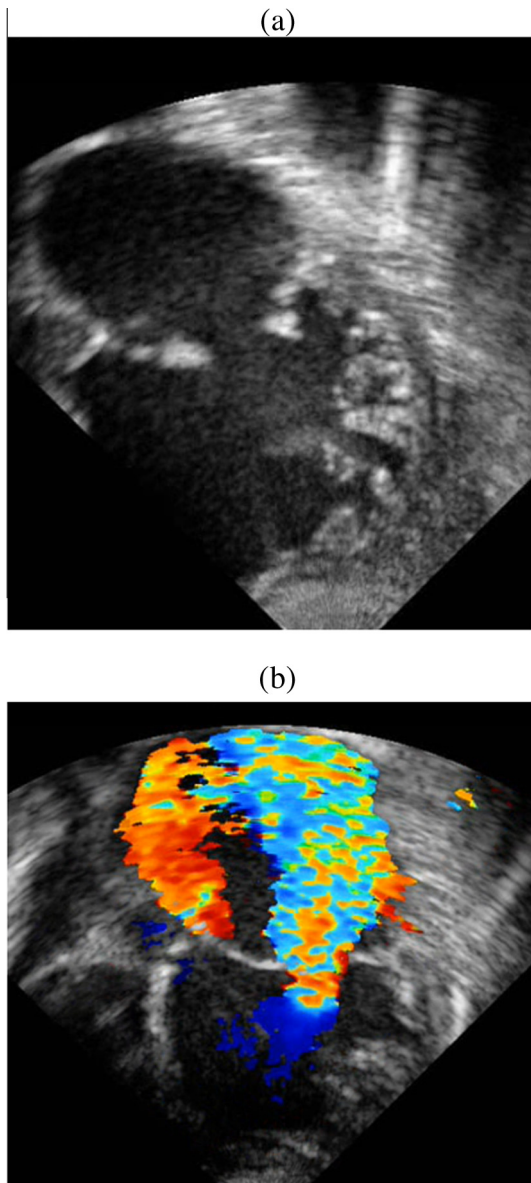


Figure 3. (a) Four-chamber view of patient 13 showing retracted MV leaflets, VNC with extensive papillary muscle involvement. (b) Four-chamber view of patient 13 showing a large central MR jet, swirling in left atrium.

However, myocardial trabeculations continued to be present [3].

Intra operative and pathological correlations

Pathological features of NCCM-MR are available from one of our patients and three other patients from the literature (Table 3). Sclerotic and calcific changes were seen in our patient (4), Myxomatous degeneration was found in two patients. Papillary muscles were found to be friable and fibrosed, and chordal rupture of AML was documented during intra operative

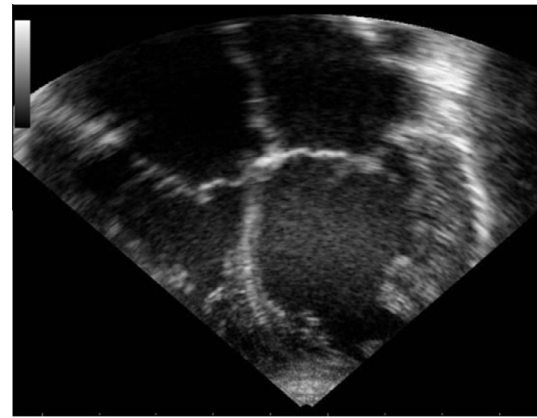


Figure 4. Four-chamber view of patient 18 showing biventricular noncompaction with mitral and tricuspid valve retraction and deformity (arrows).

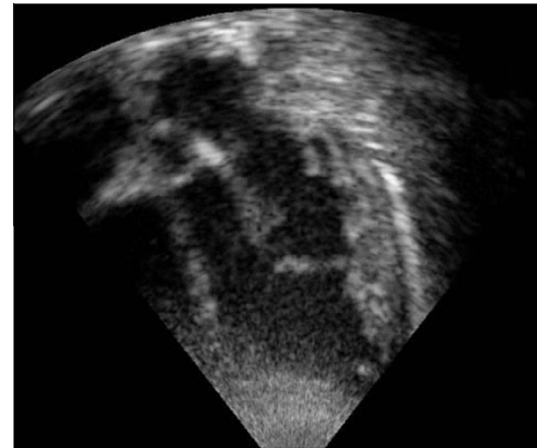


Figure 5. Four-chamber with aorta view of patient 19 showing elongated mitral valve chord (arrows).

examination of the valve [5,9]. Endocardial fibroelastosis was noted at the base of the papillary muscle [11]. In addition, postmortem studies performed for 14 cases of NCCM revealed two patients with atrioventricular valve dysplasia including one MV and one tricuspid valve, findings that support our echocardiographic observations. Furthermore, the authors of this study described right ventricle involvement in 6/14 patients, similar to our findings in patient number 18 [12].

These pathological findings explain the echocardiographic features of malcoaptation which seems to be secondary to chordal elongation/rupture due to papillary muscle involvement.

Potential pitfalls in diagnosis of NCCM-MR association

NCCM is typically an under-diagnosed condition due to the lack of full understanding of its

distinctive features on the part of both cardiologists and echocardiographers. On the other hand, the absence of consensus regarding its echocardiographic criteria may lead to over diagnosis.

The following may need to be observed for the diagnosis of NCCM-MR association:

1. *Criteria for NCCM:* Several proposed criteria are present but the most widely used is that of Jenni et al. [7] Although these criteria need to exclude associated heart disease, we omitted this from our inclusion criteria as NCCM is known to occur in patients with congenital heart disease [3]. Some authors have expressed concern about the reliability and reproducibility of these criteria especially since they depend on loading conditions of the ventricle which is the case in patients with MR [13]. Some authors have used the term 'hypertrabeculation,' which is synonymous with NCCM [13]. However, we feel this leads to confusion and we suggest that a unified nomenclature be used.
2. *Exclusion of other causes of MR:* In infants and young children, congenital MR needs to be carefully excluded in patients with NCCM-MR association. The pattern of echocardiographic abnormalities of the MV in NCCM-MR association, though individually not pathognomonic, renders the constellation of findings together with the presence of NCCM a unique one. Furthermore, in patients with congenital MR the LV is usually dilated and thin walled rather than hypertrabeculated.

In older children, acquired causes of MR like rheumatic heart disease and MV prolapse should be investigated. The typical pattern of rheumatic MR constitutes tethering of the posterior leaflet and malcoaptation of AML with eccentric posteriorly directed MR jet, features not present in NCCM-MR association [14].

Features that help to distinguish NCCM-MR association from MV prolapse

These include:

- i. In MV prolapse, the leaflets have increased mobility which usually involves both leaflets, while in NCCM-MR association, leaflets have retracted appearance with limited motion.
- ii. The MR jet is usually eccentric, posteriorly directed in MV prolapse, while it is usually central in NCCM-MR association.
- iii. The tips of the leaflets are typically thickened in MV prolapse but not in NCCM-MR association.

Of note is that superior displacement of AML and chordal rupture can occur in both MV prolapse and NCCM-MR association.

Therapeutic and prognostic implications of diagnosis of NCCM-MR association

In this patient cohort group, two patients underwent MV replacement with good short and long term outcomes. Tariq and Chung reported two cases where the papillary muscle affection prohibited MV repair, and the patients underwent MV replacement with good short term outcome and recovery of left ventricle systolic dysfunction [5,8]. In two patients, ventricular septal defect closure was done, with one patient developing post operative ventricular arrhythmia, a known complication of NCCM, that led to neurological sequelae. The following are important implications of the diagnosis on patient management:

1. Myocardial systolic dysfunction is a known association of NCCM that needs to be considered at the time of surgery for MR and on patient counseling. On the other hand, recovery of myocardial function may be anticipated before or after surgery. The potential improvement in myocardial dysfunction may change the treatment decision from heart transplant to MV repair even when the EF is as low as 15%, as has been reported by Badwar [6].
2. NCCM is known to predispose to ventricular arrhythmias especially perioperatively, which can add to morbidity and mortality.
3. Thromboembolism, a known complication of NCCM, needs to be considered and interventions to prevent it initiated.

Limitations

This study contains a limited number of patients with histopathological examinations.

Conclusion

In what we believe is an under-diagnosed entity, we described the mechanism of MR caused by NCCM and its clinical, echocardiographic features as well as intra operative and pathological correlations.

Appendix A. Supplementary data

Supplementary data associated with this article can be found, in the online version, at <http://dx.doi.org/10.1016/j.jsha.2014.07.002>.

References

- [1] Hare, JM. The dilated, restrictive, and infiltrative cardiomyopathies. In: Libby P, Bonow RO, Mann DL, Zipes DP, editors, Braunwald's heart disease: a textbook of cardiovascular medicine. 8th edition, vol. 2. Philadelphia: Saunders Elsevier. p. 1739–1762.
- [2] Maron BJ, Towbin JA, Thiene G, Antzelevitch C, Corrado D, Arnett D, et al.. Contemporary definitions and classification of the cardiomyopathies: an American Heart Association Scientific Statement from the council on clinical cardiology, heart failure and transplantation committee; quality of care and outcomes research and functional genomics and translational biology interdisciplinary working groups; and council on epidemiology and prevention. *Circulation* 2006;113(14):1807–16.
- [3] Pignatelli RH, McMahon CJ, Dreyer WJ, Denfield SW, Price J, Belmont JW, et al.. Clinical characterization of left ventricular noncompaction in children: a relatively common form of cardiomyopathy. *Circulation* 2003;108(21):2672–8.
- [4] Ali SK, Omran AS, Najm H, Godman MJ. Noncompaction of ventricular myocardium with mitral regurgitation and preserved ventricular function. *J Am Soc Echocardiogr* 2004;17(1):87–90.
- [5] Chung JW, Lee SJ, Lee JH, Chin JY, Lee HJ, Lee CJ, et al.. Isolated left ventricular noncompaction cardiomyopathy accompanied by severe mitral regurgitation. *Korean Circ J* 2009;39(11):494–8.
- [6] George KM, Badhwar V. Sustainable myocardial recovery after mitral reconstruction for left ventricular noncompaction. *Ann Thorac Surg* 2010;89(4):1283–4.
- [7] Jenni R, Oechslin E, Schneider J, Attenhofer Jost C, Kaufmann PA. Echocardiographic and pathoanatomical characteristics of isolated left ventricular non-compaction: a step towards classification as a distinct cardiomyopathy. *Heart* 2001;86(6):666–71.
- [8] Bhat T, Costantino T, Bhat H, Olkovsky Y, Akhtar M, Teli S, et al.. Long-term myocardial recovery after mitral valve replacement in noncompaction cardiomyopathy. *J Cardiothorac Surg* 2011;6:124.
- [9] Igarashi T, Takase S, Satokawa H, Wakamatsu H, Kurosawa H, Yokoyama H. Left ventricular noncompaction complicated by mitral valve prolapse: report of a case. *Surg Today* 2013;43(7):818–20.
- [10] Martinez HR, Niu MC, Sutton VR, Pignatelli R, Vatta M, Jefferies JL. Coffin-Lowry syndrome and left ventricular noncompaction cardiomyopathy with a restrictive pattern. *Am J Med Genet A* 2011;155A(12):3030–4.
- [11] Curcic P, Knez I, Kandolf R, Gamillscheg A. A rare case of left ventricular non-compaction in early infancy. *Eur J Cardiothorac Surg* 2012;41(4):960.
- [12] Burke A, Mont E, Kutys R, Virmani R. Left ventricular noncompaction: a pathological study of 14 cases. *Hum Pathol* 2005;36(4):403–11.
- [13] Stöllberger C, Finsterer J. Left ventricular hypertrabeculation/noncompaction. *J Am Soc Echocardiogr* 2004;17(1):91–100.
- [14] Reményi B, Wilson N, Steer A, Ferreira B, Kado J, Kumar K, et al.. World Heart Federation criteria for echocardiographic diagnosis of rheumatic heart disease—an evidence-based guideline. *Nat Rev Cardiol* 2012;9(5):297–309.