

# Failed Transcatheter Closure of a Giant Ruptured Sinus of Valsalva Aneurysm

Bo Zhang, Yong Sun, Jian Wu, Jing-Yi Zhu, Rui Cao, Xiang-Lan Liu, Bo Yu

Department of Cardiology, Second Affiliated Hospital of Harbin Medical University, Harbin, Heilongjiang 150081, China

To the Editor: I want to introduce to you a very unusual case today. A 24-year-old man consulted us because of a 2-year history of palpitations and shortness of breath after physical exertion. Physical examination revealed a heart rate of 80 beats/min and blood pressure of 150/70 mmHg. Heart auscultation revealed diastolic and systolic (class VI) murmurs between the 3<sup>rd</sup> and 4<sup>th</sup> ribs at the left sternal border. His New York Heart Association functional class was III. Echocardiography showed a slightly enlarged left ventricle (57 mm) with significant widening of the aortic root, a thin right coronary sinus with extension into the distal right ventricular outflow tract, and a 1.4 cm diameter defect in the upper part of the outflow tract. Transesophageal echocardiography showed the aortic root diameter was 46.2 cm. There was mild aortic regurgitation with an aortic valve area of 2.24 cm<sup>2</sup>. Doppler ultrasonography showed continuous diastolic and systolic blood flow from the defect in the right ventricular outflow tract, with a flow rate of 4.49 m/s and a pressure difference of 80 mmHg; and increased blood flow velocity at the pulmonary valve orifice. The patient was diagnosed with a ruptured sinus of the valsalva aneurysm (RSVA). As the patient urged to take the minimally invasive treatment, we chose transcatheter closure. Moreover, the patient signed a consent form for the use of a patent ductus arteriosus (PDA) occluder.

For aortic root angiography, the patient was placed horizontally, and 1% lidocaine was infiltrated for local anesthesia. The right femoral vein and femoral artery were punctured, and a 6 Fr sheath was placed in each vessel. A 6 Fr pigtail catheter was advanced via the femoral artery to the aortic root. Multi-angle angiography was performed. The 45° right anterior oblique view clearly showed an RSVA. The base of the defect was 14 mm in diameter and irregular, and extended into the right ventricular outflow tract [Figure 1]. The distance between the ostium of the right coronary artery and the neck of the defect was 20 mm. Moreover, the distance between the aortic annulus and the defect was 18 mm. A 12 Fr PDA delivery sheath was advanced via the femoral vein to the aorta, and the defect was occluded with an 18–20 mm PDA occluder (Xin Jian, China). Angiography showed a small amount of residual shunt [Figure 2]. Coronary angiography showed device had no effect on the coronary artery. The patient was asked to take aspirin for 6 months.

After the procedure, the New York Heart Association functional class was II. Echocardiography showed mild enlargement of the left ventricle (58 mm). Doppler ultrasonography showed a 3.75 cm<sup>2</sup>

area of blood flow from the aortic valve orifice to the left ventricular outflow tract during diastole. Transesophageal echocardiography showed the aortic root diameter was 40 cm. There was aortic regurgitation with an aortic valve area of 2.27 cm<sup>2</sup>. The patient was discharged after his symptoms improved. Six months after the procedure, auscultation revealed a diastolic murmur between the 3<sup>rd</sup> and 4<sup>th</sup> ribs at the left sternal border. Echocardiography showed a left ventricular size of 52 mm, and an increased area of aortic regurgitation (4.9 cm<sup>2</sup>). One year after the procedure, the patient experienced recurrence of palpitations and shortness of breath during physical exertion. Echocardiography showed mild prolapse of the right coronary cusp of the aortic valve, and an eccentric 5.5 cm<sup>2</sup> area of blood flow from the aortic valve orifice to the left ventricular outflow tract during diastole. Blood flow was observed at the lower edge of the occluder, measuring 0.23 cm in width with a flow velocity of 5.35 m/s. The patient underwent surgical repair 1 month later.

Successful transcatheter closure of RSVAs has been reported with increasing frequency since 1994.<sup>[1–3]</sup> Kerkar *et al.*<sup>[4]</sup> reported 20 patients who underwent transcatheter closure of an RSVA (median defect size 9 mm, range: 4–11 mm). In our patient, the heart murmur disappeared, and the cardiac chambers reduced in size for a short time after the procedure. The residual shunt disappeared because the edge of the defect was occluded by local thrombosis. The main reasons for the poor long-term outcome in this case are as follows. First, the aortic sinus aneurysm caused a large defect (14 mm diameter), and some of the adjacent tissues were fragile and weak. Second, the defect was closed using an 18–20 mm PDA occluder. The weight of this large occluder caused deformation of the aortic annulus, resulting in increased aortic regurgitation and enlargement of the left ventricle.

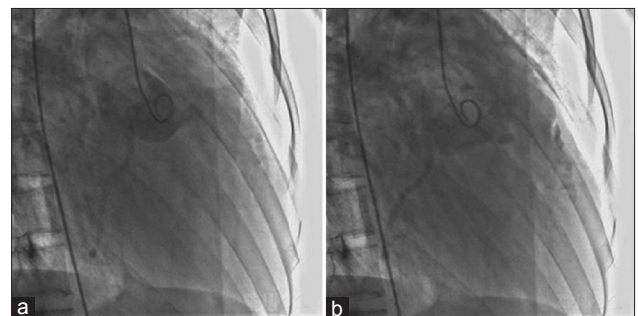


Figure 1: (a and b) The angiography before closure.

## Access this article online

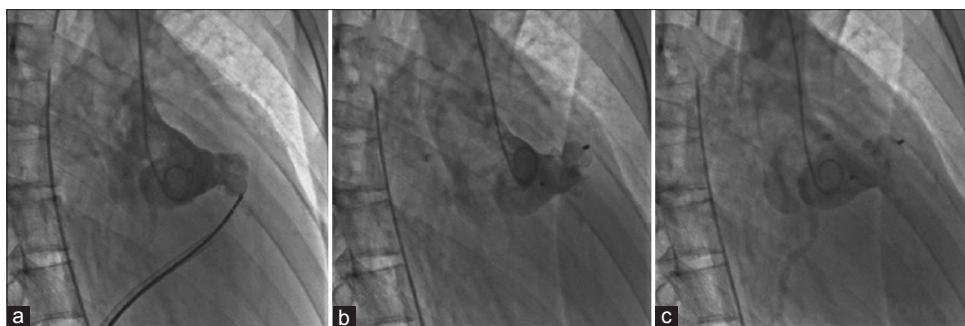
### Quick Response Code:



Website:  
www.cmj.org

DOI:  
10.4103/0366-6999.160624

**Address for correspondence:** Dr. Yong Sun,  
Department of Cardiology, Second Affiliated Hospital of Harbin Medical  
University, Harbin, Heilongjiang 150081, China  
E-Mail: zb081720@126.com



**Figure 2:** (a-c) The angiography after closure.

There are currently no dedicated occluders for the treatment of RSVA, and PDA occluders are commonly used for this condition.<sup>[3,4]</sup> In a reported case of RSVA with two defects, two occluders were used.<sup>[5]</sup> Successful closure of an RSVA with a modified double-disk ventricular occluder (Shanghai Shape Memory Alloy Ltd., China) has also been reported.<sup>[6]</sup> Rittger *et al.*<sup>[7]</sup> successfully used an Amplatzer Vascular Plug II to close an RSVA. Considering our patient's large defect, the domestic thin-waist-big-side type ventricular septal defect occluder might have been a better choice, as it weighs less than the PDA occluder and would have caused less traction on the aortic annulus.

In conclusion, interventional treatment failed in this case because of the large size of the defect and generally low success rate of such procedures. Use of a relatively large occluder caused traction on the aortic annulus, resulting in increased aortic regurgitation. If the diameter of the RSVA defect exceeds 10 mm, we recommend surgical treatment rather than transcatheter closure. Development of dedicated occluders for the treatment of RSVA is urgently needed.

## REFERENCES

1. Zhi HJ, Yi TM. Interventional therapy of aortic aneurysm rupture. *China J Inter Cardiol* 2008;16:55, 57.
2. Cullen S, Somerville J, Redington A. Transcatheter closure of a ruptured aneurysm of the sinus of Valsalva. *Br Heart J* 1994;71:479-80.
3. Zhong L, Tong SF, Zhang Q, Zhang ZH, Yao Q, Li YH, *et al.* Clinical efficacy and safety of transcatheter closure of ruptured sinus of valsalva aneurysm. *Catheter Cardiovasc Interv* 2014;84:1184-9.
4. Kerkar PG, Lanjewar CP, Mishra N, Nyayadhish P, Mammen I. Transcatheter closure of ruptured sinus of Valsalva aneurysm using the Amplatzer duct occluder: Immediate results and mid-term follow-up. *Eur Heart J* 2010;31:2881-7.
5. Szkutnik M, Kusa J, Glowacki J, Fiszer R, Bialkowski J. Transcatheter closure of ruptured sinus of valsalva aneurysms with an Amplatzer occluder. *Rev Esp Cardiol* 2009;62:1317-21.
6. Chen F, Li SH, Qin YW, Li P, Liu SX, Dong J, *et al.* Transcatheter closure of giant ruptured sinus of valsalva aneurysm. *Circulation* 2013;128:e1-3.
7. Rittger H, Gundlach U, Koch A. Transcatheter closure of ruptured sinus of Valsalva aneurysm into the right ventricle with an Amplatzer Vascular Plug II. *Catheter Cardiovasc Interv* 2015;85:166-9.

**Received:** 28-12-2014 **Edited by:** Xiu-Yuan Hao

**How to cite this article:** Zhang B, Sun Y, Wu J, Zhu JY, Cao R, Liu XL, *et al.* Failed Transcatheter Closure of a Giant Ruptured Sinus of Valsalva Aneurysm. *Chin Med J* 2015;128:1985-6.

**Source of Support:** Nil. **Conflict of Interest:** None declared.