

## Scientific Research Report

## The Influence of the Maxillary Posterior Region on Smile Aesthetics in a Chinese Cohort

Ning Wei<sup>a</sup>, Cui Wang<sup>a</sup>, Yanling Zhang<sup>a</sup>, Yiping Wei<sup>a</sup>, Wenjie Hu<sup>a\*</sup>, Xu Yang<sup>b</sup>, Kwok-Hung Chung<sup>c</sup><sup>a</sup> Department of Periodontology, Peking University School and Hospital of Stomatology, National Engineering Laboratory for Digital and Material Technology of Stomatology, Beijing Key Laboratory of Digital Stomatology, Beijing, China<sup>b</sup> Department of Prosthodontics, Peking University School and Hospital of Stomatology, National Engineering Laboratory for Digital and Material Technology of Stomatology, Beijing Key Laboratory of Digital Stomatology, Beijing, China<sup>c</sup> Department of Restorative Dentistry, School of Dentistry, University of Washington, Seattle, Washington, USA

## ARTICLE INFO

## Article history:

Received 1 September 2021

Received in revised form

5 January 2022

Accepted 11 February 2022

Available online 24 March 2022

## Key words:

Anterior smile line

Posterior smile line

Aesthetics

Visual analog scale

## ABSTRACT

**Objectives:** The aim of this research was to establish standard norms for posterior smile-related characteristics including posterior smile line (PSL), the most posterior teeth displayed, buccal corridor ratio (BCR), and buccal corridor symmetry (BCS) and investigate its aesthetic contributions to smile attractiveness in a Chinese population.**Materials and methods:** From digitally recorded dynamic smile videos of young Chinese participants, 188 standardised full-smile images were captured and then aesthetically evaluated by 22 laypersons using a visual analog scale (VAS). Four smile-related variables in the posterior region were analysed. VAS data were compared between subgroups to test the influence of these variables on smile aesthetics with significance level of  $P < .05$ .**Results:** The VAS scores of participants with high PSL were significantly lower than those with average or low PSL ( $P < .01$ ), especially when they display average or low anterior smile line ( $P < .05$ ). Smiles with the second premolar displayed obtained the highest VAS amongst the 3 subgroups ( $P < .05$ ). No significant differences were found between the VAS scores of BCR and BCS ( $P > .05$ ).**Conclusions:** Maxillary posterior gingiva and teeth displayed influence smile attractiveness evaluated by laypersons, which should be given attention when treating patients with compromised aesthetics, especially those displaying average or low anterior smile lines.

© 2022 The Authors. Published by Elsevier Inc. on behalf of FDI World Dental Federation.

This is an open access article under the CC BY-NC-ND license

<http://creativecommons.org/licenses/by-nc-nd/4.0/>

## Introduction

A harmonious smile plays an undeniable role in facial attractiveness, which exerts an important influence on personal self-esteem and social activities.<sup>1,2</sup> Even tiny imperfections in dental and gingival aesthetics may compromise the whole smile attractiveness, thus adversely affecting facial appearance and related psychological behaviour.<sup>3</sup> An aesthetic smile is a harmonious entity formed by fundamental components including teeth, gingiva, lips, and spaces.<sup>4,5</sup>

Previous studies on smile aesthetics mainly focused on the effect of dental gingiva-related factors in the maxillary anterior region, such as the shape, size, proportion, and position of anterior teeth, midline deviation, anterior teeth and gingival display, and gingival architecture and morphology.<sup>5-10</sup> Only a few reports reviewed the norms of posterior smile-related characteristics and their influence on smile attractiveness.<sup>4,11-13</sup> It is worth pointing out that most people display maxillary premolars when smiling, partially showing the continuous gingival band during smiling, according to Maulik and Nanda.<sup>12</sup> Therefore, great attention should be paid to aesthetically demanding cases, in which posterior teeth and gingiva are displayed when smiling. To date, insufficient scientific data about various posterior components can serve as guidance in clinical situations, and the contribution of these characteristics to aesthetics perception by laypersons is largely unknown.<sup>10,13,14</sup>

\* Corresponding author. Department of Periodontology, Peking University School and Hospital of Stomatology, National Engineering Laboratory for Digital and Material Technology of Stomatology, Beijing key Laboratory of Digital Stomatology, 22 Zhongguancun Avenue South, Haidian District, Beijing 100081, China.

E-mail address: [huwenjie@pkuss.bjmu.edu.cn](mailto:huwenjie@pkuss.bjmu.edu.cn) (W. Hu).

<https://doi.org/10.1016/j.identj.2022.02.004>

0020-6539/© 2022 The Authors. Published by Elsevier Inc. on behalf of FDI World Dental Federation. This is an open access article under the CC BY-NC-ND license (<http://creativecommons.org/licenses/by-nc-nd/4.0/>)

Several smile-related characteristics of the posterior region have been proposed.<sup>4,12</sup> The posterior smile line (PSL)<sup>12</sup> or posterior gingival display was found to be related with smile aesthetic perception; this was evaluated by a small sample of a European population through a series of computer-manipulated smiling images that displayed different percentages of posterior teeth and gingiva, rather than authentic ones.<sup>4</sup> The most posterior teeth displayed (MPTD) represents to some degree the width of the white aspects-related factor (tooth-related aesthetics) and indicate the scope of aesthetic treatment. The buccal corridor, also called as lateral negative space or lateral dark space, refers to visually dark space conceived between the buccal surface of the posterior teeth and the corners of the lips during smiling.<sup>15</sup> Previous studies analysed the average of buccal corridor amongst the general population and celebrities, including the ideal range preferred by volunteers with different educational or ethical backgrounds.<sup>16-19</sup> Nevertheless, controversial results were produced in different studies,<sup>17,18</sup> thus requiring more thorough research to investigate the relationship between the buccal corridor and aesthetic perception. In addition, several studies have been conducted on authentic images to analyse some of these smile-related characteristics in the posterior region,<sup>9,20</sup> but none of them considered the posterior region as a whole. To predict outcomes and achieve an attractive smile, it is necessary to analyse the impact of the posterior region on smile aesthetics and explore the relationship between smile variables in the posterior and anterior region.

The purpose of this study was to establish norms for posterior smile-related characteristics including PSL, MPTD, buccal corridor ratio (BCR), buccal corridor symmetry (BCS), and aesthetic contributions of these components to smile attractiveness as perceived by laypersons. Furthermore, the relationships amongst these 4 characteristics along with anterior smile line (ASL), smile pattern (SP), and upper lip curvature (ULC) were also explored. We hypothesised that PSL, MPTD, BCR, and BCS would have no influence on the perception of smile aesthetics and that there would be no correlation between ASL and PSL.

## Materials and methods

### Ethical approval

Peking University Medical Ethics Committee reviewed and granted the ethical consideration for this investigation (institutional review board approval number: 0902-12). The research was conducted in accordance with the World Medical Association Declaration of Helsinki and the guidelines of the committee. All participants voluntarily provided an informed consent statement after hearing the full explanation of the purpose of this project.

### Sample size

Using PSL as the main indicator, the sample size was calculated based on an estimated difference of 3 (mm/100 mm) in visual analog scale (VAS) scores. Allocation ratio was set at 1, assuming a ratio of 2:1 between individuals with and without

a high PSL.<sup>12,21</sup> The standard deviation of VAS scores in the assessment of smile aesthetics was 6 (mm/100 mm) according to our previous study.<sup>21</sup> Therefore, the estimated sample size was 170 participants in total, based on an alpha error at 0.05 and beta error at 0.2. To allow greater precision in the multivariate analysis, the sample size was increased by about 10%, 188 participants in total.

### Participants for smile assessment

A total of 188 young Chinese participants (88 men and 100 women) whose dynamic smile process was recorded digitally were enrolled in this study between October 2012 and April 2013, with inclusion criteria as follows: (1) age between 20 and 35 years; (2) complete permanent dentition with no tooth loss, caries, severe tooth wear, restorations, or prostheses in anterior teeth and premolars; (3) angle class I molar relationship with no malposition conditions such as severe crowding, spacing, tipping, or rotations in anterior teeth and premolars; (4) no active gingival and periodontal disease and no or minor gingival recessions (<1 mm); (5) no symptoms of facial paralysis or lip irregularities; and (6) no history of orthodontic treatment or maxillofacial surgery. Participants who were systemically compromised, pregnant, or lactating and those who had taken gingival hyperplasia-inducing drugs in the preceding 3 months were excluded. Initially, all participants received oral hygiene instructions and prophylactic treatment at least 2 weeks before dynamic smile recording.

### Dynamic smile videos and smile images

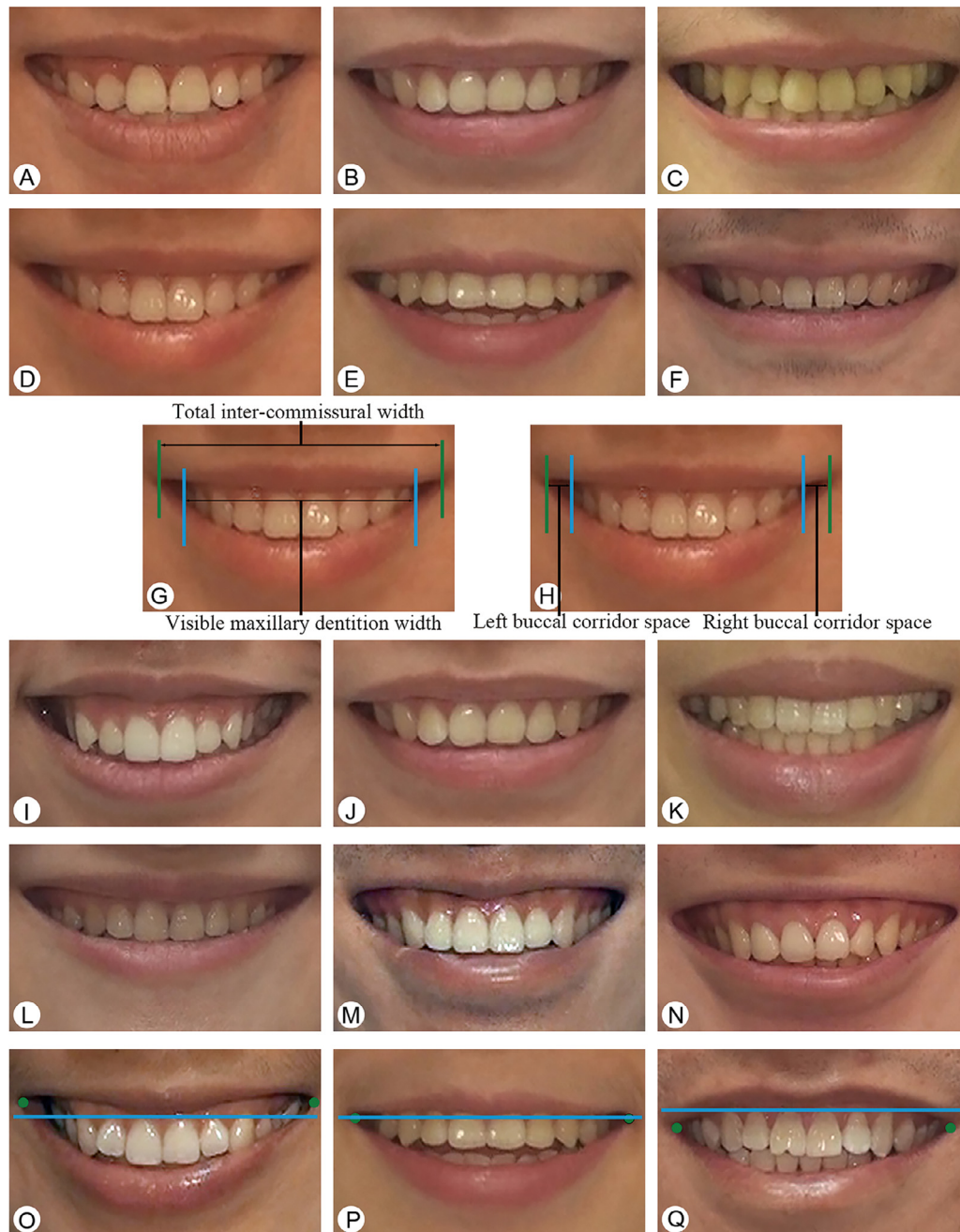The test setup, dynamic smile recording procedures with a calibrated scale, and full-smile image selected from smile video and standardised have been described in detail in previous studies.<sup>7,21</sup>

### Measurements of smile-related characteristics

Totally, 188 standardised frontal full-smile images with calibration were acquired for data collection on smile characteristics and aesthetic evaluation by laypersons using a VAS. Four posterior smile variables (PSL, MPTD, BCR, and BCS) and 3 anterior smile characteristics possibly related with posterior smile variables were measured digitally on full-smile images using Adobe Photoshop (version CS6, Adobe Systems Inc). One attending clinician (C.W.) performed all the measurements and analyses of the following smile variables, and intra-examiner reproducibility was assessed on 10 random-sampled participants. Then all the full-smile images were evaluated by laypeople.

PSL<sup>12</sup> was categorised as follows: (1) high PSL displays a contiguous band of gingiva above the maxillary first premolar; (2) average PSL displays 75% to 100% of the maxillary first premolar and interproximal papilla only; and (3) low PSL displays less than 75% of the maxillary first premolar (Figure 1A, B, C). The higher PSL was chosen when bilaterally asymmetric.

MPTD: A tooth exhibiting more than 50% of its buccal surface was deemed visible during smiling. Smiles were categorised by teeth displayed up to the first premolar, the second



**Fig. 1 – Examples of smile variables collected from left to right. A, B, C, High, average, and low posterior smile line. D, E, F, The most posterior teeth displayed: first premolar, second premolar, and first molar. G and H, Measurements to calculate buccal corridor ratio and buccal corridor symmetry. I, J, K, High, average, and low anterior smile line. L, M, N, Smile pattern of Rubin's classification: commissure smile, cuspid smile, and gummy smile. O, P, Q, Upwards, straight, and downwards upper lip curvature: the corner of the mouth (green points) and the hypothetical horizontal line (blue line) through the centre of lower border of the upper lip.**

premolar, or the first molar (Figure 1D, E, F). The most posterior visible tooth was chosen if bilateral asymmetry existed.

BCR was calculated as the difference between the total intercommissural width and the visible maxillary dentition width divided by total intercommissural width.<sup>9,17</sup> The ratio was categorised as follows: narrow (<10%), medium (10%-15%), medium-broad (15%-20%), and broad (>20%) (Figure 1G).

BCS referred to the uniformity of bilateral negative space. It is the ratio of the left buccal corridor space and the right

one (Figure 1H). The buccal corridor was symmetric if the ratio was over 0.5 and below 2.

ASL was divided into 3 categories including high, average, and low, based on the percentage of visible teeth and gingiva at the central incisor.<sup>5</sup> The higher ASL was chosen when bilaterally asymmetric (Figure 1I, J, K).

SP was the modification of Rubin's classification<sup>7</sup> and categorised in 3 types: (1) a commissure smile occurs when the corners of the mouth turn upwards initially due to the pull of

zygomaticus dominantly when the upper lip is elevated; (2) a cuspid smile, when the pull of the levator labii superioris displays the maxillary canines without the corners of the mouth turning upwards whilst the upper lip is elevated; and (3) a complex smile, where the upper lip is elevated uniformly and the lower lip moves inferiorly without the corners of the mouth turning upwards (Figure 1L, M, N).

ULC refers to the horizontal morphology of the inferior border of the upper lip, including 3 categories: (1) an upwards pattern means the corner of the mouth was 1 mm higher than the hypothetical horizontal line through the centre of the lower border of the upper lip; (2) a straight pattern means the corner of the mouth was at or within 1 mm higher or lower than the centre of the inferior border; and (3) a downwards pattern means the corner of the mouth was more than 1mm lower than the horizontal line (Figure 1O, P, Q).

### Assessment of smile aesthetics

All 188 standardised full-smile images were converted to a black-and-white JPEG format with the same size and pixel using Adobe Photoshop and then copied to one Microsoft PowerPoint document, each with a code number for further VAS assessment.

Twenty-two native laypersons (11 men and 11 women) aged between 20 and 35 years (average age,  $24.73 \pm 2.90$  years) with no educational background or participation in any dental professional or art-related fields were selected randomly from the patients of Peking University Stomatology Hospital. Following the study parameters and data collection, such as gender, age, education, and occupation of the patient, these participants judged aesthetics of each smile using the VAS. The methodology for VAS measurements adopted in this study has been described in detail previously, including the design of questionnaire, evaluation process, and score measurements.<sup>21</sup> Ten random-sampled participants were selected to test the intra-examiner reproducibility after all smile images randomly sequenced at the 2-week interval.

### Statistical analysis

All data were analysed by IBM SPSS Statistics (version 22.0, IBM Corp), and diagrams were made by OriginPro (version 2017, Origin Lab Corp) software. The kappa value was used to validate the intra-examiner consistency of smile variable measurements, whilst intra-class correlation coefficients (ICCs) was adopted for VAS assessments. PSL, MPTD, BCR, and BCS were calculated and expressed as percentage of each subgroup. Means and standard deviations of participants' general information and VAS scores were calculated and then compared between subgroups using unpaired Student's t test or one-way analysis of variance. Mann-Whitney U and Kruskal-Wallis rank sum test were used respectively if heterogeneity of variance existed. Last, the Chi-square test was used to compare the frequency of smile variable measurements between subgroups. The statistically significant level was established at  $P < .05$ .

## Results

### Reproducibility

The intra-examiner agreements for the 7 evaluated variables were good, with kappa values ranging from 0.837 to 0.882, indicating an excellent level of intra-examiner agreement for the smile variable measurements. The ICC of VAS measurements for 10 randomly selected participants revealed good intra-participant agreements, ranging from 0.628 to 0.802.

### Frequencies of smile variables measurements

The frequencies of 4 smile variables of maxillary posterior region including PSL, MPTD, BCR, and BCS are summarised in Figure 2. No statistically significant differences in the distribution of these smile variables between male and female participants were found ( $P < .05$ ).

### Aesthetic perception of smile variables

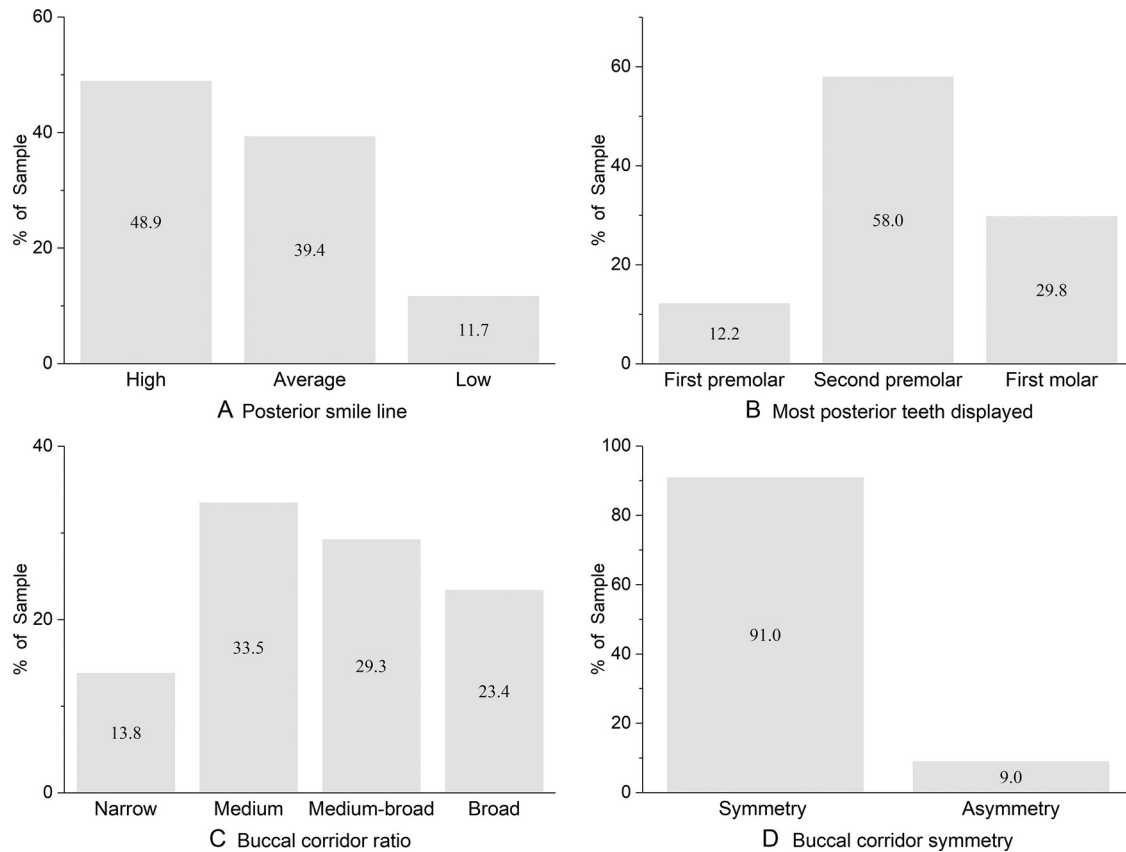
The VAS measurements of 4 smile variables are shown in the Table and categorised in different subgroups. On comparison of the VAS scores between subjects with different PSL, it appeared that a high PSL had a lower score on all the subgroups (high: 34.23; average: 37.84, and low: 37.81, respectively,  $P < .05$ ). As for the MPTD, smile with the second premolar displayed revealed the highest VAS amongst the 3 subgroups, with statistically significant differences detected between subgroups displaying the second premolar and the first molar ( $P < .05$ ). No statistically significant differences were found in BCR or BCS ( $P > .05$ ).

### Correlation between anterior and posterior smile variables

The relationships between anterior smile variables (ASL, SP, and ULC) and posterior smile variables affecting aesthetic perception (PSL and MPTD) are shown in Figure 3. There were statistically significant correlations between PSL and ASL ( $P < .01$ ). Of particular note, 64.4% of participants exhibited the same categories (ie, high, average, and low) of the ASL and PSL, respectively (Figure 3). To explore when high PSL affects smile aesthetics most, we compared the VAS measurements of subjects with different PSL in high and average/low ASL subgroups (Figure 4). The VAS measurements of high PSL were significantly lower than those of average-low PSL, when participants displayed average-low ASL (44.97 vs 46.63,  $P < .05$ ). For participants with high ASL, there were no significant differences between high or average-low PSL.

## Discussion

This study analysed the standard norms for posterior smile-related characteristics (PSL, MPTD, BCR, and BCS) and their contributions to smile attractiveness evaluated by laypersons. The null hypothesis that none of the above-mentioned 4 posterior smile-related elements influence the perception of smile aesthetics was rejected. Based on the findings of the



**Fig. 2 – Frequency of smile variables of maxillary posterior region. A, Posterior smile line. B, The most posterior teeth displayed. C, Buccal corridor ratio. D, Buccal corridor symmetry.**

present study, posterior smile variables including PSL and MPTD can impact the perception of smile attractiveness. And the discrepancies between ASL and PSL cannot be neglected. When the ASL is average/low, the display of gingiva and teeth in the maxillary posterior region should be taken into consideration.

**Table – VAS measurements (mm/100 mm) amongst different subgroups of the 4 smile variables.**

Smile variables	P value	Subgroups	Mean	SD
Posterior smile line	.006*	High	34.23*	0.75
		Average	37.84	0.98
		Low	37.81	1.05
Most posterior teeth displayed	.013*	First premolar	34.64	1.45
		Second premolar	37.45	0.77
		First molar	33.97*	0.89
Buccal corridor ratio	.470	Narrow	35.48	1.08
		Medium	36.99	0.81
		Medium-broad	36.02	1.26
		Broad	35.17	1.24
Buccal corridor symmetry	.668	Symmetry	36.15	0.59
		Asymmetry	35.30	1.84

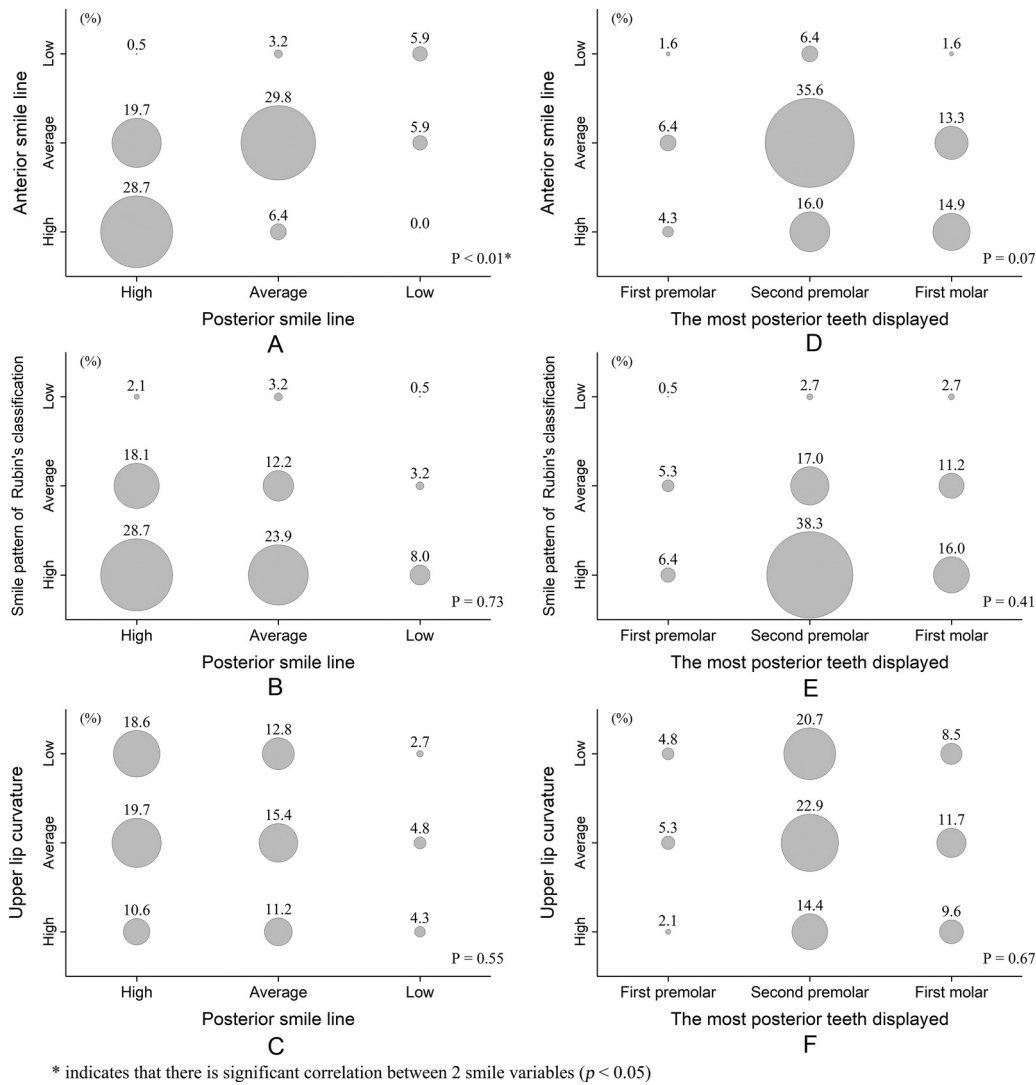
SD, standard deviation.

\* Represents that the visual analog scale (VAS) measurements between subgroups are significantly different ( $P < .05$ ).

The smile line refers to the position of the upper lip, which determines the frame of a smile, in both maxillary anterior and posterior regions. Based on the classification of Tjan et al,<sup>5</sup> many studies validated that high (anterior) smile line (ie, excessive gingival display) was deemed as less attractive by both professionals and laypersons.<sup>8,22</sup> However, the impact of the gingiva and teeth displayed in maxillary posterior region during smiling was neglected.

Limited available evidence was found on the perception of individuals regarding smile aesthetics related to posterior smile characteristics. In this study, nearly 54% female participants and 38% male participants demonstrated a high PSL, which was proven to be less attractive than those with average/low ones. Crawford et al<sup>4</sup> found 0- to 2-mm gingival display at first premolar was considered aesthetically pleasing using computer-altered images. Oliveira et al<sup>8</sup> reported that more attractive smiles reveal a posterior gingival display of 1.44 mm and 1.75 mm for females and males, respectively. Moreover, several studies pointed that smiles with gingival display of 2 to 4 mm or 4 to 6 mm were deemed aesthetically acceptable.<sup>11,13</sup> However, this was not the case in this study. Natural smile images, rather than manipulated ones, were analysed and rated by different evaluators, which may explain this discrepancy.

As a matter of fact, all the participants recruited in this study displayed no less than the first premolar and its surrounding gingiva was visible in most of the cases. Similar to



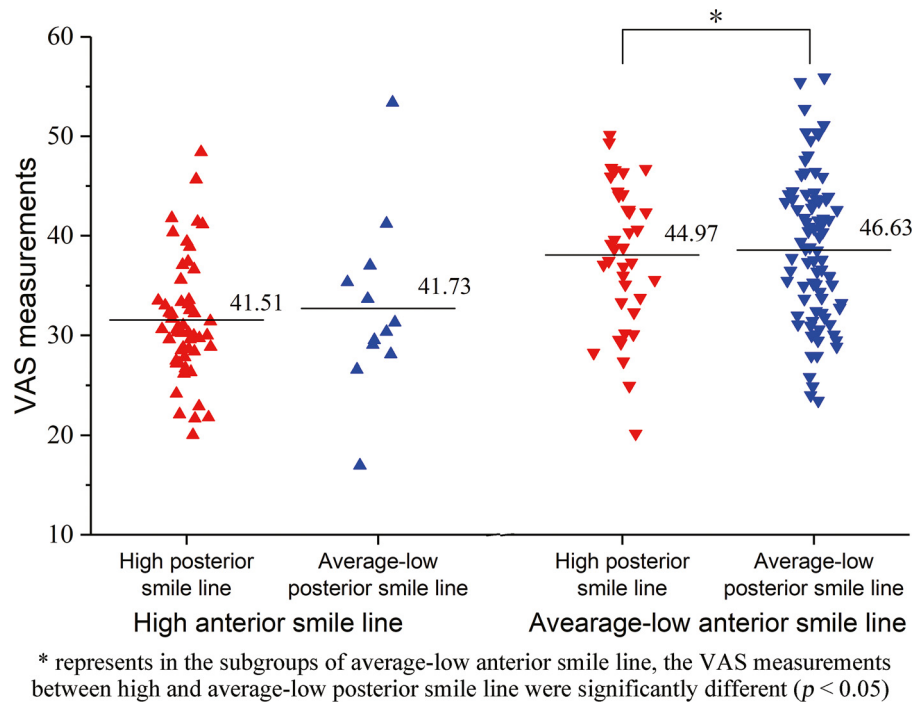
**Fig. 3 – Relationship between posterior and anterior smile variables. A, B, C, Correlations between posterior smile line and anterior smile line, smile pattern of Rubin's classification, and upper lip curvature. D, E, F, Correlations between the most posterior teeth displayed and anterior smile variables.**

previous studies,<sup>6,9,23</sup> the maxillary second premolars were the most commonly MPTD and the most widely accepted by laypersons. Pham and Nguyen<sup>20</sup> found that 78.5% of attractive smile images had posterior teeth displayed up to the second premolar. Chen et al also reported that 56% of celebrities revealed teeth to the second premolar. However, the current study found visible teeth up to second premolars the most attractive, but denied the relation between smile line and MPTD. In summary, display of both gingiva and teeth in the posterior region may compromise the smile aesthetics precepted by laypersons.

After first described by Frush and Fisher,<sup>15</sup> researchers persisted in finding the aesthetically proper size of the buccal corridors perceived by laypersons and orthodontists.<sup>17,18,24,25</sup> However, whether buccal corridor could be noticed by laypersons and influence their judgement of smile attractiveness were not investigated in depth. In the present study, 62.8% of the participants smile with a medium buccal corridor,

consistent with Chen et al.<sup>9</sup> However, the VAS scores indicated that the buccal corridor may be not noticed in an authentic smile by laypersons who had no prior knowledge of its existence. In contrast, some previous studies draw different conclusions that the size of buccal corridor has an impact on smile attractiveness, from 10%<sup>18</sup> to 15%.<sup>17</sup> These different results between this current study and previous ones may involve the various biases amongst participant groups with different ethnic and racial backgrounds.<sup>16,26</sup>

As a result, the components of posterior region including teeth, gingiva, and space may have a different impact on smile aesthetics through the evaluation of laypeople. The smile line and teeth displayed in the posterior region affect smile attractiveness according to current study, which is consistent with previous reported results of both authentic and artificial images.<sup>4,9,20</sup> However, the imperfections in the buccal corridor seems minor when evaluated by laypeople, which is in marked contrast to previous studies conducted on



**Fig. 4 – VAS measurements of posterior smile line in different subgroups of anterior smile line.**

artificial images.<sup>16-19</sup> Further studies are needed to investigate this discrepancy in authentic and artificial images assessed by laypeople.

The diversity between PSL and ASL during smiling has been reported in some previous studies,<sup>8,27</sup> which was validated again in this study. Nearly one-third of the participants with an average ASL displayed a high PSL, which implied that considering the position of the upper lip in only the anterior region is incomplete in pretreatment examination, diagnosis, and relevant clinical decision-making. Congenitally developed smile characteristics, including SP and smile arc, were intended to be related with smile height of posterior region.<sup>12</sup> However, the correlations between PSL and ULC, and also PSL and SP using Rubin's classification, were denied in our study.

Limitations of the present study should be considered. On one hand, the sample may not represent the general youth population in Chinese Han population, and the numbers of female and male participants were not balanced, implying a possibility of selection bias. On the other hand, qualitative analysis of smile variables and these contributions to smile aesthetics in maxillary posterior region were performed, rather than quantitative analysis. Future study is needed to obtain the quantitative standard norms of gingiva and teeth displayed to instruct treatment decision-making in clinical practice.

## Conclusions

Within the limitations of the present study, it was possible to draw the following conclusions:

1. The maxillary first premolars are almost always displayed during smiling, sometimes even more posterior teeth,

which should be taken into consideration when smile aesthetics are involved.

2. Smile variables, including PSL and the MPTD, have an impact on smile aesthetics.
3. The smile attractiveness in natural smiles is not affected by buccal corridor space or ratio confirmed by laypersons.
4. High PSL exerts an adverse effect on smile attractiveness. In these cases, participants with an average or low ASL may be misdiagnosed with a harmonious smile.

## Author contributions

Ning Wei and Cui Wang are co-first authors and contributed equally to this article.

## Funding

This study was funded by the National Natural Science Foundations of China, Beijing, China (grant number 61876005).

## Conflict of interest

None disclosed.

## Acknowledgments

The authors thank Dr Joelle Moussi for editorial assistance with the manuscript.

## REFERENCES

1. Van der Geld P, Oosterveld P, Van Heck G, et al. Smile attractiveness. Self-perception and influence on personality. *Angle Orthod* 2007;77:759–65.
2. Lukez A, Pavlic A, Trinajstic Zrinski M, et al. The unique contribution of elements of smile aesthetics to psychosocial well-being. *J Oral Rehabil* 2015;42:275–81.
3. Lajnert V, Kovacevic Pavicic D, Pavlic A, et al. Smile Aesthetics Satisfaction Scale: development and validation of a new brief five-item measure of satisfaction with smile aesthetics in adults and the elderly. *Int Dent J* 2018;68:162–70.
4. Crawford RW, Tredwin C, Moles D, et al. Smile esthetics: the influence of posterior maxillary gingival margin position. *J Prosthodont* 2012;21:270–8.
5. Tjan AHL, Miller GD, The JGP. Some esthetic factors in a smile. *J Prosthet Dent* 1984;51:24–8.
6. Sharma N, Rosenstiel SF, Fields HW, et al. Smile characterization by U.S. white, U.S. Asian Indian, and Indian populations. *J Prosthet Dent* 2012;107:327–35.
7. Liang LZ, Hu WJ, Zhang YL, et al. Analysis of dynamic smile and upper lip curvature in young Chinese. *Int J Oral Sci* 2013;5:49–53.
8. Oliveira PLE, Motta A, Pithon M, et al. Details of pleasing smiles. *Int J Esthet Dent* 2018;13:494–514.
9. Chen YH, Cheng YL, Cheng H, et al. Comparison of smile esthetics among celebrities, dentists, and dental students in a Han Chinese population. *J Prosthet Dent* 2020;123:845–9.
10. Parrini S, Rossini G, Castroflorio T, et al. Laypeople's perceptions of frontal smile esthetics: a systematic review. *Am J Orthod Dentofacial Orthop* 2016;150:740–50.
11. Rodriguez-Martinez A, Vicente-Hernandez A, Bravo-Gonzalez LA. Effect of posterior gingival smile on the perception of smile esthetics. *Med Oral Patol Oral Cir Bucal* 2014;19:e82–7.
12. Maulik C, Nanda R. Dynamic smile analysis in young adults. *Am J Orthod Dentofacial Orthop* 2007;132:307–15.
13. Mamillapalli PK, Sesham VM, Neela PK, et al. Influence of gingival display on smile esthetics. *Indian J Dent Adv* 2016;8:232–5.
14. Gill DS, Naini FB, Tredwin CJ. Smile aesthetics. *Dent Update* 2007;34(152–4):157–8.
15. Frush JP, Fisher RD. The dynesthetic interpretation of the denotogenic concept. *J Prosthet Dent* 1958;8:558–81.
16. Moore T, Southard KA, Casco JS, et al. Buccal corridors and smile esthetics. *Am J Orthod Dentofacial Orthop* 2005;127:208–13.
17. Ioi H, Kang S, Shimomura T, et al. Effects of buccal corridors on smile esthetics in Japanese and Korean orthodontists and orthodontic patients. *Am J Orthod Dentofacial Orthop* 2012;142:459–65.
18. Nimbalkar S, Oh YY, Mok RY, et al. Smile attractiveness related to buccal corridor space in 3 different facial types: a perception of 3 ethnic groups of Malaysians. *J Prosthet Dent* 2018;120:252–6.
19. McLeod C, Fields HW, Hechter F, et al. Esthetics and smile characteristics evaluated by laypersons. *Angle Orthod* 2011;81:198–205.
20. Pham TAV, Nguyen PA. Morphological features of smile attractiveness and related factors influence perception and gingival aesthetic parameters. *Int Dent J* 2021 S0020-6539 (0021)00039-00033.
21. Wang C, Hu WJ, Liang LZ, et al. Esthetics and smile-related characteristics assessed by laypersons. *J Esthet Restor Dent* 2018;30:136–45.
22. Pinzan-Vercelino CRM, Costa ACS, Ferreira MC, et al. Comparison of gingival display in smile attractiveness among restorative dentists, orthodontists, prosthodontists, periodontists, and laypeople. *J Prosthet Dent* 2020;123:314–21.
23. Koidou VP, Chatzopoulos GS, Rosenstiel SF. Quantification of facial and smile esthetics. *J Prosthet Dent* 2017;119:270–7.
24. Springer NC, Chang C, Fields HW, et al. Smile esthetics from the layperson's perspective. *Am J Orthod Dentofacial Orthop* 2011;139:e91–e101.
25. Moura W, Bellini-Pereira SA, Cotrin-Silva PP, et al. Buccal corridor changes for improvement of smile esthetics. *J Clin Orthod* 2020;54:111–20.
26. Krishnan V, Daniel ST, Lazar D, et al. Characterization of posed smile by using visual analog scale, smile arc, buccal corridor measures, and modified smile index. *Am J Orthod Dentofacial Orthop* 2008;133:515–23.
27. Kapagiannidis D, Kontonasaki E, Bikos P, et al. Teeth and gingival display in the premolar area during smiling in relation to gender and age. *J Oral Rehabil* 2005;32:830–7.