

Crack Formation Following Root-End Preparation in Roots with the Butterfly Effect

 Assil A. RUSSELL,  Nicholas P. CHANDLER,  Lara T. FRIEDLANDER

ABSTRACT

Objective: To investigate apical cracks in roots that exhibit the butterfly effect and that have undergone apical resection and ultrasonic root-end cavity preparation. The effect of the obturation material was also studied.

Methods: Forty extracted single-rooted teeth were decoronated at the cemento-enamel junction. Roots were viewed under a light microscope and coded according to the presence or absence of the butterfly effect. Canals were prepared using ProTaper Next instruments to size X3 and assigned to two obturation groups (gutta-percha and AH Plus, and ProRoot MTA alone). Each contained twenty roots (10 with the butterfly effect and 10 without the butterfly effect). Roots were resected perpendicular to their long axis, 3 mm from the apex, and cavities were cut using ultrasonic retrotips. Resin replicas were used for crack imaging from scanning electron micrographs. Statistical analyses were performed using Stata 13.1 (StataCorp, College Station, TX, USA).

Results: Cracks occurred more frequently in teeth with the butterfly effect (80%), with this difference being significant ($P=0.001$). Most cracks (73%) ran buccolingually. Teeth obturated with MTA developed fewer cracks compared to those obturated with GP and sealer.

Conclusion: Root-ends with the butterfly effect had a significantly higher number of buccolingual cracks following resection and ultrasonic root-end preparation. This might explain the development of some vertical root fractures, which usually run buccolingually. Canal obturation with MTA may be protective.

Keywords: Apical cracks, vertical root fracture, root-end resection

HIGHLIGHTS

- Roots with the butterfly effect develop significantly more cracks after apical surgery compared to roots without the effect.
- Cracks observed ran predominantly in a buccolingual direction, which may explain the prevalence of vertical root fractures in this direction.
- ProRoot MTA may have a protective effect against crack formation during apical surgery.

INTRODUCTION

The “Butterfly Effect” is an optical phenomenon that occurs in some cross-sections of root canals (1). It has been attributed to dentinal tubular sclerosis that differs in the mesiodistal and buccolingual directions. This produces a characteristic butterfly shape in transverse sections of the roots, caused by different shades of dentine (1). The presence of sclerotic dentine causes light to refract and scatter (2). A decrease in the number of dentinal tubules results in greater light transmission to give a translucent appearance (3). Root sections with the butterfly effect have been reported to have a lower density of dentinal tubules mesiodistally, corresponding to the wings of the butterfly. This effect has been observed in teeth from all age groups and at all levels of the roots (4). Roots with the effect have greater penetration of sealers and MTA buccolingually (5). This is thought to enhance entombment of bacteria, which could lead to improved treatment outcomes (5, 6).

The use of ultrasonic retrotips for root-end preparation can lead to increased formation of cracks in dentine (7, 8, 9). Cracks could promote microleakage and may even propagate to form vertical root fractures (VRF) (10). Most VRFs occur in root-filled teeth, and they usually run in the buccolingual direction (11). It has been suggested that teeth with the butterfly effect are more prone to developing cracks in this direction because of their significantly higher dentine hardness mesiodistally (12).

Please cite this article as: Russell AA, Chandler NP, Friedlander LT. Crack formation following rootend preparation in roots with the butterfly effect. *Eur Endod J* 2018; 2: 107-12

From the Department of Endodontics (A.A.R. ✉ assilrussell@yahoo.com) Sir John Walsh Research Institute, Faculty of Dentistry, University of Otago, Dunedin, New Zealand; Department of Oral Rehabilitation, (N.P.C., L.T.F.), Sir John Walsh Research Institute, Faculty of Dentistry, University of Otago, Dunedin, New Zealand

Received 15 April 2018, last revision received 18 June 2018, accepted 16 June 2018

Published online: 19 July 2018
DOI 10.14744/ej.2018.47965

In recent years, numerous canal obturation materials have become available, with some claiming to have superior properties, such as the ability to strengthen teeth and minimize VRF. Roots filled with MTA demonstrate a higher resistance to VRF than those filled with gutta-percha (GP) and a sealer (13). Research on crack formation in teeth with the butterfly effect is lacking, and its potential clinical relevance warrants investigation. The aim of this study was to investigate apical crack formation following root-end resection and preparation in teeth with and without the butterfly effect and to determine whether this is influenced by the obturation material. It was hypothesized that teeth with the effect would develop more cracks buccolingually and that the obturation material would not be a contributing factor.

MATERIALS AND METHODS

A professional biostatistician was consulted and reviewed the study design. Power calculations were carried out to determine an appropriate sample size, which featured 80% power to detect differences. Ethical approval was granted from the University of Otago, Dunedin, New Zealand (reference H15/077), to collect 40 permanent, single-rooted maxillary human teeth of similar shape and size. Teeth with root resorption, immature apices, fracture, or a root filling were rejected. Teeth were washed and stored in phosphate buffered saline (PBS, pH 7.4) until required. Teeth were decoronated at the cemento-enamel junction with a diamond bur under constant water irrigation. Roots were viewed under a light microscope (EHT; Olympus, Tokyo, Japan) at 10× magnification and coded as “B” butterfly

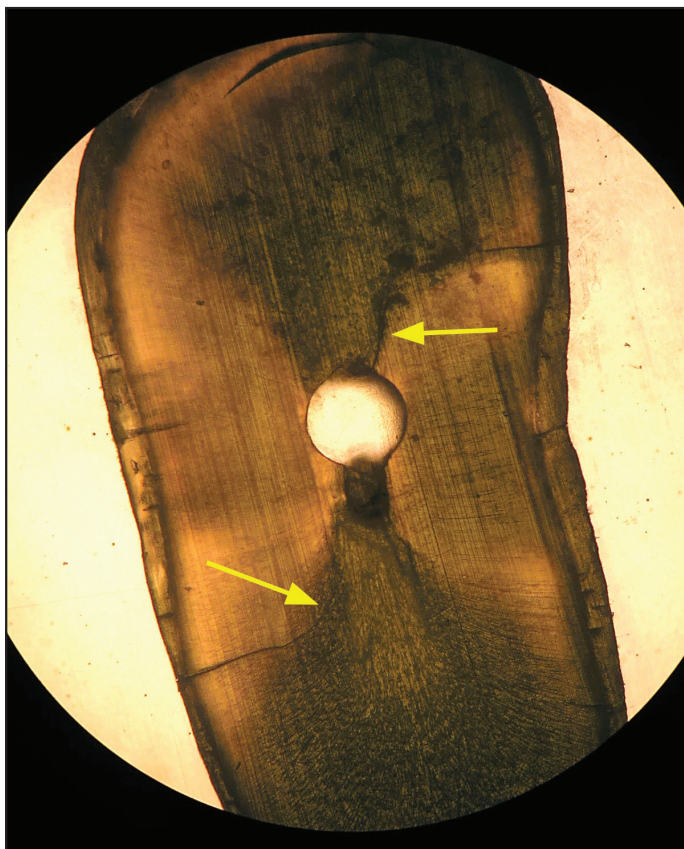


Figure 1. Root section (10×) under light microscope showing the butterfly effect. Arrows indicate complete buccal and lingual cracks

or “NB” non-butterfly on the basis of the presence or absence of the effect (Fig. 1).

The working length of the roots was visually determined by subtracting 1 mm from the point at which a size 10-K file (Dentsply Tulsa Dental, Tulsa, OK, USA) was seen at the major apical foramen. Canal orifices were flared with X-Gates files (Dentsply Tulsa Dental, Tulsa, OK, USA), and canals were prepared using ProTaper Next (Dentsply Maillefer, Ballaigues, Switzerland) instruments to size X3. Irrigation and recapitulation with 5.25% sodium hypochlorite was carried out during canal preparation, and apical patency was maintained with a size 10-K file. Prior to obturation, the canals were irrigated with 5 mL of EDTA (EDTA 15%; Ultradent, South Jordan, UT, USA) solution for 2 min and then 5 mL of NaOCl for another 2 min for removing the organic material and cutting debris. Canals were finally rinsed with 0.9% sterile saline and dried with paper points. Roots were randomly assigned to two obturation groups; GP with AH Plus sealer (Dentsply DeTrey, Konstanz, Germany) and ProRoot MTA (Dentsply Tulsa Dental, Tulsa, OK, USA). Each group comprised 20 roots (10 B and 10 NB).

The sealer was placed in the canals using a size 15-K file at the working length with a counter-clockwise motion. Obturation was performed with single ProTaper Next X3 GP cones. Excess GP was removed with a heated instrument and vertically condensed. MTA was placed in the other group of canals using the Micro Apical Placement System (Dentsply Tulsa Dental) and condensed using Buchanan pluggers (Kerr, Romulus, MI, USA). Filled roots were stored in 100% humidity at 37°C for 2 weeks to allow complete setting of the materials.

Roots were embedded in acrylic resin (Vertex™ Castapress, Vertex-Dental, Zeist, The Netherlands) in plastic cuvettes (LP Italiana SpA, Milan, Italy) such that the apical third extended beyond the cuvette to allow access for resection. A silicone stent was made to simulate a bony crypt and mimic a limited degree of visual and surgical access (Fig. 2). All preparations were done by a single operator using a dental operating microscope (DOM; OPMI pico, Carl Zeiss Ltd, Oberkochen, Germany) at 6× magnification within the crypt simulator. Roots were resected perpendicular to their long axis, 3 mm from the apex, using a high-speed tungsten carbide surgical bur (H162, Komet, Gebr. Brasseler, Lemgo, Germany) under copious water irrigation. Root-ends were polished with an ultra-fine 30-fluted composite finishing bur (H135UF, Komet). They were then inspected for cracks using DOM at 10× magnification.

Three-millimeter-deep root-end cavities were cut using ultrasonic retrotips (ProUltra No. 2, Dentsply) powered by a Satelec P5 Newtron™ ultrasonic unit (Acteon, Merignac, France) on a power setting of 7, according to the manufacturer's recommendation, and with continuous water spray. Each retrotip was used a maximum of 10 times. Roots were re-inspected using DOM at 10×.

Impressions of the resected root-ends and root-end cavities were taken using a light-bodied polyvinyl siloxane (Exafast, GC Corporation, Tokyo, Japan). Replicas were poured using Araldite epoxy resin (Selleys Pty Ltd, Padstow, NSW, Australia).



Figure 2. Simulated bony crypt used for resection and root-end preparation

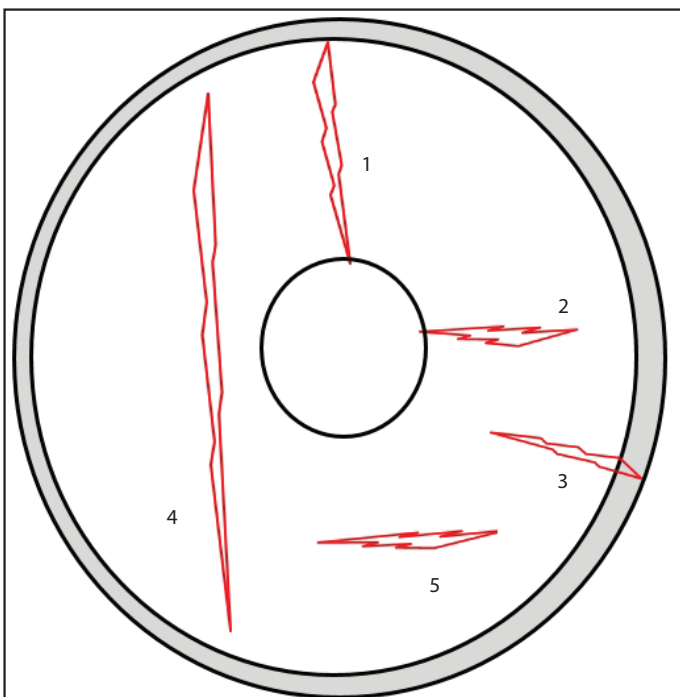


Figure 3. Crack classification following ultrasonic preparation (modified from Layton et al. 1996)

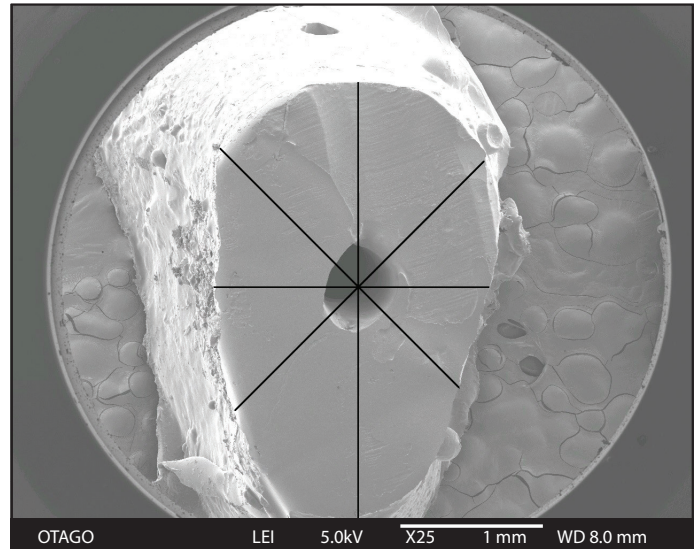


Figure 4. SEM image (25×) of a resin replica of a root end showing assessment grid

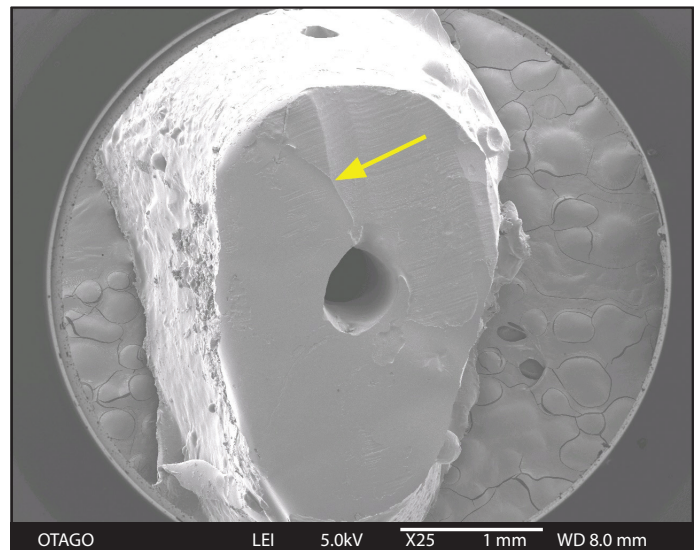


Figure 5. SEM image (25×) of a resin replica of a root end showing a buccal crack (arrow)

They were left to cure at room temperature for 48 h and used for scanning electron microscope (SEM) analysis of cracks (JSM 6700F, JEOL Ltd, Tokyo, Japan).

Bird's eye-view micrographs (25×) of all roots were assessed by an examiner. Ten of the micrographs were further assessed by two calibrated and independent specialist endodontists. All three assessors were unaware about which root end condition was under consideration. Cracks were recorded according to a modified version of the classification provided by Layton et al. 1996 (9) (Fig. 3). A superimposed grid was used to standardize crack direction records (Fig. 4). Observers viewed the images on their own computers following familiarization using example micrographs.

Statistical analysis

A chi-squared test was used with an alpha value of 0.05 to analyze data, and Kappa tests were performed to determine

TABLE 1. Presence of cracks in resected and prepared root-ends (data from AR)

Tooth type	Obturation group	Detection method & number of teeth with cracks		
		Resected root-ends (operating microscope x10)	Resected, prepared root-ends (operating microscope x10)	Replicas of resected, prepared root-ends (SEM x25)
Butterfly (n=20)	AH Plus & GP (n=10)	0	8*	10
	MTA (n=10)	0	5*	6
Non butterfly (n=20)	AH Plus & GP (n=10)	0	2	2
	MTA (n=10)	0	2	2

*Teeth had no detectable cracks under an operating microscope, but cracks were seen on the SEM image of the resin replica

TABLE 2. Crack type and direction in replicas of resected and prepared root-ends (data from AR)

		Number of cracks
Direction	Bucco-lingual	16
	Mesio-distal	6
	TOTAL	22
Crack Classification	Complete canal	9
	Incomplete canal	
	Intradentine	5
	Cemental	1
	TOTAL	22

*Total number of cracks exceeds the number of teeth as some roots developed multiple cracks

interexaminer reliability. Statistical analyses were performed with Stata 13.1 (StataCorp, College Station, TX, USA).

RESULTS

An example of apical cracks in a tooth with the butterfly effect is shown in Fig. 5, and SEM results appear in Tables 1 and 2. None of the teeth developed cracks during root-end resection, but half of them developed cracks following ultrasonic preparation. Cracks occurred significantly more often in teeth with the butterfly effect (80%) than in those without the effect (20%) ($P=0.001$). Majority cracks ran in the buccolingual direction (73%) compared with that in the mesiodistal direction (27%). Complete and incomplete canal cracks were more common (41% and 32%, respectively) than intradentine and cemental cracks (22% and 5%, respectively). Teeth obturated with ProRoot MTA developed fewer cracks (40%) than those obturated with GP and AH Plus (60%), but this finding did not reach statistical significance ($P=0.206$). Agreement between the three examiners was moderate ($Kappa=0.524$). Two examiners agreed very well with each other ($Kappa=0.783$).

DISCUSSION

In this study, it has been determined that the presence of the butterfly effect is a risk factor for the formation of cracks during ultrasonic preparation of root-end cavities. Ultrasonic instruments are used because they achieve ideal cavity designs during root-end preparations, minimizing the need for bevels (14). Because of their size, the cutting tips are easily placed into the canal and oriented down the long axis of the root. Ultrasonic tips are able to produce well-defined conservative preparations, 3 mm into the root, that are parallel to the axial inclination and conform to the root canal anatomy (15). However, these instruments have some limitations. Studies have highlighted an increased formation of cracks in radicular dentine (7, 8). This was first noted as an incidental finding in the study by Saunders et al. (7). Their methodology dehydrated the material prior to evaluation of cracks; therefore, artifacts could not be eliminated (7).

Preparation of teeth for SEM requires extensive dehydration, which is associated with artifactual cracks in the dentine (16) and shrinkage of filling materials (17). To overcome such limitations, dimensionally stable replicas of roots are used (16). The replicas are formed using polyvinyl siloxane impressions poured with epoxy resin (8, 18). These are accurate and resistant to damaging SEM preparation processes (8, 16, 18).

Another confounder is the ultrasonic power setting. Layton et al. investigated crack formation after root resection and root-end preparation using different power settings (9). They reported significantly more canal cracks after root-end preparations than after root resection and found that cracking occurred significantly more often in preparations done with high power. Another study on power settings reported similar results (19). However, an in vitro study found that lowering the power setting produced a greater number of cracks (20). In the present study, the power setting used was that recommended by the manufacturer and was kept constant for all roots.

Crack class	Description
1. Complete canal	Crack emerges from the canal space and extends to the outer root surface.
2. Incomplete canal	Crack emerges from the canal space and extends partially into the radicular dentine but ends short of the external root surface.
3. Cemental	Crack radiating from the cemental surface to the cementodentinal junction and into the dentine.
4. Intradentine BL	Crack confined to the dentine and runs in a buccolingual direction, mesial or distal to the canal.
5. Intradentine MD	Crack confined to the dentine and runs in a mesiodistal direction, either buccal or lingual to the canal.

Teeth of known patient age (25–40 years) were used. Age was unlikely to be a confounding factor as teeth of all age groups have been reported to exhibit the butterfly effect (4). A possible limitation of the present study is that it is unknown if crack formation is the same in vivo where a periodontal ligament allows physiological movement. Cutting was performed in hand-held cuvettes. A recent in vivo study reported that ultrasonic preparation is safe for intact teeth but can promote propagation of existing defects (21). The presence of natural periradicular tissues (periodontium and bone) may prevent cracking in teeth undergoing orthograde root canal instrumentation (21). However, teeth requiring apical surgery are often associated with periapical bone resorption.

It is well documented that majority VRFs occur in root-filled teeth and that they usually run in the buccolingual direction (11, 22). Such fractures can be devastating for patients who have often invested time and finances, only to have the tooth extracted. Cracks following apical surgery have also been reported to run predominantly in the buccolingual direction (23). Studies exploring why cracks develop in this direction are limited. Research has suggested that teeth with the butterfly effect are more prone to developing cracks in the buccolingual direction because of their significantly higher dentine hardness mesiodistally (12). The present investigation demonstrates the high number of buccolingual defects that develop in teeth with the butterfly effect following ultrasonic root-end preparation. This suggests that these roots are more prone to developing VRFs in the buccolingual direction during or after apical surgery. It is, therefore, prudent for clinicians to examine root-ends during surgery to try to identify the presence of the butterfly effect.

Cracks are difficult to diagnose in a surgical situation; in this study, three cracks in roots with the butterfly effect were not detected using DOM but were seen later using SEM. The accuracy of crack detection improves with increasing magnification; however, even at 35× magnification, sensitivity and specificity is limited (24). Refraction of light on sclerosed dentin and the presence of translucent wings of the butterfly may explain the increased difficulty in crack detection. Use of an endoscope (25), transillumination with an LED diagnostic probe (21), and staining of the root-end with dyes, such as methylene blue, may help in detecting cracks (25).

The present study determined that crack detection from SEM images can be challenging. Two examiners agreed very well with each other ($Kappa=0.783$) and the other agreed only moderately ($Kappa=0.546$). This difference highlights difficulties in obtaining an accurate diagnosis on cracks, even under ideal conditions of high magnification using a computer screen rather than in a surgical site. This finding is in accordance with previous studies that have reported that crack detection can be difficult and subjective regardless of the method used (24).

Orthograde obturation of the apical canal space with MTA should be considered when future apical surgery is anticipated. Studies have shown that root-end resection does not significantly affect the sealing ability of MTA when at least 3 mm of the material remains (26, 27). This is advantageous because canal obturation with MTA removes the need to use

ultrasonic for preparing a root-end cavity. This, in turn, may reduce the risk of crack formation in the resected root-end. However, if after resection, MTA appears poorly condensed or in retreatment cases, GP cannot be completely cleared from the canal wall, ultrasonic root-end preparation and fresh MTA placement is recommended (28).

The bioactivity of MTA has been attributed to its setting reaction, which produces calcium hydroxide and calcium silicate hydrate (29). A SEM study reported that MTA used in obturation of root canals can entomb bacteria within dentinal tubules by an intratubular mineralization effect (30). Over time, MTA induces hydroxyapatite crystalline growth inside the dentinal tubules (30). This property of MTA is favourable and potentially promotes healing by creating an environment that is inhospitable to microbial growth. The mineralization effect within the tubules may also strengthen roots and protect against crack formation. The present study supports this suggestion. Although not statistically significant, fewer cracks were observed in roots obturated with ProRoot MTA following resection and cavity preparation, regardless of the presence or absence of the butterfly effect. Further research into the possible protective effect of MTA canal obturation against VRF formation is warranted; its use as a root-end restorative material may also have a protective effect.

CONCLUSION

Roots with the butterfly effect featured significantly more buccolingual cracks following root resection and ultrasonic root-end preparation. This may explain the high prevalence of VRFs that run buccolingually and that may be promoted by cutting a root-end cavity. Obturation of the root canal with ProRoot MTA potentially protects against crack formation during apical surgery.

Disclosures

This research article was written using the author's published thesis "Butterfly Effect: An investigation of sealer penetration, adaptation and apical crack formation in filled root canals" (DCLinDent thesis). Dunedin, New Zealand: Otago University; 2017.

Grant information: This research was supported by a University of Otago Fuller Scholarship. The authors deny any conflict of interest related to this study.

Acknowledgments: We wish to thank Miss Liz Girvan of the Otago Centre for Electron Microscopy and Mr Andrew Gray, biostatistician of the Department of Social and Preventive Medicine, University of Otago, for their time, guidance and knowledge.

Conflict of interest: No conflict of interest was declared by the authors.

Ethics Committee Approval: Ethical approval was granted from the University of Otago, Dunedin, New Zealand (reference H15/077).

Peer-review: Externally peer-reviewed.

Financial Disclosure: None declared.

Authorship contributions: Concept – A.A.R., N.P.C., L.T.F.; Design – A.A.R., N.P.C., L.T.F.; Supervision – A.A.R., N.P.C., L.T.F.; Materials – A.A.R., N.P.C., L.T.F.; Data collection &/or processing – A.A.R., N.P.C., L.T.F.; Analysis and/or interpretation – A.A.R., N.P.C., L.T.F.; Literature search – A.A.R., N.P.C., L.T.F.; Writing – A.A.R., N.P.C., L.T.F.; Critical Review – A.A.R., N.P.C., L.T.F.

REFERENCES

1. Beust TB. Reactions of the dentinal fibril to external irritation. *J Am Dent Assoc* 1931; 18:1060-73.
2. Vasiliadis L, Stavrianos C, Dagkalis P. Translucent root dentine in relation to increasing age: review of literature. *Res J Biol Sci* 2011; 6:292-5.
3. Van Huysen G. The microstructure of normal and sclerosed dentine. *J Prosthet Dent* 1960; 10:976-82.
4. Russell AA, Chandler NP, Hauman C, Siddiqui AY, Tompkins GR. The butterfly effect: an investigation of sectioned roots. *J Endod* 2013; 39(2):208-10.
5. Russell AA, Chandler NP, Friedlander L. Sealer penetration and adaptation in root canals with the butterfly effect. *Aust Endod J* 2017; Oct 16. doi:10.1111/aej.12238. [Epub ahead of print]
6. Russell AA. The Butterfly Effect: An investigation of sealer penetration, adaptation and apical crack formation in filled root canals (DClinDent thesis). Dunedin, New Zealand:University of Otago; 2017.
7. Saunders WP, Saunders EM, Gutmann JL. Ultrasonic root-end preparation, Part 2. Microleakage of EBA root-end fillings. *Int Endod J* 1994; 27(6):325-9.
8. Abedi HR, Van Mierlo BL, Wilder-Smith P, Torabinejad M. Effects of ultrasonic root-end cavity preparation on the root apex. *Oral Surg Oral Med Oral Pathol Oral Radiol Endod* 1995; 80(2):207-13.
9. Layton CA, Marshall JG, Morgan LA, Baumgartner JC. Evaluation of cracks associated with ultrasonic root-end preparation. *J Endod* 1996; 22(4):157-60.
10. De Bruyne MA, De Moor RJ. Influence of cracks on leakage and obturation efficiency of root-end filling materials after ultrasonic preparation: an in vitro evaluation. *Quintessence Int* 2008; 39(8):685-92.
11. Russell AA, Chandler NP, Friedlander LT. Vertical root fractures in root canal-treated teeth. *ENDO* 2017; 11(3):173-82.
12. Russell AA, Chris He LH, Chandler NP. Investigation of dentin hardness in roots exhibiting the butterfly effect. *J Endod* 2014; 40(6):842-4.
13. EL-Ma'aaita AM, Qualtrough AJ, Watts DC. Resistance to vertical fracture of MTA-filled roots. *Dent Traumatol* 2014; 30(1):36-42.
14. Carr G. Advanced techniques and visual enhancement for endodontic surgery. *Endod Rep* 1992; 7(1):6-9.
15. Carr GB. Ultrasonic root end preparation. *Dent Clin North Am* 1997; 41(3):541-54.
16. Barnes IE. Replica models for the scanning electron microscope. A new impression technique. *Br Dent J* 1972; 133(8):337-42.
17. Torabinejad M, Smith PW, Kettering JD, Pitt Ford TR. Comparative investigation of marginal adaptation of mineral trioxide aggregate and other commonly used root-end filling materials. *J Endod* 1995; 21(6):295-9.
18. Aiach D, Malone WF, Sandrik J. Dimensional accuracy of epoxy resins and their compatibility with impression materials. *J Prosthet Dent* 1984; 52(4):500-4.
19. Beling KL, Marshall JG, Morgan LA, Baumgartner JC. Evaluation for cracks associated with ultrasonic root-end preparation of gutta-percha filled canals. *J Endod* 1997; 23(5):323-6.
20. De Bruyne MA, De Moor RJ. SEM analysis of the integrity of resected root apices of cadaver and extracted teeth after ultrasonic root-end preparation at different intensities. *Int Endod J* 2005; 38(5):310-9.
21. Tawil PZ. Periapical Microsurgery: Can Ultrasonic Root-end Preparations Clinically Create or Propagate Dentinal Defects? *J Endod* 2016; 42(10):1472-5.
22. von Arx T, Bosshardt D. Vertical root fractures of endodontically treated posterior teeth: A histologic analysis with clinical and radiographic correlates. *Swiss Dent J* 2017; 127(1):14-23.
23. von Arx T, Bosshardt D, Bingisser AC, Bornstein MM. Endoscopic evaluation of cut root faces and histologic analysis of removed apices following root resection: A clinical study. *Eur Endod J* 2018; 3(1):18-23.
24. Slaton CC, Loushine RJ, Weller RN, Parker MH, Kimbrough WF, Pashley DH. Identification of resected root-end dentinal cracks: a comparative study of visual magnification. *J Endod* 2003; 29(8):519-22.
25. von Arx T, Steiner RG, Tay FR. Apical surgery: endoscopic findings at the resection level of 168 consecutively treated roots. *Int Endod J* 2011; 44(4):290-302.
26. Andelin WE, Browning DF, Hsu GH, Roland DD, Torabinejad M. Microleakage of resected MTA. *J Endod* 2002; 28(8):573-4.
27. Lamb EL, Loushine RJ, Weller RN, Kimbrough WF, Pashley DH. Effect of root resection on the apical sealing ability of mineral trioxide aggregate. *Oral Surg Oral Med Oral Pathol Oral Radiol Endod* 2003; 95(6):732-5.
28. Hachmeister DR, Schindler WG, Walker WA 3rd, Thomas DD. The sealing ability and retention characteristics of mineral trioxide aggregate in a model of apexification. *J Endod* 2002; 28(5):386-90.
29. Bogen, G, Lawaty I, Chandler N. MTA root canal obturation. In Torabinejad M, editor. *Mineral Trioxide Aggregate: Properties and clinical applications*. 1st ed. Oxford: Wiley Blackwell; 2014. p. 208-49.
30. Yoo JS, Chang SW, Oh SR, Perinpanayagam H, Lim SM, Yoo YJ, et al. Bacterial entombment by intratubular mineralization following orthograde mineral trioxide aggregate obturation: a scanning electron microscopy study. *Int J Oral Sci* 2014; 6(4):227-32.