

Pulsed-wave Doppler ultrasonographical measurements of supra-mammary lymph nodes for diagnosis of bovine mastitis

Ali Rişvanli^{1,2*}, Halef Dogan³, Tarik Safak⁴, Mehmet Akif Kilic⁵, Ibrahim Seker⁶

¹Department of Obstetrics and Gynecology, Faculty of Veterinary Medicine, University of Firat, Elazig, Turkiye; ²Department of Obstetrics and Gynecology, Faculty of Veterinary Medicine, Kyrgyz-Turkish Manas University, Bishkek, Kyrgyzstan; ³Department of Obstetrics and Gynecology, Faculty of Veterinary Medicine, University of Namik Kemal, Tekirdag, Turkiye; ⁴Department of Obstetrics and Gynecology, Faculty of Veterinary Medicine, University of Kastamonu, Kastamonu, Turkiye; ⁵Department of Obstetrics and Gynecology, Faculty of Veterinary Medicine, University of Bingol, Bingol, Turkiye; ⁶Department of Zootechny, Faculty of Veterinary Medicine, University of Firat, Elazig, Turkiye.

Article Info

Article history:

Received: 19 April 2020

Accepted: 03 August 2020

Available online: 15 September 2022

Keywords:

Cow

Doppler

Mastitis

Supra-mammary lymph node

Ultrasonography

Abstract

The aim of this study was to investigate the relationship between mastitis and supra-mammary lymph nodes in lactating cows in terms of Pulsed-wave (PW) Doppler ultrasonographical measurements. A total of 102 head cows in lactation period were divided into three groups. The cows in which all mammary lobes were California mastitis test (CMT)-negative (n = 27) formed the 1st group; those with CMT-positive mammary lobe (n = 43) formed the 2nd group and the cows with clinical mastitis in at least one mammary lobe (n = 32) formed the 3rd group. In PW Doppler ultrasonography, end-diastolic velocity, systolic peak velocity and time-averaged maximum velocity were measured at the most prominent artery of the lymph node. A quantitative scaling was performed by determining the pulsatile index and resistance index scales based on blood flow parameters. There was no statistically significant difference between the study groups in terms of PW Doppler ultrasonographical measurements of supra-mammary lymph nodes. In conclusion, the use of PW Doppler ultrasonographic data of the supra-mammary lymph nodes will not provide useful information about the current condition of mastitis in cows.

© 2022 Urmia University. All rights reserved.

Introduction

Supra-mammary lymph nodes play an important role in the immune system of the udder.^{1,2} Mastitis causes cell proliferation (e.g., fibrous connective tissue growth and lymphocyte infiltration) and leads to inflammatory changes in supra-mammary lymph nodes.² There are previous studies about the usefulness of gray-scale ultrasonography to detect morphological changes in supra-mammary lymph nodes.^{2,3} Ultrasonography has been used for evaluating mammary health due to its advantages including ease of use and being a non-invasive method. Different ultrasonographic techniques may be used for determining intra-mammary situations (e.g., B mod real time, Doppler and M mod). However, there are a limited number of publications regarding the use of Doppler ultrasonography in the examination of supra-

mammary lymph nodes. Five different techniques are used in Doppler ultrasonography including continuous waveform (CW) Doppler, pulsed waveform (PW) Doppler, colour Doppler, power Doppler and spectral Doppler or duplex scanning.

This study was carried out to investigate the relationships of PW Doppler ultrasonographic features of supra-mammary lymph nodes with mastitis in lactating cows.

Materials and Methods

Animals. The animals used in this study were selected from 1,000 head animals brought to the Firat University Animal Hospital (Elazig, Turkiye, 38° 35' 51.55" N, 39° 16' 53.28" E) for examination between 01.05.2018 and 01.09.2018. A total of 102 head cows with a body weight of 450-500 kg between 3 - 5 years of age belonging to various

*Correspondence:

Ali Rişvanli. DVM, PhD

Department of Obstetrics and Gynecology, Faculty of Veterinary Medicine, University of Firat, Elazig, Turkiye | Department of Obstetrics and Gynecology, Faculty of Veterinary Medicine, Kyrgyz-Turkish Manas University, Bishkek, Kyrgyzstan

E-mail: arisvanli@firat.edu.tr



This work is licensed under a Creative Commons Attribution-NonCommercial-ShareAlike 4.0 International (CC BY-NC-SA 4.0) which allows users to read, copy, distribute and make derivative works for non-commercial purposes from the material, as long as the author of the original work is cited properly.

breeds were included in the study. The body condition scores of the animals ranged between 3.00-3.50 points. The supra-mammary lymph node of 28 animals was considered avascular because no vascularization was observed. The study was approved by the local Ethics Committee of the Experimental Animals of Firat University, Elazig, Turkiye (2018/87). The animals included in the study were divided into three groups as follows: Group 1 (n = 27): Consisting of the animals of which all mammary lobes were California mastitis test (CMT)-negative. The supra-mammary lymph nodes of 15 animals were avascular; therefore, the measurement could not be performed. Group 2 (n = 43): Consisting of the animals with at least one CMT-positive mammary lobe (CMT+: n = 20, CMT++: n = 13 and CMT+++ : n = 10). The supra-mammary lymph nodes of 6 animals were avascular; therefore, the measurement could not be performed. Group 3 (n = 32): Clinical mastitis group (acute: n = 5, chronic: n = 21 and subacute: n = 6) consisted of the cows with mastitis at least in one mammary lobe. The supra-mammary lymph nodes of seven animals were avascular; therefore, the measurement could not be performed.

For ultrasonographic examination, the animals were immobilized as far as possible in the labour setting. The animal was adapted to the environment by waiting for about ten min. The region of the lymph nodes in the udder was washed with soap and water. Doppler application was suspended in cases when the animal activity or respiratory rate increased during the examination.⁴ The anatomical position of the supra-mammary lymph node was detected as described by Bradley *et al.*² Under the perineal region of the animals and on the dorsal surface of the udder, the B-mode and colour Doppler modes were activated by a PW command via a 2.50-inch convex probe (Mindray DC - T6 Colour Doppler Ultrasound System; Shenzhen, China). After detecting the supra-mammary lymph node, the insonation angle was set to 60.00° for colour Doppler and PW Doppler examinations.

Pulsed-wave Doppler ultrasonographic examination.

This was performed as described by Rişvanli *et al.*⁵ End

diastolic velocity (EDV), systolic peak velocity (SPV) and time-averaged maximum velocity (TAMV) were measured as Doppler characteristics on the most prominent vessel of the lymph nodes. Numerical scaling was performed by determining the pulsatile index (PI) and resistance index (RI) scales based on the blood flow parameters. To perform these measurements, the most prominent vessel in the lymph node was chosen.

California mastitis test. This test was performed as described by Seker *et al.*⁶ Accordingly, the animals that gave positive results to CMT at least in one mammary lobe were included in the CMT-positive group (measurements were made on the lymph lump of the quarters, which was positive for CMT); while, those that gave a negative result in all mammary lobes were included in the CMT-negative group.

Statistical analysis. The PI, RI, EDV, SPV and TAMV measurements of the most prominent vessels in the lymph nodes were compared between the groups. The effect of the study groups on the PI, RI, EDV, SPV and TAMV values was determined using the one-way analysis of variance (ANOVA) test. For the variables with a significant variance analysis result, the Duncan post-hoc test was used for the multiple group comparisons. The Pearson correlation test was used to determine the correlation coefficients and the statistical significance level between some numerical variables. All statistical analyses were performed using the SPSS (version 22.0; IBM Corp., Armonk, USA).

Results

There was no statistically significant difference between the groups in terms of PW Doppler ultrasonographic measurements of the supra-mammary lymph nodes ($p > 0.05$; Table 1 and Fig. 1). The PI, RI, EDV, SPV and TAMV values of supra-mammary lymph nodes in the udder lobes with clinical mastitis were determined as 1.75 ± 0.22 , 0.17 ± 0.03 , 3.82 ± 0.28 (cm sec⁻¹), 5.57 ± 0.24 (cm sec⁻¹) and 9.07 ± 1.40 (cm sec⁻¹), respectively.

Table 1. Comparison of the pulsed-wave Doppler ultrasono-graphical measurements of the supra-mammary lymph nodes among the groups. Data are presented as mean \pm standard error.

Parameters	CMT-negative (n = 12) *	CMT-positive (n = 37) **	Clinical mastitis (n = 25) ***
PI	1.51 \pm 0.47	1.75 \pm 0.33	1.75 \pm 0.22
RI	0.15 \pm 0.01	0.16 \pm 0.01	0.17 \pm 0.03
EDV (cm sec ⁻¹)	3.50 \pm 0.65	3.33 \pm 0.34	3.82 \pm 0.28
SPV (cm sec ⁻¹)	5.98 \pm 0.32	5.61 \pm 0.31	5.57 \pm 0.24
TAMV (cm sec ⁻¹)	12.60 \pm 2.63	9.23 \pm 1.33	9.07 \pm 1.40

EDV: End diastolic velocity; SPV: Systolic peak velocity; TAMV: Time-averaged maximum velocity; CMT: California mastitis test.

* The supra-mammary lymph nodes of 15 animals were avascular; therefore, the measurement could not be performed. ** The supra-mammary lymph nodes of six animals were avascular; therefore, the measurement could not be performed. *** The supra-mammary lymph nodes of seven animals were avascular; therefore, the measurement could not be performed. No statistical differences were observed in each row ($p > 0.05$).

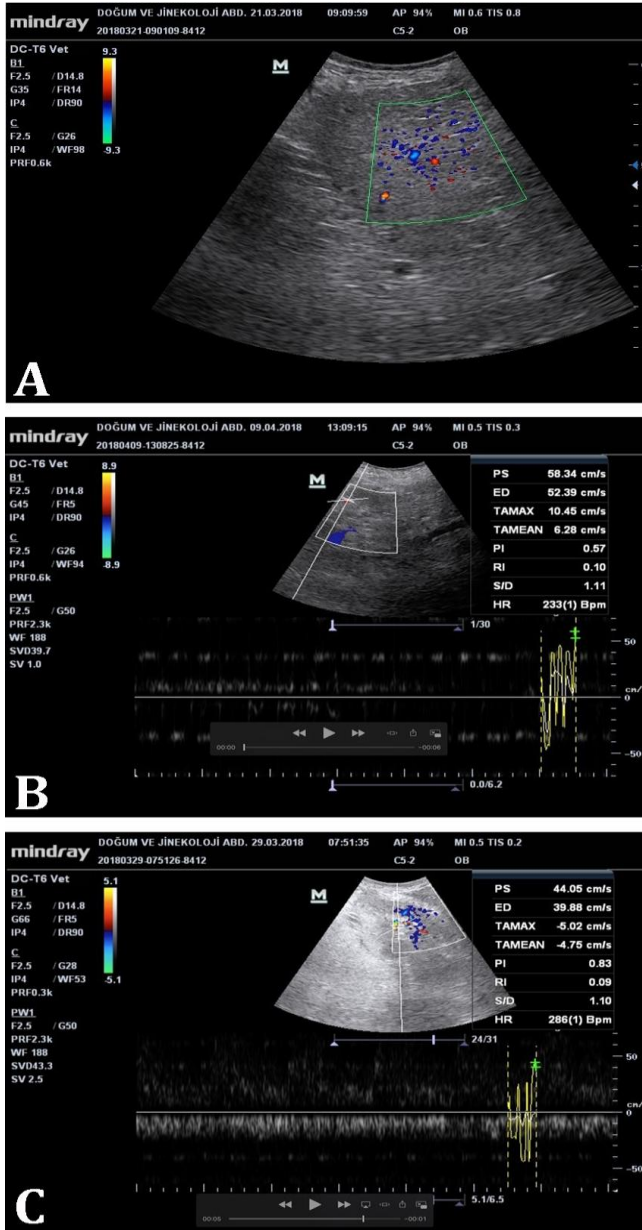


Fig. 1. Pulsed-wave Doppler ultrasonographical image of supra-mammary lymph nodes in **A)** clinical mastitis, **B)** negative California mastitis test (CMT), and **C)** positive CMT.

Discussion

Analysis of the blood flow by Doppler ultrasonography is used in veterinary practice to assess the physiological and pathological conditions of various organs and tissues of animals. However, mostly, the PW Doppler ultrasound method is preferred. In this technique, parameters such as EDV, SPV, TAMV, PI and RI are used for the evaluation of blood flow in organs.⁷⁻⁹ The PW Doppler ultrasonography does not provide sufficient information about the blood supply in small structures such as lymph nodes, ovaries, corpus luteum and tumours.

On the other hand, ultrasonographic examination of the lymph nodes was reported to be highly important in terms of prognosis prediction and the decision for treatment choice during the evaluation of some tumour metastases in dogs, and in line with that colour Doppler and PW Doppler ultrasonography could provide useful information about the intra-nodal vascular distribution, blood flow velocities and vascular resistance in superficial lymph nodes.¹⁰

Studies with colour Doppler ultrasonography in humans have reported high PI values for malignant lymph nodes due to increased peripheral vascular resistance and peripheral vascular obstruction.^{11,12} In general, a high RI value in humans is reported to indicate malignancy;¹³ however, there are also studies claiming the opposite.¹⁴

In conclusion, in this study, it was found that the use of PW Doppler ultrasonographic methods to determine the current condition regarding mastitis in cows during the lactation period are not useful and also these non-invasive methods can provide essential information about the intra-nodal structure of the supra-mammary lymph nodes in healthy cows and those with clinical mastitis.

Acknowledgments

This study was presented as a full text speech at VIII. National & II. International Congress of Turkish Society of Veterinary Gynecology in October 2019, Antalya, Turkey.

Conflict of interest

The authors declare that there is no conflict of interest.

References

- Kimura K, Harp JA, Goff JP, et al. Lymphocytes from one side of the bovine mammary gland migrate to the contra lateral gland and lymph node tissue. *Vet Immunol Immunopathol* 2005; 108(3-4): 409-415.
- Bradley KJ, Bradley AJ, Barr FJ. Ultrasonographic appearance of the superficial supramammary lymph nodes in lactating dairy cattle. *Vet Rec* 2001; 148(16): 497-501.
- Khoramian B, Vajhi A, Ghasemzadeh-Nava H, et al. Ultrasonography of the supramammary lymph nodes for diagnosis of bovine chronic subclinical mastitis. *Iran J Vet Res* 2015; 16(1): 75-77.
- Erdoğan G, Çetin H, Ceylan A, et al. Comparison of foetal growth in singleton and twin pregnancies by B-mode and Doppler ultrasonography in Karya ewes. *Turk J Vet Anim Sci* 2016; 40(5): 616-621.
- Rişvanli A, Doğan H, Saat N, et al. Relationship between pulsed wave Doppler ultrasonographic features of milk veins and CMT scores in Simmental cows. *Ankara Üniv Vet Fak Derg* 2018; 65(1): 69-72.

6. Seker I, Rişvanli A, Yuksel M, et al. Relationship between California Mastitis Test scores and ultrasonographic teat measurements in dairy cows. *Aust Vet J* 2009; 87(12): 480-483.
7. Dziecioł M, Scholbach T, Stańczyk E, et al. Dynamic tissue perfusion measurement in the reproductive organs of the female and male dogs. *Bull Vet Inst Pulawy* 2014; 58(1): 149-155.
8. Starke A, Schmidt S, Haudum A, et al. Evaluation of portal blood flow using transcutaneous and intraoperative Doppler ultrasonography in dairy cows with fatty liver. *J Dairy Sci* 2011; 94(6): 2964-2971.
9. Brozos CN, Pancarci MS, Valencia J, et al. Effect of oxytocin infusion on luteal blood flow and progesterone secretion in dairy cattle. *J Vet Sci* 2012; 13(1): 67-71.
10. Gaschen L, Angelette N, Stout R. Contrast-enhanced harmonic ultrasonography of medial iliac lymph nodes in healthy dogs. *Vet Radiol Ultrasound* 2010; 51(6): 634-637.
11. Na DG, Lim HK, Byun HS, et al. Differential diagnosis of cervical lymphadenopathy: usefulness of color Doppler sonography. *AJR Am J Roentgenol* 1997; 168(5): 1311-1316.
12. Tschammler A, Gunzer U, Reinhart E, et al. The diagnostic assessment of enlarged lymph nodes by qualitative and semiquantitative evaluation of lymph node perfusion with color-coded duplex sonography [German]. *Rofo* 1991; 154(4): 414-418.
13. Yilmaz O, Balta ZD, Tuñçbilek I, et al. Ultrasonographic findings addition for the differentiation of malign and benign lenfadenopatı [Turkish]. *S.D.Ü Sağlık Enstitüsü Dergisi* 2012; 3(1): 1-9.
14. Chang DB, Yuan A, Yu CJ, et al. Differentiation of benign and malignant cervical lymph nodes with color Doppler sonography. *AJR Am J Roentgenol* 1994; 162(4): 965-968.