



Intramedullary compression screw fixation of metacarpal and phalangeal fractures

Marco Guidi
Florian S. Frueh
Inga Besmens
Maurizio Calcagni

- The intramedullary headless compression screw (IMCS) technique represents a reliable alternative to percutaneous Kirschner-wire and plate fixation with minimal complications.
- Transverse fractures of the metacarpal shaft represent a good indication for this technique. Non-comminuted subcapital and short oblique fractures can also be treated with IMCS.
- This technique should not be used in the presence of an open epiphysis, infection and, most of all, in subchondral fractures, because of the lack of purchase for the head of the screw.
- A double screw construct is recommended for comminuted subcapital fractures of the metacarpal to avoid metacarpal shortening. IMCS can even be applied for peri-articular fractures of the proximal third of the phalanx and in some multi-fragmentary proximal and middle phalangeal fractures.
- Usually the intramedullary screws are not removed. The main indications for screw removal are joint protrusion, infection and screw breakage after new fracture.

Keywords: intramedullary headless compression screws; metacarpal fractures; phalangeal fractures

Cite this article: *EFORT Open Rev* 2020;5:624-629.

DOI: 10.1302/2058-5241.5.190068

Introduction

Several devices and techniques are currently used for the treatment of phalangeal and metacarpal fractures.^{1,2} While percutaneous intramedullary Kirschner (K) wires, plate fixation and lag screws exhibit specific advantages and drawbacks, there is still no agreement on the ideal technique to manage these fractures.¹⁻⁴ Complications such as stiffness, flexion contractures and extensor lag regularly occur and may require secondary surgery.^{3,4}

Recent studies⁵⁻¹² indicate that intramedullary fixation with headless compression screws (IMCS) is a reliable technique for the treatment of unstable extra-articular fractures of the metacarpals as well as middle and proximal phalanges. Importantly, this treatment is associated with a minimally invasive approach and allows early active mobilization. The screws are left buried beneath the articular surfaces without joint motion interference and the need for removal. In this article, we describe the possible techniques using intramedullary headless compression screws for the treatment of metacarpal and phalangeal fractures.

Metacarpal fractures

Retrograde technique

Transverse fractures of the metacarpal shaft represent a good indication for this technique. Non-comminuted subcapital and short oblique fractures can also be treated with IMCS.

Appropriate screw length and width should be measured on pre-operative imaging. First, a closed reduction is performed. To better reach the head of the metacarpal, the metacarpophalangeal (MCP) joint is flexed to 90°. A 3.0 mm longitudinal incision is made over the MCP joint. A guidewire is inserted along the metacarpal axis under fluoroscopy. The entry point should be on the dorsal part of the metacarpal head for optimal positioning of the screw inside the intramedullary canal. Some authors⁵ suggest using a blunt K-wire to avoid cortical penetration. We use headless cannulated compression screws (SpeedTip CCS, Medartis, Basel, Switzerland) and normally insert 3.0 mm screws for the metacarpals.

Jann et al⁸ suggested to reach the metacarpal isthmus with the screw to ensure a rigid fixation. To minimize the cartilage injury, we advise the use of 3.0 mm screws even for the fifth metacarpal where the isthmus can measure 5.0 mm. In this case, the relative stabilization will lead to

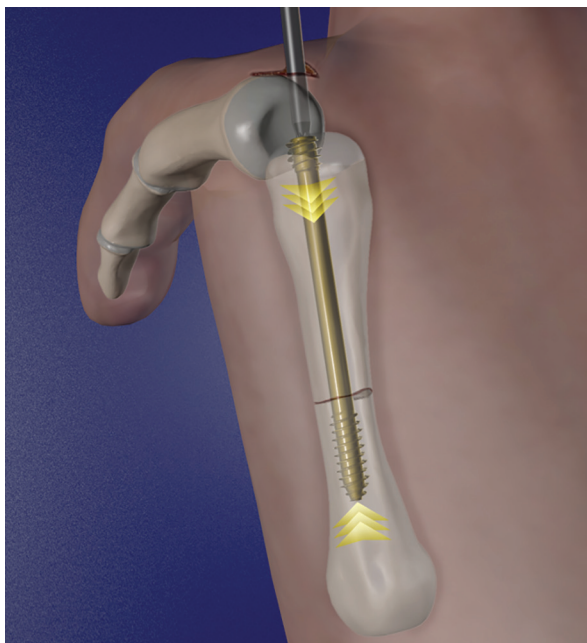


Fig. 1 Intramedullary screw fixation of a transverse metacarpal fracture.

callus formation by means of an elastic fixation. We advise to always go completely beyond the fracture with the screw thread (Fig. 1).

Y-strutting technique

In cases with comminuted subcapital or distal shaft fractures of the metacarpal, the use of a single headless compression screw can jeopardize the stability of the construct with subsequent shortening of the metacarpal head. Del Piñal et al⁵ proposed the new surgical concept of 'Y-strutting' (Fig. 2). Two guidewires are inserted in convergent directions. Then, two screws (3.0 mm and 2.2 mm) are used to create a triangular-shaped frame that supports the bone and prevents a structural collapse. The surgeon should be aware of the potential conflict between the two screws and one screw should be shorter than the other.

Proximal phalanx fractures

Intra-articular technique

The diameter of the intramedullary canal should always be measured before surgery on lateral and antero-posterior radiographs. If the diameter is less than 3.0 mm, we use a 2.2 mm diameter screw.

A 3.0 mm incision is made over the MCP joint. A guide wire is inserted under fluoroscopic control at the dorsal side of the MCP joint, which is bent to 70° of flexion. To facilitate the insertion of the wire, the base of the proximal phalanx

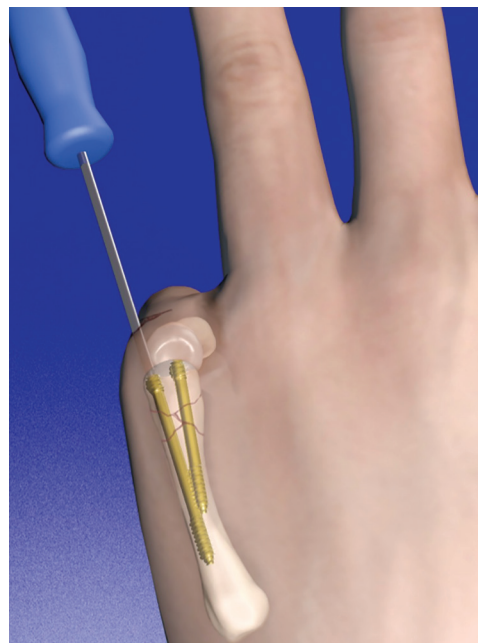


Fig. 2 Y-strutting technique with two screws for a multi-fragmentary subcapital metacarpal fracture.

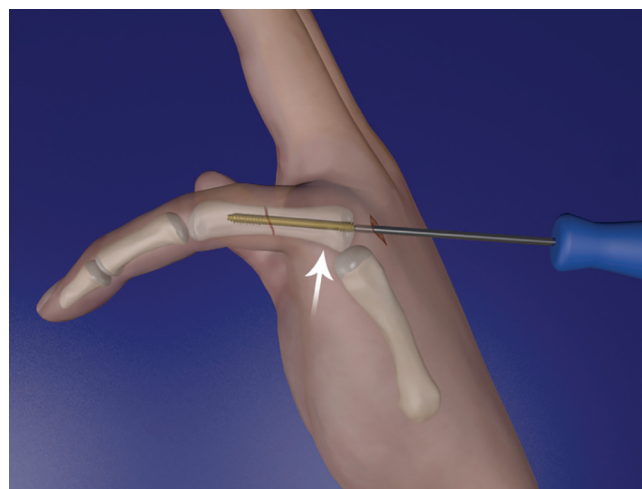


Fig. 3 Anterograde intra-articular intramedullary headless compression screw (IMCS) fixation of the proximal phalanx. A subluxating force is applied by the surgeon to allow a better entry point at the base of the phalanx.

is pushed dorsally to provide a dorsal subluxation. A 90° flexion position of the MCP joint can prevent the dorsal displacement of the proximal phalanx because of the tightness of the dorsal capsule and the collateral ligaments. The wire is then advanced into the base of the proximal phalanx along its longitudinal axis. A 3.0 mm or 2.2 mm headless compression screw is then inserted (Fig. 3). The guidewire can also be advanced in the base of the proximal

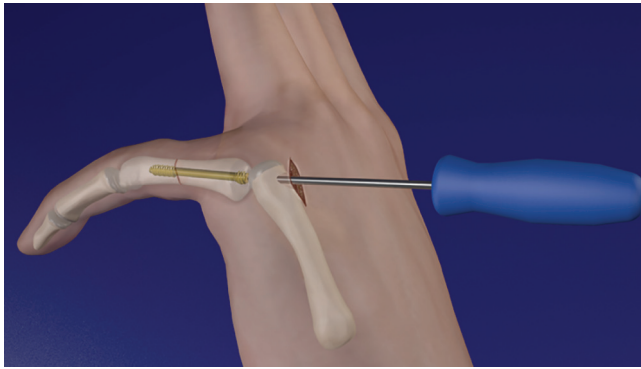


Fig. 4 Trans-articular technique (through the metacarpal head) for an anterograde intramedullary headless compression screw (IMCS) fixation of the proximal phalanx.

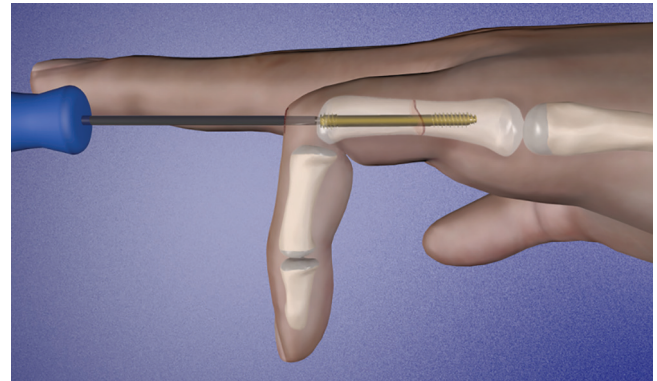


Fig. 5 Retrograde intramedullary headless compression screw (IMCS) fixation of the proximal phalanx.

phalanx in an oblique direction without articular violation, particularly if subluxation of the MCP joint is difficult.

Anterograde trans-articular technique

When it is impossible to achieve a sufficient dorsal subluxation of the proximal phalanx or the guidewire position is not satisfactory, a trans-articular technique is advised. A 3.0 mm incision is made over the MCP joint which is bent to 90° of flexion. The guidewire is inserted into the dorsal side of the metacarpal head. The wire is then advanced through the metacarpal into the base of the proximal phalanx (Fig. 4). The drawback of this technique is that both the cartilage of the metacarpal head and the base of the proximal phalanx are injured. A cannulated 2.2 mm or 3.0 mm headless compression screw is advanced over the guide wire with a cannulated screwdriver until the screw head is beneath the cartilage of the base of the phalanx.

Retrograde intra-articular technique

Retrograde headless compression screws may also be introduced through the proximal interphalangeal joint.⁵ For this purpose, a 3.0 mm incision is made over the proximal interphalangeal (PIP) joint, which is flexed 90°. The wire is then advanced into the base of the proximal phalanx along its longitudinal axis (Fig. 5). This is an easier and technically faster procedure but creates a larger area of chondral damage of the joint surface of the head of the proximal phalanx compared with the trans-articular procedure. The central slip of the extensor apparatus may also be significantly injured during the insertion of the screw.

Dual anterograde intra-articular fixation

In cases of comminuted extra-articular fractures of the proximal third of the proximal phalanx, the use of a single headless compression screw can result in a less stable

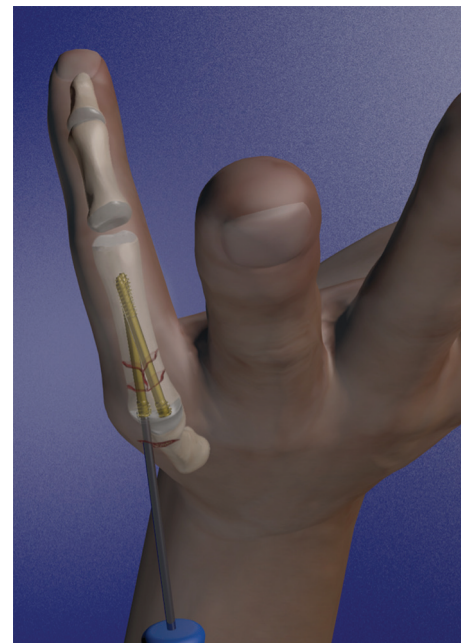


Fig. 6 Dual anterograde proximal phalanx fixation. Proximal phalanx 'Y-strutting'.

construct. As described for comminuted subcapital metacarpal fractures, the 'Y-strutting' technique with a dual anterograde fixation (Fig. 6) can be an option to stabilize these fractures as reported by Gaspar et al.⁹ A transverse incision is made over the MCP joint which is then flexed to 70°. The proximal end of the phalanx can be subluxated dorsally to facilitate insertion of the first guidewire under fluoroscopy. The first wire can then be inserted in an oblique direction to the long axis of the phalanx. Finally, the second screw is placed in a more oblique orientation and with shorter length. We normally use two 2.2 mm CCS headless compression screws.

Middle phalanx fractures

Anterograde extra-articular technique

In cases with transverse fractures of the middle phalanx, the PIP joint is more difficult to sublux. Therefore, we advise the insertion of the guidewire from the ulnar aspect of the base of the middle phalanx in an oblique direction. Subsequently, a 2.2 mm screw is inserted.

Anterograde trans-articular technique

When a good placement of the guidewire cannot be achieved, a trans-articular technique needs to be used. The PIP joint should be flexed to 90° to avoid the risk of fracturing the head of the proximal phalanx during the screw introduction. A guidewire is then introduced into the dorsal aspect of the head of the proximal phalanx with a temporary transfixation of the PIP joint. Then a 2.2 mm screw is inserted.

Retrograde intra-articular technique

A 2.2 mm CCS headless compression screw can be inserted through the distal interphalangeal (DIP) joint using a retrograde technique (Fig. 7). The surgeon must be aware of an extensor tendon injury during this insertion. Furthermore, due to the smaller surface of the DIP joint of the middle phalanx, this technique may result in a greater percentage of damage when compared with the anterograde and trans-articular technique.

The use of IMCS can be extended even to selected cases of multi-fragmentary extra-articular fractures of the phalanges. The screw should be as long as possible to avoid excessive compression of the fracture site. A trans-articular technique is advised to better place the screw at the centre of the base of the phalanx (Fig. 8). Buddy tape protection is strongly suggested to control the rotational forces on the finger, post-operatively.

Post-operative management

After the surgery, the finger is protected with a buddy tape bandage to the adjacent finger to reduce rotational instability. Early active motion is encouraged after the surgery and a removable splint is made for pain control and removed within a week by a hand therapist. The patients are then seen six weeks post-operatively for radiological follow-up to verify fracture union.

Clinical results

Ruchelsman et al¹³ examined 20 metacarpal head and neck fractures treated with IMCS. A three-month follow-up of all patients demonstrated full active MCP joint extension and flexion. Mean MCP joint flexion measured 88° (range, 70–100°). No secondary surgeries were

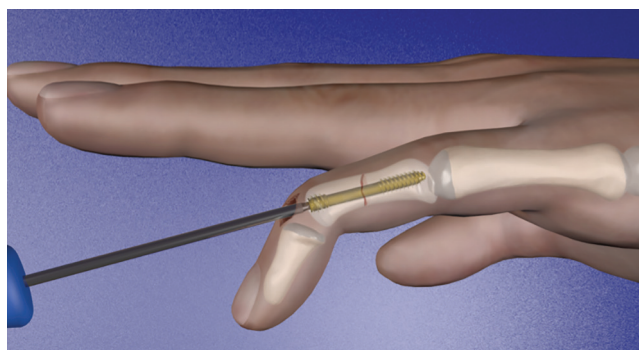


Fig. 7 Retrograde fixation of the middle phalanx.

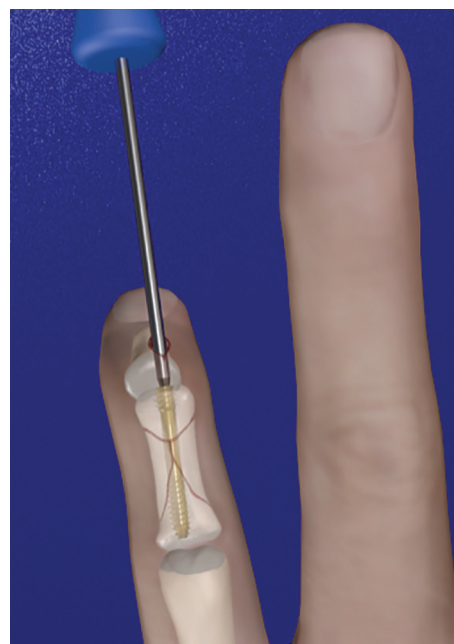


Fig. 8 Intramedullary fixation of a multi-fragmentary fracture of the middle phalanx. The screw should be as long as possible to avoid compression.

performed. All patients achieved radiographic union in six weeks. Two patients had a re-fracture of the metacarpal shaft due to high-energy trauma after consolidation. These patients were treated with screw removal and open reduction and internal fixation with plates.

Jann et al⁸ analysed the results of 20 unstable metacarpal fractures treated with IMCS and no immobilization. Seventeen digits in 13 patients had full range of motion, except for one patient with a head fracture of the second metacarpal who had a 25° extension lag. The mean grip strength in all patients was 93% of the contralateral hand. This study did not report any infections, non-union or rotational deformities. No cases of complex regional pain syndrome were reported. One patient underwent screw removal because of proximal migration.

Giesen et al⁶ reported their experience with 31 consecutive extra-articular unstable fractures of the proximal or middle phalanges. An intra-articular technique was used in 17 fractures of the proximal phalanx and five fractures of the middle phalanx. A trans-articular technique was adopted in seven fractures of the proximal phalanx and two fractures of the middle phalanx. All fractures healed clinically and radiographically between 28 and 43 days after surgery. At the last follow-up, a mean total active motion (TAM) of 222° (range, 90–295°) was noted. The average extension deficit for the PIP joint was 8° (range, 0–20°).

Gaspar et al⁹ described 10 proximal phalanx fractures treated with dual anterograde intra medullary headless screw fixation (IMHS) fixation. At an average follow-up of 84 weeks (range, 61–106 weeks), the TAM was 258° (range, 245–270°) and the mean post-operative Quick-DASH score was 3.9 (range, 0–13.6). No complications occurred and no patients required additional surgeries.

Chondral damage

A common point of concern when using intramedullary headless compression screws for the fixation of metacarpal and phalangeal fractures is the potential articular cartilage damage. In general, antegrade fixation from the base of the proximal phalanx produces less damage to the cartilage compared with the retrograde technique.^{1,11} Moreover, Borbas et al⁷ stated that the loss of cartilage surface in proximal phalanx fractures appears to be less relevant in the intra-articular technique than the trans-articular one, although this difference was not statistically significant. Ten Berg et al¹⁴ reported that the volume of the head of the screws in the metacarpal head has a relatively low relevance (4% for the 2.4 mm screws and 5% of the total joint surface for the 3.0 mm screw). From computed tomography scans of the head of the proximal phalanx, Del Piñal et al⁵ reported, instead, a higher articular surface injury by cannulated screws (13% to 18% for a 2.5 mm screw and 19% to 25% for the 3.0 mm screw). At the level of the head of the metacarpal and phalanx there are still no reports of mid-term osteoarthritic degeneration using IMCS.

Tendon injuries

In the study by del Piñal et al,⁵ only two patients had an extension lag greater than 30° at the PIP joint. One patient had a concomitant flexor tendon injury. In a cadaveric study, Borbas et al⁷ did not find significant damage to the extensor tendons except cases of partial tears < 20% of the width of the tendon.

Screw removal

Usually the intramedullary screws are not removed and can remain inside the bones. However, the main indications for screw removal are joint protrusion, infection, screw fracture after new fracture.

In cases of joint protrusion of the screw, it is possible to perform a small surgical approach at the joint level and easily remove it with a screwdriver. It is also possible to use the guidewire under fluoroscopy to find the screw in cases of a percutaneous procedure.

In cases of screw breakage with a new fracture, it is possible to remove the part of screw nearer to the joint where it was inserted with a small incision and with the help of the guidewire under fluoroscopy.

For the removal of the other part of the screw it is necessary to gain dorsal access through the fracture site especially for metacarpal fractures. Subsequently it is possible to perform a new intramedullary screw fixation, but it is usually advisable to perform an osteosynthesis with a plate due to the risk of further joint damage and screw loosening. Furthermore, in cases of new trauma the screw can be bent. In the case of an acceptable flexion deformity, the screw is left in the bone and the treatment is conservative. In cases with an excessive flexion and rotational deformity, it is necessary to perform a dorsal approach through the fracture site and try to mobilize the screw and remove it through the joint with a second incision.

Giesen et al⁶ found a protruding screw in the MCP joint one month after the operation. The screw removal required a mini-open approach to the MCP joint to grasp the protruding part of the screw and remove it.

Complication rate with IMCS, K-wires and plates compared

Stahl and Schwartz¹⁵ reported their experience in 590 K-wire fracture fixations of the hand performed on 236 patients. They found a 15.2% complication rate (osteomyelitis, tendon rupture, nerve lesion, pin tract infection, pin loosening or migration). Fusetti et al⁴ reported 32% of complications in 157 metacarpal fractures treated using open reduction and internal fixation with plates, including difficulty with fracture healing (15%), stiffness (10%), plate loosening or breakage (8%), complex regional pain syndrome (two patients) and deep infection (one patient). Jann et al⁸ reported results of 20 unstable metacarpal fractures which were surgically managed with compression screws. Out of 15 patients, one required arthrolysis and one had extension lag. Del Piñal et al⁵ reported only two patients with a major extension lag at the proximal interphalangeal joint.

Conclusions

Although different fixation methods are described for the treatment of fractures of the hand, surgeons tend to be tempted to use more stable devices with extensive soft tissue damage. This can lead to tendon adhesions, restricted motion, stiffness, and to secondary surgeries.⁴ Less invasive procedures, with minor tissue dissection, minimize these complications, but they provide less stability for the fracture. IMCS fixation of the metacarpals and phalanx has been popularized worldwide in recent years due to the minimally invasive approach and to the short learning curve. To date, it is still not clear whether the IMCS can be defined as a rigid fixation or a dynamic one similar to an elastic endomedullary device. However, IMCS may be prone to a rotational instability due to the long lever arm of the finger. This technique should not be used in the presence of an open epiphysis, infection and most of all in subchondral fractures, because of the lack of purchase for the head of the screw.

Overall, IMCS fixation is a reliable technique for the surgical management of transverse and short oblique metacarpal, proximal and middle phalangeal fractures. This intramedullary fixation is not advisable for long oblique fractures and the critical angle at which an oblique fracture becomes unsuitable for IMCS is still under debate. A double-screw construct is recommended for comminuted subcapital fractures of the metacarpal to avoid metacarpal shortening. IMCS can even be applied for peri-articular fractures of the proximal third of the phalanx and in some multi-fragmentary proximal and middle phalangeal fractures.

AUTHOR INFORMATION

Department of Plastic Surgery and Hand Surgery, University Hospital Zurich, Zurich, Switzerland.

Correspondence should be sent to: Maurizio Calcagni, Department of Plastic Surgery and Hand Surgery, University Hospital Zurich, Raemistrasse 100, 8091 Zurich, Switzerland.

Email: maurizio.calcagni@usz.ch

ICMJE CONFLICT OF INTEREST STATEMENT

MC reports non-financial support from SOBI, non-financial support from MEDARTIS, non-financial support from SILK BIOMATERIALS, and non-financial support from DYCARE, outside the submitted work.

The other authors have nothing to disclose.

FUNDING STATEMENT

The author or one or more of the authors have received or will receive benefits for personal or professional use from a commercial party related directly or indirectly to the subject of this article. In addition, benefits have been or will be directed to a research fund, foundation, educational institution, or other non-profit organization with which one or more of the authors are associated.

LICENCE

© 2020 The author(s)

This article is distributed under the terms of the Creative Commons Attribution-Non Commercial 4.0 International (CC BY-NC 4.0) licence (<https://creativecommons.org/licenses/by-nc/4.0/>) which permits non-commercial use, reproduction and distribution of the work without further permission provided the original work is attributed.

REFERENCES

1. Henry MH. Fractures of the proximal phalanx and metacarpals in the hand: preferred methods of stabilization. *J Am Acad Orthop Surg* 2008;16:586–595.
2. Kozin SH, Thoder JJ, Lieberman G. Operative treatment of metacarpal and phalangeal shaft fractures. *J Am Acad Orthop Surg* 2000;8:111–121.
3. Eberlin KR, Babushkina A, Neira JR, et al. Outcomes of closed reduction and periarticular pinning of base and shaft fractures of the proximal phalanx. *J Hand Surg Am* 2014;39:1524–1528.
4. Fusetti C, Della Santa DR. Influence of fracture pattern on consolidation after metacarpal plate fixation. *Chir Main* 2004;23:32–36.
5. del Piñal F, Moraleda E, Rúas JS, de Piero GH, Cerezal L. Minimally invasive fixation of fractures of the phalanges and metacarpals with intramedullary cannulated headless compression screws. *J Hand Surg Am* 2015;40:692–700.
6. Giesen T, Gazzola R, Poggetti A, Giovanoli P, Calcagni M. Intramedullary headless screw fixation for fractures of the proximal and middle phalanges in the digits of the hand: a review of 31 consecutive fractures. *J Hand Surg Eur Vol* 2016;41:688–694.
7. Borbas P, Dreu M, Poggetti A, Calcagni M, Giesen T. Treatment of proximal phalangeal fractures with an antegrade intramedullary screw: a cadaver study. *J Hand Surg Eur Vol* 2016;41:683–687.
8. Jann D, Calcagni M, Giovanoli P, Giesen T. Retrograde fixation of metacarpal fractures with intramedullary cannulated headless compression screws. *Hand Surg Rehabil* 2018;37:99–103.
9. Gaspar MP, Gandhi SD, Culp RW, Kane PM. Dual antegrade intramedullary headless screw fixation for treatment of unstable proximal phalanx fractures. *Hand (N Y)* 2019;14:494–499.
10. Doorn MC, Nydick JA, Williams BD, Garcia MJ. Retrograde headless intramedullary screw fixation for displaced fifth metacarpal neck and shaft fractures: short term results. *Hand (N Y)* 2015;10:314–318.
11. Weiss AP. Intramedullary Herbert screws for treatment of phalangeal nonunion. *Tech Hand Up Extrem Surg* 1997;1:41–47.
12. Boulton CL, Salzler M, Mudgal CS. Intramedullary cannulated headless screw fixation of a comminuted subcapital metacarpal fracture: case report. *J Hand Surg Am* 2010;35:1260–1263.
13. Ruchelsman DE, Puri S, Feinberg-Zadek N, Leibman MI, Belsky MR. Clinical outcomes of limited-open retrograde intramedullary headless screw fixation of metacarpal fractures. *J Hand Surg Am* 2014;39:2390–2395.
14. ten Berg PW, Mudgal CS, Leibman MI, Belsky MR, Ruchelsman DE. Quantitative 3-dimensional CT analyses of intramedullary headless screw fixation for metacarpal neck fractures. *J Hand Surg Am* 2013;38:322–330.
15. Stahl S, Schwartz O. Complications of K-wire fixation of fractures and dislocations in the hand and wrist. *Arch Orthop Trauma Surg* 2001;121:527–530.