



Massive hemothorax after central venous catheter insertion in a patient with multiple trauma

Jeong Heon Park¹, Jaegyok Song¹, Pyeong-wha Oh²

¹Department of Anesthesiology and Pain Medicine, Dankook University College of Medicine, Cheonan, Korea

²Department of Anesthesiology and Pain Medicine, Dankook University Hospital, Cheonan, Korea

Central venous catheter (CVC) insertion is commonly used in the operating room and intensive care unit to monitor central venous pressure and secure an intravenous route to deliver medications and nutritional support that cannot be safely infused into peripheral veins. However, CVC insertion may be associated with serious complications such as arterial puncture, hematoma, pneumothorax, hemothorax, catheter infections, and thrombosis. Several methods have been recommended to prevent these complications. Here we report a case of massive hemothorax caused by attempts of CVC insertion into the internal jugular vein and subclavian vein in a patient with multiple trauma. CVC placement should be performed or supervised by an experienced physician to decrease the incidence of CVC-related complications. CVC insertion under ultrasound guidance is recommended.

Keywords: Catheterization; Central Venous Catheters; Hemothorax; Ultrasonography.



This is an Open Access article distributed under the terms of the Creative Commons Attribution Non-Commercial License (<http://creativecommons.org/licenses/by-nc/4.0/>) which permits unrestricted non-commercial use, distribution, and reproduction in any medium, provided the original work is properly cited.



INTRODUCTION

Central venous catheter (CVC) insertion into the internal jugular or subclavian vein is commonly used in the operating room and intensive care unit to monitor central venous pressure and secure an intravenous route to deliver medications and nutritional support that cannot be infused safely to peripheral veins [1]. This procedure is particularly useful in patients undergoing major surgery, or in critically ill patients who require close monitoring and a high dose of inotropic agents and vasopressors. However, CVC insertion may be associated with complications such as arterial puncture, hematoma, pneumothorax, hemothorax, catheter infections, and thrombosis [1-3]. Here we report a case of massive

hemothorax due to attempts at CVC insertion into the internal jugular and subclavian veins, and provide a brief review of the current literature.

CASE REPORT

This report was presented after receiving IRB approval (DKUH 2020-12-008) and obtaining written informed consent from the patient. A 42-year-old woman (ASA class I; weight, 53 kg; height, 163 cm) presented with multiple traumas (blow out fracture of the right orbit, right femur shaft fracture, and 11th thoracic spine fracture) and was scheduled for surgery (Fig. 1). She was previously healthy and had no history of systemic disease or medications. Preoperative evaluation, including

Received: December 29, 2020 • Revised: January 14, 2021 • Accepted: January 17, 2021

Corresponding Author: Jaegyok Song, Department of Anesthesiology and Pain Medicine, Dankook University College of Medicine, 119, Dandae-ro, Dongnam-gu, Cheonan-si, Chungnam 31116, Korea

Tel: +82-41-550-6819, Cellular Phone: +82-10-2685-3258 Fax: +82-41-550-6819 E-mail: jaegyoksong@gmail.com

Copyright© 2021 Journal of Dental Anesthesia and Pain Medicine

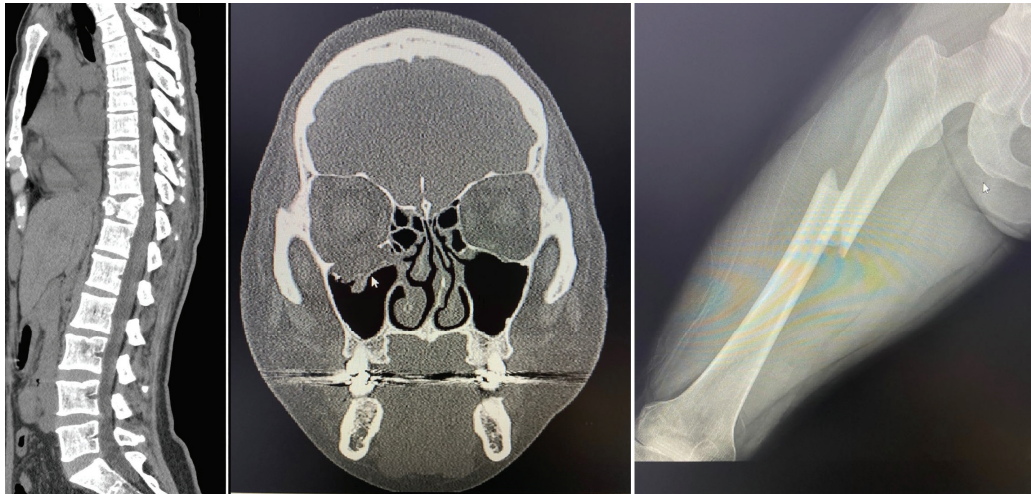


Fig. 1. Preoperative radiographs of the patient. T11 Spine body fracture, blow-out fracture of the right maxilla, and right femur shaft fracture.

laboratory tests, electrocardiography, and chest radiography, showed normal findings.

Patient monitors included standard monitors and continuous arterial blood pressure monitoring with radial artery catheter insertion. General anesthesia was induced with intravenous injection of 50 μ g fentanyl, 60 mg lidocaine, 120 mg propofol, and 40 mg rocuronium and maintained with 7–10 vol % desflurane. After intubation, central CVC (Bio Line-Next, 8.5-F triple lumen catheter; Ewha Biomedics, Republic of Korea) insertion was performed into the right internal jugular vein using the anatomical landmark technique. However, the procedure was difficult and eventually failed after three attempts because we encountered impingement while inserting the guidewire despite adequate blood aspiration. The first two attempts were performed by a resident, and the third was performed by an attending physician. After 10 min. of compression with clean gauze, we confirmed no remarkable swelling at the puncture site. The attending physician inserted a CVC into the right subclavian vein and succeeded on the second attempt. During the procedure, the patient's blood pressure decreased to 75/50 mmHg and was managed with the intravenous injection of 100 μ g phenylephrine, 5 mg ephedrine, and volume replacement. The patient's blood pressure subsequently recovered to 130/70 mmHg.

The duration of the first surgery (external fixation of

femur shaft fracture) was approximately 1 h. The patient's position was changed from supine to prone to perform spine surgery. At this point, her hemoglobin (Hb) had decreased from 11.2 g/dl to 6.5 g/dl, and the transfusion of 3 units of packed red blood cells (PRBC) was initiated. After the initiation of spine surgery, the peak inspiratory pressure gradually increased from 22 to 28 cmH₂O, and the heart rate also increased from 80 to 98/min. Bleeding at the operation site was estimated to be approximately 800 ml, and an additional 6 units of PRBC and 3 units of fresh frozen plasma (FFP) were infused. However, the patient's blood pressure gradually decreased to 80/50 mmHg, and the heart rate increased to 105/min. PaO₂ decreased from 260 mmHg to 152 mmHg, and the Hb level was 10.5 g/dl. Infusion of norepinephrine 0.1 μ g/kg/min was started; however, more volume replacement was necessary to maintain adequate blood pressure. We suspected hemothorax caused by CVC insertion and performed chest radiography, which showed tension hemothorax in the right thoracic cavity (Fig. 2). The thoracic surgeon was consulted to insert a chest tube. After chest tube insertion, approximately 3 L of fresh blood was drained, and draining was continued at a rate of approximately 100 ml per minute. The patient's position was changed from prone to supine following completion of the spine surgery. The CVC was removed, and the insertion site was compressed by grabbing the

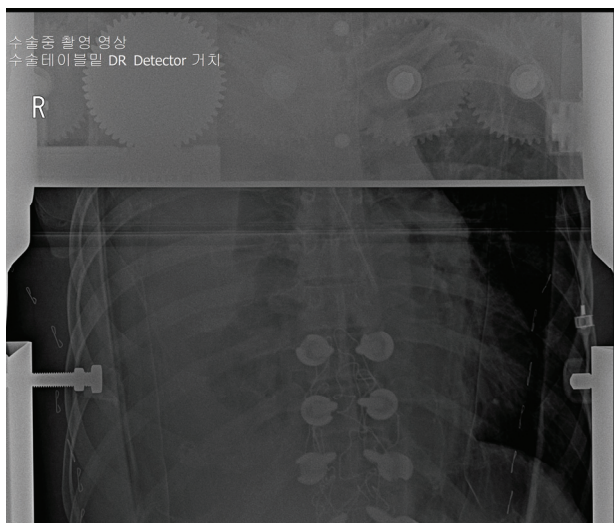


Fig. 2. Intraoperative chest radiograph (PA view, prone position) showing massive hemothorax in the right lung field.

clavicle. The operation time was 5 h and 5 min. The infused volume was 16000 ml of crystalloids, 3000 ml of colloids, 23 units of PRBC, and 13 units of FFP. The urine output was 410 ml, and the estimated blood loss was 7000 ml. The patient was transferred to the intensive care unit and kept sedated with endotracheal intubation. The CVC was inserted again in the left femoral vein; however, fresh blood still drained into the chest tube, and the blood pressure decreased whenever compression was released at the subclavian catheter insertion site. Severe swelling developed at the neck puncture site. We performed a chest computed tomography (CT) scan, which showed massive contrast media leakage in the right side of the neck and severe hemothorax (Fig. 3). The patient was transferred to the operating room, and bleeding sites (internal jugular vein, common carotid artery, thyrocervical trunk, and distal subclavian artery) were repaired, and the hematoma was evacuated through a neck incision and median sternotomy under general anesthesia. Her vital signs stabilized immediately after the bleeding was controlled, and norepinephrine infusion was stopped. The operation time was 6 h, the estimated blood loss was 5000 ml, and the urine output was 2700 ml. We infused 4000 ml of crystalloids, 500 ml of colloids, 15 units of PRBC, 15 units of FFP, and 20 units of platelet concentrate. The patient's postoperative laboratory findings

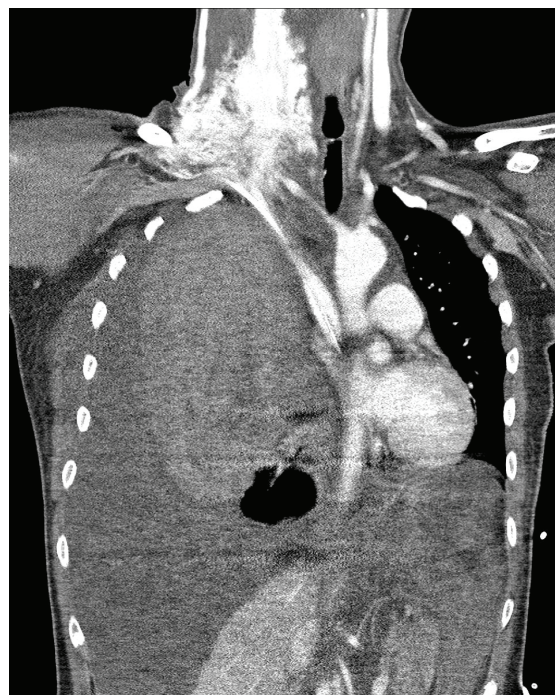


Fig. 3. Postoperative chest computed tomography showing contrast media leakage in the right supraclavicular area and massive hemothorax.

were as follows: Hb, 10.5 g/dl; platelet count, 88000/ μ l; and arterial blood gas analysis results were within normal limits. The patient was transferred to the general ward on the eighth postoperative day (POD 8). Additional operations (right orbit reconstruction on POD 13, and closed reduction and internal fixation of the right femur on POD 15) were performed without complications, and she was discharged on POD 27.

DISCUSSION

This case highlights the risk of multiple blind punctures during CVC insertion. When tension hemothorax was diagnosed, we suspected that the subclavian artery puncture site would be the main source of bleeding. However, the chest CT showed that supraclavicular bleeding was the main cause of tension hemothorax. During the surgery to control bleeding, the main bleeding focus was the thyrocervical trunk puncture site that penetrated the anterior to posterior wall of the vessel. Prior to this, the anatomical landmark technique was used

routinely. The needle insertion site was the triangle formed by the clavicle and the sternal and clavicular heads of the sternocleidomastoid muscle. We used a 23-G, 3-cm needle to confirm the depth of the internal jugular vein before the 18-G 6.3 cm needle was inserted for threading the spring guidewire. Although the policy of our practice is to not go deeper than 3 cm, but the needle penetrated the thyrocervical trunk deep in the neck. It is difficult to know how deep the needle reached because the needle for CVC placement has no scale, unlike a Tuohy needle. Srinivasan et al. [4] reported that the internal jugular vein overlaps with the carotid artery 70%–90% of the time, and more so with increasing age. Therefore, arterial puncture cannot be prevented with a blind technique.

In this case, it was difficult to obtain adequate blood aspiration from the targeted blood vessel. However, there are some cases in which adequate blood aspiration does not ensure accurate needle placement. Wallin et al. [5] reported a case of unrecognized intrathoracic placement of a subclavian CVC by the anatomic landmark technique in a patient with traumatic hemothorax. They obtained adequate blood aspiration during the procedure; however, the blood was from the pleural cavity and not the subclavian vein.

McGee et al. recommended several policies to decrease CVC-related mechanical complications: 1) Recognizing risk factors for difficult catheterization, 2) seeking assistance from experienced clinicians, 3) avoiding femoral venous catheterization, 4) use of ultrasound guidance during internal jugular catheterization, and 5) avoiding scheduling of routine catheter changes.

Ultrasound-guided techniques have been recommended to avoid these risks because they have been reported to increase the success rate and reduce the rate of total complications, arterial puncture, and procedure time [1,6-9]. Srinivasan et al. [4] compared the anatomic landmark method to ultrasound-guided techniques in internal jugular venous CVC placement. Ultrasound-guided techniques were shown to have a significantly smaller number of failed attempts, posterior wall

punctures, arterial punctures, and CVC placement-related complications. Appropriate training and education are required to benefit from the ultrasound-guided technique [6-8].

The ultrasound-guided technique has several limitations. Wetzel et al. [2] reported a case of massive hemothorax related to a left brachiocephalic vein perforation caused by a dilator. They used ultrasound-guided techniques, and the procedures were performed smoothly. Adequate aspiration from all ports was noted; however, massive tension hemothorax occurred after catheterization, and contrast leakage was observed from the left brachiocephalic vein. This case shows that left-sided CVC placement should be performed cautiously since an ultrasound-guided technique and adequate guidewire placement were not sufficient to prevent left brachiocephalic vein injury by the dilator.

CVC insertion should be performed or supervised by an experienced physician. Indeed, when the procedure was performed by physicians who had performed more than 50 CVC insertions, the incidence of mechanical complications was reduced by half compared to those who did not [1]. In addition, the incidence of mechanical complications after three or more insertion attempts was six times that of the rate after one attempt [1].

In our case, chest radiography was helpful for the diagnosis of hemothorax, but, unlike chest CT, it could not be used to identify the bleeding site. Routine chest radiograph has been recommended as a screening test after CVC insertion. However, Chui et al. [10] retrospectively reviewed 7 years of ultrasound-guided CVC placements and found that chest radiography was unnecessary in terms of cost/benefit. Moreover, Woodland et al. [11] reported 200 cases (198 cases of internal jugular vein and 2 cases of subclavian vein) of CVC placements, and concluded that routine chest radiography rarely affected management, and that the decision for chest radiography should be guided by clinical factors.

In conclusion, CVC placement is a useful procedure, but can lead to serious complications. Our patient

experienced severe hemothorax after multiple attempts at CVC placement. CVC placement should be performed or supervised by an experienced physician under ultrasound guidance. Chest radiographs post-CVC placement should not be performed routinely, but should be guided by clinical factors.

AUTHOR ORCIDs

Jeong-Heon Park: <https://orcid.org/0000-0003-3852-5390>

Jaegyok Song: <https://orcid.org/0000-0002-4727-6296>

Pyeonghwa Oh: <https://orcid.org/0000-0002-8995-2854>

AUTHOR CONTRIBUTIONS

Jeong-Heon Park: Writing - review & editing

Jaegyok Song: Data curation, Writing - original draft, Writing - review & editing

Pyeonghwa Oh: Data curation

NOTE: The authors have no funding or conflicts of interest.

REFERENCES

1. McGee DC, Gould MK. Preventing complications of central venous catheterization. *N Engl J Med* 2003; 348: 1123-33.
2. Wetzel LR, Patel PR, Pesa NL. Central venous catheter placement in the left internal jugular vein complicated by perforation of the left brachiocephalic vein and massive hemothorax: a case report. *A A Case Rep* 2017; 9: 16-9.
3. Lee HK, Hong SW, Kim GJ, Ryu T, Han JK, Kim JC. Massive hemothorax immediately after removal of central venous catheter -A case report. *Korean J Anesthesiol* 2013; 65: 77-9.
4. Srinivasan S, Govil D, Gupta S, Patel S, Jagadeesh KN, Tomar DS. Incidence of posterior wall penetration during internal jugular vein cannulation: A comparison of two techniques using real-time ultrasound. *Indian J Anaesth* 2017; 61: 240-4.
5. Wallin D, Privette AR, Campbell AR, Tang JF. A case of unrecognized intrathoracic placement of a subclavian central venous catheter in a patient with large traumatic hemothorax. *Case Rep Emerg Med* 2015; 2015: 382624.
6. Brass P, Hellmich M, Kolodziej L, Schick G, Smith AF. Ultrasound guidance versus anatomical landmarks for subclavian or femoral vein catheterization. *Cochrane Database Syst Rev* 2015; 1: Cd011447.
7. Brass P, Hellmich M, Kolodziej L, Schick G, Smith AF. Ultrasound guidance versus anatomical landmarks for internal jugular vein catheterization. *Cochrane Database Syst Rev* 2015; 1: Cd006962.
8. Hoffman T, Du Plessis M, Prekupec MP, Gielecki J, Zurada A, Tubbs RS, et al. Ultrasound-guided central venous catheterization: A review of the relevant anatomy, technique, complications, and anatomical variations. *Clin Anat* 2017; 30: 237-50.
9. Kayir S, Ozyalcin S, Dogan G, Diken AI, Turkmen U. Internal jugular vein catheterization: the landmark technique versus ultrasonography guidance in cardiac surgery. *Cureus* 2019; 11: e4026.
10. Chui J, Saeed R, Jakobowski L, Wang W, Eldeyasty B, Zhu F, et al. Is routine chest x-ray after ultrasound-guided central venous catheter insertion choosing wisely?: a population-based retrospective study of 6,875 patients. *Chest* 2018; 154: 148-56.
11. Woodland DC, Randall Cooper C, Farzan Rashid M, Rosario VL, Weyker PD, Weintraub J, et al. Routine chest X-ray is unnecessary after ultrasound-guided central venous line placement in the operating room. *J Crit Care* 2018; 46: 13-6.