

# Successful peficitinib addition on anti-MDA5 antibody-positive dermatomyositis refractory to triple therapy and glucocorticoid reduction

SAGE Open Medical Case Reports  
Volume 10: 1–6  
© The Author(s) 2022  
Article reuse guidelines:  
sagepub.com/journals-permissions  
DOI: 10.1177/2050313X221141277  
journals.sagepub.com/home/sco



Yuki Oba<sup>1</sup>, Masayuki Yamanouchi, Daisuke Ikuma, Hiroki Mizuno, Noriko Inoue, Akinari Sekine, Eiko Hasegawa, Tatsuya Suwabe, Naoki Sawa and Yoshifumi Ubara

## Abstract

Anti-melanoma differentiation-associated gene 5 antibody-positive dermatomyositis is the poorest prognosis of all dermatomyositis due to its associated rapidly progressive interstitial lung disease. Intensive treatment is required from the onset and triple therapy with prednisolone, calcineurin inhibitors, and intravenous cyclophosphamide is recommended. However, some patients are refractory or dependent on this treatment and additional immunosuppressive therapy is required. Recently, the efficacy of tofacitinib, a JAK inhibitor, has been reported. Here, we describe a case of a 50-year-old woman with anti-melanoma differentiation-associated gene 5 antibody-positive dermatomyositis who became refractory to triple therapy and prednisolone reduction, and achieved remission with the addition of peficitinib, a JAK inhibitor. This is the first report showing that peficitinib is effective for anti-melanoma differentiation-associated gene 5 antibody-positive dermatomyositis and it may be a potential treatment option.

## Keywords

Anti-MDA5 antibody-positive dermatomyositis, interstitial lung disease, triple therapy, JAK inhibitor, peficitinib

Date received: 8 July 2022; accepted: 7 November 2022

## Introduction

Anti-melanoma differentiation-associated gene 5 (MDA5) antibody (Ab)-positive dermatomyositis (DM) is characterized for amyopathic DM with rapidly progressive interstitial lung disease (RP-ILD).<sup>1,2</sup> Especially, RP-ILD is difficult to save unless the acute stage of the disease is overcome, and if treatment is delayed, it is fatal due to lack of response for the treatment even if the treatment was intensified later. Therefore, the treatment for anti-MDA5 Ab-positive DM should be initiated as soon as RP-ILD is recognized in the presence of anti-MDA5 Ab-positive patients. As the treatment, triple therapy with prednisolone (PSL), calcineurin inhibitors (CNIs), and intravenous cyclophosphamide (IVCY) are recommended.<sup>3,4</sup> However, some patients are refractory or dependent on these drugs, and the additional immunosuppressive therapy in such cases has been debated, with plasma exchange (PEX) and other therapies having been selected. Recently, the efficacy of tofacitinib (TOF), a Janus kinase (JAK) inhibitor, has been reported.<sup>5,6</sup>

Here, we describe a case of a 50-year-old woman with anti-MDA5 Ab-positive DM who became dependent on triple therapy and achieved remission with the addition of peficitinib, a JAK inhibitor.

## Case report

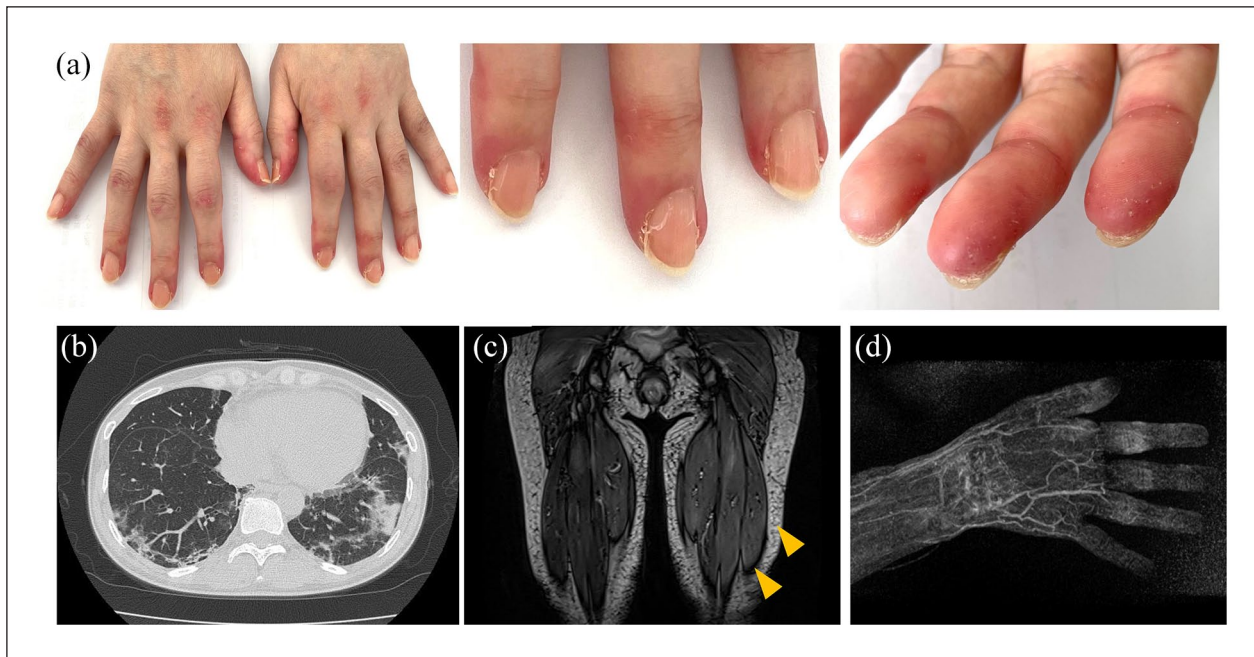
A 50-year-old woman became aware of eczema on her fingers 1 month before admission, which worsened within a week and arthralgia appeared. She visited a local dermatologist, but the rash was treated only with topical medications. One month later, she had sudden anorexia

Nephrology Center and Department of Rheumatology, Toranomon Hospital Kajigaya, Kawasaki, Kanagawa, Japan

### Corresponding Author:

Yuki Oba, Nephrology Center and Department of Rheumatology, Toranomon Hospital Kajigaya, 1-3-1, Takatsu, Kawasaki 212-0015, Kanagawa, Japan.  
Email: pugpug.yuki008@gmail.com





**Figure 1.** Physical and imaging findings at the time of her admission. (a) Photographs of her hands and fingers. They show Gottron's sign and reverse Gottron's sign, periungual erythema, and pre-ulcerative lesion of fingertips. (b) Computed tomography images of the chest. Reticular shadows in bilateral lower lobes, just below the pleura, and around bronchovascular bundles, a decrease in the volume of the bilateral lower lungs, and multiple consolidations were shown. (c) The non-contrast MRI of the lower extremities. Her left semitendinosus and biceps femoris showed high intensity in short T1 inversion recovery (STIR) (yellow arrowhead). (d) Maximum intensity projection (MIP) imaging using slice-stacking contrast-enhanced magnetic resonance imaging (MRI) of her right hand. Her PIP, MCP, and wrist joints are enhanced and imply the presence of synovitis.

and persistent low-grade fever around  $37.5^{\circ}\text{C}$ , so she was referred to our hospital. Her laboratory tests uncovered her hepatic dysfunction: aspartate aminotransferase (AST) 1160 U/mL and alanine aminotransferase (ALT) 393 U/mL. She was admitted to the Department of Gastroenterology in our hospital for a thorough examination of hepatic dysfunction and other conditions. After admission, computed tomography (CT) images showed abnormal findings in her lung and the respiratory physician suspected collagen disease-related ILD and she was referred to the Department of Rheumatology.

She had no specific medical history or comorbidities. She did not have any viral infections before her hospitalization. There was no family history of collagen disease. She had no regular medications. She had no allergy and drank about 500 mL of wine daily and had no smoking history.

On admission to the Department of Rheumatology, the patient was 160 cm tall and weighed 46.7 kg. She showed normal blood pressure of 127/88 mmHg, heart rate of 83 beats per minute, her body temperature was  $36.7^{\circ}\text{C}$ , and her oxygen saturation was 98% on ambient air. The photographs of her hands and fingers are shown in Figure 1(a). She complained of pain in the joints and fingertips of her fingers and showed Gottron's signs, reverse Gottron's signs, and periungual erythema. Swelling and tenderness of metacarpophalangeal joints and wrist joints were also observed. Muscle

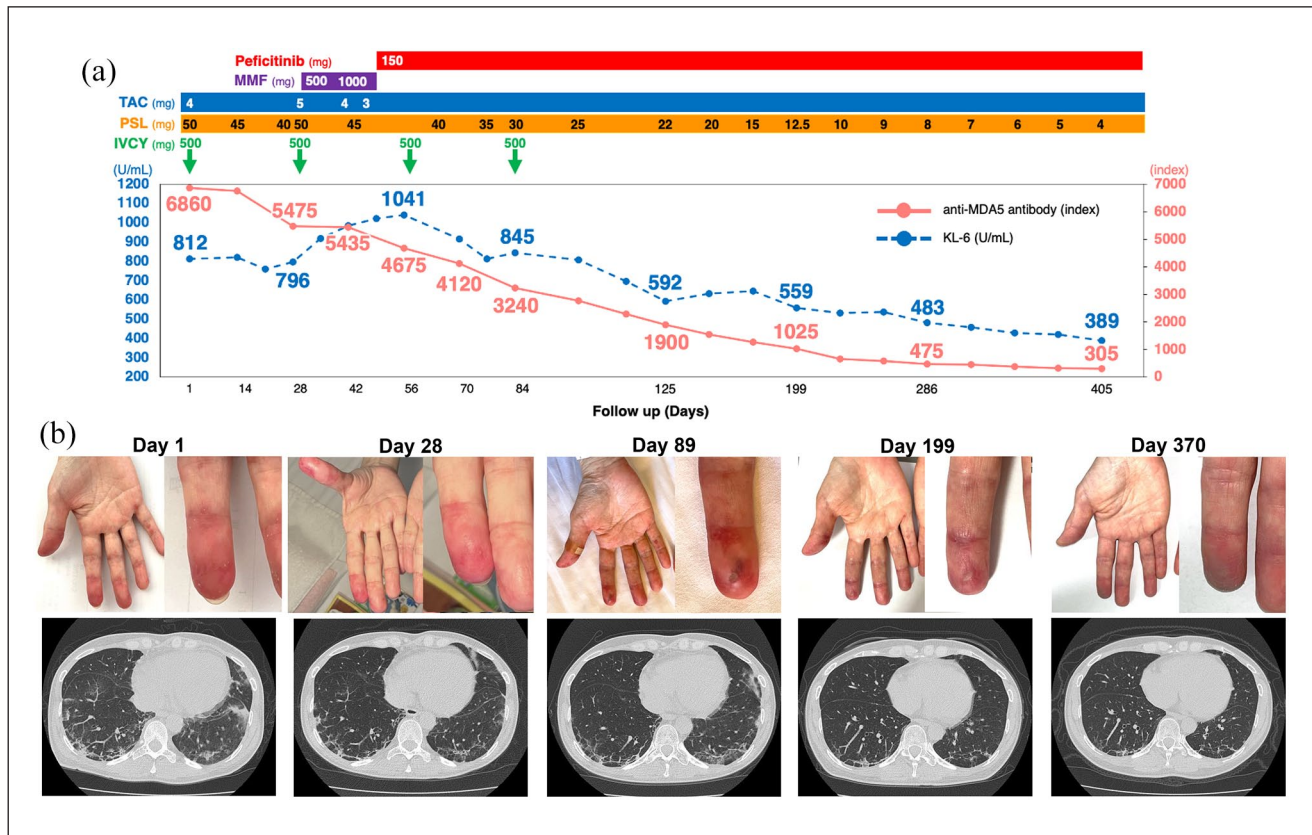
weakness and myalgia were not observed and the manual muscle testing (MMT) by our neurologist was normal in all muscles, but she had difficulty gripping and picking things due to pain.

Results of laboratory tests are shown in Table 1. Her creatinine kinase and aldolase levels were slightly elevated, respectively (156 and 12.9 IU/L); her ferritin level was 59 IU/L. Anti-nuclear autoantibodies are all negative. The myositis-specific autoantibodies were negative except for anti-MDA5 Ab (6860 indexes). Her chest CT images are shown in Figure 1(b), which indicated the non-specific interstitial pneumonia (NSIP) with organizing pneumonia variant. Artery blood gas analysis showed ventilation-perfusion mismatch (alveolar-arterial oxygen difference; 14.75 Torr). Her spirometry analysis showed that the diffusing capacity of the lung for carbon monoxide (DLCO) had dropped to 58%. The non-contrast magnetic resonance imaging (MRI) of the lower extremities is shown in Figure 1(c). Her right vastus lateralis and left semitendinosus and biceps femoris showed high intensity in short T1 inversion recovery (STIR). Muscle-skeletal echography showed high-power Doppler and maximum intensity projection (MIP) imaging using slice-stacking contrast-enhanced MRI of her right hand enhanced and imply the presence of synovitis on her proximal interphalangeal, metacarpophalangeal, and wrist joints (Figure 1(d)).

**Table 1.** Results of laboratory tests at admission to Department of Rheumatology.

Laboratory values, unit	Patient result	Reference range
<b>Blood biochemistry</b>		
Total protein, g/dL	6.6	6.6–8.1
Albumin, g/dL	3.0	4.1–5.1
AST, U/L	103	13–30
ALT, U/L	63	7–13
LDH (IFCC), U/L	206	124–222
ALP (IFCC), U/L	202	38–113
γGTP, U/L	340	9–32
Bilirubin, total, mg/dL	0.5	<1.5
Urea nitrogen, mg/dL	6	8.0–20.0
Creatinine, mg/dL	0.44	0.46–0.79
Uric acid, mg/dL	1.9	2.6–7.0
Sodium, mmol/L	141	138–145
Potassium, mmol/L	2.8	3.6–4.8
Chloride, mmol/L	103	101–108
Creatinine kinase, IU/L	156	41–153
Aldolase, IU/L	12.9	2.7–7.5
Erythrocyte sedimentation rate, mm/h	35	3–15
CRP, mg/dL	0.02	<0.14
Ferritin, IU/L	59	5–120
KL-6, IU/mL	812	<500
SP-D, ng/mL	60.8	<110
SP-A, ng/mL	81	<43.8
IgG, mg/dL	1719	861–1747
IgA, mg/dL	231.7	93–393
IgM, mg/dL	142.9	50–269
CH50, IU/L	34	31–58
Complement C3, IU/L	82	73–138
Complement C4, IU/L	6	11–31
Anti-nuclear antibodies (IF), titers	1:80, Speckled	<1:40
Anti-double-stranded DNA antibodies, IU/mL	<1.0	<10.0
Rheumatoid factor, IU/mL	4	0–15
Anti-CCP antibody, IU/mL	1.0	<4.5
PR3-ANCA, IU/mL	<0.5	<2.0
MPO-ANCA, IU/mL	<0.5	<3.5
Anti-MDA5 antibody, index	6860	<32
<b>Complete blood count</b>		
WBC count, $\times 10^9/\mu\text{L}$	29	4–11
Hemoglobin, g/dL	8.5	12.0–16.0
Hematocrit, %	28.7	35.1–44.4
Platelet count, $\times 10^3/\mu\text{L}$	245	120–450
Hemoglobin A1c, %	5.8	4.0–5.6
<b>Arterial blood gas test, for room air</b>		
pH	7.48	7.36–7.44
PaCO <sub>2</sub> , Torr	37	36–44
PaO <sub>2</sub> , Torr	89	80–100
HCO <sub>3</sub> <sup>-</sup> , mmol/L	27	22–28
SaO <sub>2</sub> , %	97.8	94–98
A-aDO <sub>2</sub> , Torr	14.75	

AST: aspartate aminotransferase; ALT: alanine aminotransferase; LDH: lactate dehydrogenase; ALP: alkaline phosphatase; γGTP: gamma-glutamyl transpeptidase; CRP: C-reactive protein; KL-6: Krebs von den Lungen-6; SP-D/A: pulmonary surfactant protein-D/A; Ig: Immunoglobulin; CH50: 50% hemolytic unit of complement; CCP: cyclic citrullinated peptide; PR3: proteinase-3; MPO: myeloperoxidase; ANCA: antineutrophil cytoplasmic antibody; WBC: white blood cell; IFCC: International Federation of Clinical Chemistry and Laboratory Medicine.



**Figure 2.** Therapeutic intervention and clinical course of treatment. (a) The numbers displayed on the horizontal axis represent days. Triple therapy was started on day 1. The dose of PSL was reduced by 5 mg every 2 weeks. The dose of PSL reached 40 mg daily on day 26. Her skin lesions became worsened and the dose of PSL elevated up to 50 mg daily on day 33 and continued for 2 weeks. Peficitinib was started on day 49 and continues to the present. IVCY was administered on day 1, 31, 59, and 87 (PSL: prednisolone; TAC: tacrolimus; IVCY: intravenous cyclophosphamide; MMF: mycophenolate mofetil). (b) Transition of skin lesions and chest CT images from admission to 1 year after treatment. They improved over time.

Her clinical course of treatment is shown in Figure 2. Based on the clinical findings described above, we diagnosed her with anti-MDA5 Ab-positive DM and started triple therapy; PSL for 1 mg/kg/day (50 mg daily), tacrolimus at an initial dose of 4 mg daily, aiming for a trough value of around 10 ng/mL, and IVCY for every 4 weeks. We reduced the dose of PSL by 10% every 2 weeks.

Her treatment seemed to be going well, but on day 26, when the dose of PSL reached 0.8 mg/kg/day (40 mg daily), skin lesion of her fingertips worsened, and antihelix/helix violaceous macules newly emerged on both her ears. We redose PSL up to 50 mg daily, and also increased tacrolimus to exceed the target trough level 10 ng/mL, but her Krebs von den Lungen-6 (KL-6) elevated and the titer of anti-MDA5 Ab stopped decreasing at the 5435 indexes. To control the disease, we then added mycophenolate mofetil (MMF) to triple therapy on day 33, but no improvement of the skin lesion and no reduction of these markers were observed after 2 weeks.

As mentioned earlier, she had synovitis on some joints of her finger and wrist. This synovitis resembles that of

rheumatoid arthritis (RA); we considered the possibility that treatment as seronegative RA might be effective. So, after we explained enough and obtain the patient's written consent, we decided to stop MMF and administer peficitinib at 150 mg daily on day 47. After that, findings of her skin were improving gradually, and the titer of anti-MDA5 Ab also decreased more remarkably than before the addition of peficitinib. The titer of anti-MDA5 Ab and KL-6 continued to drop even though the PSL had been tapering and IVCY was completed in four times as indicated by the green arrow in Figure 2. When the dose of PSL reached 30 mg, she was discharged from the hospital and continued her outpatient visit. One year later, although anti-MDA5 Ab remains, the titer of the antibody decreased to 325 indexes, and she is currently in remission with the only oral treatment of PSL 5 mg daily, tacrolimus 3 mg daily, and peficitinib 150 mg daily. The skin lesion and the pain in her fingers disappeared, and her grip strength improved to the point where she could open the lid of a plastic bottle. Her interstitial pneumonia has not worsened.

## Discussion

Anti-MDA5 Ab-positive DM is characteristic with its amyopathic DM, skin manifestation, and RP-ILD. It is myositis with a poor prognosis, and the antibody positivity, hyperferritinemia, and high titer of the antibody are poor prognostic factors.<sup>1,2</sup> So intensive immunosuppressive regimen, the combination of high-dose glucocorticoids, oral CNIs, and IVCY pulse, is recommended.<sup>3</sup> However, the titer of her anti-MDA5 Ab at the time of diagnosis was 6860 indexes, which predicted a very poor prognosis, but her ferritin was low level and the progression of ILD was slow in this case. Allenbach et al.<sup>7</sup> reported that among patients with anti-MDA5 Ab-positive DM, a cluster of women with arthritis existed to have a good prognosis for life, and she seemed to be in this cluster. Recently, Gono et al.<sup>8</sup> also reported that there is a cluster that includes patients with Anti-MDA5 Ab-positive clinically amyopathic DM who did not require oxygen, whose C-reactive protein (CRP) was negative, and whose KL-6 was mildly elevated. The cumulative survival rate of the patients in this cluster was not poorer than those in the cluster of RP-ILD whether they were receiving triple or dual therapy.

Based on these reports, the life prognosis for this case might not be poor and triple therapy was not always necessary. However, in this case, the problem was that the skin manifestation could not be completely suppressed even with triple therapy and was worsened by PSL reduction. Residual skin manifestation means that disease activity remains and may affect her prognosis and quality of life. Our patient was still dependent on high-dose PSL as described. We needed other immunosuppressant options to taper off PSL.

It is still an ongoing issue how to treat patients with anti-MDA5 Ab-positive DM that is refractory to triple therapy. To treat such patients, various methods such as intravenous immunoglobulins (IVIg), rituximab, or PEX have been used. Recently, some studies have reported the efficacy of TOF, JAK inhibitor.<sup>5,6</sup> For example, Hosokawa and Oiwa<sup>6</sup> reported that a patient whose ILD worsened even after triple therapy and PEX achieved remission with the addition of TOF. Compared to other idiopathic inflammatory muscle diseases, DM has been reported to have significantly elevated expression of type I interferon genes.<sup>9</sup> In particular, the expression of type I interferon is significantly higher in anti-MDA5 Ab-positive DM, and the skin lesions of patients with anti-MDA5-positive DM show higher expression of myxovirus resistance protein A (MxA), an interferon-induced protein.<sup>10,11</sup> MDA5 is an innate immunity-associated protein that detects viral RNA and activates, amplifies, and induces type I interferon, which is consistent with these findings.<sup>12</sup> The function and underlying mechanism of the anti-MDA5 antibody remain unclear in the pathological process of DM. As Sato et al.<sup>13</sup> reported, the increase in MDA5 antibodies might be a secondary change for the increase in MDA5, the treatment that suppresses type I interferon rather than

antibody removal may be effective in this disease, and JAK inhibitors, which block the JAK-STAT pathway activated by type I interferon, have the potential to be that treatment option.

In this case, we selected peficitinib as an additional treatment, which is the third JAK inhibitor approved in Japan. Peficitinib inhibits more JAK families than other JAK inhibitors. As Choy<sup>14</sup> reported, TOF shows selectivity for JAK1 and JAK3, while peficitinib shows selectivity for JAK1, JAK2, JAK3, and non-receptor tyrosine-protein kinase 2 (TYK2). Moreover, the concentration needed to inhibit 50% (IC50) of JAK isoforms activation of peficitinib is lower than that of TOF for all JAK isoforms. In particular, inhibiting TYK2 is thought to suppress type I interferon and may be more effective for the pathogenesis of anti-MDA5 Ab-positive DM. Peficitinib is also easy to use for a variety of reasons. Peficitinib is taken once a day, but TOF has a short elimination half-life and needs to be taken twice a day, suggesting that peficitinib is more adherent to medication. Although TOF is recommended to reduce a dose for moderate and severe renal dysfunction, peficitinib does not require a dose reduction. From the time she started using this drug to the present, she has had no adverse events.

## Conclusion

We showed that peficitinib has the potential to be another additional option for anti-MDA5 Ab-positive DM dependent on triple therapy and refractory to glucocorticoid reduction. We should have many treatment options to help the patients with this disease. We expect that our case report triggered the further discussion and research for the molecular mechanisms of JAK inhibitors in the future.

## Author contributions

Yuki Oba: Investigation, Data Curation, Writing-Original draft, Visualization. Masayuki Yamanouchi: Investigation, Resources, Writing-Review & Editing, Supervision. Daisuke Ikuma, Hiroki Mizuno, Noriko Inoue, Akinari Sekine, Eiko Hasegawa, Tatsuya Suwabe: Resources. Naoki Sawa: Conceptualization, Resources, Writing-Review & Editing, Project administration. Yoshifumi Ubara: Writing-Review & Editing.

## Availability of data and materials

Further clinical data and images of this case are available from the corresponding author upon reasonable request.

## Declaration of conflicting interests

The author(s) declared no potential conflicts of interest with respect to the research, authorship, and/or publication of this article.

## Funding

The author(s) received no financial support for the research, authorship, and/or publication of this article.

### Ethical approval and consent to participate

This study was performed following the Declaration of Helsinki and its revisions. The authors declare that informed, voluntary, and written consent for publication was obtained from the patient described in the article.

### Informed consent

Written informed consent was obtained from the patient(s) for their anonymized information to be published in this article.

### ORCID iD

Yuki Oba  <https://orcid.org/0000-0002-1494-3291>

### References

- Gono T, Kawaguchi Y, Satoh T, et al. Clinical manifestation and prognostic factor in anti-melanoma differentiation-associated gene 5 antibody-associated interstitial lung disease as a complication of dermatomyositis. *Rheumatology* 2010; 49(9): 1713–1719.
- Sato S, Masui K, Nishina N, et al. Initial predictors of poor survival in myositis-associated interstitial lung disease: a multicentre cohort of 497 patients. *Rheumatology* 2018; 57: 1212–1221.
- Nakashima R, Hosono Y and Mimori T. Clinical significance and new detection system of autoantibodies in myositis with interstitial lung disease. *Lupus* 2016; 25(8): 925–933.
- Romero-Bueno F, Diaz Del Campo P, Trallero-Araguás E, et al. Recommendations for the treatment of anti-melanoma differentiation associated gene 5-positive dermatomyositis-associated rapidly progressive interstitial lung disease. *Semin Arthritis Rheum* 2020; 50(4): 776–790.
- Kurasawa K, Arai S, Namiki Y, et al. Tofacitinib for refractory interstitial lung diseases in anti-melanoma differentiation-associated 5 gene antibody-positive dermatomyositis. *Rheumatology* 2018; 57: 2114–2119.
- Hosokawa Y and Oiwa H. A case of refractory interstitial lung disease in anti-MDA5-positive dermatomyositis that improved after switching to tofacitinib. *J Clin Rheumatol* 2021; 27: S661–S662.
- Allenbach Y, Uzunhan Y, Toquet S, et al. Different phenotypes in dermatomyositis associated with anti-MDA5 antibody: study of 121 cases. *Neurology* 2020; 95: e70–e78.
- Gono T, Masui K, Sato S, et al. Mortality risk stratification using cluster analysis in patients with myositis-associated interstitial lung disease receiving initial triple-combination therapy. *Front Med* 2022; 9: 883699.
- Greenberg SA. Dermatomyositis and type 1 interferons. *Curr Rheumatol Rep* 2010; 12(3): 198–203.
- Ono N, Kai K, Maruyama A, et al. The relationship between type 1 IFN and vasculopathy in anti-MDA5 antibody-positive dermatomyositis patients. *Rheumatology* 2019; 58: 786–791.
- Okiyama N, Yamaguchi Y, Kodera M, et al. Distinct histopathologic patterns of finger eruptions in dermatomyositis based on myositis-specific autoantibody profiles. *JAMA Dermatol* 2019; 155: 1080–1082.
- Dias Junior AG, Sampaio NG and Rehwinkel J. A balancing act: MDA5 in antiviral immunity and autoinflammation. *Trends Microbiol* 2019; 27: 75–85.
- Sato S, Hoshino K, Satoh T, et al. RNA helicase encoded by melanoma differentiation-associated gene 5 is a major autoantigen in patients with clinically amyopathic dermatomyositis: association with rapidly progressive interstitial lung disease. *Arthritis Rheum* 2009; 60: 2193–2200.
- Choy EH. Clinical significance of Janus Kinase inhibitor selectivity. *Rheumatology* 2019; 58: 953–962.