

Received: 2018.05.30  
Accepted: 2018.10.14  
Published: 2019.02.18

# Bullous Pemphigoid with Atypical Skin Lesions and Acute Interstitial Nephritis: A Case Report and Focused Literature Review

Authors' Contribution:  
Study Design A  
Data Collection B  
Statistical Analysis C  
Data Interpretation D  
Manuscript Preparation E  
Literature Search F  
Funds Collection G

ABCDEF 1 **Bindu Ganapathineedi**  
ABCDEF 1 **Alaap Mehta**  
EF 1 **Susmitha Dande**  
B 2 **Anjali Shinde**  
BDE 1 **Gary Barsky**  
ABCDEFG 1 **Nadew Sebro**

1 Department of Internal Medicine, Mount Sinai Hospital, Chicago, IL, U.S.A.  
2 Department of Pathology, Mount Sinai Hospital, Chicago, IL, U.S.A.

**Corresponding Author:** Nadew Sebro, e-mail: [nadew@post.harvard.edu](mailto:nadew@post.harvard.edu)  
**Conflict of interest:** None declared  
**Source of support:** This work was supported in part by a grant from the Everest Foundation to Graduate Medical Education Training, Research and Innovation Program (GME TRIP) of Mount Sinai Hospital, Chicago

**Patient:** Male, 76  
**Final Diagnosis:** Drug induced bullous pemphigoid  
**Symptoms:** Skin rash  
**Medication:** Cephalexin  
**Clinical Procedure:** Skin biopsy  
**Specialty:** General and Internal Medicine





**Objective:** Unusual clinical course  
**Background:** The hallmark of bullous pemphigoid (BP) is widespread tense blisters arising on normal or erythematous skin, often with marked pruritus, the diagnosis of which is confirmed by direct immunofluorescence (DIF). BP is an autoimmune process that can be induced, though rarely, by medications. Drug-induced BP often has atypical clinical presentation, which requires a good understanding of other dermatological conditions with similar presentations, in particular, bullous subtype of erythema multiforme. End organ involvement warrants differentiating it from one of the severe cutaneous adverse reaction (SCAR) syndromes.

**Case Report:** A 76-year-old African American male presented with extensive targetoid purplish skin lesions that clinically resembled atypical erythema multiforme, and one tense blister that raised a concern for BP. The patient presented 6 weeks after treatment with cephalexin for a urinary tract infection. Initial workup showed serum eosinophilia, acute kidney injury and eosinophiluria requiring deliberations on SCAR syndromes. A skin biopsy at an intralesional location showed a negative DIF, however, a skin biopsy at a perilesional site showed a positive DIF, confirming the diagnosis of BP.

**Conclusions:** This case demonstrates an atypical presentation of BP induced by drugs. It emphasizes the need for a greater level of awareness of diagnosis and treatment of the various entities that fall under adverse drug reactions in the elderly. It also highlights the need for appropriate choice of skin biopsy techniques (intralesional versus perilesional) to avoid misdiagnosis, as well as lessons on how to approach dermatologic conditions with end organ involvement for hospitalists and other medical professionals who routinely deal with undifferentiated disease conditions.

**MeSH Keywords:** Drug Hypersensitivity Syndrome • Drug-Related Side Effects and Adverse Reactions • Erythema Multiforme • Hypereosinophilic Syndrome • Nephritis, Interstitial • Pemphigoid, Bullous

Full-text PDF: <https://www.amjcaserep.com/abstract/index/idArt/911422>

 2722   5  42



## Background

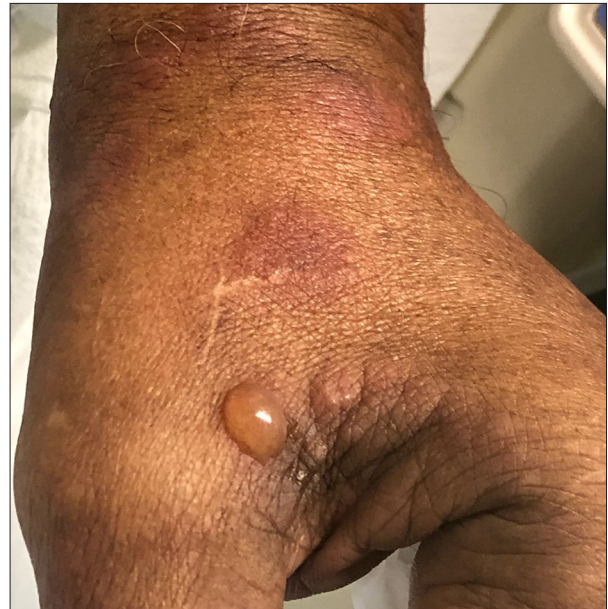Bullous pemphigoid (BP) is an autoimmune subepidermal blistering disease that clinically presents with tense bullae with widespread erythema primarily in the elderly population. It is often idiopathic, but may be associated with malignancy, medications, and rarely, other autoimmune disorders [1]. Its pathophysiology is mediated by autoantibodies to antigens on hemidesmosomes that attach epithelial cells to underlying basement membrane. Diagnosis is based on direct immunofluorescence (DIF) study on skin biopsy samples that confirms the presence of immunoglobulins and complements in the epidermal basement membrane zone and other serological tests. Drug-induced BP, however, tends to have an atypical clinical presentation that poses a diagnostic challenge [2], such as was the case for this patient, who required a repeat skin biopsy due to our high degree of clinical suspicion.

This patient case peaked our interest for an academic discussion because it embodied a unique set of challenges faced by those in medical disciplines who routinely deal with undifferentiated disease conditions such as those who practice in internal medicine, family medicine, and emergency medicine [3]. This is acutely relevant for hospitalists, since most dermatologic conditions are managed in outpatient settings depriving them of exposure to a wider range of dermatologic conditions. In the inpatient setting, hospitalists are often the ones who will first encounter these cases, diagnose, determine illness severity, and initiate therapy and consultations.

The clinical care in this case was surrounded with dilemmas. The initial therapeutic dilemma was inpatient versus outpatient care, since it was not clear if the presence of just one small active bullous lesion (Figure 1) on presentation should warrant a higher-level of concern for potentially life-threatening skin disorders. After an inpatient admission, the second diagnostic dilemma was triggered by the presence of multiple potential etiologies on further history and workup, including a positive syphilis serology and patient use of multiple medications. Third, further workup also showed the presence of systemic eosinophilia (serum eosinophilia, eosinophiluria, and eosinophilic infiltration of the dermis) with end organ involvement (acute kidney injury), which raised the question of the role of eosinophils either as a primary hematologic disorder with a different prognosis or a relatively benign secondary marker of another etiology.

## Case Report

A 76-year-old African American male nursing home resident presented to the emergency department with a diffuse rash and worsening renal function of 3 weeks duration. His past

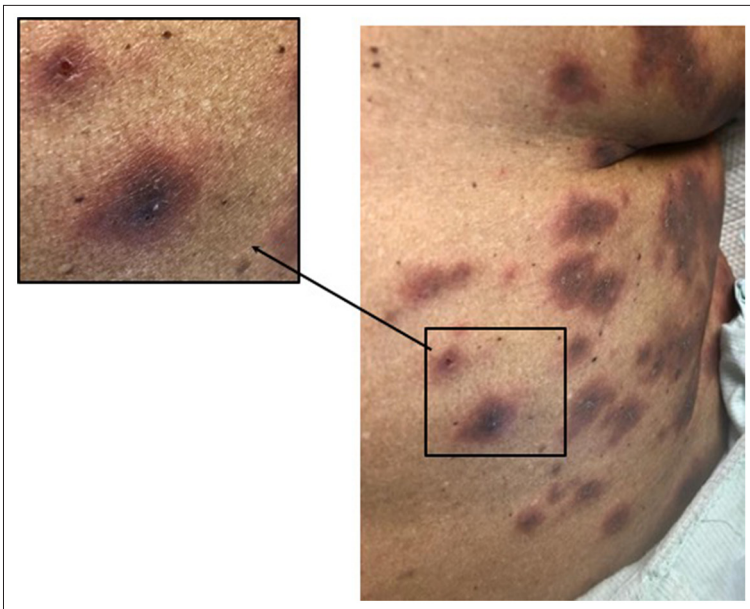


**Figure 1.** A single tense blister on the dorsal left hand, with minimal surrounding erythema.

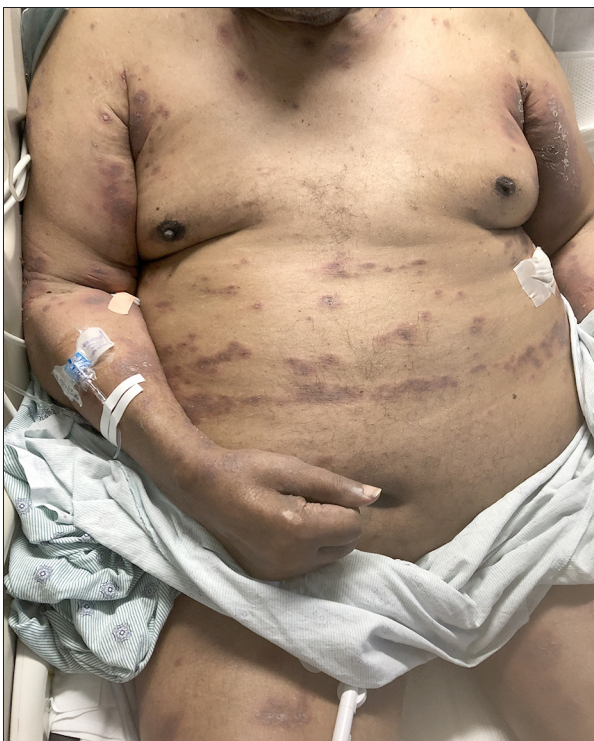medical history included hypertension, diabetes mellitus type II, chronic kidney disease stage 2, treated secondary syphilis, and a prior ischemic stroke. The pruritic rash was first noticed on his lower back and gradually spread to his upper and front parts of his trunk and extremities. The rash was reported to include “pockets of fluids” initially, but bulla was only visible only at one location (Figure 1) on presentation. The patient denied any sores or blisters in his mouth. He was treated with cephalexin for 7 days for a urinary tract infection 6 weeks prior to admission. His list of preadmission medications included losartan, metformin, gabapentin, atorvastatin, tolterodine, and aspirin.

On physical examination, the patient was afebrile with stable vital signs. There was a mix of purplish discrete and confluent targetoid macules (Figure 2) and diffuse plaques, which were symmetrically distributed on the trunk, arms, legs, palms, and soles (Figures 3, 4). The distribution spared the face and oral mucous membranes. There was a single tense blister on the dorsal left hand, with minimal surrounding erythema (Figure 1). The targetoid lesions were partially blanching, non-palpable, non-tender, with a darker central area and scaling in some cases, which appears to be a secondary change after the rupture of blisters (Figure 2).

Pertinent initial laboratory findings include: total white cell count of 9700 cells/mL with eosinophilia 11.0%, absolute eosinophil count (AEC) of 1200 cells/mL, serum creatinine of 2.1 mg/dL (increased from a baseline of 1.3 mg/dL), and urine Hansel’s stain showed presence of 4.3% eosinophils. Serology showed rapid positive plasma reagin (RPR) with 1:4 titers and a reactive T. pallidum microhemagglutination assay (MHA-TP).



**Figure 2.** Atypical purplish targetoid lesions comprising discrete macules with central darkening and confluent patches. The shallow central ulcerations and scaling in some appear to be a secondary change after the rupture of blisters.

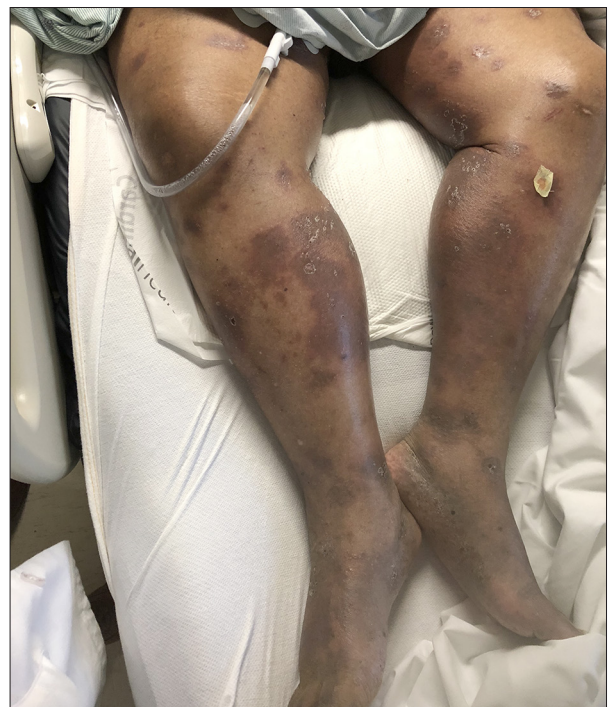

**Figure 3.** Symmetrical involvement the arms and trunk by a mix of diffuse plaque and discrete targetoid macules.

A detailed further infectious disease and autoimmune serology workup was unremarkable.

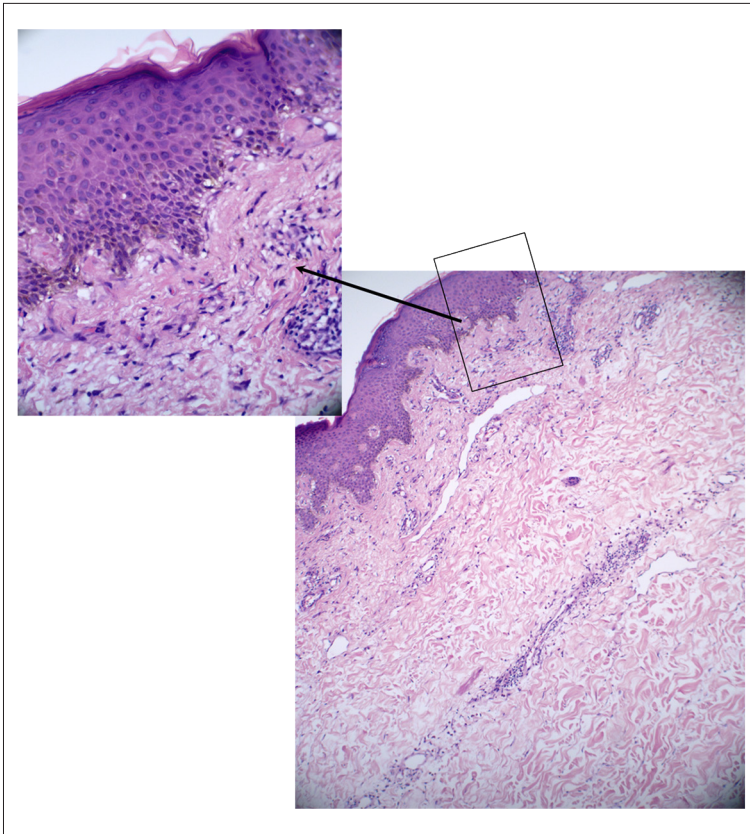
#### **Punch biopsy**

Epidermis showed mild spongiosis and interface vacuolar changes. The dermal venules were dilated and contained



**Figure 4.** Symmetrical involvement the lower extremities, including plantar surfaces, by a mix of diffuse plaque and discrete targetoid macules.

neutrophils. Inflammatory infiltrate composed of lymphocytes, neutrophils, and eosinophils were present in the dermis. There was focal vacuolar alteration of the basal cell layer. There were also necrotic keratinocytes, mild superficial, and mid dermal perivascular inflammatory cell infiltrate containing frequent eosinophils and dilated vessels (Figure 5).



**Figure 5.** Histologic sections of skin biopsy showing changes involving all skin layers, including superficial necrotic keratinocytes, epidermal spongiosis, vacuolar changes at the interface, and basal cell layer, along with dilated dermal venules with inflammatory infiltrate composed of lymphocytes, neutrophils and eosinophils.

### Direct immunofluorescence (DIF) (performed twice)

DIF on intralesional biopsy was negative for fibrinogen, C1q, C3, IgA, IgM, and IgG within the epidermis, at the dermal epidermal junction and around the dermal blood vessels. However, on a perilesional biopsy, stains for C3 and IgG showed linear positivity of the basement membrane zone. DIF stain for fibrinogen showed nonspecific staining. Stains for IgM, IgA, and C1q were negative.

### Hospital course

The patient was started on oral prednisone, topical clobetasol (clobetasol propionate 0.05% cream), and oral diphenhydramine. The skin lesions showed clinical improvement after 36 hours; however, serum eosinophilia increased from an initial 11.0% to 22.4% with an AEC increase from 1200 cells/mL to 3423 cells/mL. Treatment with topical and systemic steroids was continued and the patient was discharged improved. On a 10-day post-discharge clinic follow-up visit, there was a significant improvement in the skin lesions and resolution of eosinophilia and acute kidney injury.

### Discussion

This discussion, with the benefit of hindsight, outlines a general approach framework and delves deeper into relevant diagnostic and treatment topics in a focused literature review format.

### Broad differentials

The differential diagnosis for a combination of skin lesions and serum eosinophilia encompasses a wide range of diseases, including allergy or hypersensitivity, parasitosis, fungal infections, neoplasm or hyperplastic disorders, HIV-related eruptions, cutaneous vasculitis, autoimmune blistering skin disorders, pregnancy-related disorders, pediatric specific disorders, and other systemic diseases [4,5]. The overwhelming majority of eosinophilic dermatoses epidemiologically, however, lie in the allergy related group, which includes allergic drug eruption, urticaria, allergic contact dermatitis, atopic dermatitis, and eczema [5,6].

Allergic drug eruptions, also referred to as “drug allergy” or adverse drug reactions (ADR), comprise various entities. Thus, reaching at a specific diagnosis required familiarity with the various disease entities and classifications under ADR. Of note, ADR should not be confused with the broader concept of adverse drug events (ADE) which, in addition to ADR, includes

other non-pharmacologic events like inappropriate use of drugs and medication administration errors [7,8].

### **Dermatologic manifestations of drug allergy**

The most common types of ADR are referred to as type-A reactions and occur directly due to the pharmacologic action of a drug [9]. However, most drug-related dermatologic conditions, such as in this patient case, are due to ADR and belong to its type-B subcategory referred to as drug hypersensitivity reactions (DHR) [9]. Type B reactions are not related to the known pharmacologic action of the drug. Their underlying mechanisms are not entirely understood but are often mediated through immunologic reactions to an otherwise safe and effective therapeutic agent and are often associated with high mortality [7,8,10].

Clinically, DHR are classified as immediate, typically <1 hour following the last intake of the culprit drug, or delayed-type DHR (DTH), typically >1 hour to days after the start of a treatment with the culprit drug [9,11,12]. This patient presented 2 months after a course of cephalexin, most likely fitting delayed DHR timeline [12]. On the other hand, to correlate clinical presentations with underlying immune mechanism, drug hypersensitivity, and other immune reactions are frequently classified into 4 categories described by Coombs and Gell in 1963 [9]. It is important to note that each of the 4 hypersensitivity class types have their own dermatologic clinical manifestations, although some reports find the classification limiting and not comprehensive enough [13–15].

ADR can virtually affect any organ, but skin, liver, and blood cells are the most common targets [16]. The clinical spectrum of ADR dermatologic manifestations ranges from fixed drug eruption (FDE), maculopapular eruption (MPE), general exfoliative dermatitis or erythroderma, drug reaction with eosinophilia, and systemic symptoms (DRESS syndrome), acute generalized exanthematous pustulosis (AGEP), Stevens-Johnson syndrome (SJS), toxic epidermal necrolysis (TEN), other bullous reactions mimicking pemphigus vulgaris and bullous pemphigoid up to vasculitis [11,12].

One of the first tasks in the management of this patient was ruling out potentially life-threatening ADRs. Among the dermatologic manifestations of ADR, 4 entities with high mortality rate belong to a class referred to as severe cutaneous adverse reactions (SCAR): SJS, TEN, AGEP, and DRESS [17]. Studies show that SJS and TEN, do not usually produce eosinophilia, but rather neutrophilia and lymphocytopenia [18]. Furthermore, although AGEP and DRESS present with eosinophilia, AGEP does not typically involve end organs [19]. DRESS syndrome was strongly entertained as a possibility in this patient, as it is characterized by multi-systemic involvement and frequent

eosinophilia. Nonetheless, although this patient had significant eosinophilia, end organ involvement, and body surface area involvement >50%; the absence of fever, lymphadenopathy, protracted resolution of rash >15 days and lack of characteristic biopsy features of the syndrome has made DRESS unlikely with a RegiSCAR-Group Diagnosis Score of 1 (no case) [17].

After excluding SCAR, the next differential diagnosis considered among ADR was bullous pemphigoid (BP), given the presence of tense bulla.

### **Erythema multiforme (EM)-like BP versus bullous EM**

This patient presented with skin lesions that were predominantly purplish erythema and only one blister (Figures 1–4). It was a dilemma whether the presence of a single blister should raise a possibility of a bullous disorder. Furthermore, the purplish erythema had central darkening that gave it a targetoid appearance, which, at best, clinically resembled atypical erythema multiforme (EM) (Figure 2).

BP and EM represent 2 separate groups of pathologies; nonetheless several reports [20–23] have documented that the clinical diagnosis of BP can be challenging when EM-like lesions are present, such as in this patient case.

The hallmark of BP is widespread tense blisters arising on normal or erythematous skin in an elderly person, often with marked pruritus confirmed by DIF and histology [1]. Several clinical variants have been described, including classic (bullous), localized, nodular, vegetating, erythrodermic, erosive, childhood, and drug-induced forms [1]. On the other hand, EM, which also can present as different subtypes (major, minor, recurrent, bullous and persistent) is generally diagnosed clinically with its polymorphous eruption of macules, papules, and characteristic target lesions that are symmetrically distributed with or without mucosal involvement [24]. Cutaneous manifestations of EM evolve over the course illness and vary widely [25].

The typical lesions for EM are target lesions, which are annular and red or purple with an iris configuration, that are symmetrically distributed with a propensity for the distal extremities and subsequently spread in a centripetal manner [24]. The characteristic feature is that the central area, which is slightly raised and cyanotic, is more involved than the periphery, hence the name target lesions. When the degree of damage to the skin is greater, the center of the target lesion becomes a vesicle or a bulla [26].

The correct clinical identification of BP from EM becomes difficult when BP is caused by a drug reaction. BP, in general, is usually idiopathic but may be associated with malignancy, medications, and rarely autoimmune disorders [2]. The drug-induced bullous

pemphigoid subtype, compared to its idiopathic counterparts, is known to be difficult to diagnose clinically due to its EM like targetoid lesions [20,27,28]. Similarly, unlike other subtypes of EM, bullous type EM presents with multiple blisters posing a diagnostic challenge, and is most commonly associated with drug reactions, herpes simplex virus (HSV), varicella zoster virus (VZV), and rarely with mycoplasma pneumoniae infections [29,30].

The etiologic and clinical overlap between the 2 entities – EM-like BP and bullous EM – also carries over to a histological level. It is generally considered that BP and EM cannot be distinguished on the basis of histological features alone [31]. Histologically, BP demonstrates eosinophilic spongiosis or sub-epidermal bulla with numerous eosinophils [3]. On the other hand, EM shows a significantly wider spectrum of findings with varying degree of involvement of the histologic layers of the skin and inconsistent inflammatory cell infiltrate that is often predominantly lymphocytic or eosinophilic at times [32], as seen in this patient case. The stage of the disease, site of biopsy (center versus periphery) [33], clinical subtype [32], and etiology [30], contributes to the wide spectrum of histological appearance of EM. The predominantly eosinophilic infiltrate seen in BP is not diagnostic, since significant numbers of eosinophil infiltrate were present in 60% of bullous EM and 28% of macular EM lesions in other studies [32].

Positive DIF for IgG, IgM, IgA, and C3 to confirm that bullae are due to antibody deposition at the dermo-epidermal junction, is the cornerstone test for the diagnosis of BP, along with the presence of circulating autoantibodies against hemidesmosomal molecules in select cases [1,34]. However, DIF results should be looked at closely since, according to Howland et al., positive DIF for C3 and IgM has been observed in EM [33].

An important lesson from this patient case is that unless DIF is performed with the right skin biopsy technique, it could result in a false negative finding [1], and in our patient case, we had to obtain a repeat biopsy based on our strong clinical suspicion. The biopsy site should be perilesional, as opposed to intralesional skin on the upper body within 2 cm of a bulla, or clinically uninvolved skin from the flexor aspect of a forearm or anterior thigh [1,35]. Biopsy specimen from the lower legs should be avoided because of false-negative results in up to a third of samples from this region [36,37].

### Eosinophilia from bullous pemphigoid

Lastly, this patient presented with peak AEC of 3423/mm<sup>3</sup>. Literature defines AEC >1500/mm<sup>3</sup> as hypereosinophilia, and it may be associated with secondary tissue damage just from the cytotoxic content of elevated eosinophils regardless of the etiology. Hypereosinophilia could be non-hematologic (secondary or reactive) or a primary hematologic clonal disorder [38,39].

Therefore, hypereosinophilia, paradoxically, could be the primary cause of end organ damage or just a secondary result of end organ damage from other causes. This poses a challenge to clinicians in understanding the chronology and cause-and-effect association of various diseases that present with a combination of hypereosinophilia and end organ involvement. For example, this patient presented with skin lesions, acute kidney injury, and systemic eosinophilia (serum eosinophilia, eosinophiluria, and eosinophilic infiltration of the dermis). This left us pondering whether the acute kidney injury was caused by hypereosinophilia triggered by an adverse reaction to cephalexin or acute kidney injury from interstitial nephritis induced by cephalexin caused a secondary hypereosinophilia. Literature review shows that essentially all organ systems may be susceptible to the effects of sustained eosinophilia. During follow-up of patients with hypereosinophilia, dermatologic involvement was the most common clinical manifestation reported in 69% of patients, followed by pulmonary manifestation (44%) and gastrointestinal manifestations (38%) [38,40,41].

Another important lesson here is that if this patient had not presented early to receive the appropriate therapy, the eosinophilia would have continued to increase and led to additional end organ involvement, particularly the lungs and heart. Peripheral eosinophilia is seen in up to 50% of patients with BP with a median AEC of 1300/μL [4]. If untreated, this would obviously cause morbidity and mortality from the disease, as well as from additional invasive diagnostic tests. The quick resolution of eosinophilia in this patient fits the pattern of drug allergies [18], yet a persistent level would have warranted a different approach [42]. This highlights the need for proper diagnosis and treatment of the underlying cause of hypereosinophilia as early as possible, to prevent secondary end organ damages.

### Conclusions

This report provides a showcase for the atypical presentation of drug induced BP. With a brief overview of drug reactions, it calls for higher degree of familiarity with entities under Adverse Drug Reactions by general practitioners. In addition, through a focused literature review on differences between BP and EM, it navigates the unique set of diagnostic challenges of various dermatologic syndromes with overlapping features. In particular, it highlights key features of life-threatening dermatologic conditions referred to as severe cutaneous adverse reactions (SCAR): SJS, TEN, AGEP and DRESS. It also underscores vital lessons on appropriate biopsy techniques for BP (intralesional versus perilesional) to avoid misdiagnosis and on the importance of early diagnosis and treatment of patients with hypereosinophilia.

## Department and Institution where work was done

Department of Internal Medicine, Mount Sinai Hospital, Chicago, IL, U.S.A.

## Conflicts of interest

None.

## References:

1. Walsh SR, Hogg D, Mydlarski PR: Bullous pemphigoid: From bench to bedside. *Drugs*, 2005; 65(7): 905–26
2. Iwata H, Ujiie H: Complement-independent blistering mechanisms in bullous pemphigoid. *Exp Dermatol*, 2017; 26(12): 1235–39
3. O’Riordan M, Dahinden A, Akturk Z et al: Dealing with uncertainty in general practice: An essential skill for the general practitioner. *Qual Prim Care*, 2011; 19(3): 175–81
4. Montgomery ND, Dunphy CH, Mooberry M et al: Diagnostic complexities of eosinophilia. *Arch Pathol Lab Med*, 2013; 137(2): 259–69
5. Long H, Zhang G, Wang L, Lu Q: Eosinophilic skin diseases: A comprehensive review. *Clin Rev Allergy Immunol*, 2016; 50(2): 189–213
6. Heymann WR: Eosinophilic dermatoses. *J Am Acad Dermatol*, 2006; 55(1): 114–15
7. Edwards IR, Aronson JK: Adverse drug reactions: Definitions, diagnosis, and management. *Lancet*, 2000; 356(9237): 1255–59
8. Nebeker JR, Barach P, Samore MH: Clarifying adverse drug events: A clinician’s guide to terminology, documentation, and reporting. *Ann Intern Med*, 2004; 140(10): 795–801
9. Pichler WJ: Delayed drug hypersensitivity reactions. *Ann Intern Med*, 2003; 139(8): 683–93
10. Riedl MA, Casillas AM: Adverse drug reactions: Types and treatment options. *Am Fam Physician*, 2003; 68(9): 1781–90
11. Schrijvers R, Gilissen L, Chiriac AM, Demoly P: Pathogenesis and diagnosis of delayed-type drug hypersensitivity reactions, from bedside to bench and back. *Clin Transl Allergy*, 2015; 5: 31
12. Demoly P, Adkinson NF, Brockow K et al: International consensus on drug allergy. *Allergy*, 2014; 69(4): 420–37
13. van Beek N, Schulze FS, Zillikens D, Schmidt E: IgE-mediated mechanisms in bullous pemphigoid and other autoimmune bullous diseases. *Expert Rev Clin Immunol*, 2016; 12(3): 267–77
14. Descotes J, Choquet-Kastylevsky G: Gell and Coombs’s classification: Is it still valid? *Toxicology*, 2001; 158(1–2): 43–49
15. Choquet-Kastylevsky G, Vial T, Descotes J: Drug allergy diagnosis in humans: possibilities and pitfalls. *Toxicology*, 2001; 158(1–2): 1–10
16. Uetrecht J, Naisbitt DJ: Idiosyncratic adverse drug reactions: Current concepts. *Pharmacol Rev*, 2013; 65(2): 779–808
17. Roujeau JC, Allanore L, Liss Y, Mockenhaupt M: Severe cutaneous adverse reactions to drugs (SCAR): Definitions, diagnostic criteria, genetic predisposition. *Dermatol Sinica*, 2009; 27: 203–9
18. Kovalszki A, Weller PF: Eosinophilia. *Prim Care*, 2016; 43(4): 607–17
19. Schmid S, Kuechler PC, Britschgi M et al: Acute generalized exanthematous pustulosis: Role of cytotoxic T cells in pustule formation. *Am J Pathol*, 2002; 161(6): 2079–86
20. Hirano SA, Mason AR, Harvey VM, Hood AF: Erythema multiforme-like bullous pemphigoid associated with furosemide. *J Clin Exp Dermatol Res*, 2011; 2: 123
21. Alcalay J, David M, Ingber A et al: Bullous pemphigoid mimicking bullous erythema multiforme: an untoward side effect of penicillins. *J Am Acad Dermatol*, 1988; 18(2 Pt 1): 345–49
22. Hayakawa K, Shiohara T: Atypical bullous disease showing features of both erythema multiforme and bullous pemphigoid. *Acta Derm Venereol*, 2002; 82(3): 196–99
23. Mehrovaran M, Gyulai R, Husz S, Dobozy A: Drug-induced erythema multiforme-like bullous pemphigoid. *Acta Derm Venereol*, 1999; 79(3): 233
24. Lamoreux MR, Sternbach MR, Hsu WT: Erythema multiforme. *Am Fam Physician*, 2006; 74(11): 1883–88
25. Sokumbi O, Wetter DA: Clinical features, diagnosis, and treatment of erythema multiforme: A review for the practicing dermatologist. *Int J Dermatol*, 2012; 51(8): 889–902
26. du Vivier A: *Atlas of clinical dermatology*, 3<sup>rd</sup> ed. Churchill Livingstone: London, 2002
27. Stavropoulos PG, Soura E, Antoniou C: Drug-induced pemphigoid: A review of the literature. *J Eur Acad Dermatol Venereol*, 2014; 28(9): 1133–40
28. Kijima A, Inui S, Nakamura T et al: Does drug-induced hypersensitivity syndrome elicit bullous pemphigoid? *Allergol Int*, 2008; 57(2): 181–82
29. Weisman K, Petersen CS, Blichmann CW et al: Bullous erythema multiforme following herpes zoster and varicella-zoster virus infection. *J Eur Acad Dermatol Venereol*, 1998; 11(2): 147–50
30. Schalock PC, Brennick JB, Dinulos JG: *Mycoplasma pneumoniae* infection associated with bullous erythema multiforme. *J Am Acad Dermatol*, 2005; 52(4): 705–6
31. Macvicar DN, Graham JH, Burgoon CF Jr.: Dermatitis herpetiformis, erythema multiforme and bullous pemphigoid: A comparative histopathological and histochemical study. *J Invest Dermatol*, 1963; 41: 289–300
32. Bedi TR, Pinkus H: Histopathological spectrum of erythema multiforme. *Br J Dermatol*, 1976; 95(3): 243–50
33. Howland WW, Golitz LE, Weston WL, Huff JC: Erythema multiforme: Clinical, histopathologic, and immunologic study. *J Am Acad Dermatol*, 1984; 10(3): 438–46
34. Lo Schiavo A, Ruocco E, Brancaccio G et al: Bullous pemphigoid: etiology, pathogenesis, and inducing factors: facts and controversies. *Clin Dermatol*, 2013; 31(4): 391–99
35. Kirtschig G, Wojnarowska F: Autoimmune blistering diseases: An up-date of diagnostic methods and investigations. *Clin Exp Dermatol*, 1994; 19(2): 97–112
36. Weigand DA: Effect of anatomic region on immunofluorescence diagnosis of bullous pemphigoid. *J Am Acad Dermatol*, 1985; 12(2 Pt 1): 274–78
37. Koch CA, Mazzaferri EL, Larry JA, Fanning TS: Bullous pemphigoid after treatment with furosemide. *Cutis*, 1996; 58(5): 340–44
38. Gotlib J: World Health Organization-defined eosinophilic disorders: 2017 update on diagnosis, risk stratification, and management. *Am J Hematol*, 2017; 92(11): 1243–59
39. Roufosse F, Weller PF: Practical approach to the patient with hypereosinophilia. *J Allergy Clin Immunol*, 2010; 126(1): 39–44
40. Valent P: Pathogenesis, classification, and therapy of eosinophilia and eosinophil disorders. *Blood Rev*, 2009; 23(4): 157–65
41. Chusid MJ, Dale DC, West BC, Wolff SM: The hypereosinophilic syndrome: Analysis of fourteen cases with review of the literature. *Medicine (Baltimore)*, 1975; 54(1): 1–27
42. Nutman TB: Evaluation and differential diagnosis of marked, persistent eosinophilia. *Immunol Allergy Clin North Am*, 2007; 27(3): 529–49