

Corneal endothelium and central corneal thickness changes in type 2 diabetes mellitus

Amira El-Agamy^{1,2,*}
Shams Alsubaie^{3,*}

¹Department of Optometry and Vision Sciences, College of Applied Medical Sciences, King Saud University, Riyadh, Saudi Arabia; ²Mansoura Ophthalmic Center, Faculty of Medicine, Mansoura University, Mansoura, Egypt;

³Department of Optometry and Vision Sciences, Sulaiman Al Habib Hospital, Riyadh, Saudi Arabia

*These authors contributed equally to this work

Purpose: This study was conducted to compare the corneal endothelial cell density (ECD), morphological features, and central corneal thickness (CCT) in type 2 diabetes mellitus (DM) with age-matched, nondiabetic control subjects using EM-3000 Specular Microscope.

Study design: This was a prospective, hospital-based, nonrandomized, case-control, observational, and quantitative study.

Subjects and methods: The study included 57 patients (57 eyes) with type 2 DM and 45 control (nondiabetic) subjects (45 eyes). The corneal endothelial structure and CCT were examined in all eyes by noncontact specular microscopy using EM-3000 Specular Microscope. The endothelial structure was studied for ECD, coefficient of variation of cell area (CV), and percentage of hexagonal cells.

Results: The study included 36 eyes without diabetic retinopathy (DR), 14 eyes with nonproliferative DR, and 7 eyes with proliferative DR. There were 26 eyes with a duration of ≤ 10 years and 31 eyes with a duration of > 10 years. Also, there were 24 eyes with $HbA_{1c} \leq 7.5\%$ and 33 eyes with $HbA_{1c} > 7.5\%$. ECD was significantly lower in the diabetic cornea than in control group ($P=0.014$). CV was higher in diabetic cornea ($P=0.008$). The diabetic cornea group had lower percentage of hexagonal cells than the control group, but the difference was not statistically significant ($P=0.603$). Also, diabetic cornea was thicker than control group, but not statistically significant ($P=0.301$).

Conclusion: This study documented that type 2 DM causes a significant reduction of ECD and increased CV (polymegathism). Also, diabetic cornea has increased CCT and lower percentage of hexagonal cells than normal subjects, but without statistical significance.

Keywords: endothelial cell density, central corneal thickness, diabetes mellitus, diabetic retinopathy, noncontact specular microscopy

Introduction

Many studies have demonstrated considerable effects of diabetes mellitus (DM) on all the layers of the cornea. These studies have documented that diabetic cornea is vulnerable to many abnormalities such as corneal endothelial damage, recurrent corneal erosions, punctate epithelial keratopathy, persistent epithelial defects, impaired corneal sensitivity, ulcers, slowed wound repair, and superficial keratitis.¹⁻³

Morphological features of the corneal endothelium in diabetic patients recognized by a number of studies include a decrease in endothelial cell density (ECD) and polymorphism (decrease in the percentage of hexagonal cells [the normal percentage $> 50\%$]) as well as polymegathism, which means increased coefficient of variation (CV) of cell area (CV values measured between 0.22 and 0.31 are considered normal and above 0.4 are abnormal) and increased central corneal thickness (CCT).⁴⁻⁶

Correspondence: Amira El-Agamy
Department of Optometry and Vision Sciences, College of Applied Medical Sciences (female section), King Saud University, Office 223, Third Floor, Building 11, Riyadh 12372, Saudi Arabia
Tel +966 5 4236 0577
Email aelagamy@ksu.edu.sa

EM-3000 Specular Microscope (CBD/Tomey, Phoenix, AZ, USA) is a noncontact specular microscope that avoids some disadvantages of the classic contact specular microscopes such as corneal ulceration and transmission of infectious diseases. It has the ability to assess corneal endothelium features and measure CCT at the same time with accuracy of $\pm 10 \mu\text{m}$.⁷

The aim of this study was to compare corneal ECD, morphological features, and CCT in type 2 DM with age-matched, nondiabetic control subjects using EM-3000 Specular Microscope. In addition, correlation between these corneal changes and the duration of DM and severity of diabetic retinopathy (DR) and glycemic control (glycated hemoglobin [HbA_{1c}] level) were also assessed.

Study design

This study was a prospective, hospital-based, nonrandomized, case-control, observational, and quantitative study. It got the approval of Research Ethics Committee of College of Applied Medical Sciences, King Saud University, and Security Forces Hospital, Riyadh, Saudi Arabia. It adhered to the tenets of the Declaration of Helsinki. All the participants signed comprehensive consent after explanation of the possible consequences of the study prior to investigations.

Subjects and methods

The study included 57 patients (27 males and 30 females [57 eyes]) with type 2 DM and 45 control (nondiabetic) subjects (45 eyes [22 males and 23 females]). The age range of diabetic group was 42–80 years (mean: 57.08 ± 8.37 years), and the age range of the control group was 40–76 years (mean: 50.80 ± 8.39 years). All patients were recruited from ophthalmology department at Security Forces Hospital, Riyadh, Saudi Arabia, by nonrandomized convenience sampling method from February to April 2015. The diagnosis of type 2 DM was based on the criteria of the World Health Organization (WHO).⁸ Control patients did not have diabetes was confirmed by random blood sugar test. The mean duration of DM was 12.87 ± 8.03 years (range: 1–40 years), and the mean value of HbA_{1c} was $8.57\% \pm 2.09\%$ (range: 6.3%–17.2%). Demographics of control and diabetic patients (eyes) are shown in Table 1.

Table 1 Demographics of control and diabetic patients (eyes)

Demographic data	Control group	DM patients (eyes)
Patients (eyes) (n)/percent	45/44.1%	57/55.9%
Mean age \pm SD/range (years)	$50.80 \pm 8.39/40-76$	$57.08 \pm 8.37/42-80$
Sex (males/females) (n)	22/23	27/30

Abbreviations: DM, diabetes mellitus; SD, standard deviation.

Exclusion criteria included presence of high myopia, history of past intraocular surgery or corneal disease or dystrophy such as Fuch's endothelial dystrophy, active or previous eye infection or inflammation, previous ocular surgery or trauma, previous retinal photocoagulation, pterygium, entropion, trichiasis, contact lens wear, regular usage of any eyedrops or known tear-interfering systemic drugs (such as hormone replacement and antihistamines), systemic illness such as rheumatoid arthritis and systemic lupus erythematosus that are known to impair tear function, pregnancy, labor, and glaucoma. In addition, patients who are unable to provide informed consent were excluded.

Age, gender, duration of diabetes, most recent HbA_{1c} value, status of DR, other medical illness, and current medical treatment were recorded. In this study, only the right eye of each patient was tested. All subjects underwent a complete ophthalmic examination that included visual acuity assessment using the Snellen chart, refraction using auto-refractometer (Topcon, Tokyo, Japan), and intraocular pressure measurement using air puff tonometer, slit-lamp biomicroscopy, and fundus examination.

The corneal endothelial structure and CCT were examined in all eyes by noncontact specular microscopy using EM-3000 Specular Microscope, and this examination was done by a single examiner. The endothelial structure was studied by measuring a variety of factors, including ECD, CV, and percentage of hexagonal cells.

The patient was positioned on a chair in front of the EM-3000 Specular Microscope. His/her chin was placed on the chin rest and his/her forehead rested on the special head area. The patient was asked to fixate his/her eye for a few seconds on the red light coming from inside the device until the instrument automatically took a clear image of the corneal endothelium and measured the CCT at the same time. The measurements were done three times and the average was taken.

The diabetic eyes were classified into 3 groups according to the status of DR (group without DR, group with nonproliferative DR [NPDR], and group with proliferative DR [PDR]). Also, they were divided into 2 groups according to DM duration (group with a duration of ≤ 10 years and group with a duration of > 10 years) and according to HbA_{1c} value (group with HbA_{1c} $\leq 7.5\%$ and group with HbA_{1c} $> 7.5\%$).

Statistical analysis

The data were analyzed using SPSS 21 for windows software (IBM, Armonk, NY, USA). The results were expressed as

mean \pm standard deviation. An independent sample *t*-test was performed to compare the means of CCT and corneal endothelium features in diabetic and control groups. The differences among 3 or more groups were analyzed by one-way analysis of variance. Pearson correlation test was performed to find the relationship between corneal changes and DM duration, HbA_{1c}%, and DR status. A value of $P \leq 0.05$ was considered statistically significant.

Results

The study included 36 eyes without DR, 14 eyes with NPDR, and 7 eyes with PDR. There were 26 eyes with DM duration of ≤ 10 years and 31 eyes with DM duration of > 10 years. Also, there were 24 eyes with HbA_{1c} $\leq 7.5\%$ and 33 eyes with HbA_{1c} $> 7.5\%$. Classification of groups of diabetic eyes is shown in Table 2.

ECD was significantly lower in the diabetic cornea group (2,491.98 \pm 261.08 cell/mm²) than in the control group (2,629.68 \pm 293.45 cell/mm²) ($P=0.014$). CV was higher in the diabetic cornea group (0.41 \pm 0.07) than in the control group (0.37 \pm 0.08) ($P=0.008$, which was considered statistically significant). Diabetic cornea group had lower percentage of hexagonal cells (33.24% \pm 10.25%) than control group (34.24% \pm 8.73%), but the difference was not statistically significant ($P=0.603$). Also, cornea was thicker in the diabetic group (545.61 \pm 30.39 μ m) than control group (539.42 \pm 29.22 μ m), but not statistically significant ($P=0.301$). A comparison of the mean values of CCT, ECD, CV, and hexagonality between control and diabetic eyes is shown in Table 3. Specular microscope pictures taken from control and diabetic eyes are shown in Figures 1–4.

Eyes with DM duration of ≤ 10 years had higher ECD (2,509.38 \pm 303.49 cell/mm²) than eyes with DM duration of > 10 years (2,477.38 \pm 223.61 cell/mm²) ($P=0.658$), and they also had more hexagonality (35.61% \pm 9.87%) than those with DM duration of > 10 years (31.26% \pm 10.29%) ($P=0.111$), but the differences were not significant. Also, there were no significant differences in CCT ($P=0.431$) and CV ($P=0.927$) between the 2 groups. A comparison of the mean values of CCT, ECD, CV, and hexagonality between the diabetic groups according to the duration of DM is shown

Table 2 Classification of groups of diabetic eyes

Clinical data	DR			DM duration (years)		HbA _{1c}	
	No DR	NPDR	PDR	≤ 10	> 10	$\leq 7.5\%$	$> 7.5\%$
Eyes (n)	36	14	7	26	31	24	33

Abbreviations: DM, diabetes mellitus; DR, diabetic retinopathy; HbA_{1c}, glycated hemoglobin; NPDR, nonproliferative DR; PDR, proliferative DR.

Table 3 A comparison of the mean values of CCT, ECD, CV, and hexagonality between control and diabetic eyes (mean \pm SD)

Group	CCT (μ m)	ECD (cell/mm ²)	CV	Hexagonality (%)
Control	539.42 \pm 29.22	2,629.68 \pm 293.45	0.37 \pm 0.08	34.24 \pm 8.73
DM	545.61 \pm 30.39	2,491.98 \pm 261.08	0.41 \pm 0.07	33.24 \pm 10.25
<i>P</i> -value	0.301	0.014	0.008	0.603

Abbreviations: CCT, central corneal thickness; CV, coefficient of variation of cell area; DM, diabetes mellitus; ECD, endothelial cell density; SD, standard deviation.

in Table 4. Specular microscope pictures taken from diabetic eyes with DM duration of > 10 years and ≤ 10 years are shown in Figures 2 and 4.

Diabetic patients with HbA_{1c} ≤ 7.5 had higher, but not statistically significant, ECD (2,537.62 \pm 311.86 cell/mm²) than those with HbA_{1c} > 7.5 (2,458.78 \pm 216.06 cell/mm²) ($P=0.293$) and higher hexagonality (35.58% \pm 10.09%) than the other group (31.54% \pm 10.17%) ($P=0.144$). The mean of CV was significantly lower ($P=0.017$) in diabetic patients with HbA_{1c} ≤ 7.5 (0.39 \pm 0.05) than in the other group (0.43 \pm 0.07). Also, there was no statistically significant difference in CCT between the 2 groups (0.789). A comparison of the mean values of CCT, ECD, CV, and hexagonality between the diabetic groups according to HbA_{1c} is shown in Table 5.

In addition, there were no significant differences between CCT, ECD, CV, and hexagonality percentage of the corneal endothelial cells in diabetic patients without DR, with NPDR, and with PDR ($P=0.344$, 0.806, 0.284, and 0.500, respectively) (Table 6).

Pearson correlation analysis showed that DM duration, HbA_{1c} levels, and severity of DR had no significant correlations with CCT, CV, hexagonality, or ECD (Table 7).

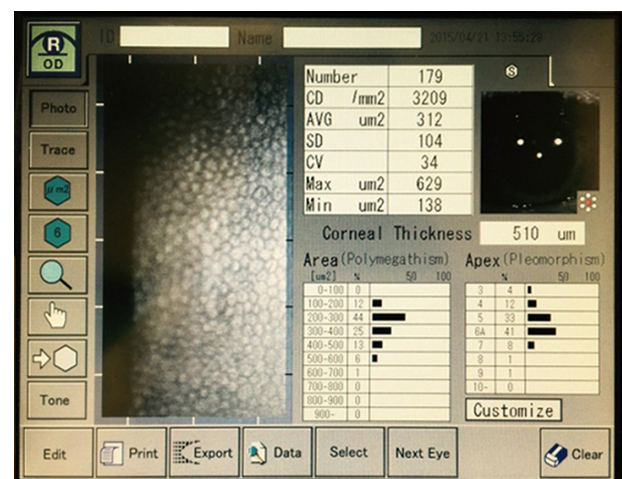


Figure 1 Corneal endothelium picture taken by EM-3000 Specular Microscope (CBD/Tomey, Phoenix, AZ, USA) for non-DM female (46 years old).

Abbreviation: DM, diabetes mellitus.

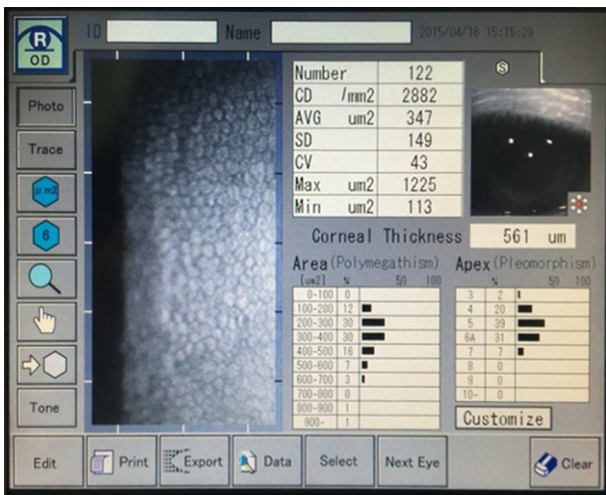


Figure 2 Corneal endothelium picture taken by EM-3000 Specular Microscope (CBD/Tomey, Phoenix, AZ, USA) for DM female (46 years old) with PDR (DM duration of 20 years and HbA_{1c} =9.2%).

Abbreviations: DM, diabetes mellitus; HbA_{1c}, glycated hemoglobin; PDR, proliferative diabetic retinopathy.

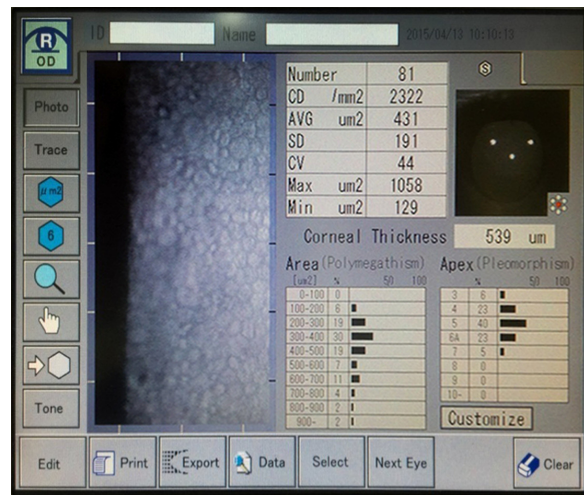


Figure 4 Corneal endothelium picture taken by EM-3000 Specular Microscope (CBD/Tomey, Phoenix, AZ, USA) for DM male (56 years old) without DR (DM duration of 8 years and HbA_{1c} =9.5%).

Abbreviations: DM, diabetes mellitus; DR, diabetic retinopathy; HbA_{1c}, glycated hemoglobin.

Discussion

Diabetic cornea may give the impression that is healthy, but actually it may suffer from many morphological features affecting its function later on. This fact was evidenced by several studies.¹⁻⁶

In this study, we found that diabetic corneas showed a statistically significant reduction in mean corneal ECD of 5.24% ($P=0.014$) compared to the corneas in the control group. This was similar to the results of Choo et al⁴ of 4.5% significant reduction in ECD ($P<0.01$) in Malaysian type 2 DM patients. Also, the results of Inoue et al⁹ study of the corneal

endothelium and CCT in type 2 DM in Japan showed similar results of 4.1% ($P=0.016$) significant reduction in ECD in the diabetic group. However, results of Storr-Paulsen et al⁶ and Siribunkum et al¹⁰ studies of corneal endothelium morphology in type 2 DM according to ECD were not consistent with our findings. The CV of corneal endothelial cells was found to be significantly increased in diabetic patients ($P=0.008$). This increase indicated the presence of polymegathism, in which endothelial cells enlarge to fill the gaps between adjacent cells. This result was concordant with those obtained by Shenoy et al¹¹ and Lee et al,¹² but not similar to those of Sudhir et al⁵ and Chen et al.¹³

Also, our study demonstrated no significant difference in the percentage of hexagonal cells between the diabetic patients and the controls, which was in agreement with the results of Sudhir et al,⁵ Storr-Paulsen et al,⁶ and Inoue et al,⁹ and in disagreement with those of Choo et al,⁴ and Lee et al.¹²

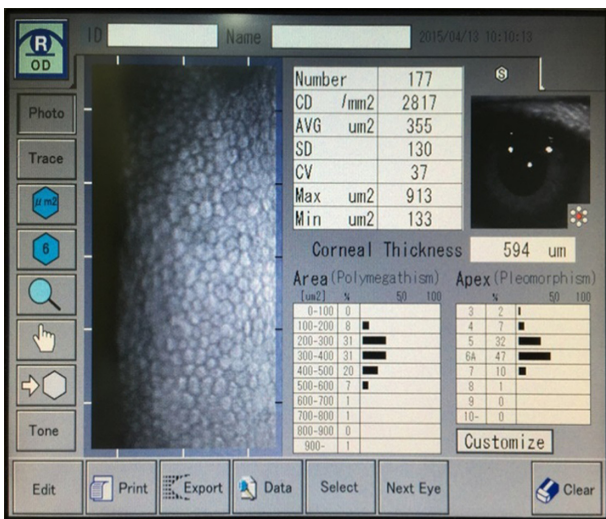


Figure 3 Corneal endothelium picture taken by EM-3000 Specular Microscope (CBD/Tomey, Phoenix, AZ, USA) for non-DM male (58 years old).

Abbreviation: DM, diabetes mellitus.

Table 4 A comparison of the mean values of CCT, ECD, CV, and hexagonality between the diabetic groups, according to duration of DM (mean ± SD)

DM duration (years)	CCT (μm)	ECD (cell/mm ²)	CV	Hexagonality (%)
≤ 10	549.11±30.57	2,509.38±303.49	0.41±0.09	35.61±9.87
> 10	542.67±30.43	2,477.38±223.61	0.42±0.04	31.26±10.29
P-value	0.431	0.658	0.927	0.111

Abbreviations: CCT, central corneal thickness; CV, coefficient of variation of cell area; ECD, endothelial cell density; HbA_{1c}, glycated hemoglobin; SD, standard deviation.

Table 5 A comparison of the mean values of CCT, ECD, CV, and hexagonality between the diabetic groups, according to HbA_{1c}% (mean ± SD)

HbA _{1c} %	CCT (μm)	ECD (cell/mm ²)	CV	Hexagonality (%)
≤7.5	544.33±28.89	2,537.62±311.86	0.39±0.05	35.58±10.09
>7.5	546.54±31.84	2,458.78±216.06	0.43±0.07	31.54±10.17
P-value	0.789	0.293	0.017	0.144

Abbreviations: CCT, central corneal thickness; CV, coefficient of variation of cell area; ECD, endothelial cell density; HbA_{1c}, glycated hemoglobin; SD, standard deviation.

Many studies^{4,14,15} have explained the morphological features of diabetic cornea. This was established by the assessment of polyol (sorbitol–aldose reductase) pathway in diabetic cornea. These studies documented that high glucose levels lead to increased activity of the aldose reductase, causing sorbitol buildup in the corneal epithelial and endothelial cells. This sorbitol acts as an osmotic agent and leads to swelling of endothelial cells. Also, DM diminishes Na⁺–K⁺ ATPase activity of the corneal endothelium, resulting in morphological and permeability changes in diabetic cornea, thereby leading to corneal destruction. Furthermore, endothelial pump function was proven to be affected by decreased ATP production as a result of slowing down of the Krebs cycle in diabetic cornea.

Regarding CCT in our study, there was no significant difference between diabetic and control groups. This result was in concordance with those of Choo et al⁴ and Sudhir et al.⁵ Other studies, for instance, Storr-Paulsen et al⁶ and Lee et al,¹² demonstrated a statistically significant increase in CCT of diabetic compared to control subjects.

As regards the comparison of the mean values of CCT, ECD, CV, and cell hexagonality in patients with DM duration of ≤10 years and those with DM duration of >10 years, no statistically significant difference was detected in all these morphological features in this study. This finding was in agreement with Altay et al,¹⁶ who reported absence

Table 6 A comparison of the mean values of CCT, ECD, CV, and hexagonality between the diabetic groups, according to the status of DR (mean ± SD)

DR status	CCT (μm)	ECD (cell/mm ²)	CV	Hexagonality (%)
No DR	550.14±31.23	2,478.61±286.71	0.40±0.07	34.25±9.91
NPDR	537.50±27.73	2,497.98±240.52	0.44±0.05	30.43±10.08
PDR	538.57±30.47	2,549.86±162.02	0.42±0.05	33.71±12.73
P-value	0.344	0.806	0.284	0.500

Abbreviations: CCT, central corneal thickness; CV, coefficient of variation of cell area; DR, diabetic retinopathy; ECD, endothelial cell density; NPDR, nonproliferative DR; PDR, proliferative DR; SD, standard deviation.

Table 7 Correlation between corneal changes and DM duration, HbA_{1c}%, and DR status

Clinical data	CCT (μm)	ECD (cell/mm ²)	CV	Hexagonality (%)
DM duration, years				
R value	–0.163	–0.069	0.051	–0.134
P-value	0.226	0.610	0.702	0.320
HbA _{1c} %				
R value	0.156	–0.218	0.125	–0.160
P-value	0.245	0.103	0.351	0.234
DR status				
R value	–0.175	0.085	0.158	–0.081
P-value	0.192	0.527	0.240	0.554

Abbreviations: CCT, central corneal thickness; CV, coefficient of variation of cell area; DM, diabetes mellitus; DR, diabetic retinopathy; ECD, endothelial cell density; HbA_{1c}, glycated hemoglobin; SD, standard deviation.

of statistically significant difference in CCT between the 2 groups. However, Lee et al¹² documented that CCT and CV were significantly higher in patients with DM duration of >10 years compared with those with DM duration of ≤10 years, but there was no statistically significant difference regarding ECD and hexagonality between the 2 groups.

Concerning the comparison of the mean values of CCT, ECD, CV, and cell hexagonality in diabetic patients with HbA_{1c} ≤7.5% and those with HbA_{1c} >7.5% in our study, no significant differences were detected between the 2 groups in CCT, ECD, and hexagonality, but CV showed a statistically significant difference (*P*=0.017). Storr-Paulsen et al⁶ found significantly lower ECD in patients with elevated HbA_{1c}, but without any influence on CCT. However, Altay et al¹⁶ documented significantly thicker CCT in hyperglycemic condition than in euglycemic condition in the same patient before and after successful control of HbA_{1c}.

Regarding the comparison of the mean values of CCT, ECD, CV, and hexagonality between the 3 diabetic groups according to the status of DR, our study found no significant differences between the 3 groups. This finding was not in accordance with that of Shenoy et al,¹¹ who demonstrated significantly lower ECD in eyes with DR than those without DR.

Pearson correlation analysis reported absence of significant correlations between DM duration, HbA_{1c} levels, and severity of DR and morphological features of diabetic cornea such as CCT, CV, hexagonality, or ECD. These results were similar to those of Choo et al.⁴ However, Siribunkum et al¹⁰ found a significant correlation between DM duration and pleomorphism, polymegathism, and CCT. Severity of DR was correlated with ECD, but these correlations were low. However, the corneal morphological abnormalities were not correlated with HbA_{1c} levels.

Conclusion

This study documented that type 2 DM resulted in a significant reduction of ECD and increased CV (polymegathism). Also, diabetic cornea had increased CCT and lower percentage of hexagonal cells than in the cornea of normal subjects, but this is not statistically significant. In addition, our study demonstrated that DM duration, HbA_{1c} levels, and severity of DR had no significant correlations with CCT, CV, hexagonality, or ECD.

In this study, patients with a history of laser photocoagulation were excluded due to its influence on the corneal structures.¹⁷ This exclusion produced a small sample size because most of diabetic patients who came to the clinic had undergone laser treatments. Therefore, further studies with a large sample size are recommended to verify the extent of corneal damage caused by type 2 DM.

Disclosure

Dr Amira El-Agamy is financially supported by the Research Center of College of Applied Medical Sciences, King Saud University, Saudi Arabia. The authors report no other conflicts of interest in this work.

References

1. Herse PR. A review of manifestations of diabetes mellitus in the anterior eye and cornea. *Am J Optom Physiol Optics*. 1988;65:224–230.
2. Thomas N, Jeyaraman K, Asha HS, Velevan J. *A Practical Guide to Diabetes Mellitus*. New Delhi, India: Jaypee Brothers Medical Publishers; 2012.
3. Chawla R. *Complications of Diabetes*. New Delhi, India: Jaypee Brothers Medical Publishers 2012.
4. Choo M, Prakash K, Samsudin A, Soong T, Ramli N, Kadir A. Corneal changes in type II diabetes mellitus in Malaysia. *Int J Ophthalmol*. 2010; 3(3):234–236.
5. Sudhir R, Raman R, Sharma T. Changes in the corneal endothelial cell density and morphology in patients with type 2 diabetes mellitus: a population-based study, Sankara Nethralaya Diabetic Retinopathy and Molecular Genetics Study (SN-DREAMS, Report 23). *Cornea*. 2012; 31(10):1119–1122.
6. Storr-Paulsen A, Singh A, Jeppesen H, Norregaard J, Thulesen J. Corneal endothelial morphology and central thickness in patients with type II diabetes mellitus. *Acta Ophthalmol*. 2013;92(2):158–160.
7. Guthrie DW, Guthrie R. *Management of Diabetes Mellitus: A Guide to the Pattern Approach*. 6th ed. New York, NY: Springer Publishing Company; 2008.
8. World Health Organization. *Definition, Diagnosis and Classification of Diabetes Mellitus and Its Complications*. Report of a WHO Consultation. Geneva, Switzerland: World Health Organization; 1999.
9. Inoue K, Kato S, Inoue Y, Amano S, Oshika T. The corneal endothelium and thickness in type II diabetes mellitus. *Jpn J Ophthalmol*. 2002; 46(1):65–69.
10. Siribunkum J, Kosrirukvongs P, Singalavanija A. Corneal abnormalities in diabetes. *J Med Assoc Thai*. 2001;84(8):1075–1083.
11. Shenoy R, Khandekar R, Bialasiewicz A, Al Muniri A. Corneal endothelium in patients with diabetes mellitus: a historical cohort study. *Eur J Ophthalmol*. 2009;19(3):369–375.
12. Lee JS, Oum BS, Choi HY, Lee JE, Cho BM. Differences in corneal thickness and corneal endothelium related to duration in diabetes. *Eye*. 2006;20(3):315–318.
13. Chen Y, Huang S, Jonna G, Channa P. Corneal endothelial cell changes in diabetes mellitus. *Invest Ophthalmol Vis Sci*. 2014;55(5):2054.
14. Browning DJ. *Diabetic Retinopathy: Evidence-Based Management*. New York, NY: Springer; 2010.
15. Tripathy BB, Chandalia HB, Das AK, Rao PV. *Textbook of Diabetes Mellitus*. New Delhi, India: Jaypee Brothers Medical Publishers; 2012.
16. Altay Y, Burcu A, Ornek F. The change in central corneal thickness after successful control of hyperglycemia in diabetic patients. *Int Eye Sci*. 2014;14(4):575–578.
17. Pardos GJ, Krachmer JH. Photocoagulation: its effect on the corneal endothelial cell density of diabetics. *Arch Ophthalmol*. 1981;99(1): 84–86.

Clinical Ophthalmology

Publish your work in this journal

Clinical Ophthalmology is an international, peer-reviewed journal covering all subspecialties within ophthalmology. Key topics include: Optometry; Visual science; Pharmacology and drug therapy in eye diseases; Basic Sciences; Primary and Secondary eye care; Patient Safety and Quality of Care Improvements. This journal is indexed on

Submit your manuscript here: <http://www.dovepress.com/clinical-ophthalmology-journal>

Dovepress

PubMed Central and CAS, and is the official journal of The Society of Clinical Ophthalmology (SCO). The manuscript management system is completely online and includes a very quick and fair peer-review system, which is all easy to use. Visit <http://www.dovepress.com/testimonials.php> to read real quotes from published authors.