

Case Report

Evolution of epilepsy in hemimegalencephaly from infancy to adulthood: Case report and review of the literature



Kristin M. Ikeda ^{*}, Seyed M. Mirsattari

Department of Clinical Neurological Sciences, Western University, Room B10-106, 339 Windermere Road, London, ON N6A 5A5, Canada

ARTICLE INFO

Article history:

Received 2 December 2016
 Received in revised form 9 February 2017
 Accepted 15 February 2017
 Available online 1 March 2017

Keywords:

Hemimegalencephaly
 hemispherectomy
 Natural history
 Seizure
 Drug-resistant epilepsy

ABSTRACT

Hemimegalencephaly (HME) is a rare disorder of cortical development with overgrowth of one cerebral hemisphere. Patients have intellectual delay, hemiparesis and severe epilepsy. Drug-resistant epilepsy is often treated with a hemispherectomy. We review the literature on HME natural history and report a 26-year-old man with HME who did not undergo hemispherectomy in childhood with recurrent focal convulsive or non-convulsive status epilepticus.

Few patients with HME have been followed into adulthood. Reported adult cases have milder epilepsy or underwent hemispherectomy in childhood. Patients surviving to adulthood have poor outcomes, regardless of treatment method, although seizure burden is improved with hemispherectomy.

© 2017 The Authors. Published by Elsevier Inc. This is an open access article under the CC BY-NC-ND license (<http://creativecommons.org/licenses/by-nc-nd/4.0/>).

1. Introduction

Hemimegalencephaly (HME) is a rare disorder characterized by overgrowth of one cerebral hemisphere. It can occur as an isolated finding, or as part of a syndrome, such as hypomelanosis of Ito, tuberous sclerosis complex, epidermal nevus syndrome or Klippel–Trenaunay syndrome [1,2]. HME is classically associated with the triad of epilepsy, global developmental delay and contralateral motor deficit [3]. Epilepsy in these patients is notoriously difficult to treat, and patients generally have a poor neurodevelopmental outcome [2–4].

In children with HME and drug-resistant epilepsy (DRE), a hemispherectomy is often performed to decrease the burden of seizures [2]. These children may not become seizure free, but there is usually a significant improvement in seizure control and quality of life [2,5]. We report the clinical course of an adult with right HME diagnosed in infancy and severe epilepsy who did not undergo treatment with hemispherectomy.

2. Case report

A 26-year-old man was admitted to hospital for DRE and increased seizure frequency. Seizures consisted of head and eye deviation to the left, blinking, left arm abduction and right arm flexion (fencing posture).

Abbreviations: HME, hemimegalencephaly; SE, status epilepticus; EPC, epilepsia partialis continua; DRE, drug-resistant epilepsy.

^{*} Corresponding author.

E-mail addresses: kristin.ikeda@londonhospitals.ca (K.M. Ikeda), seyed.mirsattari@lhsc.on.ca (S.M. Mirsattari).

Awareness was partially retained through the seizure, and they occurred on a daily basis. He also had seizures characterized by generalized tonic stiffening, which were increasing in frequency and prompted hospital admission. His antiseizure medications, included valproic acid 2000 mg per day, lacosamide 400 mg per day and perampanel 4 mg daily. He also took quetiapine and vitamin B6.

Three days prior to admission, seizure frequency increased to hourly, and two weeks before admission the seizure frequency increased to three or four per day. No clear trigger was identified for the increased seizure frequency. The infectious workup was negative, and his serum valproic acid level was supratherapeutic at 1007 $\mu\text{mol/L}$ (350–700 $\mu\text{mol/L}$).

The patient was known to have right HME. He was severely developmentally disabled, non-verbal and wheelchair-bound. There was no history of febrile seizures, CNS infections, head trauma or family history of epilepsy.

At birth, he required an emergency caesarean section for fetal distress 10 h after premature rupture of membranes. Macrocephaly was noted on prenatal ultrasound. Seizures began 5 min after birth, when he turned blue and had generalized tonic-clonic seizures. He developed respiratory distress requiring intubation, and was hospitalized for six weeks.

He had multiple hospitalizations for respiratory tract infections throughout childhood, partially explained by aspiration, which required insertion of a gastrojejunostomy tube.

Seizures remained difficult to control, and he had several admissions for focal status epilepticus (SE) with tonic or clonic jerking of his left hand. Multiple antiseizure medications were tried, including phenytoin, phenobarbital, carbamazepine, clonazepam, clobazam, vigabatrin,

lamotrigine, valproic acid and levetiracetam without achieving seizure control.

When the patient was 18 months old, he was assessed for possible epilepsy surgery. His EEG demonstrated multifocal spikes, with the principle focus in the right occipital–parietal–temporal regions. Occasional left temporal–parietal spikes and generalized spike–wave discharges were seen. Episodes of electrographic SE were captured on multiple EEGs, principally in the right occipital region, spreading locally to the right parietal and posterior temporal regions. Discrete clinical seizures were also captured with origin in this area. Seizures were characterized by head and eye deviation to the left in a tonic and/or clonic manner lasting a few seconds, identical to current semiology. The MRI demonstrated right HME (Fig. 1). He was discussed for consideration of a possible right posterior hemisphere resection with or without a corpus callosotomy, or a right hemispherectomy. The patient's mother declined surgical intervention, and the patient has been medically managed. He has had periods of relative seizure control, however has never been seizure free.

During the current hospitalization, he was monitored with continuous video-EEG, which demonstrated SE in the right posterior temporal–occipital–parietal region, and at times independently at the right central–parietal region (Fig. 2). No clear clinical correlate was seen during the majority of the electrographic SE. There was occasional eye deviation to the left and repetitive blinking with no other clinical manifestations. Ictal activity was briefly interrupted by periods of arrhythmic delta.

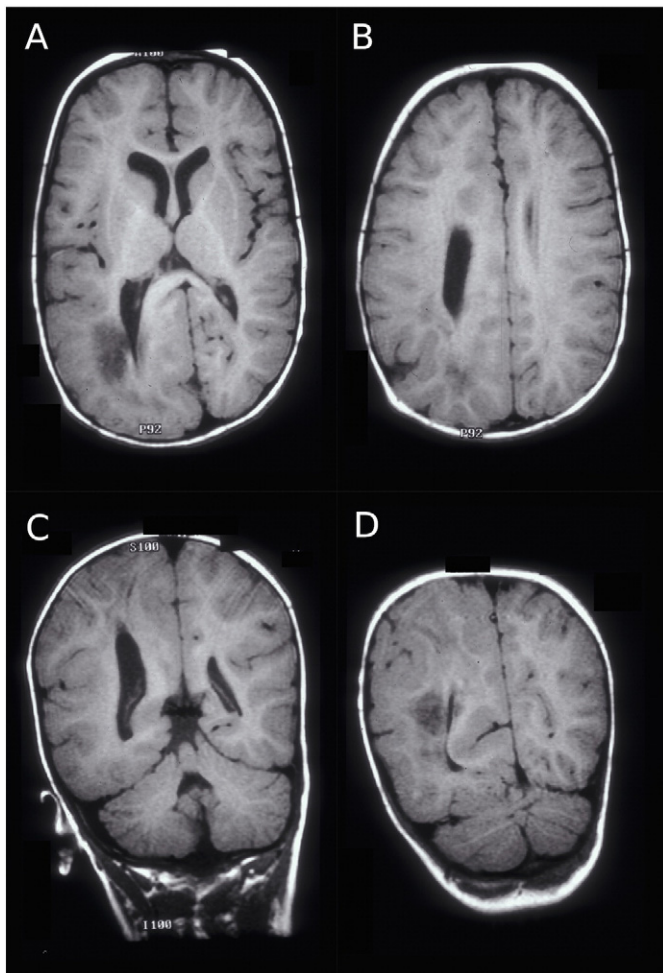


Fig. 1. MRI at 18 months of age. Axial (A, B) and coronal (C, D) T1-weighted images demonstrating right hemimegalencephaly. The ventricles are asymmetric and there is thickening of the cortex on the right, particularly in the parietal and occipital lobes.

His antiseizure medications were adjusted, and he returned to his baseline. He was discharged home on lacosamide, phenytoin, a tapering dose of perampanel, and a reduced dose of valproic acid.

3. Discussion

This case follows HME from initial presentation shortly after birth to adulthood. Cases of HME surviving to adulthood without hemispherectomy are rarely reported. This patient had severe epilepsy since birth, and a hemispherectomy, which is the most beneficial procedure for these cases [2,3], was not performed. Most children with HME and DRE undergo hemispherectomy, making this case unique in documenting the progression of epilepsy over time. His epilepsy has remained difficult to control and the ictal rhythms have become more hemispheric, rather than limited to the posterior quadrant. Despite this, seizure semiology remains largely unchanged. His episodes of SE do not have any identifiable clinical changes, but would be best classified using the ILAE classification for SE [6], as focal SE without impairment of consciousness, due to HME with electrographic features of fluctuating, nearly continuous spike–wave, with neonatal age of onset.

Most of the literature regarding outcomes in patients with HME is following surgical intervention for DRE. Moreover, there are even fewer reports of outcomes into adulthood. Seizure control is typically better if the onset of epilepsy is when the child is older than seven years of age [7]. It was also shown that a younger age of seizure onset and longer duration of epilepsy prior to surgery were predictors of a poor outcome from surgery in childhood [8,9].

3.1. Hemispherectomy for treatment of drug-resistant epilepsy

Hemispherectomy for epilepsy became an accepted treatment for “catastrophic” epilepsy after 1950, when Krynauw reported a case series of seizure control following hemispherectomy in patients with congenital vascular lesions [10]. With advancing neuroimaging techniques and identification of HME and other cortical abnormalities, hemispherectomy was also offered as a surgical management option for DRE [4,5]. Indications for the procedure include DRE secondary to HME or extensive cortical dysplasia, Rasmussen's encephalitis, or vascular lesions such as perinatal stroke. Hemispherectomy is less commonly performed in adulthood for DRE; however, indications are more commonly birth trauma or meningoencephalitis [11,12]. It is felt that hemispherectomy is the best therapeutic option for DRE in these patients [2].

3.1.1. Benefits of hemispherectomy

Overall there is considerable benefit from this surgery; however, the patients who benefit most are those with Rasmussen's encephalitis or congenital vascular abnormalities [4,8,13]. Overall, 54–78% of patients become seizure free after hemispherectomy, though this is lower in patients with HME, with 38–67% achieving seizure freedom [5,13,14]. Patients with HME are reported to have a significantly improved seizure burden following hemispherectomy [5]. Hemispherectomy has been performed in adulthood for similar indications, with good outcomes in terms of seizure control with 55–92% becoming seizure free [11,12].

3.1.2. Risks of hemispherectomy

Early hemispherectomies were associated with many complications, particularly superficial siderosis [15]; however functional hemispherectomies or hemispherotomies are now performed, due to less surgical risk [5,8,14]. Fatalities are rare, and most do not suffer from major complications. Hydrocephalus is commonly seen, as are infections, fever, anemia and temporary worsening of previous deficits [1,15]. In adults, hemianopia, loss of pincer grasp and worsening gait, all expected effects of hemispherectomy [16,17], cause more impairment than in children. However, overall motor and intellectual function has been seen to improve after surgery [17].

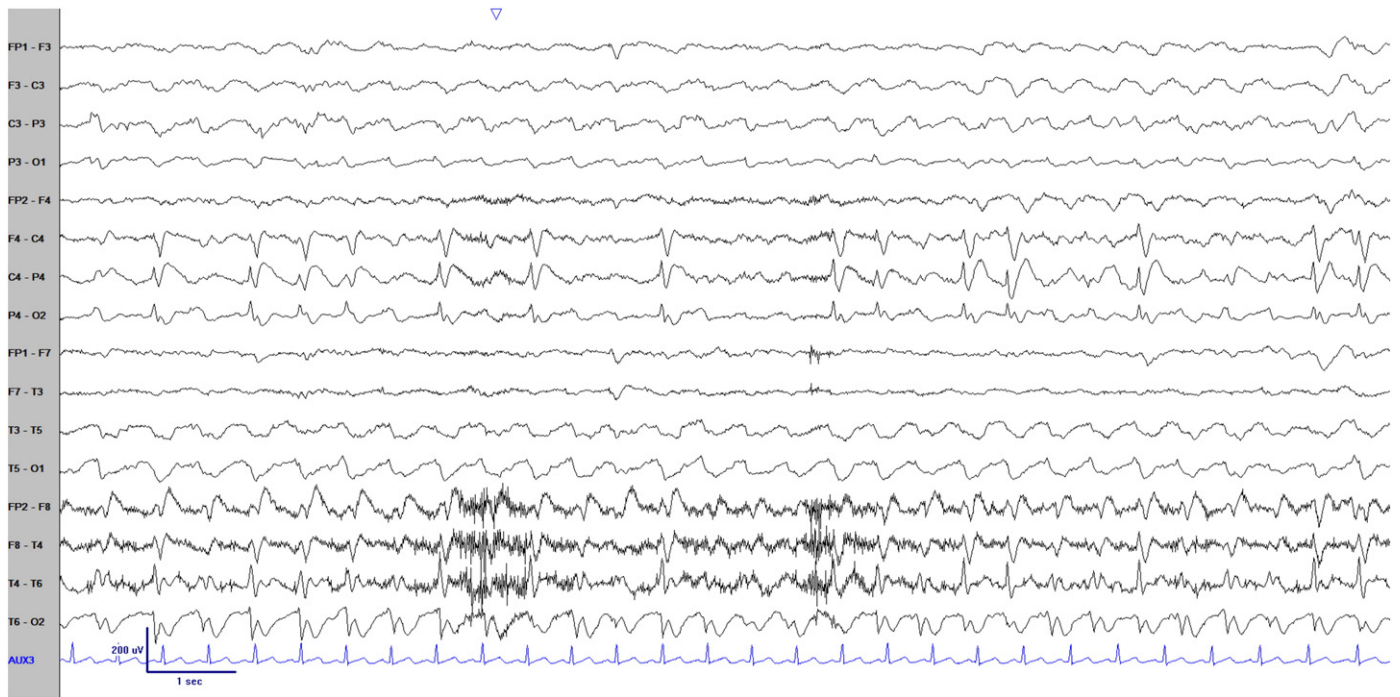


Fig. 2. EEG at age 26 years. Longitudinal Bipolar Montage showing status epilepticus from the right posterior parietal-occipital-temporal region. (Sensitivity 10 μ V/mm, low frequency filter 1 Hz, high frequency filter 70 Hz, Notch (60 Hz) ON).

3.2. Outcomes in HME

Outcomes of children with HME have rarely been studied into adulthood, and there are no reports comparing the outcomes of children who did and did not undergo hemispherectomy due to DRE. Reported adult cases of HME typically have epilepsy that is easy to control with medications. Thus in some patients surgical treatment is not indicated, or previously they underwent hemispherectomy due to DRE (Table 1). Three cases of HME in adults with DRE beginning in infancy have been previously reported [18–20]. Two patients became seizure free with medical management. The third patient did not undergo hemispherectomy due to contraindications when evaluated as a child; as an adult, a vagus nerve stimulator was implanted with a significant decrease in seizure frequency [20]. There are two reports of hemispherectomy for HME performed in adulthood, one with a poor seizure outcome [16] and the other with a good outcome [12]. Epilepsia partialis continua (EPC) secondary to HME was also reported in an adult, but the EPC was not severe enough to warrant surgery [21].

Rarely, cases of HME are discovered in adults with normal development, presenting as seizures [22] or weakness [23]. There is also one case series reporting the neuroradiological features of HME with two adults in the series [24]. Both were reported to have seizures, but no additional clinical information was provided.

A recent case series of five adults with HME illustrated a wide range of disability [7]. One patient was seizure free on a single antiseizure medication with no intellectual disability, one patient had monthly seizures, one had seizures twice a year. The two most severe cases had 30–60 seizures per month after hemispherectomy, severe developmental delay, and one patient is non-ambulatory [7]. Interestingly, only one patient in this series had isolated HME, which is reported to occur in approximately half the cases of HME [1], and this patient had the best outcome. The remainder of the cases were syndromic with coexisting hypomelanosis of Ito or linear nevus sebaceous syndrome. Of the three cases in this series who did not have a hemispherectomy, one was seizure free, one had seizures every six months, and one had three seizures per month [7]. It is possible that the patients with DRE who did not

Table 1

Previous reports of adults with HME. Note that 4 cases with drug-resistant epilepsy did not undergo hemispherectomy. Syndromic HME includes hypomelanosis of Ito, linear sebaceous nevus syndrome, epidermal nevus. EPC: epilepsia partialis continua; TMS: transcranial magnetic stimulation; NR: not reported.

Paper	Number of adult cases	Age at evaluation (years)	Epilepsy duration (years)	Cognitive impairment	Hemiparesis	Seizures	Refractory epilepsy	Hemispherectomy	Syndromic	Comments
Wu et al. [7]	5	18–34	16–34	None (1); Mild (1); Severe (3)	Y (5)	Y (5)	Y (4)	Y (2)	Y (4)	
Ohtsuka et al. [21]	1	30	30	Mild	Y	Y	Y	N	N	EPC
Fusco et al. [22]	1	19	5	N	N	Y	N	N	N	
Beaulieu-Boire et al. [25]	1	19	1	N	Y	Y	N	N	N	
Singh et al. [19]	1	26	0.5	Mild	Y	Y	N	N	N	
Rao et al. [18]	1	30	29	Moderate	Y	Y	N	N	N	
Tinkle et al. [1]	1	29	NR	Y	Y	Y	NR	N	Y	
Chrastina et al. [20]	1	18	18	Severe	Y	Y	Y	N	N	VNS implantation
Civardi et al. [26]	1	26	4	N	N	Y	N	N	N	TMS study
Barkovich et al. [24]	2	33–41	NR	NR	NR	NR	NR	NR	NR	Imaging study
Schramm et al. [16]	1	28	19	NR	NR	Y	Y	Y	NR	ILAE class 4 outcome
Current study	1	26	26	Severe	Y	Y	Y	N	N	

undergo hemispherectomy did so due to the relatively infrequent seizures given the risks of the procedure.

4. Conclusions

Hemispherectomy was declined in this patient, and he has continued to be managed medically in the 23 years following this decision. This case demonstrates that patients with HME may survive into adulthood despite multiple episodes of SE and severe DRE. The epilepsy may progress to involve more of the affected hemisphere or contralateral hemisphere than at seizure onset, as it did in this case, becoming hemispheric after seizures localized to the posterior temporal–occipital regions as a child. The ictal EEG activity did not appear to spread to the contralateral hemisphere in this case, despite the presence of multifocal spikes. It is rare to see a patient with HME and DRE in adulthood who did not undergo hemispherectomy in childhood. Outcomes in these patients are rarely reported.

Consent

Written consent was obtained from the patient's legal guardian, and is available to the Editor upon request.

Conflicts of interest

The authors report no conflicts of interest.

Funding

No funding was received for this article.

References

- [1] Tinkle BT, Schorry EK, Franz DN, Crone KR, Saal HM. Epidemiology of hemimegalencephaly: a case series and review. *Am J Med Genet* 2005;139A:204–11.
- [2] Flores-Sarnat L. Hemimegalencephaly: part 1. genetic, clinical and imaging aspects. *J Child Neurol* 2002;17:373–84.
- [3] Di Rocco C, Battaglia D, Pietrini D, Piastra M, Massimi L. Hemimegalencephaly: clinical implications and surgical treatment. *Childs Nerv Syst* 2006;22:852–66.
- [4] Jonas R, Nguyen S, Hu B, Asarnow RF, Lopresti C, Curtiss S. Cerebral hemispherectomy hospital course, seizure, developmental, language, and motor outcomes. *Neurology* 2004;62:1712–21.
- [5] Vining EPG, Freeman JM, Pillas DJ, Uematsu S, Carson BS, Brandt J, et al. Why would you remove half a brain? The outcome of 58 children after hemispherectomy – the Johns Hopkins experience: 1968 to 1996. *Pediatrics* 1997;100:163–71.
- [6] Trinka E, Cock H, Hesdorffer D, Rossetti O, Scheffer IE, Shinnar S, et al. A definition and classification of status epilepticus – report of the ILAE task force on classification of status epilepticus. *Epilepsia* 2015;56:1515–23.
- [7] Wu N, Borlot F, Ali A, Krings T, Andrade DM. Hemimegalencephaly: what happens when children get older? *Dev Med Child Neurol* 2014;56:905–9.
- [8] Basheer SN, Connolly MB, Lautzenhiser A, Sherman EMS, Henderson G, Steinbok P. Hemispheric surgery in children with refractory epilepsy: seizure outcome, complications, and adaptive function. *Epilepsia* 2007;48:133–40.
- [9] Bulteau C, Otsuki T, Delalande O. Epilepsy surgery for hemispheric syndromes in infants: hemimegalencephaly and hemispheric cortical dysplasia. *Brain Dev* 2013;35:742–7.
- [10] Krynauw RA. Infantile hemiplegia treated by removing one cerebral hemisphere. *J Neurol Neurosurg Psychiatry* 1950;13:243–67.
- [11] McClelland S, Maxwell RE. Hemispherectomy for intractable epilepsy in adults: the first reported series. *Ann Neurol* 2007;61:372–6.
- [12] Liang S, Zhang G, Li Y, Ding C, Yu T, Wang X, et al. Hemispherectomy in adults patients with severe unilateral epilepsy and hemiplegia. *Epilepsy Res* 2013;106:257–63.
- [13] Kossoff E, Vining E, Pillas D, Pyzik P, Avellino A, Carson B, et al. Hemispherectomy for intractable unihemispheric epilepsy etiology vs outcome. *Neurology* 2003;887–90.
- [14] Honda R, Kaido T, Sugai K, Takahashi A, Kaneko Y, Nakagawa E, et al. Long-term developmental outcome after early hemispherotomy for hemimegalencephaly in infants with epileptic encephalopathy. *Epilepsy Behav* 2013;29:30–5.
- [15] Di Rocco C, Iannelli A. Hemimegalencephaly and intractable epilepsy: complications of hemispherectomy and their correlations with the surgical technique: a report on 15 cases. *Pediatr Neurosurg* 2000;33:198–207.
- [16] Schramm J, Delev D, Wagner J, Elger CE, Von Lehe M. Seizure outcome, functional outcome, and quality of life after hemispherectomy in adults. *Acta Neurochir (Wien)* 2012;154:1603–12.
- [17] Cukiert A, Cukiert CM, Argenton M, Baise-Zung C, Forster CR, Mello VA, et al. Outcome after hemispherectomy in hemiplegic adult patients with refractory epilepsy associated with early middle cerebral artery infarcts. *Epilepsia* 2009;50:1381–4.
- [18] Rao JVB, Vengamma B, Naveen T, Ramakrishna G. Isolated hemimegalencephaly in an adult. *J Neurosci Rural Pract* 2014;5:439–40.
- [19] Singh P, Paliwal VK, Neyaz Z, Lal H. Periodic lateralized triphasic waves in an adult with isolated hemimegalencephaly. *Neurol India* 2013;61:85–6.
- [20] Chrastina J, Novak Z, Brazdil M, Hermanova M. Glioblastoma multiforme in a patient with isolated hemimegalencephaly. *J Neurol Surg Rep* 2015;76:e160–3.
- [21] Ohtsuka Y, Ohno S, Oka E. Electroclinical characteristics of hemimegalencephaly. *Pediatr Neurol* 1999;20:390–3.
- [22] Fusco L, Ferracuti S, Fariello G, Manfredi M, Vigeveno F. Hemimegalencephaly and normal intellectual development. *J Neurol Neurosurg Psychiatry* 1992;55:720–2.
- [23] Beaulieu-Boire I, Lortie A, Bissonnette J, Prevost S, Bergeron D, Bocti C. Hemimegalencephaly in an adult with normal intellectual function and mild epilepsy. *Dev Med Child Neurol* 2012;54:284–6.
- [24] Barkovich AJ, Chuang SH. Unilateral megalencephaly: correlation of MR imaging and pathologic characteristics. *Am J Neuroradiol* 1990;11:523–31.
- [25] Beaulieu-Boire I, Lortie A, Bissonnette J, Prevost S, Bergeron D, Bocti C. Hemimegalencephaly in an adult with normal intellectual function and mild epilepsy. *Dev Med Child Neurol* 2012;54:284–6. <http://dx.doi.org/10.1111/j.1469-8749.2011.04136.x>.
- [26] Civarđi C, Vicentini R, Collini A, Boccagni C, Cantello R, Monaco F. Motor cortical organization in an adult with hemimegalencephaly and late onset epilepsy. *Neurosci Lett* 2009;460:126–9. <http://dx.doi.org/10.1016/j.neulet.2009.05.030>.