


Review

Mucormycosis and COVID-19-Associated Mucormycosis: Insights of a Deadly but Neglected Mycosis

Laura C. García-Carnero * and Héctor M. Mora-Montes * 

Departamento de Biología, División de Ciencias Naturales y Exactas, Campus Guanajuato, Universidad de Guanajuato, Noria Alta s/n, col. Noria Alta, C.P., Guanajuato 36050, Mexico

* Correspondence: laura_cgc@hotmail.com (L.C.G.-C.); hmora@ugto.mx (H.M.M.-M.);
Tel.: +52-473-7320006 (ext. 8193) (H.M.M.-M.)

Abstract: The ongoing COVID-19 pandemic has quickly become a health threat worldwide, with high mortality and morbidity among patients with comorbidities. This viral infection promotes the perfect setting in patients for the development of opportunistic infections, such as those caused by fungi. Mucormycosis, a rare but deadly fungal infection, has recently increased its incidence, especially in endemic areas, since the onset of the pandemic. COVID-19-associated mucormycosis is an important complication of the pandemic because it is a mycosis hard to diagnose and treat, causing concern among COVID-19-infected patients and even in the already recovered population. The risk factors for the development of mucormycosis in these patients are related to the damage caused by the SARS-CoV-2 itself, the patient's overstimulated immune response, and the therapy used to treat COVID-19, causing alterations such as hyperglycemia, acidosis, endothelial and lung damage, and immunosuppression. In this review, the molecular aspects of mucormycosis and the main risk factors for the development of COVID-19-associated mucormycosis are explained to understand this virus–fungi–host interaction and highlight the importance of this neglected mycosis.

Keywords: COVID-19; SARS-CoV-2; mucormycosis; CAM; immunosuppression; hyperglycemia; corticosteroids; iron overload; ACE2; cytokine storm; GRP-78



Citation: García-Carnero, L.C.; Mora-Montes, H.M. Mucormycosis and COVID-19-Associated Mucormycosis: Insights of a Deadly but Neglected Mycosis. *J. Fungi* **2022**, *8*, 445. <https://doi.org/10.3390/jof8050445>

Academic Editor: David S. Perlin

Received: 28 March 2022

Accepted: 22 April 2022

Published: 25 April 2022

Publisher's Note: MDPI stays neutral with regard to jurisdictional claims in published maps and institutional affiliations.



Copyright: © 2022 by the authors. Licensee MDPI, Basel, Switzerland. This article is an open access article distributed under the terms and conditions of the Creative Commons Attribution (CC BY) license (<https://creativecommons.org/licenses/by/4.0/>).

1. Introduction

In late 2019, the novel severe acute respiratory syndrome coronavirus 2 (SARS-CoV-2), the etiological agent of the coronavirus disease 2019 (COVID-19), was firstly associated with human disease [1,2]. SARS-CoV-2 was identified in China on 12 December 2019, and since then, it has become an important health threat worldwide, being declared by the World Health Organization on 11 March 2020 as the etiological agent of the ongoing pandemic [3].

Like in other viral diseases, secondary infections are important COVID-19 complications, which might be caused by other viruses, bacteria, protozoa, and fungi [4]. At the beginning of the pandemic, it was reported that about 1% of the secondary infections in COVID-19 patients were caused by fungal pathogens [5–7], and several factors are thought to contribute to this. The patient's preexisting health conditions, such as diabetes, immunosuppressive and antimicrobials agents misuse, and a long stay in the hospital may contribute to the development of secondary infections [8].

COVID-19-associated mucormycosis (CAM) is a severe emerging systemic fungal infection caused by several species of the *Mucorales* order [9,10], and it is already considered an epidemic in India [5,9,11,12]. However, CAM cases have also been reported worldwide, including in Brazil, Chile, Honduras, Paraguay, Uruguay, Mexico, the United States, the United Kingdom, Italy, France, Austria, and Iran [12–28]. Thus, it is a global health threat.

In this review, we will explain the molecular aspects of mucormycosis and discuss CAM's main physiopathological characteristics and the fundamentals of its development to understand this pathogen–host interaction.

2. Mucormycosis

Mucormycosis, previously known as zygomycosis, is a rare opportunistic, invasive, and deadly fungal infection that has increased in incidence in the last few years, as a secondary infection in patients with debilitating diseases, such as diabetes, cancer, and organ transplantation, and during natural disasters, such as tsunamis and earthquakes [29]. Despite the availability of treatment options for mucormycosis, mortality rates range between 50% and 100% [30], which highlights the importance of this emerging disease.

Although precise data about the prevalence of this mycosis are unknown, due to the lack of diagnosis, according to epidemiological data of autopsy reports on invasive fungal diseases from 2008 to 2013, the etiological agents of mucormycosis were the fourth most common cause of invasive mycoses in the general population and the third most common cause in the onco-hematological and stem cell transplant populations, with a high prevalence of severe cases (around 70%) [31]. This infection is widely found in developing countries, being highly reported in India with uncontrolled diabetes as the main cause, while in developed countries, it is mainly found in patients with hematologic malignancies and hematopoietic stem cell transplantation [32,33].

The transmission route for these fungi can be through spores inhalation, contaminated food ingestion, traumatic inoculation with contaminated materials, or implantation in already abraded skin [34,35], which results in the development of several forms of the disease, including rhino-cerebral/rhino-orbital, pulmonary, gastrointestinal, cutaneous, and other disseminated forms. The disseminated disease is caused by the fungal angioinvasive capacity [36], with the rhino-cerebral form being the most common one in developing countries [32]. Regardless of the clinical form, patients show hemorrhage, thrombosis, infarction, and tissue necrosis [37], and the mortality rate depends on the organ affected, the causative agent, the patient's health condition, and early diagnosis and treatment [38].

The mucormycosis causative agents are fast-growing thermotolerant fungi belonging to the *Mucorales* order, under the subphylum *Mucormycotina* and the phylum *Glomeromycota* [39,40]. *Rhizopus* is the genus most frequently associated with the disease, followed by *Mucor* and *Lichtheimia*, while *Zygomycetes* genera, including *Saksenae*, *Cunninghamella*, *Apophysomyces*, and *Rhizomucor*, are less common [35,40,41]. These organisms form a heterogeneous group and are saprobes or facultative parasites, found worldwide growing on decaying organic matter, agricultural and forest soils, and animal feces, all with similar morphologies characterized by large aseptate/pauci-septated, ribbon-like hyaline hyphae with irregular or right-angle branching [36,38,42]. Most of these species are heterothallic [43,44] and reproduce asexually forming nonmotile mitospores of 3–11 µm in diameter, produced in multi- or few-spored sporocarps, but there are a few species reported as homothallic, which are self-fertile [34,36].

Although all *Mucorales* share many unique characteristics, there are important differences among species in their epidemiology, pathogenesis, virulence, susceptibilities to the host immune response and antifungals, disease severity, and outcome [45–47]. However, most of the research has focused on *Rhizopus oryzae*, which is the most common mucormycosis causative agent [36].

2.1. Risk Factors

As mentioned before, these fungi are ubiquitously found in the environment, and their ability to cause disease in immunocompetent hosts is anecdotic but possible [48]. In the majority of the cases, the patients have underlying health conditions [40,49,50]. These patients have comorbidities or certain conditions that cause impairment of the host immune defenses and immunosuppression directly or indirectly [29,49], such as:

- Conditions that cause decreased numbers of phagocytes and altered immune functions, including hematologic malignancies, hematopoietic stem cell transplantation, solid organ malignancies and transplantation, and rheumatological diseases [10,40,42,49];
- Uncontrolled diabetes, diabetic ketoacidosis, and metabolic acidosis, which are conditions that cause changes in pH and iron availability within the host [10,29,40,42,49,51];

- The use of corticosteroids/immunosuppressors in high doses and for long periods [40,42], chelator therapy with deferoxamine (DFO) [10,29,40,42,49], and prolonged use of voriconazole [40,42,52];
- Malnutrition and neonatal prematurity [42,49]. On the other hand, the main factors linked to the development of mucormycosis in immunocompetent patients are:
 - Traffic and home accidents, trauma, skin injuries, and burns [10,29,32,33,41];
 - Natural disasters, such as tsunamis, tornadoes, and volcanic eruptions [29,34,41,53];
 - The use of contaminated medical materials, such as bandages and tongue depressors, and prolonged hospital stays [32,34].

2.2. Pathogenesis

Mucorales have many traits that contribute to their ability to cause such an aggressive disease, including thermotolerance [54,55], rapid growth and angioinvasive nature [54,56], cell wall remodeling to endure hostile environments [56], iron uptake from the host [34,36,57], ability to bind to glucose-regulated proteins on endothelial cells [58], downregulation of host genes involved in the immune response and tissue repair [50,59], and resistance to most available antifungals [60].

The fungus might enter the host through different vias, including spore inhalation, skin inoculation, or ingestion through the gastrointestinal tract [50]. Independently of the inoculation route, the establishment of the infection depends on several steps: inoculation of spores, immune response evasion, attachment to the endothelium, endocytosis, germination into hyphae, endothelial damage, and hematogenous dissemination [41,50,55]. Thus far, the most studied *Mucorales* virulence factors that participate in the infection process are the attachment to endothelial cells and iron uptake. *Mucorales* are vasotropic; therefore, the interaction between the fungus and endothelial cells around blood vessels is an indispensable step in mucormycosis pathogenesis [29,40], which explains the angioinvasive nature of these organisms.

Once in the host, spores attach to the basement membrane extracellular matrix proteins, laminin and collagen IV, and secrete proteolytic enzymes [61–63], subtilases [64], and lipolytic/glycosidic enzymes [65], which contribute to the destruction of the host tissue, which could have been already damaged by other host conditions, such as hyperglycemia or chemotherapy [36]. This interaction with the endothelial cells is specific and is through the spore-coat homolog (CoH) proteins [66], which bind to the receptor glucose-regulator protein 78 (GRP-78) [58]. It is well-reported that the expression levels of the CoH proteins determine the fungal virulence degree since high-virulent genera, such as *Rhizopus*, *Mucor*, and *Lichtheimia*, have three to seven CoH copies expressed, while low-virulent genera, such as *Apophysomyces*, *Cunninghamella*, *Saksenaia*, and *Syncephalastrum*, express only one to two copies, and *Entomophthorales* isolates, previously considered close to *Mucorales*, have no CoH genes and are avirulent [67].

The GRP-78 recognition by CoH proteins causes host cell death by the induction of endothelial cell-mediated endocytosis, initiating the fungal invasion of the endothelium [67]. The expression of both CoH and GRP-78 is highly enhanced in a hyperglycemic environment and with high concentrations of iron in acid pH, which is the reason diabetes and ketoacidosis are important risk factors for the development of mucormycosis [36,58]. GRP-78 binding to CoH proteins has been recognized as a unique mechanism for the *Mucorales* order since other opportunistic pathogens, such as *Candida albicans* and *Aspergillus fumigatus*, do not bind this endothelial cell receptor [58]. However, it is not the only factor involved in *Mucorales* binding to the host's cells since blockage or suppression of GRP-78 does not completely abolish endothelial invasion [29]. In this regard, the platelet-derived growth factor receptor B (PDGFRB), found in the transcriptome of endothelial cells interacting with *Rhizopus delemar*, *R. oryzae*, and *Mucor circinelliodes* [67], also contributes to the fungus growth and angioinvasion since inhibition of PDGFRB phosphorylation partially reduces *Mucorales*-mediated endothelial damage in vitro [67].

When talking about fungal growth and replication, nutrition is a very important factor, and iron is essential for these processes. In *Mucorales*, iron uptake is performed by three mechanisms: low molecular weight iron chelators or siderophores, high-affinity iron permeases, and heme-oxygenases [34,36]. In healthy individuals, iron is bound to the serum proteins, but in diabetic patients with uncontrolled high glucose levels and ketoacidosis, iron is found unbound and in elevated concentrations, improving *R. oryzae* growth and causing phagocytosis defects [68,69]. In hyperglycemia conditions, excessive iron sequestering proteins glycation, such as transferrin, ferritin, and lactoferrin, is induced, which reduces iron affinity and increases free iron levels [29] while increasing CotH and GRP-78 expression [58,70]. Under acidic conditions due to the accumulation of ketone bodies, such as β -hydroxy butyrate, the transferrin capacity of chelating iron is impaired [51], and the GRP-78 expression is also increased [70]. *Mucorales* have an intrinsic siderophore known as rhizoferrin, which supplies the fungus with unbound iron through a receptor-mediated process [71,72] that, however, is incapable of obtaining iron bound to serum proteins [72,73], which is thought to be the main mechanism for iron uptake under hyperglycemic and acidic conditions. However, for iron uptake, *Rhizopus* is capable of using external siderophores, such as DFO, an iron chelator used as a treatment in patients with increased iron overload [36,73]. DFO chelates iron from transferrin and forms the complex iron-DFO, known as ferroxamine, which binds to the fungal cell surface receptors Fob1 and Fob2, where the iron from the complex is reduced [72–74], reoxidized, and transported intracellularly by the high-affinity iron permease FTR1 [57,72]. The use of DFO plays an important predisposing role in the development of highly lethal and disseminated mucormycosis [73]. FTR1 permease has been proved to be important for fungal pathogenicity since during infection, *R. oryzae* expresses *FTR1*, which, when inhibited or reduced, causes fungal virulence reduction [57].

Finally, hemoglobin can also be used as a source of ferric iron by *Mucorales*, to which they have access due to their angioinvasive ability [36]. Once the fungus transports hemoglobin intracellularly, the heme-oxygenases in the cytoplasm, through the reductase-permease system, enable the iron uptake from the host hemoglobin [56,57,72]. It is thought that during this process, FTR1 acts as a cytoplasmic membrane permease that facilitates intracellular heme uptake [34].

2.3. Immune Response during Mucormycosis

The main host defense against the *Mucorales* spores germination and dissemination are innate immune cells, consisting of circulating neutrophils, mononuclear cells, and macrophages [75]. Tissue and alveolar macrophages phagocytose the spores and kill them, and in the case where any spore survives and germinates, hyphae then induce neutrophils chemotaxis, which eliminate them through reactive oxygen metabolites, cationic peptides, perforin, and the production of proinflammatory cytokines, such as $\text{TNF}\alpha$, $\text{INF}\gamma$, and $\text{IL-1}\beta$, which recruit and activate other immune cells [34,75–77]. However, other reports suggest that, although capable of phagocytosing *R. oryzae* spores and inhibiting their germination, macrophages cannot kill them due to the inhibition of LC3-associated phagocytosis (LAP), an important antifungal pathway that participates in the host defense regulation [78]. It was observed that melanin in the *Rhizopus* spore cell wall blocks phagosome responses, completely inhibiting phagosome maturation and allowing fungal intracellular persistence [75]. This fungistatic activity of macrophages and other phagocytes is thought to promote *Mucorales* virulence, prolonging fungal survival in the lungs and serving as transport of spores to other organs [78,79]. Therefore, it is suggested that macrophages' fungicidal activity is dependent on the spores development stage since lack of cell wall remodeling and germination, which results in the retention of the cell wall melanin, inhibits LAP and therefore causes intracellular persistence [78,80]. In addition, recognition and phagocyte binding of *Mucorales* seem to be dependent on the spore wall composition [78], and the receptors participating in this process include Toll-like receptors, especially TLR-2,

which plays an important role in *Rhizopus* recognition by neutrophils [75,76] and activation of proinflammatory cytokines such as IL-1 β and TNF α [76].

Platelets also participate in the host immune response during this infection, as they strongly bind to *Mucorales* spores and hyphae. Once the platelets bind the pathogen and are activated, they damage hyphae in a time-dependent manner through the secretion of granules with pro- and anti-inflammatory cytokines and chemokines with antifungal properties [77,81] as well as increasing their tendency to aggregate, which enhances clot formation and suppresses hyphal growth and dissemination [47,77,81]. It was even observed that platelet antifungal activity is greater than that of polymorphonuclear leucocytes [81,82]. Additionally, these cells express membrane-bound molecules that bind to endothelial cells, monocytes, and dendritic cells, activating them and enhancing the immune response against the fungus [83].

Natural killer (NK) cells are also considered to have an important role in the immune response against *Mucorales*. It has been observed that NK cells are activated by *R. oryzae* hyphae and damage this morphology, mainly by the protein perforin [84,85] and depending on the amount of fungal biomass [86]. However, direct contact of *R. oryzae* hyphae with these cells decreases secretion of IFN γ and RANTES (Regulated upon Activation, Normal T-Cell Expressed, and Presumably Secreted), which are important molecules that improve the fungicidal activity of macrophages and the host defense against fungi [84,86]. Therefore, these cells' activity is more effective in the early stage of the infection [85,86].

It has been demonstrated that *Mucorales* are capable of down-regulating genes involved in pathogen recognition, innate immune responses, and tissue repair mechanisms, facilitating fungal growth [87].

Although the knowledge regarding the adaptative response against *Mucorales* is scarce, it is already known that greater resistance to pulmonary mucormycosis is associated with an early Th-1 response, mediated by IFN γ and IL-2, while the infection control is mediated by the Th-17 response, with increased production of IL-17 and IL-2 by the spleen [88]. Just like in the pulmonary infection, in disseminated mucormycosis, IL-17 signaling and the Th1- response, through IFN γ signaling, are crucial for fungal clearance and thus control of the infection [88].

Finally, the patient's health conditions, such as diabetes and acidosis, alter the immune response against *Mucorales*. It has been widely reported that hyperglycemia causes phagocyte dysfunction [89] and suppresses T lymphocyte induction and IFN γ production [36], while ketoacidosis impairs chemotaxis and neutrophils functions [34,59,65], all of them factors that favor the fungus growth and dissemination.

2.4. Treatment

Proper mucormycosis treatment depends on the etiological agent since the different *Mucorales* species have different drug resistance profiles. The main antifungals used for the treatment of this mycosis are amphotericin B, posaconazole, isavuconazole, and itraconazole, and they have different responses against the major agents of human infection, including *Lichtheimia* spp., *Rhizopus* spp., *Cunninghamella* spp., and *Mucor* spp. [90]. The most active antifungal for all *Mucorales* species is amphotericin B, with low minimum inhibitory concentrations (MICs) in vitro; however, higher MICs have been reported for this drug against *Cunninghamella* spp. and *Rhizopus* spp. [91–96]. On the other hand, posaconazole, isavuconazole, and itraconazole activity in vitro has been reported to be limited against *Mucorales* and highly dependent on the species, with higher MICs in vitro than amphotericin B; however, in vivo studies have demonstrated that azoles can be active against these pathogens: itraconazole can be effective against *Rhizomucor*, *Syncephalastrum*, and *Absidia*, but its effect is limited against *Cunninghamella* spp. and *Mucor* spp.; posaconazole has good effectivity against *Absidia* spp. and *Mycocladus corymbifera* but needs higher MICs for *Rhizopus* spp. and *Cokeromyces recurvatus*; and isavuconazole has partial in vitro activity against most *Mucorales* except for *Mucor circinelloides* [90–98]. In the case of voriconazole, it has been found to have a poor antifungal effect in vitro against most *Mucorales*, such as

Mucor spp., *Rhizopus* spp., *Absidia* spp., *Cunninghamella* spp., and *Syncephalastrum* spp. [91]. Echinocandins have been reported to be active only against some *Mucorales* species in vitro but are thought to be a good option when used in combination with other drugs [93].

Combined therapy, such as antifungals plus surgical intervention, is usually related to a better mucormycosis outcome [99–101]. However, treatment preferences may vary depending on the mucormycosis clinical type: pulmonary, rhino-orbital/cerebral, and renal mucormycosis are treated preferably with concurrent antifungal and surgical therapy, while cutaneous mucormycosis can be treated just with antifungal drugs [102]. In most cases, if surgery and antifungal combined treatment are not administered on time, the disease progresses rapidly, causing the patient's death [103].

Liposomal amphotericin B is the first-line antifungal monotherapy for the treatment of mucormycosis with the involvement of various organs [104], but different effects have been observed depending on the etiological agent genus and species [100]. Amphotericin B deoxycholate can also be used, but due to its toxicity in the doses and durations needed to treat mucormycosis [105,106], it is restricted to cases where no other antifungal therapy is available [104]. Surgical debridement and intravenous amphotericin B, along with the control of the patient's underlying diseases, have proven to be an effective therapy for the control and treatment of mucormycosis [101].

Azoles such as posaconazole and isavuconazole are also considered first-line treatments [104]. Isavuconazole efficacy has been observed to be similar to amphotericin B [107,108] and is considered to be less hepatotoxic than other antifungals [109,110]. Posaconazole is also highly effective with a good tolerance [33,111], but due to its high oral bioavailability, the use of delayed-release tablets and intravenous formulation is recommended [112–115].

Evidence in animal models suggests that antifungal combination therapy can improve disease outcomes and survival rates [104]. Posaconazole in combination with amphotericin B or echinocandins shows a synergistic effect in vitro against some *Mucorales* species, a combination that might be used as good salvage therapy [116–119]. Moreover, posaconazole and amphotericin B in combination with surgical removal of damaged tissue have shown to be effective for aggressive mucormycosis infections [99,120,121]. In mucormycosis cases caused by trauma, combined therapy is especially recommended since mixed infection by several *Mucorales* species can be observed. For this, a combination of liposomal amphotericin B and either posaconazole or voriconazole can be used [122,123]. The reported cons of combined therapy are the potential added toxicity, drug interactions, and cost [104].

In the cases of refractory mucormycosis or toxicity to first-line therapy, some salvage treatments can be used. Itraconazole alone has been used to treat cutaneous mucormycosis caused by *M. irregularis* in patients with no underlying diseases and intolerance to amphotericin B [102] and, in combination with surgical treatment, leads to a favorable outcome in cases of cutaneous diseases in immunocompetent patients [118].

As already mentioned, the use of iron chelators such as deferoxamine is associated with a higher risk to develop this mycosis and a worsening of the disease, but newer iron chelators, such as deferiprone and deferasirox, have been successfully used to treat experimental mucormycosis [124].

In addition, immunotherapy strategies have also been used for the control of mucormycosis since anti-*Rhizopus* T cells from healthy donors show reactivity against *Mucorales* and enhance the phagocyte killing effect [125,126]. In addition, the use of IFN γ and GM-CDF stimulates human polymorphonuclear cells and increases *Rhizopus* hyphal damage [127]. A combination of immunotherapy and IFN γ was proven to be an effective treatment for intractable invasive mucormycosis [128].

3. COVID-19-Associated Mucormycosis

Although the first report of mucormycosis in the literature dates from 1855 [129], and despite having extremely high mortality rates [30], this infection has not received enough attention, as much information about the disease and its etiological agents is still unknown. However, with the surge of the COVID-19 pandemic, a rise in mucormycosis

cases has been reported [12,130], highlighting the severity and importance of both diseases, especially when combined. Before the COVID-19 pandemic, mucormycosis had a mortality rate of 50%, but now, the mortality of CAM has increased to 85% in India not only due to the COVID-19 infection but also due to crowded hospitals and inadequate infrastructure, ineffective healthcare resources, lack of healthcare workers, poor diagnosis, and lack of awareness [131,132]. Currently, CAM represents 0.3% of fungal COVID-19 coinfections [133].

The increase in CAM development has been mainly observed during the second wave of the COVID-19 pandemic, which might suggest a more effective association between mucormycosis and the SARS-CoV-2 delta variant, probably because it is more contagious and resistant to vaccines, with a higher risk of hospitalization and predisposition for the rhino-cerebral form, and also because of this variant's ability to affect the pancreas, predisposing to hyperglycemia [134].

The majority of CAM cases reported worldwide are from India, followed by the United States, Egypt, Iran, Brazil, and Chile, and a few cases have also been reported in the United Kingdom, France, Italy, Austria, and Mexico [135].

According to epidemiological reports, it has been observed that, just like COVID-19, CAM is mainly present in male patients with diabetes, hypertension, or treated with glucocorticoids [5,9,12,135–141]. Furthermore, in concordance with what has been observed in mucormycosis, the main clinical form of CAM is the rhino-orbital/cerebral, followed by pulmonary, cutaneous, disseminated, and gastrointestinal forms, with the most common etiological agents being *Rhizopus* spp. [12,130,135,141].

CAM has been reported in patients with active SARS-CoV-2 infection but also in patients already recovered, and although the majority of CAM cases were reported in severe COVID-19 patients, the mycosis has also been found in mild/moderate SARS-CoV-2 infections [135]. The first evidence of CAM is usually found 15 days after COVID-19 diagnosis, but it can take up to 90 days to detect the earliest symptoms [15,142].

To cause such an aggressive and lethal infection, the causative mucormycosis fungi take advantage of the many alterations that SARS-CoV-2 infection generates on the host, such as (Figure 1):

- i. Hyperglycemia, caused by the use of corticosteroids to treat COVID-19 [143] and dysregulation of the host receptor ACE2 (angiotensin-converting enzyme 2) observed during the viral infection [144,145] (explained in vii). Pre-existing diabetes is the main risk factor in most CAM cases [12] and is also related to an increase in the severity of SARS-CoV-2 infection [146];
- ii. Low pH, caused by diabetic ketoacidosis or metabolic acidosis caused by corticosteroid use [147], which reduces the leukocytes' phagocytic activity and impairs bronchoalveolar macrophages migration and functions [12,148];
- iii. Immunosuppression, caused by SARS-CoV-2 infection and hypoxia, corticosteroids, and tocilizumab use [148,149] or patients' previous comorbidities. Endothelial damage, thrombosis, and lymphopenia are usually observed during COVID-19, which contribute to the host immunosuppression [150,151];
- iv. Free iron availability, caused by hyperglycemia, the COVID-19 cytokine storm, or by acidosis. Hyperglycemia and diabetic ketoacidosis cause dissociation of iron from ferritin and lactoferrin, thus elevating free iron concentrations [152], and some cytokines, mainly IL-6, stimulate ferritin synthesis and decrease iron export, increasing intracellular iron storage [153–155] and causing tissue damage and thus the release of iron into circulation [156]. Therapeutic intervention with lactoferrin has been suggested to revert iron availability [157–159];
- v. Pulmonary changes, including vascular endothelitis, thrombosis, and angiogenesis, caused by SARS-CoV-2 infection, which provides a focal point for fungal growth and dissemination [103,160]. The damage to alveolar cells can also promote anaerobic glycolysis, which causes lactic acidosis [145];

- vi. Overexpression of endothelial cells GRP-78, caused by hyperglycemia, acidosis, and iron availability, which enables angiogenesis, hematogenous dissemination, and tissue necrosis [58];
- vii. Dysregulation of ACE2 by SARS-CoV-2. By being present in many organs and tissues, the alteration of the receptor ACE2 expression causes a suitable environment for the development of mucormycosis. During COVID-19, a downregulation of ACE2 has been observed in the lungs [161], which causes inflammation, leukocytes exudation, and altered pulmonary function and therefore poor oxygenation [144]. Additionally, the effect of the virus on ACE2 in the pancreatic beta cells causes hyperglycemia, while dysregulation of the receptor in the vascular endothelium causes endothelial damage and vascular thrombosis, leading to vascular endothelial injury and venous stasis, causing an increase in serum iron due to hemolysis [144,145];
- viii. Prolonged hospital stays and mechanical ventilation in severe COVID-19 cases expose the patient to fungal coinfections [15,103].

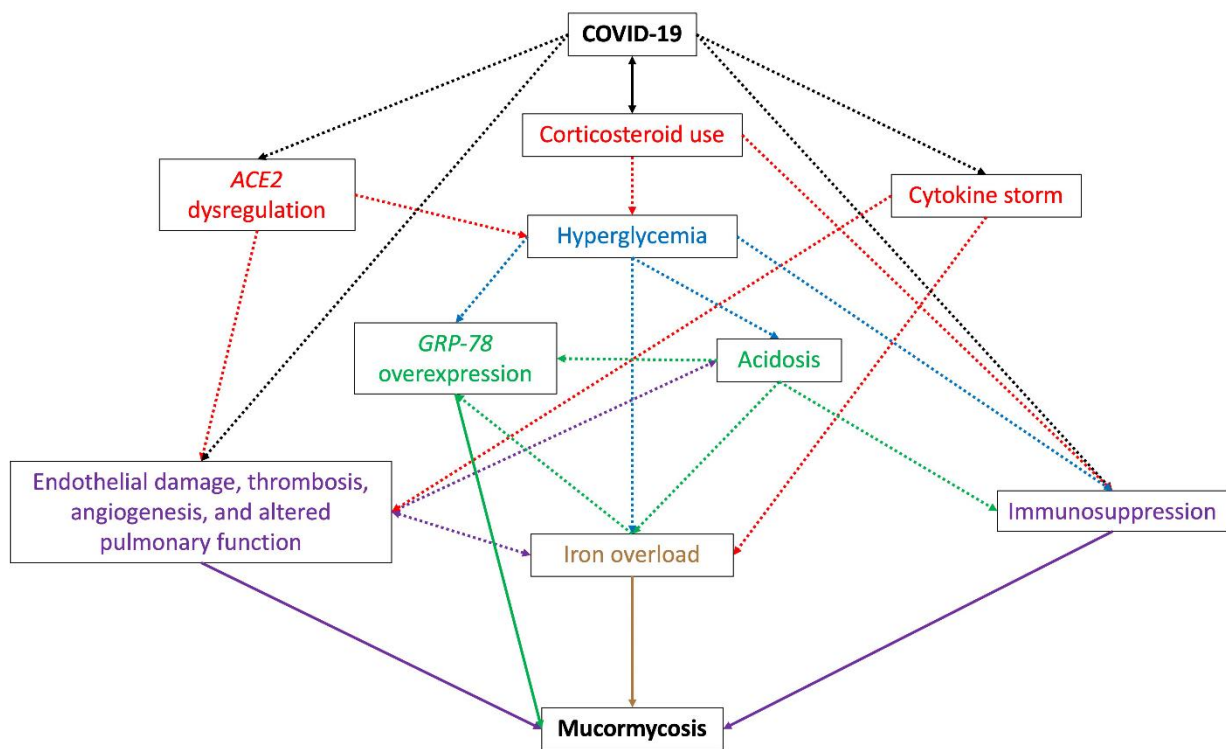


Figure 1. Schematic diagram representing the environment promoted by COVID-19 that predisposes the development of mucormycosis. The use of corticosteroids for COVID treatment and the dysregulation of ACE2 caused by SARS-CoV-2 create a hyperglycemic status in the patient, which causes overexpression of GRP-78, acidosis, and immunosuppression, this last also promoted by corticosteroid use, acidosis, and the COVID-19 itself. GRP-78 overexpression and acidosis are closely related since the presence of one promotes the development of the other, both causing iron overload; this last is also promoted by the cytokine storm observed during COVID-19. ACE2 dysregulation is related to the development of endothelial damage, thrombosis, angiogenesis, and altered pulmonary function, which can also be caused by the SARS-CoV-2 replication and the cytokine storm. Iron overload, GRP-78 overexpression, immunosuppression, endothelial damage, thrombosis, angiogenesis, and altered pulmonary function are directly related to mucormycosis development during COVID-19. Double black arrow: a risk factor for COVID-19 and mucormycosis infection. Dotted black lines: alterations directly caused by SARS-CoV-2 and COVID-19. Dotted red, blue, green, and purple lines: alterations caused by COVID-19. Purple, green, and brown lines: factors directly related to the development of mucormycosis.

In addition, the use of industrial oxygen in COVID-19 patients due to a shortage of medical oxygen and the re-use of oxygen masks is suggested to be related to the development of CAM, especially in third-world countries. Unlike medical oxygen, industrial oxygen is not purified nor stored in disinfected cylinders [141,162].

3.1. Clinical Manifestations

In patients with the rhino-orbital/cerebral form, the most commonly observed symptoms are orbital/facial pain and edema, followed by loss of vision, nasal blockage, and ptosis [163]. These patients may also present fever, headache, ear pain, nasal blockage and discharge, eyelid edema, conjunctival swelling, vision loss, proptosis, extraocular muscle and cranial nerve palsy, diplopia, periorbital pain, orbital/facial discoloration, black nasal crusts, periocular hypoesthesia, palatal ulcer, toothache and loose teeth, epistaxis, and facial deviation [163–166]. Computed tomography (CT) or magnetic resonance imaging (MRI) can show sinusitis, erosion of the nasal septum, oroantral fistula, hard palate, air in bony sinus structures, focal mucosal non-enhancement, panophthalmitis, orbital infiltration, skull base involvement, cerebral sinus thrombosis and vasculitis, border zone infarcts, and meningeal enhancement [166,167].

In patients with pulmonary involvement, the most common symptoms are fever, cough, dyspnea, and hypoxia, and radiographic findings might include consolidations, cavitory lung lesions, and bronchopleural fistula formations with empyema [5,16,168].

3.2. CAM Diagnosis and Treatment

Both the European Confederation of Medical Mycology (ECMM) and the Mycoses Study Group Education and Research Consortium have released a detailed guide to facilitate mucormycosis diagnosis and treatment [104], while the ECMM and the International Society for Human and Animal Mycology (ISHAM) have published a guideline to identify CAM and how to manage it [169].

The gold standard for mucormycosis diagnosis is culture and microbiological or histopathological examination of tissues from different lesions [104,145,170]. Direct microscopic inspection reveals wide, non-septate, ribbon-like hyaline hyphae [171]. Culture of clinical specimens is usually made on Sabouraud agar and potato dextrose agar at 37 °C since all *Mucorales* grow in these media in 2 to 7 days [172]. Histopathological examination of tissue samples reveals non-pigmented, thin-walled, ribbon-like hyphae, with right angle-branching [173]. However, sometimes and depending on the clinical form, the sample can be difficult to obtain, and its processing might damage the hyphae preventing its growth in culture [169,174]. In addition, morphological identification is challenging, since *Mucorales* can be misidentified as *Aspergillus* spp. [175]. In addition, blood cultures are usually negative even in disseminated cases [176].

For pulmonary mucormycosis, radiological features can be suggestive of the infection, but these are non-specific and can overlap with other fungal cases of pneumonia or COVID-19. A pulmonary CT scan can be used for the detection of the reverse halo, which is observed as ground-glass opacity surrounded by a ring of consolidation mainly in the peripheral locations of the lungs [104]. However, this feature can overlap with findings associated with SARS-CoV-2 infection, which results in missed or late diagnoses [177]. Besides, CAM can also be mistaken for other fungal infections, such as pulmonary aspergillosis, which is highly associated with COVID-19 acute respiratory distress syndrome. Cavitory lung lesions can be a little more specific when trying to distinguish between COVID-19 and fungal infection, but both mucormycosis and aspergillosis can present these lesions, making it hard to identify the etiological agent of the mycosis [178]. In rhino-orbital/cerebral mucormycosis, radiological features are more specific than those for pulmonary infection. CT and MRI of the brain and paranasal sinus can be used to observe mucosal thickening and sinuses opacification, edema, inflammation, or brain infarction [169].

Other techniques, such as conventional and quantitative PCR (polymerase chain reaction) targeting the internal transcribed spacer (ITS) [179], semi-nested PCR targeting the

18S and ITS [180], PCR and RFLP (restriction fragment length polymorphism) analyses of the 18S [181], and DNA sequencing of the *FTRI* [182–189], have been used, but despite being highly specific, these might vary in sensitivity, are not widely available, or are extremely expensive [104]. PCR techniques alone can identify only certain species, including *Mucor*, *Rhizopus*, *Lichtheimia*, and *Rhizormucor* [33,184,185,190,191], but are not fully standardized [104]. PCR combined with matrix-assisted laser desorption/ionization-time of flight (MALDI-TOF) can also be used for species-level identification with higher accuracy [104,192]. In addition, MALDI-TOF mass spectrometry has been used to identify species-specific fungal peptides from fungal isolates or direct clinical specimens in a fast and sensible way [193–195]. Finally, a breath-based biosensor has been also proposed, where the volatile sesquiterpene metabolite profiles from murine models is analyzed by thermal desorption gas chromatography/tandem mass spectrometry (GC-MS/MS), obtaining different profiles for each *Mucorales* species, which can also be distinguished from aspergillosis [196]. However, these diagnosis techniques are expensive and need specialized equipment, hindering their daily use.

Currently, there are no serological diagnostic methods for mucormycosis [197], but some serological assays have been tested, including immunohistochemistry [187–189], ELISA (enzyme-linked immunosorbent assays), immunoblots, immunodiffusion, and 1,3- β -D-glucan assay, with different levels of success [198,199]. In addition, a lateral flow immunoassay (LIFA) was developed using a monoclonal antibody against the cell wall fucomannan of *Mucorales*, proving to be highly sensitive for the diagnosis of invasive murine mucormycosis [199].

Some carbon assimilation commercial kits are available for the identification of the *Mucorales* species, such as the ID32C and API 50CH kits, that successfully identify species such as *Lichtheimia corymbifera*, *Lichtheimia ramosa*, and *Rhizomucor pusillus* [194,200]. However, these kits are not capable of identifying all of the many *Mucorales* species that cause mucormycosis and have shown high variability in the assimilation patterns among *R. oryzae* isolates [200]. Furthermore, antifungal susceptibility testing can be used for the identification of the etiological agent, including methods such as broth microdilution, disk diffusion, and agar screening, and the use of the commercial kits YeastOne and VITEK2, but these methodologies are available only for a few antifungals, and their results are often hard to interpret [201].

Therefore, diagnosis of CAM mostly relies on conventional culture and histopathological demonstration, which is time-consuming and with low sensitivity, delaying diagnosis and treatment [177].

A meta-analysis of published cases of CAM suggests that this infection is associated with high morbidity and mortality, mainly due to late diagnosis [177]. This study found that mucormycosis was diagnosed at a median of 10 days after COVID-19 diagnosis; for hospitalized patients that did not have any sign of mucormycosis on the day of admission, diagnosis took about 14.5 days after admission; in patients with uncontrolled diabetes, CAM was diagnosed in a median of 3.5 days after COVID-19 diagnosis, while in patients with controlled diabetes, diagnosis took 20 days; patients admitted to the ICU for COVID-19 advanced critical care were diagnosed at a median of 8 days after admission to the ICU. Diagnosis in these patients was made by histology or culture, and in some cases, samples were obtained post mortem [177]. All-cause mortality was reported in 49% of patients: for rhino-orbital/cerebral mucormycosis, mortality was reported in 37% of patients; for pulmonary, gastrointestinal, or disseminated mucormycosis, mortality was reported in 81% of patients. Among survivors with rhino-orbital/cerebral disease, loss of vision was reported in 46% of patients [177]. These data demonstrate that even in hospitalized patients, mucormycosis diagnosis takes too long, delaying treatment and increasing the patient's mortality and risk of developing long-term side effects.

The therapy approach for the management of CAM is similar to that of mucormycosis, and the early diagnosis is essential for a good outcome [104,169]. The first step in treating CAM is to control or eliminate underlying predisposing factors, such as diabetes, acidosis,

and corticosteroid use [104,169]. After this, the first recommended therapy is surgical resection and debridement of the affected tissues [104,169,202], followed by antifungal therapy for at least 6 weeks [104,141,169]. Amphotericin B, preferably its liposomal form, is the first-line therapy. In cases where amphotericin B cannot be used, posaconazole and isavuconazole can be used as salvage treatments [169]. Due to the current mucormycosis epidemic in India, a shortage of these antifungals has created the need to use other drugs. Although itraconazole is not recommended for the management of mucormycosis, it can be used as intravenous therapy [169].

Due to the limitations of antifungal drugs, which include side effects and optimal dosage, nanosystems have been used for the delivery of amphotericin B via oral, topical or pulmonary routes with promising results [203]. In these systems, the toxicity of the drugs has been reduced, and the route of administration has been optimized. In addition, the use of silver and zirconium oxide nanoparticles and nano-emulsion NB-201 themselves exhibit antifungal properties against *Mucorales* [204].

When CAM is being treated during active SARS-CoV-2 infection, potential drug-drug interactions of antifungals, antivirals, and immune therapies need to be addressed. For example, the administration of amphotericin B with steroids can cause hypokalemia in the patient, complicating the disease [141].

As new treatments are being tested for CAM, statin therapy has been suggested [205]. Statins have been shown to induce cytoprotective GRP-78 expression, decrease infection risk, and enhance the anti-CAM drug levels in plasma, as has been observed in in vitro studies with lovastatin, which causes apoptosis of *Mucor racemosus*, and gluvastatin and rosuvastatin, which have fungicidal effects against *Rhizomucor* and *Rhizopus* spp. [206]. Moreover, the combination of amphotericin B and atorvastatin/lovastatin showed a better effect against *R. arrhizus* than amphotericin B monotherapy [206].

In addition, anti-CotH3 and CotH7 antibodies have been found to protect mice with neutropenia and diabetes ketoacidosis against mucormycosis [207], while anti-integrin $\beta 1$ antibodies inhibit *R. delemar* damage of alveolar epithelial cells in mice with diabetes ketoacidosis infected with pulmonary mucormycosis [208].

The use of hyperbaric oxygen has been proven beneficial as a possible adjunctive treatment, especially in patients with diabetes [209], due to the fungicidal activity that high concentrations of oxygen have against *Mucorales* in vitro [210].

Probiotics, due to their anti-inflammatory activity and antifungal and anti-mycotoxigenic activities [211–215], are also being proposed as a treatment for CAM because although their efficiency has not been proven for *Mucorales*, it has been demonstrated in candidiasis and other fungal infections [216–219] and for COVID-19 with good results [220–224].

A treatment being proposed for COVID-19 and some fungal infections that is gaining popularity are retinoids or vitamin A. Retinoic acid, the retinol biologically active metabolite, regulates many mechanisms in the host, including inflammatory effects, innate and adaptive immune responses, cell proliferation and differentiation, antiviral effects, and angiogenesis [225–227]. Retinoids increase the differentiation of respiratory epithelial cells, which might reduce the pathogen shedding period of infected cells and accelerate the repair processes of epithelial damaged by infection or inflammatory response [228]. However, retinoids also cause inflammation, dryness, and increased fragility of the mucosal epithelia, probably facilitating the penetration and colonization of the pathogen in the host [229,230]. Vitamin A is also related to the stimulation of NK, DCs, and innate lymphoid cells, promotion of the secretory IgA response, IL2 receptor transcription, and lymphocyte development and maturation, enhancing the immune response [225,227]. Finally, retinoids have inhibitory effects on diseases with aberrant angiogenesis [231], such as that observed during COVID-19. It has been observed that retinoids reduce ACE2 expression, reducing the risk of infection, and it is suggested they might inhibit the protease activity of SARS-CoV-2, decreasing viral proliferation [232]. Mega doses of vitamin A are proposed as an affordable adjunct therapy for COVID-19 with minimal side effects [233]. Although there are no reports of retinoids activity against *Mucorales*, it has been proven they have in vitro

and in vivo antimycotic activity against *Candida albicans*, *Candida glabrata*, *Trichophyton* spp. [234], and *Aspergillus niger* [235], for which they are thought to be a possible treatment candidate for mucormycosis and thus also for CAM.

Drugs in the preclinical investigation, such as VT-1161, APX001A, and hemofungin, have been suggested as potential anti-*Mucorales* agents [236]. VT-1161 is a fungal CYP51 inhibitor gene responsible for voriconazole and fluconazole resistance in *R. oryzae*, which has shown a strong therapeutic action against *Rhizopus* spp., as observed by the increased survival rates of neutropenic mice with mucormycosis [237,238]; APX001A or fosmanogepix inhibits an important step of the glycosylphosphatidylinositol inositol post-translational pathway of surface proteins, which protects from *Rhizopus* infection in immunosuppressed mice [239]; hemofungin inhibits the in vitro growth of several *Mucorales*, including *Rhizopus* spp., and inhibits the final step of heme biosynthesis [240].

3.3. CAM Prevention and Outcome

The occurrence of CAM can be reduced up to a certain point, following several steps as suggested by [169]:

- During COVID-19 management, hyperglycemia should be strictly controlled;
- Corticosteroid therapy should only be used in patients with severe SARS-CoV-2 infection, for short periods and at low doses, just like other drugs that target the immune response, such as tocilizumab [210];
- The patient's exposition to *Mucorales* should be limited as much as possible by using face masks and avoiding being outdoors;
- Mass vaccination against COVID-19 can also help to reduce the chance to develop severe secondary complications [210].

Even with treatment, CAM morbidity and mortality is high, being about 40–50% in prevalent regions and 50–100% in non-prevalent regions [210,241], but the prognosis might vary depending on the site of involvement, with poorer prognosis in cases of rhino-orbital/cerebral form [5]. Additionally, early diagnosis is a key determinant of the prognosis, and due to the rapid dissemination of the infection, delayed treatment initiation can result in a twofold mortality increase (up to 80%) [210].

4. Concluding Remarks

The recent rise of the COVID-19 pandemic has highlighted the importance of mucormycosis worldwide. The lack of knowledge about mucormycosis and its etiological agents has complicated CAM diagnosis, treatment, and prevention and therefore has worsened the clinical management of COVID-19 patients, affecting health and the economy globally. Many efforts have been made to understand SARS-CoV-2 and to prevent and treat COVID-19, but the study of fungal coinfections, such as mucormycosis, is a priority for both basic and clinical research.

To improve the current global crisis, the study of opportunistic pathogens such as *Mucorales* needs to be addressed urgently. For example, neither molecular nor serological diagnosis methods are commercially available for the daily and rapid identification of this mycosis, which hinders diagnosis and delays treatment. Future efforts should be made in finding fungal antigenic molecules and host antibodies generated against them, developing fast and accessible molecular and serological diagnostic methods, and also in finding molecular markers for the identification of the mucormycosis etiological agents. The different antifungal resistance profiles of *Mucorales* species highlight the importance of fungal identification at the species level. Moreover, research in new antifungal therapies is needed to improve the infection outcome and decrease the mortality rate. As mentioned before, the typical antifungal drugs currently used have different responses depending on the etiological agent and are usually not very effective for severe cases if administered out of time. Moreover, since they have to be used in high doses and for long periods, they can be toxic, permanently damage organs, and can generate resistance. In addition, the shortage of these drugs in regions where mucormycosis is endemic is of concern since it limits the

treatment of many patients with severe forms of mycosis. Therefore, due to the lack of rapid and accessible diagnosis, treatment for mucormycosis can be challenging. One alternative to overcome these hurdles is to focus future research efforts on drug repurposing, looking for already known drugs with undiscovered antifungal activity.

There is not much that can be done to prevent CAM; simply, certain measures can be taken, such as avoiding mucormycosis risk factors, which can be complicated for patients with underlying diseases and in regions with poor healthcare systems. Therefore, we conclude that research efforts in mucormycosis are as important as those in COVID-19 to fight the current pandemics and associated infections.

Author Contributions: Conceptualization, L.C.G.-C. and H.M.M.-M.; methodology, L.C.G.-C. and H.M.M.-M.; formal analysis, L.C.G.-C. and H.M.M.-M.; investigation, L.C.G.-C. and H.M.M.-M.; data curation, L.C.G.-C. and H.M.M.-M.; writing—original draft preparation, L.C.G.-C. and H.M.M.-M.; writing—review and editing, L.C.G.-C. and H.M.M.-M.; supervision, H.M.M.-M.; project administration, H.M.M.-M.; funding acquisition, H.M.M.-M. All authors have read and agreed to the published version of the manuscript.

Funding: This work was supported by Consejo Nacional de Ciencia y Tecnología (ref. FC 2015-02-834; Ciencia de Frontera 2019-6380) and Red Temática Glicociencia en Salud (CONACYT-México). The funding sources that supported this work did not have any involvement in the design, acquisition, and analysis of data, and writing of the manuscript.

Institutional Review Board Statement: Not applicable.

Informed Consent Statement: Not applicable.

Data Availability Statement: Not applicable.

Conflicts of Interest: The authors declare no conflict of interest.

References

- Rodriguez-Morales, A.J.; Bonilla-Aldana, D.K.; Balbin-Ramon, G.J.; Rabaan, A.A.; Sah, R.; Paniz-Mondolfi, A.; Pagliano, P.; Esposito, S. History is repeating itself: Probable zoonotic spillover as the cause of the 2019 novel Coronavirus epidemic. *Le Infez. Med.* **2020**, *28*, 3–5.
- Krishnan, A.; Hamilton, J.P.; Alqahtani, S.A.; Woreta, T.A. COVID-19: An overview and a clinical update. *World J. Clin. Cases* **2021**, *9*, 8–23. [[CrossRef](#)] [[PubMed](#)]
- Gralinski, L.E.; Menachery, V.D. Return of the Coronavirus: 2019-nCoV. *Viruses* **2020**, *12*, 135. [[CrossRef](#)] [[PubMed](#)]
- Abdoli, A.; Falahi, S.; Kenarkoobi, A. COVID-19-associated opportunistic infections: A snapshot on the current reports. *Clin. Exp. Med.* **2021**, 1–20. [[CrossRef](#)] [[PubMed](#)]
- Patel, A.; Agarwal, R.; Rudramurthy, S.M.; Shevkani, M.; Xess, I.; Sharma, R.; Savio, J.; Sethuraman, N.; Madan, S.; Shastri, P.; et al. Multicenter Epidemiologic Study of Coronavirus Disease–Associated Mucormycosis, India. *Emerg. Infect. Dis.* **2021**, *27*, 2349–2359. [[CrossRef](#)]
- Song, G.; Liang, G.; Liu, W. Fungal Co-infections Associated with Global COVID-19 Pandemic: A Clinical and Diagnostic Perspective from China. *Mycopathologia* **2020**, *185*, 599–606. [[CrossRef](#)]
- Bhatt, K.; Agolli, A.; Patel, M.H.; Garimella, R.; Devi, M.; Garcia, E.; Amin, H.; Domingue, C.; Del Castillo, R.G.; Sanchez-Gonzalez, M. High mortality co-infections of COVID-19 patients: Mucormycosis and other fungal infections. *Discoveries* **2021**, *9*, e126. [[CrossRef](#)]
- Rodriguez-Morales, A.J.; Sah, R.; Millan-Oñate, J.; Gonzalez, A.; Montenegro-Idrogo, J.J.; Scherger, S.; Franco-Paredes, C.; Henao-Martínez, A.F. COVID-19 associated mucormycosis: The urgent need to reconsider the indiscriminate use of immunosuppressive drugs. *Ther. Adv. Infect. Dis.* **2021**, *8*, 204993612111027065. [[CrossRef](#)]
- Arora, S.; Hemmige, V.S.; Mandke, C.; Chansoria, M.; Rawat, S.K.; Dravid, A.; Sethi, Y.; Medikeri, G.; Jariwala, S.P.; Puius, Y.A. Online Registry of COVID-19–Associated Mucormycosis Cases, India, 2021. *Emerg. Infect. Dis.* **2021**, *27*, 2963–2965. [[CrossRef](#)]
- Bonifaz, A.; Tirado-Sánchez, A.; Hernández-Medel, M.L.; Araiza, J.; Kassack, J.J.; del Angel-Arenas, T.; Moisés-Hernández, J.F.; Paredes-Farrera, F.; Gómez-Apo, E.; Treviño-Rangel, R.D.J.; et al. Mucormycosis at a tertiary-care center in Mexico. A 35-year retrospective study of 214 cases. *Mycoses* **2020**, *64*, 372–380. [[CrossRef](#)]
- Bhatia, M. The rise of mucormycosis in COVID-19 patients in India. *Expert Rev. Anti-infective Ther.* **2021**, *20*, 137–138. [[CrossRef](#)] [[PubMed](#)]
- Singh, A.K.; Singh, R.; Joshi, S.R.; Misra, A. Mucormycosis in COVID-19: A systematic review of cases reported worldwide and in India. *Diabetes Metab. Syndr. Clin. Res. Rev.* **2021**, *15*, 102146. [[CrossRef](#)] [[PubMed](#)]

13. Junior, E.S.D.M.; Dos Santos, M.E.L.; Ribeiro, I.B.; Luz, G.D.O.; Baba, E.R.; Hirsch, B.S.; Funari, M.P.; De Moura, E.G.H. Rare and Fatal Gastrointestinal Mucormycosis (Zygomycosis) in a COVID-19 Patient: A Case Report. *Clin. Endosc.* **2020**, *53*, 746–749. [[CrossRef](#)]
14. Waizel-Haiat, S.; Guerrero-Paz, J.A.; Sanchez-Hurtado, L.; Calleja-Alarcon, S.; Romero-Gutierrez, L. A Case of Fatal Rhino-Orbital Mucormycosis Associated With New Onset Diabetic Ketoacidosis and COVID-19. *Cureus* **2021**, *13*, e13163. [[CrossRef](#)] [[PubMed](#)]
15. Khatri, A.; Chang, K.-M.; Berlinrut, I.; Wallach, F. Mucormycosis after Coronavirus disease 2019 infection in a heart transplant recipient—case report and review of literature. *J. Mycol. Med.* **2021**, *31*, 101125. [[CrossRef](#)] [[PubMed](#)]
16. Placik, D.A.; Taylor, W.L.; Wnuk, N.M. Bronchopleural fistula development in the setting of novel therapies for acute respiratory distress syndrome in SARS-CoV-2 pneumonia. *Radiol. Case Rep.* **2020**, *15*, 2378–2381. [[CrossRef](#)]
17. Werthman-Ehrenreich, A. Mucormycosis with orbital compartment syndrome in a patient with COVID-19. *Am. J. Emerg. Med.* **2020**, *42*, 264.e5–264.e8. [[CrossRef](#)]
18. Mekonnen, Z.K.; Ashraf, D.C.; Jankowski, T.; Grob, S.R.; Vagefi, M.R.; Kersten, R.C.; Simko, J.P.; Winn, B.J. Acute Invasive Rhino-Orbital Mucormycosis in a Patient With COVID-19-Associated Acute Respiratory Distress Syndrome. *Ophthalmic Plast. Reconstr. Surg.* **2020**, *37*, e40–e80. [[CrossRef](#)]
19. Kanwar, A.; Jordan, A.; Olewiler, S.; Wehberg, K.; Cortes, M.; Jackson, B. A Fatal Case of *Rhizopus azygosporus* Pneumonia Following COVID-19. *J. Fungi* **2021**, *7*, 174. [[CrossRef](#)]
20. Dallalzadeh, L.O.; Ozzello, D.J.; Liu, C.Y.; Kikkawa, D.O.; Korn, B.S. Secondary infection with rhino-orbital cerebral mucormycosis associated with COVID-19. *Orbit* **2021**, *2021*, 1–4. [[CrossRef](#)]
21. Johnson, A.K.; Ghazarian, Z.; Cendrowski, K.D.; Persichino, J.G. Pulmonary aspergillosis and mucormycosis in a patient with COVID-19. *Med. Mycol. Case Rep.* **2021**, *32*, 64–67. [[CrossRef](#)] [[PubMed](#)]
22. Hanley, B.; Naresh, K.; Roufousse, C.; Nicholson, A.G.; Weir, J.; Cooke, G.S.; Thursz, M.; Manousou, P.; Corbett, R.; Goldin, R.; et al. Histopathological findings and viral tropism in UK patients with severe fatal COVID-19: A post-mortem study. *Lancet Microbe* **2020**, *1*, e245–e253. [[CrossRef](#)]
23. Pasero, D.; Sanna, S.; Liperi, C.; Piredda, D.; Branca, G.P.; Casadio, L.; Simeo, R.; Buselli, A.; Rizzo, D.; Bussu, F.; et al. A challenging complication following SARS-CoV-2 infection: A case of pulmonary mucormycosis. *Infection* **2020**, *49*, 1055–1060. [[CrossRef](#)]
24. Bellanger, A.-P.; Navellou, J.-C.; Lepiller, Q.; Brion, A.; Brunel, A.-S.; Millon, L.; Berceanu, A. Mixed mold infection with *Aspergillus fumigatus* and *Rhizopus microsporus* in a severe acute respiratory syndrome Coronavirus 2 (SARS-CoV-2) patient. *Infect. Dis. Now* **2021**, *51*, 633–635. [[CrossRef](#)] [[PubMed](#)]
25. Zurl, C.; Hoenigl, M.; Schulz, E.; Hatzl, S.; Gorkiewicz, G.; Krause, R.; Eller, P.; Prattes, J. Autopsy Proven Pulmonary Mucormycosis Due to *Rhizopus microsporus* in a Critically Ill COVID-19 Patient with Underlying Hematological Malignancy. *J. Fungi* **2021**, *7*, 88. [[CrossRef](#)]
26. Ahmadikia, K.; Hashemi, S.J.; Khodavaisy, S.; Getso, M.I.; Alijani, N.; Badali, H.; Mirhendi, H.; Salehi, M.; Tabari, A.; Ardehali, M.M.; et al. The double-edged sword of systemic corticosteroid therapy in viral pneumonia: A case report and comparative review of influenza-associated mucormycosis versus COVID-19 associated mucormycosis. *Mycoses* **2021**, *64*, 798–808. [[CrossRef](#)]
27. Karimi-Galougahi, M.; Arastou, S.; Haseli, S. Fulminant mucormycosis complicating coronavirus disease 2019 (COVID-19). *Int. Forum Allergy Rhinol.* **2021**, *11*, 1029–1030. [[CrossRef](#)]
28. Veisi, A.; Bagheri, A.; Eshaghi, M.; Rikhtehgar, M.H.; Kanavi, M.R.; Farjad, R. Rhino-orbital mucormycosis during steroid therapy in COVID-19 patients: A case report. *Eur. J. Ophthalmol.* **2021**, *2021*, 1–6. [[CrossRef](#)]
29. Baldin, C.; Ibrahim, A.S. Molecular mechanisms of mucormycosis—The bitter and the sweet. *PLoS Pathog.* **2017**, *13*, e1006408. [[CrossRef](#)]
30. Gleissner, B.; Schilling, A.; Anagnostopolous, I.; Siehl, I.; Thiel, E. Improved Outcome of Zygomycosis in Patients with Hematological Diseases? *Leuk. Lymphoma* **2004**, *45*, 1351–1360. [[CrossRef](#)]
31. Dignani, M.C. Epidemiology of invasive fungal diseases on the basis of autopsy reports. *F1000Prime Rep.* **2014**, *6*, 81. [[CrossRef](#)] [[PubMed](#)]
32. Chakrabarti, A.; Singh, R. The emerging epidemiology of mould infections in developing countries. *Curr. Opin. Infect. Dis.* **2011**, *24*, 521–526. [[CrossRef](#)] [[PubMed](#)]
33. Skiada, A.; Pagano, L.; Groll, A.; Zimmerli, S.; Dupont, B.; Lagrou, K.; Lass-Flörl, C.; Bouza, E.; Klimko, N.; Gaustad, P.; et al. Zygomycosis in Europe: Analysis of 230 cases accrued by the registry of the European Confederation of Medical Mycology (ECMM) Working Group on Zygomycosis between 2005 and 2007. *Clin. Microbiol. Infect.* **2011**, *17*, 1859–1867. [[CrossRef](#)]
34. Ibrahim, A.S.; Spellberg, B.; Walsh, T.J.; Kontoyiannis, D.P. Pathogenesis of Mucormycosis. *Clin. Infect. Dis.* **2012**, *54*, S16–S22. [[CrossRef](#)]
35. Park, H.-R.; Voigt, K. Interaction of Zygomycetes with innate immune cells reconsidered with respect to ecology, morphology, evolution and infection biology: A mini-review. *Mycoses* **2014**, *57*, 31–39. [[CrossRef](#)] [[PubMed](#)]
36. Challa, S. Mucormycosis: Pathogenesis and Pathology. *Curr. Fungal Infect. Rep.* **2019**, *13*, 11–20. [[CrossRef](#)]
37. Spellberg, B.; Edwards, J., Jr.; Ibrahim, A. Novel Perspectives on Mucormycosis: Pathophysiology, Presentation, and Management. *Clin. Microbiol. Rev.* **2005**, *18*, 556–569. [[CrossRef](#)]

38. Hassan, M.A.; Voigt, K. Pathogenicity patterns of mucormycosis: Epidemiology, interaction with immune cells and virulence factors. *Med Mycol.* **2019**, *57*, S245–S256. [[CrossRef](#)]
39. Kwon-Chung, K.J. Taxonomy of Fungi Causing Mucormycosis and Entomophthoromycosis (Zygomycosis) and Nomenclature of the Disease: Molecular Mycologic Perspectives. *Clin. Infect. Dis.* **2012**, *54*, S8–S15. [[CrossRef](#)]
40. Petrikkos, G.; Skiada, A.; Lortholary, O.; Roilides, E.; Walsh, T.J.; Kontoyiannis, D.P. Epidemiology and Clinical Manifestations of Mucormycosis. *Clin. Infect. Dis.* **2012**, *54* (Suppl. 1), S23–S34. [[CrossRef](#)]
41. Farmakiotis, D.; Kontoyiannis, D.P. Mucormycoses. *Infect. Dis. Clin. North Am.* **2016**, *30*, 143–163. [[CrossRef](#)] [[PubMed](#)]
42. Sun, H.-Y.; Singh, N. Mucormycosis: Its contemporary face and management strategies. *Lancet Infect. Dis.* **2011**, *11*, 301–311. [[CrossRef](#)]
43. Richardson, M. The ecology of the Zygomycetes and its impact on environmental exposure. *Clin. Microbiol. Infect.* **2009**, *15*, 2–9. [[CrossRef](#)]
44. Idnurm, A. Sex Determination in the First-Described Sexual Fungus. *Eukaryot. Cell* **2011**, *10*, 1485–1491. [[CrossRef](#)]
45. Katragkou, A.; Walsh, T.J.; Roilides, E. Why is mucormycosis more difficult to cure than more common mycoses? *Clin. Microbiol. Infect.* **2014**, *20*, 74–81. [[CrossRef](#)] [[PubMed](#)]
46. Spellberg, B. Mucormycosis pathogenesis: Beyond Rhizopus. *Virulence* **2017**, *8*, 1481–1482. [[CrossRef](#)] [[PubMed](#)]
47. Schulze, B.; Rambach, G.; Schwartz, V.U.; Voigt, K.; Schubert, K.; Speth, C.; Jacobsen, I.D. Ketoacidosis alone does not predispose to mucormycosis by Lichtheimia in a murine pulmonary infection model. *Virulence* **2017**, *8*, 1657–1667. [[CrossRef](#)]
48. Chandra, S.; Sharma, S.; Vats, R.; Pandey, S. Isolated cerebral mucormycosis masquerading as a tumor in an immunocompetent patient. *Autops. Case Rep.* **2020**, *11*, e2020233. [[CrossRef](#)]
49. Roden, M.M.; Zaoutis, T.E.; Buchanan, W.L.; Knudsen, T.A.; Sarkisova, T.A.; Schaufele, R.L.; Sein, M.; Sein, T.; Chiou, C.C.; Chu, J.H.; et al. Epidemiology and Outcome of Zygomycosis: A Review of 929 Reported Cases. *Clin. Infect. Dis.* **2005**, *41*, 634–653. [[CrossRef](#)]
50. Petrikkos, G.; Tsioutis, C. Recent Advances in the Pathogenesis of Mucormycoses. *Clin. Ther.* **2018**, *40*, 894–902. [[CrossRef](#)]
51. Artis, W.M.; Fountain, J.A.; Delcher, H.K.; Jones, H.E. A Mechanism of Susceptibility to Mucormycosis in Diabetic Ketoacidosis Transferrin and Iron Availability. *Diabetes* **1982**, *31*, 1109–1114. [[CrossRef](#)] [[PubMed](#)]
52. Lamaris, G.A.; Ben-Ami, R.; Lewis, R.; Chamilos, G.; Samonis, G.; Kontoyiannis, D.P. Increased Virulence of Zygomycetes Organisms Following Exposure to Voriconazole: A Study Involving Fly and Murine Models of Zygomycosis. *J. Infect. Dis.* **2009**, *199*, 1399–1406. [[CrossRef](#)] [[PubMed](#)]
53. Benedict, K.; Park, B.J. Invasive Fungal Infections after Natural Disasters. *Emerg. Infect. Dis.* **2014**, *20*, 349–355. [[CrossRef](#)] [[PubMed](#)]
54. Sugar, A.M. Mucormycosis. *Clin. Infect. Dis.* **1992**, *14*, S126–S129. [[CrossRef](#)] [[PubMed](#)]
55. Lewis, R.E.; Kontoyiannis, D.P. Epidemiology and treatment of mucormycosis. *Futur. Microbiol.* **2013**, *8*, 1163–1175. [[CrossRef](#)]
56. Ma, L.-J.; Ibrahim, A.S.; Skory, C.; Grabherr, M.G.; Burger, G.; Butler, M.; Elias, M.; Idnurm, A.; Lang, B.F.; Sone, T.; et al. Genomic Analysis of the Basal Lineage Fungus *Rhizopus oryzae* Reveals a Whole-Genome Duplication. *PLoS Genet.* **2009**, *5*, e1000549. [[CrossRef](#)]
57. Ibrahim, A.S.; Gebremariam, T.; Lin, L.; Luo, G.; Husseiny, M.I.; Skory, C.D.; Fu, Y.; French, S.W.; Edwards, J.E., Jr.; Spellberg, B. The high affinity iron permease is a key virulence factor required for *Rhizopus oryzae* pathogenesis. *Mol. Microbiol.* **2010**, *77*, 587–604. [[CrossRef](#)]
58. Liu, M.; Spellberg, B.; Phan, Q.T.; Fu, Y.; Fu, Y.; Lee, A.; Edwards, J.E.; Filler, S.G.; Ibrahim, A.S. The endothelial cell receptor GRP78 is required for mucormycosis pathogenesis in diabetic mice. *J. Clin. Investig.* **2010**, *120*, 1914–1924. [[CrossRef](#)]
59. Binder, U.; Maurer, E.; Lass-Flörl, C. Mucormycosis—from the pathogens to the disease. *Clin. Microbiol. Infect.* **2014**, *20*, 60–66. [[CrossRef](#)]
60. Tissot, F.; Agrawal, S.; Pagano, L.; Petrikkos, G.; Groll, A.H.; Skiada, A.; Lass-Flörl, C.; Calandra, T.; Viscoli, C.; Herbrecht, R. ECIL-6 guidelines for the treatment of invasive candidiasis, aspergillosis and mucormycosis in leukemia and hematopoietic stem cell transplant patients. *Haematologica* **2016**, *102*, 433–444. [[CrossRef](#)]
61. Wang, H.L.; Hesseltine, C.W. Studies on the extracellular proteolytic enzymes of *rhizopus oligosporus*. *Can. J. Microbiol.* **1965**, *11*, 727–732. [[CrossRef](#)] [[PubMed](#)]
62. Staib, F. Extracellular proteolysis by Mucoraceae in serum-albumin agar tested by the agar block method. *Mycoses* **2009**, *34*, 231–233. [[CrossRef](#)]
63. Schoen, C.; Reichard, U.; Monod, M.; Kratzin, H.D.; Rüchel, R. Molecular cloning of an extracellular aspartic proteinase from *Rhizopus microsporus* and evidence for its expression during infection. *Med Mycol.* **2002**, *40*, 61–71. [[CrossRef](#)]
64. Spreer, A.; Rüchel, R.; Reichard, U. Characterization of an extracellular subtilisin protease of *Rhizopus microsporus* and evidence for its expression during invasive rhino-orbital mycosis. *Med Mycol.* **2006**, *44*, 723–731. [[CrossRef](#)]
65. Ribes, J.A.; Vanover-Sams, C.L.; Baker, D.J. Zygomycetes in Human Disease. *Clin. Microbiol. Rev.* **2000**, *13*, 236–301. [[CrossRef](#)] [[PubMed](#)]
66. Gebremariam, T.; Liu, M.; Luo, G.; Bruno, V.; Phan, Q.T.; Waring, A.J.; Edwards, J.E.; Filler, S.G.; Yeaman, M.R.; Ibrahim, A.S. CotH3 mediates fungal invasion of host cells during mucormycosis. *J. Clin. Investig.* **2013**, *124*, 237–250. [[CrossRef](#)]

67. Chibucos, M.C.; Soliman, S.; Gebremariam, T.; Lee, H.; Daugherty, S.; Orvis, J.; Shetty, A.; Crabtree, J.; Hazen, T.H.; Etienne, K.A.; et al. An integrated genomic and transcriptomic survey of mucormycosis-causing fungi. *Nat. Commun.* **2016**, *7*, 12218. [[CrossRef](#)] [[PubMed](#)]
68. Cantinieaux, B.; Janssens, A.; Boelaert, J.; Lejeune, M.; Vermyn, C.; Kerrels, V.; Cornu, G.; Winand, J.; Fondu, P. Ferritin-associated iron induces neutrophil dysfunction in hemosiderosis. *J. Lab. Clin. Med.* **1999**, *133*, 353–361. [[CrossRef](#)]
69. Shirazi, F.; Kontoyiannis, D.P.; Ibrahim, A.S. Iron starvation induces apoptosis in rhizopus oryzae in vitro. *Virulence* **2015**, *6*, 121–126. [[CrossRef](#)]
70. Gebremariam, T.; Lin, L.; Liu, M.; Kontoyiannis, D.P.; French, S.; Edwards, J.E.; Filler, S.G.; Ibrahim, A.S. Bicarbonate correction of ketoacidosis alters host-pathogen interactions and alleviates mucormycosis. *J. Clin. Investig.* **2016**, *126*, 2280–2294. [[CrossRef](#)]
71. Thieken, A.; Winkelmann, G.; Winkelmann, G. Rhizoferrin: A complexed siderophore of the mucorales and entomophthorales (Zygomycetes). *FEMS Microbiol. Lett.* **1992**, *94*, 37–41. [[CrossRef](#)]
72. De Locht, M.; Boelaert, J.R.; Schneider, Y.-J. Iron uptake from ferrioxamine and from ferrirhizoferrin by germinating spores of rhizopus microsporus. *Biochem. Pharmacol.* **1994**, *47*, 1843–1850. [[CrossRef](#)]
73. Boelaert, J.R.; De Locht, M.; Van Cutsem, J.; Kerrels, V.; Cantinieaux, B.; Verdonck, A.; Van Landuyt, H.W.; Schneider, Y.-J. Mucormycosis during deferoxamine therapy is a siderophore-mediated infection. In vitro and in vivo animal studies. *J. Clin. Investig.* **1993**, *91*, 1979–1986. [[CrossRef](#)]
74. Liu, M.; Lin, L.; Gebremariam, T.; Luo, G.; Skory, C.D.; French, S.W.; Chou, T.-F.; Edwards, J.E., Jr.; Ibrahim, A.S. Fob1 and Fob2 Proteins Are Virulence Determinants of Rhizopus oryzae via Facilitating Iron Uptake from Ferrioxamine. *PLoS Pathog.* **2015**, *11*, e1004842. [[CrossRef](#)] [[PubMed](#)]
75. Roilides, E.; Kontoyiannis, D.P.; Walsh, T.J. Host Defenses Against Zygomycetes. *Clin. Infect. Dis.* **2012**, *54*, S61–S66. [[CrossRef](#)] [[PubMed](#)]
76. Chamilos, G.; Lewis, R.E.; Lamaris, G.; Walsh, T.J.; Kontoyiannis, D.P. Zygomycetes Hyphae Trigger an Early, Robust Proinflammatory Response in Human Polymorphonuclear Neutrophils through Toll-Like Receptor 2 Induction but Display Relative Resistance to Oxidative Damage. *Antimicrob. Agents Chemother.* **2008**, *52*, 722–724. [[CrossRef](#)]
77. Ibrahim, A.S.; Voelz, K. The mucormycete–host interface. *Curr. Opin. Microbiol.* **2017**, *40*, 40–45. [[CrossRef](#)]
78. Andrianaki, A.M.; Kyrmizi, I.; Thanopoulou, K.; Baldin, C.; Drakos, E.; Soliman, S.S.M.; Shetty, A.C.; McCracken, C.; Akoumianaki, T.; Stylianou, K.; et al. Iron restriction inside macrophages regulates pulmonary host defense against Rhizopus species. *Nat. Commun.* **2018**, *9*, 1–17. [[CrossRef](#)]
79. Kraibooj, K.; Park, H.-R.; Dahse, H.-M.; Skerka, C.; Voigt, K.; Figge, M.T. Virulent strain of Lichtheimia corymbifera shows increased phagocytosis by macrophages as revealed by automated microscopy image analysis. *Mycoses* **2014**, *57*, 56–66. [[CrossRef](#)]
80. Ghuman, H.; Voelz, K. Innate and Adaptive Immunity to Mucorales. *J. Fungi* **2017**, *3*, 48. [[CrossRef](#)]
81. Perkhofer, S.; Kainzner, B.; Kehrel, B.E.; Dierich, M.P.; Nussbaumer, W.; Lass-Flörl, C. Potential Antifungal Effects of Human Platelets against Zygomycetes In Vitro. *J. Infect. Dis.* **2009**, *200*, 1176–1179. [[CrossRef](#)] [[PubMed](#)]
82. Simitopoulou, M.; Roilides, E.; Maloukou, A.; Gil-Lamaignere, C.; Walsh, T.J. Interaction of amphotericin B lipid formulations and triazoles with human polymorphonuclear leucocytes for antifungal activity against Zygomycetes. *Mycoses* **2008**, *51*, 147–154. [[CrossRef](#)] [[PubMed](#)]
83. Speth, C.; Lass-Flörl, C.; Rambach, G. Platelet immunology in fungal infections. *Thromb. Haemost.* **2014**, *112*, 632–639. [[CrossRef](#)] [[PubMed](#)]
84. Schmidt, S.; Tramsen, L.; Perkhofer, S.; Lass-Flörl, C.; Hanisch, M.; Röger, F.; Klingebiel, T.; Koehl, U.; Lehrnbecher, T. Rhizopus oryzae hyphae are damaged by human natural killer (NK) cells, but suppress NK cell mediated immunity. *Immunobiology* **2013**, *218*, 939–944. [[CrossRef](#)]
85. Schmidt, S.; Tramsen, L.; Lehrnbecher, T. Natural Killer Cells in Antifungal Immunity. *Front. Immunol.* **2017**, *8*, 1623. [[CrossRef](#)]
86. Schmidt, S.; Schneider, A.; Demir, A.; Lass-Flörl, C.; Lehrnbecher, T. Natural killer cell-mediated damage of clinical isolates of mucormycetes. *Mycoses* **2015**, *59*, 34–38. [[CrossRef](#)]
87. Chamilos, G.; Lewis, R.E.; Hu, J.; Xiao, L.; Zal, T.; Gilliet, M.; Halder, G.; Kontoyiannis, D.P. *Drosophila melanogaster* as a model host to dissect the immunopathogenesis of zygomycosis. *Proc. Natl. Acad. Sci. USA* **2008**, *105*, 9367–9372. [[CrossRef](#)]
88. dos Santos, A.R.; Fraga-Silva, T.F.; Almeida-Donanzam, D.D.F.; dos Santos, R.F.; Finato, A.C.; Soares, C.T.; Lara, V.S.; Almeida, N.L.M.; Andrade, M.I.; de Arruda, O.S.; et al. IFN- γ Mediated Signaling Improves Fungal Clearance in Experimental Pulmonary Mucormycosis. *Mycopathologia* **2022**, *187*, 15–30. [[CrossRef](#)]
89. Chinn, R.Y.; Diamond, R.D. Generation of chemotactic factors by Rhizopus oryzae in the presence and absence of serum: Relationship to hyphal damage mediated by human neutrophils and effects of hyperglycemia and ketoacidosis. *Infect. Immun.* **1982**, *38*, 1123–1129. [[CrossRef](#)]
90. Borman, A.; Fraser, M.; Patterson, Z.; Palmer, M.; Johnson, E. In Vitro Antifungal Drug Resistance Profiles of Clinically Relevant Members of the Mucorales (Mucoromycota) Especially with the Newer Triazoles. *J. Fungi* **2021**, *7*, 271. [[CrossRef](#)]
91. Guinea, J.; Peláez, T.; Recio, S.; Torres-Narbona, M.; Bouza, E. In Vitro Antifungal Activities of Isavuconazole (BAL4815), Voriconazole, and Fluconazole against 1,007 Isolates of Zygomycete, *Candida*, *Aspergillus*, *Fusarium*, and *Scedosporium* Species. *Antimicrob. Agents Chemother.* **2008**, *52*, 1396–1400. [[CrossRef](#)] [[PubMed](#)]
92. Alastruey-Izquierdo, A.; Castelli, M.; Cuesta, I.; Zaragoza, O.; Monzón, A.; Mellado, E.; Rodríguez-Tudela, J. In vitro activity of antifungals against Zygomycetes. *Clin. Microbiol. Infect.* **2009**, *15*, 71–76. [[CrossRef](#)] [[PubMed](#)]

93. Alastruey-Izquierdo, A.; Cuesta, I.; Walther, G.; Cuenca-Estrella, M.; Rodriguez-Tudela, J.L. Antifungal Susceptibility Profile of Human-Pathogenic Species of *Lichtheimia*. *Antimicrob. Agents Chemother.* **2010**, *54*, 3058–3060. [[CrossRef](#)] [[PubMed](#)]
94. Chowdhary, A.; Singh, P.K.; Kathuria, S.; Hagen, F.; Meis, J.F. Comparison of the EUCAST and CLSI Broth Microdilution Methods for Testing Isavuconazole, Posaconazole, and Amphotericin B against Molecularly Identified Mucorales Species. *Antimicrob. Agents Chemother.* **2015**, *59*, 7882–7887. [[CrossRef](#)]
95. Maurer, E.; Binder, U.; Sparber, M.; Lackner, M.; Caramalho, R.; Lass-Flörl, C. Susceptibility Profiles of Amphotericin B and Posaconazole against Clinically Relevant Mucorales Species under Hypoxic Conditions. *Antimicrob. Agents Chemother.* **2015**, *59*, 1344–1346. [[CrossRef](#)]
96. Borman, A.M.; Fraser, M.; Palmer, M.D.; Szekely, A.; Houldsworth, M.; Patterson, Z.; Johnson, E.M. MIC Distributions and Evaluation of Fungicidal Activity for Amphotericin B, Itraconazole, Voriconazole, Posaconazole and Caspofungin and 20 Species of Pathogenic Filamentous Fungi Determined Using the CLSI Broth Microdilution Method. *J. Fungi* **2017**, *3*, 27. [[CrossRef](#)]
97. Perkhofer, S.; Lechner, V.; Lass-Flörl, C. In Vitro Activity of Isavuconazole against *Aspergillus* Species and Zygomycetes According to the Methodology of the European Committee on Antimicrobial Susceptibility Testing. *Antimicrob. Agents Chemother.* **2009**, *53*, 1645–1647. [[CrossRef](#)]
98. Arendrup, M.C.; Jensen, R.H.; Meletiadis, J. In Vitro Activity of Isavuconazole and Comparators against Clinical Isolates of the Mucorales Order. *Antimicrob. Agents Chemother.* **2015**, *59*, 7735–7742. [[CrossRef](#)]
99. Van Sickels, N.; Hoffman, J.; Stuke, L.; Kempe, K. Survival of a Patient With Trauma-Induced Mucormycosis Using an Aggressive Surgical and Medical Approach. *J. Trauma: Inj. Infect. Crit. Care* **2011**, *70*, 507–509. [[CrossRef](#)]
100. Morace, G.; Borghi, E. Invasive Mold Infections: Virulence and Pathogenesis of Mucorales. *Int. J. Microbiol.* **2012**, *2012*, 349278. [[CrossRef](#)]
101. Ravi, P.; Ramadorai, A.; Narayanan, V. Rhinocerebral mucormycosis: A prospective analysis of an effective treatment protocol. *Ann. Maxillofac. Surg.* **2019**, *9*, 192–196. [[CrossRef](#)]
102. Wei, L.-W.; Zhu, P.-Q.; Chen, X.-Q.; Yu, J. Mucormycosis in Mainland China: A Systematic Review of Case Reports. *Mycopathologia* **2021**, *187*, 1–14. [[CrossRef](#)]
103. Mahalaxmi, I.; Jayaramayya, K.; Venkatesan, D.; Subramaniam, M.D.; Renu, K.; Vijayakumar, P.; Narayanasamy, A.; Gopalakrishnan, A.V.; Kumar, N.S.; Sivaprakash, P.; et al. Mucormycosis: An opportunistic pathogen during COVID-19. *Environ. Res.* **2021**, *201*, 111643. [[CrossRef](#)]
104. Cornely, O.A.; Alastruey-Izquierdo, A.; Arenz, D.; Chen, S.C.A.; Dannaoui, E.; Hochhegger, B.; Hoenigl, M.; Jensen, H.E.; Lagrou, K.; Lewis, R.E.; et al. Global guideline for the diagnosis and management of mucormycosis: An initiative of the European Confederation of Medical Mycology in cooperation with the Mycoses Study Group Education and Research Consortium. *Lancet Infect. Dis.* **2019**, *19*, e405–e421. [[CrossRef](#)]
105. Walsh, T.J.; Finberg, R.W.; Arndt, C.; Hiemenz, J.; Schwartz, C.; Bodensteiner, D.; Pappas, P.; Seibel, N.; Greenberg, R.N.; Dummer, S.; et al. Liposomal amphotericin B for empirical therapy in patients with persistent fever and neutropenia. *N. Engl. J. Med.* **1999**, *340*, 764–771. [[CrossRef](#)]
106. Ullmann, A.J.; Sanz, M.A.; Tramarin, A.; Barnes, R.A.; Wu, W.; Gerlach, B.A.; Krobot, K.J.; Gerth, W.C.; Longitudinal Evaluation of Antifungal Drugs (LEAD I) Investigators. Prospective Study of Amphotericin B Formulations in Immunocompromised Patients in 4 European Countries. *Clin. Infect. Dis.* **2006**, *43*, e29–e38. [[CrossRef](#)]
107. Marty, F.M.; Ostrosky-Zeichner, L.; Cornely, O.A.; Mullane, K.M.; Perfect, J.R.; Thompson, G.R.; Alangaden, G.J.; Brown, J.M.; Fredricks, D.N.; Heinz, W.J.; et al. Isavuconazole treatment for mucormycosis: A single-arm open-label trial and case-control analysis. *Lancet Infect. Dis.* **2016**, *16*, 828–837. [[CrossRef](#)]
108. Roilides, E.; Antachopoulos, C. Isavuconazole: An azole active against mucormycosis. *Lancet Infect. Dis.* **2016**, *16*, 761–762. [[CrossRef](#)]
109. Maertens, J.A.; Raad, I.I.; Marr, K.A.; Patterson, T.; Kontoyiannis, D.P.; Cornely, O.; Bow, E.J.; Rahav, G.; Neofytos, D.; Aoun, M.; et al. Isavuconazole versus voriconazole for primary treatment of invasive mould disease caused by *Aspergillus* and other filamentous fungi (SECURE): A phase 3, randomised-controlled, non-inferiority trial. *Lancet* **2015**, *387*, 760–769. [[CrossRef](#)]
110. Mellingshoff, S.C.; Bassetti, M.; Dörfel, D.; Hagel, S.; Lehnert, N.; Plis, A.; Schalk, E.; Vena, A.; Cornely, O.A. Isavuconazole shortens the QTc interval. *Mycoses* **2017**, *61*, 256–260. [[CrossRef](#)]
111. Ruping, M.J.G.T.; Heinz, W.J.; Kindo, A.J.; Rickerts, V.; Lass-Flörl, C.; Beisel, C.; Herbrecht, R.; Roth, Y.; Silling, G.; Ullmann, A.J.; et al. Forty-one recent cases of invasive zygomycosis from a global clinical registry. *J. Antimicrob. Chemother.* **2009**, *65*, 296–302. [[CrossRef](#)]
112. Maertens, J.; Cornely, O.A.; Ullmann, A.J.; Heinz, W.J.; Krishna, G.; Patino, H.; Caceres, M.; Kartsonis, N.; Waskin, H.; Robertson, M.N. Phase 1B Study of the Pharmacokinetics and Safety of Posaconazole Intravenous Solution in Patients at Risk for Invasive Fungal Disease. *Antimicrob. Agents Chemother.* **2014**, *58*, 3610–3617. [[CrossRef](#)]
113. Duarte, R.F.; López-Jiménez, J.; Cornely, O.A.; Laverdiere, M.; Helfgott, D.; Haider, S.; Chandrasekar, P.; Langston, A.; Perfect, J.; Ma, L.; et al. Phase 1b Study of New Posaconazole Tablet for Prevention of Invasive Fungal Infections in High-Risk Patients with Neutropenia. *Antimicrob. Agents Chemother.* **2014**, *58*, 5758–5765. [[CrossRef](#)]
114. Cornely, O.A.; Duarte, R.F.; Haider, S.; Chandrasekar, P.; Helfgott, D.; Jiménez, J.L.; Candoni, A.; Raad, I.; Laverdiere, M.; Langston, A.; et al. Phase 3 pharmacokinetics and safety study of a posaconazole tablet formulation in patients at risk for invasive fungal disease. *J. Antimicrob. Chemother.* **2015**, *71*, 718–726. [[CrossRef](#)]

115. Cornely, O.A.; Robertson, M.N.; Haider, S.; Grigg, A.; Geddes, M.; Aoun, M.; Heinz, W.J.; Raad, I.; Schanz, U.; Meyer, R.G.; et al. Pharmacokinetics and safety results from the Phase 3 randomized, open-label, study of intravenous posaconazole in patients at risk of invasive fungal disease. *J. Antimicrob. Chemother.* **2017**, *72*, 3406–3413. [[CrossRef](#)]
116. Perkhofer, S.; Locher, M.; Cuenca-Estrella, M.; Rüchel, R.; Würzner, R.; Dierich, M.P.; Lass-Flörl, C. Posaconazole Enhances the Activity of Amphotericin B against Hyphae of Zygomycetes In Vitro. *Antimicrob. Agents Chemother.* **2008**, *52*, 2636–2638. [[CrossRef](#)]
117. Song, Y.; Qiao, J.; Giovanni, G.; Liu, G.; Yang, H.; Wu, J.; Chen, J. Mucormycosis in renal transplant recipients: Review of 174 reported cases. *BMC Infect. Dis.* **2017**, *17*, 283. [[CrossRef](#)]
118. Jeong, W.; Keighley, C.; Wolfe, R.; Lee, W.L.; Slavin, M.A.; Chen, S.C.-A.; Kong, D.C. Contemporary management and clinical outcomes of mucormycosis: A systematic review and meta-analysis of case reports. *Int. J. Antimicrob. Agents* **2019**, *53*, 589–597. [[CrossRef](#)]
119. Vehreschild, J.J.; Birtel, A.; Vehreschild, M.J.G.T.; Liss, B.J.; Farowski, F.; Kochanek, M.; Sieniawski, M.; Steinbach, A.; Wahlers, K.; Fätkenheuer, G.; et al. Mucormycosis treated with posaconazole: Review of 96 case reports. *Crit. Rev. Microbiol.* **2012**, *39*, 310–324. [[CrossRef](#)]
120. Lebeau, O.; Van Delden, C.; Garbino, J.; Robert, J.; Lamoth, F.; Passweg, J.; Chalandon, Y. Disseminated *Rhizopus microsporus* infection cured by salvage allogeneic hematopoietic stem cell transplantation, antifungal combination therapy, and surgical resection. *Transpl. Infect. Dis.* **2010**, *12*, 269–272. [[CrossRef](#)]
121. Roux, B.G.-L.; Méchinaud, F.; Gay-Andrieu, F.; Lortholary, O.; Dannaoui, E.; Hoinard, D.; Corradini, N. Successful Triple Combination Therapy of Disseminated *Absidia corymbifera* Infection in an Adolescent With Osteosarcoma. *J. Pediatr. Hematol.* **2010**, *32*, 131–133. [[CrossRef](#)]
122. Warkentien, T.; Rodriguez, C.; Lloyd, B.; Wells, J.; Weintrob, A.; Dunne, J.R.; Ganesan, A.; Li, P.; Bradley, W.; Gaskins, L.J.; et al. Invasive Mold Infections Following Combat-related Injuries. *Clin. Infect. Dis.* **2012**, *55*, 1441–1449. [[CrossRef](#)]
123. Rodriguez, C.J.; Tribble, D.R.; Malone, D.L.; Murray, C.K.; Jessie, E.M.; Khan, M.; Fleming, M.E.; Potter, B.K.; Gordon, W.T.; Shackelford, S.A. Treatment of Suspected Invasive Fungal Infection in War Wounds. *Mil. Med.* **2018**, *183*, 142–146. [[CrossRef](#)]
124. Symeonidis, A.S. The role of iron and iron chelators in zygomycosis. *Clin. Microbiol. Infect.* **2009**, *15*, 26–32. [[CrossRef](#)]
125. Schmidt, S.; Tramsen, L.; Perkhofer, S.; Lass-Flörl, C.; Röger, F.; Schubert, R.; Lehrnbecher, T. Characterization of the Cellular Immune Responses to *Rhizopus oryzae* With Potential Impact on Immunotherapeutic Strategies in Hematopoietic Stem Cell Transplantation. *J. Infect. Dis.* **2012**, *206*, 135–139. [[CrossRef](#)]
126. Castillo, P.; Wright, K.E.; Kontoyiannis, D.P.; Walsh, T.; Patel, S.; Chorvinsky, E.; Bose, S.; Hazrat, Y.; Omer, B.; Albert, N.; et al. A New Method for Reactivating and Expanding T Cells Specific for *Rhizopus oryzae*. *Mol. Ther. Methods Clin. Dev.* **2018**, *9*, 305–312. [[CrossRef](#)]
127. Gil-Lamagnere, C.; Simitopoulou, M.; Roilides, E.; Maloukou, A.; Winn, R.M.; Walsh, T.J. Interferon- γ and Granulocyte-Macrophage Colony-Stimulating Factor Augment the Activity of Polymorphonuclear Leukocytes against Medically Important Zygomycetes. *J. Infect. Dis.* **2005**, *191*, 1180–1187. [[CrossRef](#)]
128. Grimaldi, D.; Pradier, O.; Hotchkiss, R.S.; Vincent, J.-L. Nivolumab plus interferon- γ in the treatment of intractable mucormycosis. *Lancet Infect. Dis.* **2017**, *17*, 18. [[CrossRef](#)]
129. Paltauf, A. Mycosis mucorina. *Virchows Arch. Pathol. Anat. Physiol. Klin. Med.* **2005**, *102*, 543–564. [[CrossRef](#)]
130. Al-Tawfiq, J.A.; Alhumaid, S.; Alshukairi, A.N.; Temsah, M.-H.; Barry, M.; Al Mutair, A.; Rabaan, A.A.; Al-Omari, A.; Tirupathi, R.; AlQahtani, M.; et al. COVID-19 and mucormycosis superinfection: The perfect storm. *Infection* **2021**, *49*, 833–853. [[CrossRef](#)]
131. Chakrabarti, A. The recent mucormycosis storm over Indian sky. *Indian J. Med Microbiol.* **2021**, *39*, 269–270. [[CrossRef](#)]
132. Suvvari, T.K.; Arigapudi, N.; Kandi, V.R.; Kutikuppala, L.S. Mucormycosis: A killer in the shadow of COVID-19. *J. De Mycol. Med.* **2021**, *31*, 101161. [[CrossRef](#)]
133. Musuza, J.S.; Watson, L.; Parmasad, V.; Putman-Buehler, N.; Christensen, L.; Safdar, N. Prevalence and outcomes of co-infection and superinfection with SARS-CoV-2 and other pathogens: A systematic review and meta-analysis. *PLoS ONE* **2021**, *16*, e0251170. [[CrossRef](#)]
134. Arakeri, G.; Rao Us, V.; Mendes, R.A.; Oepfen, R.S.; Brennan, P.A. COVID-associated mucormycosis (CAM): Is the Delta variant a cause? *Br. J. Oral Maxillofac. Surg.* **2021**, *59*, 1095–1098. [[CrossRef](#)]
135. Pal, R.; Singh, B.; Bhadada, S.K.; Banerjee, M.; Bhogal, R.S.; Hage, N.; Kumar, A. COVID-19-associated mucormycosis: An updated systematic review of literature. *Mycoses* **2021**, *64*, 1452–1459. [[CrossRef](#)]
136. Sharma, S.; Grover, M.; Bhargava, S.; Samdani, S.; Kataria, T. Post coronavirus disease mucormycosis: A deadly addition to the pandemic spectrum. *J. Laryngol. Otol.* **2021**, *135*, 442–447. [[CrossRef](#)]
137. Afzal, S.; Nasir, M. Aspergillosis and mucormycosis in COVID-19 patients; a systematic review and meta-analysis. *Medrxiv* **2021**. [[CrossRef](#)]
138. Ramaswami, A.; Sahu, A.K.; Kumar, A.; Suresh, S.; Nair, A.; Gupta, D.; Chouhan, R.; Bhat, R.; Mathew, R.; Majeed, J.A.; et al. COVID-19-associated mucormycosis presenting to the Emergency Department—an observational study of 70 patients. *QJM: Int. J. Med.* **2021**, *114*, 464–470. [[CrossRef](#)]
139. Selarka, L.; Sharma, S.; Saini, D.; Sharma, S.; Batra, A.; Waghmare, V.T.; Dileep, P.; Patel, S.; Shah, M.; Parikh, T.; et al. Mucormycosis and COVID-19: An epidemic within a pandemic in India. *Mycoses* **2021**, *64*, 1253–1260. [[CrossRef](#)]

140. Bhanuprasad, K.; Manesh, A.; Devasagayam, E.; Varghese, L.; Cherian, L.M.; Kurien, R.; Karthik, R.; Deodhar, D.; Vanjare, H.; Peter, J.; et al. Risk factors associated with the mucormycosis epidemic during the COVID-19 pandemic. *Int. J. Infect. Dis.* **2021**, *111*, 267–270. [[CrossRef](#)]
141. Aranjani, J.M.; Manuel, A.; Razack, H.I.A.; Mathew, S.T. COVID-19-associated mucormycosis: Evidence-based critical review of an emerging infection burden during the pandemic's second wave in India. *PLOS Neglected Trop. Dis.* **2021**, *15*, e0009921. [[CrossRef](#)] [[PubMed](#)]
142. Honavar, S.G.; Sen, M.; Lahane, S.; Lahane, T.P.; Parekh, R. Mucor in a Viral Land: A Tale of Two Pathogens. *Indian J. Ophthalmol.* **2021**, *69*, 244–252. [[CrossRef](#)] [[PubMed](#)]
143. Freeland, B.; Funnell, M. Corticosteroid-induced hyperglycemia. *Nursing* **2012**, *42*, 68–69. [[CrossRef](#)] [[PubMed](#)]
144. Xu, H.; Zhong, L.; Deng, J.; Peng, J.; Dan, H.; Zeng, X.; Li, T.; Chen, Q. High expression of ACE2 receptor of 2019-nCoV on the epithelial cells of oral mucosa. *Int. J. Oral Sci.* **2020**, *12*, 8. [[CrossRef](#)]
145. Agnihotri, A.K.; Vij, M.; Aruoma, O.I.; Yagnik, V.D.; Bahorun, T.; Villamil, M.E.; Menezes, G.A.; Gupta, V. The double trouble: COVID-19 associated mucormycosis a focused review and future perspectives. *Glob. J. Medical, Pharm. Biomed. Updat.* **2021**, *16*, 4. [[CrossRef](#)]
146. Lim, S.; Bae, J.H.; Kwon, H.-S.; Nauck, M.A. COVID-19 and diabetes mellitus: From pathophysiology to clinical management. *Nat. Rev. Endocrinol.* **2020**, *17*, 11–30. [[CrossRef](#)]
147. Hulter, H.N.; Licht, J.H.; Bonner, E.L.; Glynn, R.D.; Sebastián, A. Effects of glucocorticoid steroids on renal and systemic acid-base metabolism. *Am. J. Physiol. Physiol.* **1980**, *239*, F30–F43. [[CrossRef](#)]
148. Damgaci, S.; Ibrahim-Hashim, A.; Enríquez-Navas, P.M.; Pilon-Thomas, S.; Guvenis, A.; Gillies, R.J. Hypoxia and acidosis: Immune suppressors and therapeutic targets. *Immunology* **2018**, *154*, 354–362. [[CrossRef](#)]
149. Bhogireddy, R.; Krishnamurthy, V.; Jabaris S, S.L.; Pullaiah, C.P.; Manohar, S. Is Mucormycosis an inevitable complication of COVID-19 in India? *Braz. J. Infect. Dis.* **2021**, *25*, 101597. [[CrossRef](#)]
150. Ruhl, L.; Pink, I.; Kühne, J.F.; Beushausen, K.; Keil, J.; Christoph, S.; Sauer, A.; Boblitz, L.; Schmidt, J.; David, S.; et al. Endothelial dysfunction contributes to severe COVID-19 in combination with dysregulated lymphocyte responses and cytokine networks. *Signal Transduct. Target. Ther.* **2021**, *6*, 418. [[CrossRef](#)]
151. Elyaspour, Z.; Zibaeenezhad, M.J.; Razmkhah, M.; Razeghian-Jahromi, I. Is It All About Endothelial Dysfunction and Thrombosis Formation? The Secret of COVID-19. *Clin. Appl. Thromb.* **2021**, *27*, 10760296211042940. [[CrossRef](#)] [[PubMed](#)]
152. Lugito, N.P.H.; Cucunawangsih, C. How Does Mucorales Benefit from the Dysregulated Iron Homeostasis During SARS-CoV-2 Infection? *Mycopathologia* **2021**, *186*, 877–882. [[CrossRef](#)] [[PubMed](#)]
153. Kawasumi, H.; Gono, T.; Kawaguchi, Y.; Kaneko, H.; Katsumata, Y.; Hanaoka, M.; Kataoka, S.; Yamanaka, H. IL-6, IL-8, and IL-10 Are Associated with Hyperferritinemia in Rapidly Progressive Interstitial Lung Disease with Polymyositis/Dermatomyositis. *BioMed Res. Int.* **2014**, *2014*, 815245. [[CrossRef](#)] [[PubMed](#)]
154. Perricone, C.; Bartoloni, E.; Bursi, R.; Cafaro, G.; Guidelli, G.M.; Shoefeld, Y.; Gerli, R. COVID-19 as part of the hyperferritinemic syndromes: The role of iron depletion therapy. *Immunol. Res.* **2020**, *68*, 213–224. [[CrossRef](#)]
155. John, T.; Jacob, C.; Kontoyiannis, D. When Uncontrolled Diabetes Mellitus and Severe COVID-19 Converge: The Perfect Storm for Mucormycosis. *J. Fungi* **2021**, *7*, 298. [[CrossRef](#)]
156. Edeas, M.; Saleh, J.; Peyssonnaud, C. Iron: Innocent bystander or vicious culprit in COVID-19 pathogenesis? *Int. J. Infect. Dis.* **2020**, *97*, 303–305. [[CrossRef](#)]
157. Campione, E.; Cosio, T.; Rosa, L.; Lanna, C.; Di Girolamo, S.; Gaziano, R.; Valenti, P.; Bianchi, L. Lactoferrin as Protective Natural Barrier of Respiratory and Intestinal Mucosa against Coronavirus Infection and Inflammation. *Int. J. Mol. Sci.* **2020**, *21*, 4903. [[CrossRef](#)]
158. Campione, E.; Lanna, C.; Cosio, T.; Rosa, L.; Conte, M.P.; Iacovelli, F.; Romeo, A.; Falconi, M.; Del Vecchio, C.; Franchin, E.; et al. Lactoferrin as Antiviral Treatment in COVID-19 Management: Preliminary Evidence. *Int. J. Environ. Res. Public Heal.* **2021**, *18*, 10985. [[CrossRef](#)]
159. Campione, E.; Lanna, C.; Cosio, T.; Rosa, L.; Conte, M.P.; Iacovelli, F.; Romeo, A.; Falconi, M.; Del Vecchio, C.; Franchin, E.; et al. Lactoferrin Against SARS-CoV-2: In Vitro and In Silico Evidences. *Front. Pharmacol.* **2021**, *12*, 666600. [[CrossRef](#)]
160. Ackermann, M.; Verleden, S.E.; Kuehnel, M.; Haverich, A.; Welte, T.; Laenger, F.; Vanstapel, A.; Werlein, C.; Stark, H.; Tzankov, A.; et al. Pulmonary Vascular Endothelialitis, Thrombosis, and Angiogenesis in COVID-19. *N. Engl. J. Med.* **2020**, *383*, 120–128. [[CrossRef](#)]
161. Glowacka, I.; Bertram, S.; Herzog, P.; Pfefferle, S.; Steffen, I.; Muench, M.O.; Simmons, G.; Hofmann, H.; Kuri, T.; Weber, F.; et al. Differential Downregulation of ACE2 by the Spike Proteins of Severe Acute Respiratory Syndrome Coronavirus and Human Coronavirus NL63. *J. Virol.* **2010**, *84*, 1198–1205. [[CrossRef](#)] [[PubMed](#)]
162. Ong, J.J.; Chan, A.C.; Sharma, A.K.; Sharma, S.; Sharma, V.K. The mucormycosis epidemic within COVID-19 pandemic- lessons from India. *Brain, Behav. Immun.* **2021**, *97*, 4–5. [[CrossRef](#)]
163. Honavar, S.; Sen, M.; Sengupta, S.; Rao, R.; Kim, U.; Sharma, M.; Sachdev, M.; Grover, A.; Surve, A.; Budharapu, A.; et al. EpImpact of the use of digital devices on e of COVID-19-associated rhino-orbital-cerebral mucormycosis in 2826 patients in India—Collaborative OPAI-IJO Study on Mucormycosis in COVID-19 (COSMIC), Report 1. *Indian J. Ophthalmol.* **2021**, *69*, 1670–1692. [[CrossRef](#)] [[PubMed](#)]

164. Rao, R.; Shetty, A.; Nagesh, C. Orbital infarction syndrome secondary to rhino-orbital mucormycosis in a case of COVID-19: Clinico-radiological features. *Indian J. Ophthalmol.* **2021**, *69*, 1627–1630. [[CrossRef](#)] [[PubMed](#)]
165. Pakdel, F.; Ahmadikia, K.; Salehi, M.; Tabari, A.; Jafari, R.; Mehrparvar, G.; Rezaie, Y.; Rajaeih, S.; Alijani, N.; Barac, A.; et al. Mucormycosis in patients with COVID-19: A cross-sectional descriptive multicentre study from Iran. *Mycoses* **2021**, *64*, 1238–1252. [[CrossRef](#)]
166. Ashour, M.M.; Abdelaziz, T.T.; Ashour, D.M.; Askoura, A.; Saleh, M.I.; Mahmoud, M.S. Imaging spectrum of acute invasive fungal rhino-orbital-cerebral sinusitis in COVID-19 patients: A case series and a review of literature. *J. Neuroradiol.* **2021**, *48*, 319–324. [[CrossRef](#)]
167. Joshi, A.R.; Muthe, M.M.; Patankar, S.H.; Athawale, A.; Achhapalia, Y. CT and MRI Findings of Invasive Mucormycosis in the Setting of COVID-19: Experience From a Single Center in India. *Am. J. Roentgenol.* **2021**, *217*, 1431–1432. [[CrossRef](#)]
168. Garg, D.; Muthu, V.; Sehgal, I.S.; Ramachandran, R.; Kaur, H.; Bhalla, A.; Puri, G.D.; Chakrabarti, A.; Agarwal, R. Coronavirus Disease (COVID-19) Associated Mucormycosis (CAM): Case Report and Systematic Review of Literature. *Mycopathologia* **2021**, *186*, 289–298. [[CrossRef](#)]
169. Rudramurthy, S.M.; Hoenigl, M.; Meis, J.F.; Cornely, O.A.; Muthu, V.; Gangneux, J.P.; Perfect, J.; Chakrabarti, A.; Isham, E.A. ECMM/ISHAM recommendations for clinical management of COVID-19 associated mucormycosis in low- and middle-income countries. *Mycoses* **2021**, *64*, 1028–1037. [[CrossRef](#)]
170. Reid, G.; Lynch, J.P.; Fishbein, M.C.; Clark, N.M. Mucormycosis. *Semin. Respir. Crit. Care Med.* **2020**, *41*, 099–114. [[CrossRef](#)]
171. Machouart, M.; Larché, J.; Burton, K.; Collomb, J.; Maurer, P.; Cintrat, A.; Biava, M.F.; Greciano, S.; Kuijpers, A.F.A.; Contet-Audonneau, N.; et al. Genetic Identification of the Main Opportunistic Mucorales by PCR-Restriction Fragment Length Polymorphism. *J. Clin. Microbiol.* **2006**, *44*, 805–810. [[CrossRef](#)] [[PubMed](#)]
172. Lass-Flörl, C.; Mayr, A. Diagnosing invasive fungal diseases—limitations of microbiological diagnostic methods. *Expert Opin. Med. Diagn.* **2009**, *3*, 461–470. [[CrossRef](#)] [[PubMed](#)]
173. Samson, R.; Dharne, M. COVID-19 associated mucormycosis: Evolving technologies for early and rapid diagnosis. *3 Biotech* **2022**, *12*, 6. [[CrossRef](#)] [[PubMed](#)]
174. Lass-Flörl, C. Zygomycosis: Conventional laboratory diagnosis. *Clin. Microbiol. Infect.* **2009**, *15*, 60–65. [[CrossRef](#)] [[PubMed](#)]
175. Kung, V.L.; Chernock, R.; Burnham, C.-A.D. Diagnostic accuracy of fungal identification in histopathology and cytopathology specimens. *Eur. J. Clin. Microbiol.* **2017**, *37*, 157–165. [[CrossRef](#)] [[PubMed](#)]
176. Hamilos, G.; Samonis, G.; Kontoyiannis, D.P. Pulmonary Mucormycosis. *Semin. Respir. Crit. Care Med.* **2011**, *32*, 693–702. [[CrossRef](#)] [[PubMed](#)]
177. Hoenigl, M.; Seidel, D.; Carvalho, A.; Rudramurthy, S.M.; Arastehfar, A.; Gangneux, J.-P.; Nasir, N.; Bonifaz, A.; Araiza, J.; Klimko, N.; et al. The emergence of COVID-19 associated mucormycosis: A review of cases from 18 countries. *Lancet Microbe* **2022**. [[CrossRef](#)]
178. Koehler, P.; Bassetti, M.; Chakrabarti, A.; Chen, S.C.A.; Colombo, A.L.; Hoenigl, M.; Klimko, N.; Lass-Flörl, C.; Oladele, R.O.; Vinh, D.C.; et al. Defining and managing COVID-19-associated pulmonary aspergillosis: The 2020 ECMM/ISHAM consensus criteria for research and clinical guidance. *Lancet Infect. Dis.* **2021**, *21*, e149–e162. [[CrossRef](#)]
179. Hsiao, C.R.; Huang, L.; Bouchara, J.-P.; Barton, R.; Li, H.C.; Chang, T.C. Identification of Medically Important Molds by an Oligonucleotide Array. *J. Clin. Microbiol.* **2005**, *43*, 3760–3768. [[CrossRef](#)]
180. Gholinejad-Ghadi, N.; Shokohi, T.; Seifi, Z.; Aghili, S.R.; Roilides, E.; Nikkiah, M.; Pormosa, R.; Karami, H.; Larjani, L.V.; Ghasemi, M.; et al. Identification of *Mucorales* in patients with proven invasive mucormycosis by polymerase chain reaction in tissue samples. *Mycoses* **2018**, *61*, 909–915. [[CrossRef](#)]
181. Larché, J.; Machouart, M.; Burton, K.; Collomb, J.; Biava, M.F.; Gérard, A.; Fortier, B. Diagnosis of Cutaneous Mucormycosis Due to *Rhizopus microsporus* by an Innovative PCR-Restriction Fragment-Length Polymorphism Method. *Clin. Infect. Dis.* **2005**, *41*, 1362–1365. [[CrossRef](#)] [[PubMed](#)]
182. Rickerts, V.; Just-Nübling, G.; Konrad, F.; Kern, J.; Lambrecht, E.; Böhme, A.; Jacobi, V.; Bialek, R. Diagnosis of invasive aspergillosis and mucormycosis in immunocompromised patients by seminested PCR assay of tissue samples. *Eur. J. Clin. Microbiol.* **2006**, *25*, 8–13. [[CrossRef](#)] [[PubMed](#)]
183. Hata, D.J.; Buckwalter, S.P.; Pritt, B.S.; Roberts, G.D.; Wengenack, N.L. Real-Time PCR Method for Detection of Zygomycetes. *J. Clin. Microbiol.* **2008**, *46*, 2353–2358. [[CrossRef](#)] [[PubMed](#)]
184. Millon, L.; Larosa, F.; Lepiller, Q.; Legrand, F.; Rocchi, S.; Daguindau, E.; Scherer, E.; Bellanger, A.-P.; Leroy, J.; Grenouillet, F. Quantitative Polymerase Chain Reaction Detection of Circulating DNA in Serum for Early Diagnosis of Mucormycosis in Immunocompromised Patients. *Clin. Infect. Dis.* **2013**, *56*, e95–e101. [[CrossRef](#)]
185. Millon, L.; Herbrecht, R.; Grenouillet, F.; Morio, F.; Alanio, A.; Letscher-Bru, V.; Cassaing, S.; Chouaki, T.; Kauffmann-Lacroix, C.; Poirier, P.; et al. Early diagnosis and monitoring of mucormycosis by detection of circulating DNA in serum: Retrospective analysis of 44 cases collected through the French Surveillance Network of Invasive Fungal Infections (RESSIF). *Clin. Microbiol. Infect.* **2016**, *22*, 810.e1–810.e8. [[CrossRef](#)]
186. Nyilasi, I.; Papp, T.; Csernetics, A.; Krizsán, K.; Nagy, E.; Vágvölgyi, C. High-affinity iron permease (FTR1) gene sequence-based molecular identification of clinically important Zygomycetes. *Clin. Microbiol. Infect.* **2008**, *14*, 393–397. [[CrossRef](#)]
187. Jensen, H.E.; Salonen, J.; Ekfors, T.O. The use of immunohistochemistry to improve sensitivity and specificity in the diagnosis of systemic mycoses in patients with haematological malignancies. *J. Pathol.* **1997**, *181*, 100–105. [[CrossRef](#)]

188. Sunagawa, K.; Ishige, T.; Kusumi, Y.; Asano, M.; Nisihikawa, E.; Kato, M.; Yagasaki, H.; Nemoto, N. Renal abscess involving mucormycosis by immunohistochemical detection in a patient with acute lymphocytic leukemia: A case report and literature review. *Jpn. J. Infect. Dis.* **2013**, *66*, 345–347. [[CrossRef](#)]
189. Jung, J.; Park, Y.S.; Sung, H.; Song, J.S.; Lee, S.-O.; Choi, S.-H.; Kim, Y.S.; Woo, J.H.; Kim, S.-H. Using immunohistochemistry to assess the accuracy of histomorphologic diagnosis of aspergillosis and mucormycosis. *Clin. Infect. Dis.* **2015**, *61*, 1664–1670. [[CrossRef](#)]
190. Hammond, S.P.; Bialek, R.; Milner, D.A.; Petschnigg, E.M.; Baden, L.R.; Marty, F.M. Molecular Methods To Improve Diagnosis and Identification of Mucormycosis. *J. Clin. Microbiol.* **2011**, *49*, 2151–2153. [[CrossRef](#)]
191. Salehi, E.; Hedayati, M.T.; Zoll, J.; Rafati, H.; Ghasemi, M.; Doroudinia, A.; Abastabar, M.; Toloee, A.; Snelders, E.; van der Lee, H.A.; et al. Discrimination of Aspergillosis, Mucormycosis, Fusariosis, and Scedosporiosis in Formalin-Fixed Paraffin-Embedded Tissue Specimens by Use of Multiple Real-Time Quantitative PCR Assays. *J. Clin. Microbiol.* **2016**, *54*, 2798–2803. [[CrossRef](#)] [[PubMed](#)]
192. Ling, H.; Yuan, Z.; Shen, J.; Wang, Z.; Xu, Y. Accuracy of Matrix-Assisted Laser Desorption Ionization–Time of Flight Mass Spectrometry for Identification of Clinical Pathogenic Fungi: A Meta-Analysis. *J. Clin. Microbiol.* **2014**, *52*, 2573–2582. [[CrossRef](#)] [[PubMed](#)]
193. Spanu, T.; Posteraro, B.; Fiori, B.; D’Inzeo, T.; Campoli, S.; Ruggeri, A.; Tumbarello, M.; Canu, G.; Trecarichi, E.M.; Parisi, G.; et al. Direct MALDI-TOF Mass Spectrometry Assay of Blood Culture Broths for Rapid Identification of Candida Species Causing Bloodstream Infections: An Observational Study in Two Large Microbiology Laboratories. *J. Clin. Microbiol.* **2012**, *50*, 176–179. [[CrossRef](#)]
194. Schrödl, W.; Heydel, T.; Schwartz, V.U.; Hoffmann, K.; Große-Herrenthey, A.; Walther, G.; Alastruey-Izquierdo, A.; Rodriguez-Tudela, J.L.; Olias, P.; Jacobsen, I.D.; et al. Direct Analysis and Identification of Pathogenic Lichtheimia Species by Matrix-Assisted Laser Desorption Ionization–Time of Flight Analyzer-Mediated Mass Spectrometry. *J. Clin. Microbiol.* **2012**, *50*, 419–427. [[CrossRef](#)] [[PubMed](#)]
195. Lau, A.F.; Walchak, R.C.; Miller, H.B.; Slechta, E.S.; Kamboj, K.; Riebe, K.; Robertson, A.E.; Gilbreath, J.J.; Mitchell, K.F.; Wallace, M.A.; et al. Multicenter Study Demonstrates Standardization Requirements for Mold Identification by MALDI-TOF MS. *Front. Microbiol.* **2019**, *10*, 2098. [[CrossRef](#)] [[PubMed](#)]
196. Koshy, S.; Ismail, N.; Astudillo, C.L.; Haeger, C.M.; Aloum, O.; Acharige, M.T.; Farmakiotis, D.; Baden, L.R.; Marty, F.; Kontoyiannis, D.P.; et al. Breath-Based Diagnosis of Invasive Mucormycosis (IM). *Open Forum Infect. Dis.* **2017**, *4*, S53–S54. [[CrossRef](#)]
197. Richardson, M.; Page, I. Role of Serological Tests in the Diagnosis of Mold Infections. *Curr. Fungal Infect. Rep.* **2018**, *12*, 127–136. [[CrossRef](#)] [[PubMed](#)]
198. Angebault, C.; Lanternier, F.; Dalle, F.; Schimpf, C.; Roupie, A.-L.; Dupuis, A.; Agathine, A.; Scemla, A.; Paubelle, E.; Caillot, D.; et al. Prospective Evaluation of Serum β -Glucan Testing in Patients With Probable or Proven Fungal Diseases. *Open Forum Infect. Dis.* **2016**, *3*, ofw128. [[CrossRef](#)]
199. Girdhar, D.; Manocha, E. A Comprehensive Review on the Management of COVID-19-Associated Mucormycosis (CAM): The New Basics. *BioMed* **2022**, *2*, 181–198. [[CrossRef](#)]
200. Schwarz, P.; Lortholary, O.; Dromer, F.; Dannaoui, E. Carbon Assimilation Profiles as a Tool for Identification of Zygomycetes. *J. Clin. Microbiol.* **2007**, *45*, 1433–1439. [[CrossRef](#)]
201. Berkow, E.L.; Lockhart, S.R.; Ostrosky-Zeichner, L. Antifungal Susceptibility Testing: Current Approaches. *Clin. Microbiol. Rev.* **2020**, *33*, e00069-19. [[CrossRef](#)] [[PubMed](#)]
202. Honavar, S. Code Mucor: Guidelines for the Diagnosis, Staging and Management of Rhino-Orbito-Cerebral Mucormycosis in the Setting of COVID-19. *Indian J. Ophthalmol.* **2021**, *69*, 1361–1365. [[CrossRef](#)]
203. Sahu, R.K.; Salem-Bekhit, M.M.; Bhattacharjee, B.; Almoshari, Y.; Iqbal, A.M.A.; Alshamrani, M.; Bharali, A.; Salawi, A.; Widyowati, R.; Alshammari, A.; et al. Mucormycosis in Indian COVID-19 Patients: Insight into Its Patho-Genesis, Clinical Manifestation, and Management Strategies. *Antibiotics* **2021**, *10*, 1079. [[CrossRef](#)] [[PubMed](#)]
204. León-Buitimea, A.; Garza-Cervantes, J.A.; Gallegos-Alvarado, D.Y.; Osorio-Concepción, M.; Morones-Ramírez, J.R. Nanomaterial-Based Antifungal Therapies to Combat Fungal Diseases Aspergillosis, Coccidioidomycosis, Mucormycosis, and Candidiasis. *Pathogens* **2021**, *10*, 1303. [[CrossRef](#)] [[PubMed](#)]
205. Vuorio, A.; Kovanen, P.T. Mucormycosis and glucose-regulated protein 78 in COVID-19: Amenable to statin treatment? *J. Intern. Med.* **2021**, *290*, 931–933. [[CrossRef](#)]
206. Chatterjee, S.; Vardhan, B.; Singh, D.K.; Maitra, A.; Ojha, U.K. Should statins be considered for the management of mucormycosis in COVID-19? *Diabetes Metab. Syndr. Clin. Res. Rev.* **2021**, *15*, 102162. [[CrossRef](#)]
207. Gebremariam, T.; Alkhazraji, S.; Soliman, S.S.M.; Gu, Y.; Jeon, H.H.; Zhang, L.; French, S.W.; Stevens, D.A.; Edwards, J.E.; Filler, S.G.; et al. Anti-CotH3 antibodies protect mice from mucormycosis by prevention of invasion and augmenting opsonophagocytosis. *Sci. Adv.* **2019**, *5*, eaaw1327. [[CrossRef](#)]
208. Alqarihi, A.; Gebremariam, T.; Gu, Y.; Swidergall, M.; Alkhazraji, S.; Soliman, S.S.M.; Bruno, V.M.; Edwards, J.E.; Filler, S.G.; Uppuluri, P.; et al. GRP78 and Integrins Play Different Roles in Host Cell Invasion during Mucormycosis. *mBio* **2020**, *11*, e01087-20. [[CrossRef](#)]

209. John, B.; Chamilos, G.; Kontoyiannis, D. Hyperbaric oxygen as an adjunctive treatment for zygomycosis. *Clin. Microbiol. Infect.* **2005**, *11*, 515–517. [[CrossRef](#)]
210. Alshahawey, M.G.; El-Housseiny, G.S.; Elsayed, N.S.; Alshahrani, M.Y.; EL Wakeel, L.M.; Aboshanab, K.M. New insights on mucormycosis and its association with the COVID-19 pandemic. *Futur. Sci. OA* **2022**, *8*, FSO772. [[CrossRef](#)]
211. Dalié, D.; Deschamps, A.; Richard-Forget, F. Lactic acid bacteria—Potential for control of mould growth and mycotoxins: A review. *Food Control* **2010**, *21*, 370–380. [[CrossRef](#)]
212. Aiko, V.; Edamana, P.; Mehta, A. Decomposition and detoxification of aflatoxin B₁ by lactic acid. *J. Sci. Food Agric.* **2015**, *96*, 1959–1966. [[CrossRef](#)] [[PubMed](#)]
213. Russo, P.; Arena, M.P.; Fiocco, D.; Capozzi, V.; Drider, D.; Spano, G. Lactobacillus plantarum with broad antifungal activity: A promising approach to increase safety and shelf-life of cereal-based products. *Int. J. Food Microbiol.* **2017**, *247*, 48–54. [[CrossRef](#)]
214. Arasu, M.V.; Al-Dhabi, N.A. In vitro antifungal, probiotic, and antioxidant functional properties of a novel Lactobacillus paraplantarum isolated from fermented dates in Saudi Arabia. *J. Sci. Food Agric.* **2017**, *97*, 5287–5295. [[CrossRef](#)] [[PubMed](#)]
215. Azizkhani, M.; Saris, P.E.J.; Baniasadi, M. An in-vitro assessment of antifungal and antibacterial activity of cow, camel, ewe, and goat milk kefir and probiotic yogurt. *J. Food Meas. Charact.* **2020**, *15*, 406–415. [[CrossRef](#)]
216. Brzozowski, T.; Zwolinska-Wcislo, M.; Konturek, P.C.; Kwiecien, S.; Drozdowicz, D.; Konturek, S.J.; Stachura, J.; Budak, A.; Bogdal, J.; Pawlik, W.W.; et al. Influence of gastric colonization with Candida albicans ulcer healing in rats: Effect of ranitidine, aspirin and probiotic therapy. *Scand. J. Gastroenterol.* **2005**, *40*, 286–296. [[CrossRef](#)] [[PubMed](#)]
217. Vicariotto, F.; Del Piano, M.; Mogna, L.; Mogna, G. Effectiveness of the Association of 2 Probiotic Strains Formulated in a Slow Release Vaginal Product, in Women Affected by Vulvovaginal Candidiasis. *J. Clin. Gastroenterol.* **2012**, *46*, S73–S80. [[CrossRef](#)]
218. Demirel, G.; Celik, I.H.; Erdeve, O.; Saygan, S.; Dilmen, U.; Canpolat, F.E. Prophylactic Saccharomyces boulardii versus nystatin for the prevention of fungal colonization and invasive fungal infection in premature infants. *Eur. J. Pediatr.* **2013**, *172*, 1321–1326. [[CrossRef](#)]
219. Matsubara, V.H.; Bandara, H.; Mayer, M.; Samaranyake, L.P. Probiotics as Antifungals in Mucosal Candidiasis. *Clin. Infect. Dis.* **2016**, *62*, 1143–1153. [[CrossRef](#)]
220. He, L.-H.; Ren, L.-F.; Li, J.-F.; Wu, Y.-N.; Li, X.; Zhang, L. Intestinal Flora as a Potential Strategy to Fight SARS-CoV-2 Infection. *Front. Microbiol.* **2020**, *11*, 1388. [[CrossRef](#)]
221. Morais, A.H.A.; Passos, T.S.; Maciel, B.L.L.; Da Silva-Maia, J.K. Can Probiotics and Diet Promote Beneficial Immune Modulation and Purine Control in Coronavirus Infection? *Nutrients* **2020**, *12*, 1737. [[CrossRef](#)] [[PubMed](#)]
222. Olaimat, A.N.; Aolymat, I.; Al-Holy, M.; Ayyash, M.; Abu Ghoush, M.; Al-Nabulsi, A.A.; Osaili, T.; Apostolopoulos, V.; Liu, S.-Q.; Shah, N.P. The potential application of probiotics and prebiotics for the prevention and treatment of COVID-19. *NPJ Sci. Food* **2020**, *4*, 1–7. [[CrossRef](#)] [[PubMed](#)]
223. Gohil, K.; Samson, R.; Dastager, S.; Dharne, M. Probiotics in the prophylaxis of COVID-19: Something is better than nothing. *3 Biotech* **2020**, *11*, 1–10. [[CrossRef](#)] [[PubMed](#)]
224. Chhibber-Goel, J.; Gopinathan, S.; Sharma, A. Interplay between severities of COVID-19 and the gut microbiome: Implications of bacterial co-infections? *Gut Pathog.* **2021**, *13*, 1–6. [[CrossRef](#)]
225. Oliveira, L.D.M.; Teixeira, F.M.E.; Sato, M.N. Impact of Retinoic Acid on Immune Cells and Inflammatory Diseases. *Mediat. Inflamm.* **2018**, *2018*, 1–17. [[CrossRef](#)]
226. Goodarzi, A.; Sadeghzadeh-Bazargan, A.; Behranghi, E. Systemic retinoids in COVID-19 era, are they helpful, safe or harmful? A comprehensive review study. *Iran. J. Dermatol.* **2020**, *23*, 9–12. [[CrossRef](#)]
227. Cosio, T.; Gaziano, R.; Zuccari, G.; Costanza, G.; Grelli, S.; Di Francesco, P.; Bianchi, L.; Campione, E. Retinoids in Fungal Infections: From Bench to Bedside. *Pharmaceuticals* **2021**, *14*, 962. [[CrossRef](#)]
228. Ross, A.C.; Stephensen, C.B. Vitamin A and retinoids in antiviral responses. *FASEB J. Off. Publ. Fed. Am. Soc. Exp. Biol.* **1996**, *10*, 979–985. [[CrossRef](#)]
229. Cengiz, A.B.; Ozyilmaz, C.; Tabaru, A.; Kayabasi, S.; Ege, S.S.; Ruzgar, S.; Emre, F.; Oktay, M.F. Effects of oral isotretinoin on normal and wounded nasal mucosa: An experimental study. *Eur. Arch. Oto-Rhino-Laryngol.* **2018**, *275*, 3025–3031. [[CrossRef](#)]
230. Msc, A.A.; Vestita, M.; Msc, H.S.E.; Ayhan, E.; An, I.; Öztürk, M.; Goldust, M. Systemic isotretinoin therapy in the era of COVID-19. *Dermatol. Ther.* **2020**, *33*, e13482. [[CrossRef](#)]
231. Oikawa, T.; Hirotani, K.; Nakamura, O.; Shudo, K.; Hiragun, A.; Iwaguchi, T. A highly potent antiangiogenic activity of retinoids. *Cancer Lett.* **1989**, *48*, 157–162. [[CrossRef](#)]
232. Wu, C.; Liu, Y.; Yang, Y.; Zhang, P.; Zhong, W.; Wang, Y.; Wang, Q.; Xu, Y.; Li, M.; Li, X.; et al. Analysis of therapeutic targets for SARS-CoV-2 and discovery of potential drugs by computational methods. *Acta Pharm. Sin. B* **2020**, *10*, 766–788. [[CrossRef](#)] [[PubMed](#)]
233. Midha, I.K.; Kumar, N.; Kumar, A.; Madan, T. Mega doses of retinol: A possible immunomodulation in COVID-19 illness in resource-limited settings. *Rev. Med Virol.* **2020**, *31*, 1–14. [[CrossRef](#)] [[PubMed](#)]
234. Campione, E.; Paterno, E.J.; Diluvio, L.; Costanza, G.; Bianchi, L.; Carboni, I.; Chimenti, S.; Orlandi, A.; Marino, D.; Favalli, C. Tazarotene as alternative topical treatment for onychomycosis. *Drug Des. Dev. Ther.* **2015**, *9*, 879–886. [[CrossRef](#)]
235. Campione, E.; Gaziano, R.; Doldo, E.; Marino, D.; Falconi, M.; Iacovelli, F.; Tagliaferri, D.; Pacello, L.; Bianchi, L.; Lanna, C.; et al. Antifungal Effect of All- trans Retinoic Acid against Aspergillus fumigatus In Vitro and in a Pulmonary Aspergillosis In Vivo Model. *Antimicrob. Agents Chemother.* **2021**, *65*, e01874-20. [[CrossRef](#)]

236. Brunet, K.; Rammaert, B. Mucormycosis treatment: Recommendations, latest advances, and perspectives. *J. Mycol. Med.* **2020**, *30*, 101007. [[CrossRef](#)]
237. Gebremariam, T.; Wiederhold, N.; Fothergill, A.W.; Garvey, E.P.; Hoekstra, W.J.; Schotzinger, R.J.; Patterson, T.F.; Filler, S.G.; Ibrahim, A.S. VT-1161 Protects Immunosuppressed Mice from *Rhizopus arrhizus* var. *arrhizus* Infection. *Antimicrob. Agents Chemother.* **2015**, *59*, 7815–7817. [[CrossRef](#)]
238. Macedo, D.; Leonardelli, F.; Dudiuk, C.; Theill, L.; Cabeza, M.S.; Gamarra, S.; Garcia-Effron, G. Molecular Confirmation of the Linkage between the *Rhizopus oryzae* CYP51A Gene Coding Region and Its Intrinsic Voriconazole and Fluconazole Resistance. *Antimicrob. Agents Chemother.* **2018**, *62*, e00224-18. [[CrossRef](#)]
239. Gebremariam, T.; Alkhazraji, S.; Alqarihi, A.; Wiederhold, N.P.; Shaw, K.J.; Patterson, T.F.; Filler, S.G.; Ibrahim, A.S. Fosmanogepix (APX001) Is Effective in the Treatment of Pulmonary Murine Mucormycosis Due to *Rhizopus arrhizus*. *Antimicrob. Agents Chemother.* **2020**, *64*, e00178-20. [[CrossRef](#)]
240. Ben Yaakov, D.; Rivkin, A.; Mircus, G.; Albert, N.; Dietl, A.-M.; Kovalerchick, D.; Carmeli, S.; Haas, H.; Kontoyiannis, D.P.; Oshero, N. Identification and characterization of haemofungin, a novel antifungal compound that inhibits the final step of haem biosynthesis. *J. Antimicrob. Chemother.* **2016**, *71*, 946–952. [[CrossRef](#)]
241. Chao, C.-M.; Lai, C.-C.; Yu, W.-L. COVID-19 associated mucormycosis—An emerging threat. *J. Microbiol. Immunol. Infect.* **2022**, *55*, 183–190. [[CrossRef](#)] [[PubMed](#)]