



Late Retrograde Aortic Dissection after Hybrid Thoracic Endovascular Aortic Repair (TEVAR): A Case Report

Safieh Boroumand, PhD^{1,2}, Seyed Hossein Ahmadi-Tafti, MD¹, Saeed Davoodi, MD¹, Seyed Khalil Forouzannia, MD^{1*}

¹Research Center for Advanced Technologies in Cardiovascular Medicine, Tehran Heart Center, Tehran University of Medical Sciences, Tehran, Iran.

²Department of Tissue Engineering and Applied Cell Sciences, School of Advanced Technologies in Medicine, Shahid Beheshti University of Medical Sciences, Tehran, Iran.

Received 28 August 2020; Accepted 18 October 2020

Abstract

Open total arch replacement is allied to high rates of mortality and morbidity; surgeons, therefore, tend to choose hybrid aortic arch repair as a less invasive operative procedure for the treatment of aortic arch aneurysms, especially in high-risk patients. However, studies on the early and late outcomes of patients undergoing hybrid aortic arch repair have revealed high rates of reintervention and reoperation compared with open total arch replacement. Here, we describe a male patient with late retrograde aortic dissection after hybrid thoracic endovascular aortic repair for aortic arch aneurysms. The patient returned 3 years after the procedure with signs of dyspnea on exertion and chest pain. Transthoracic echocardiography and computed tomography showed dissection of the ascending aorta, for which he underwent a redo Bentall procedure. The patient was weaned from cardiopulmonary bypass without any problem and discharged after 7 days.

J Teh Univ Heart Ctr 2021;16(1):38-41

This paper should be cited as: Boroumand S, Ahmadi-Tafti SH, Davoodi S, Forouzannia SK. Late Retrograde Aortic Dissection after Hybrid Thoracic Endovascular Aortic Repair (TEVAR): A Case Report. *J Teh Univ Heart Ctr 2021;16(1):38-41.*

Keywords: Aorta, thoracic; Aneurysm; Dissection

Introduction

The management strategy for aortic arch aneurysms persists as a clinical challenge. The complexity and high mortality and morbidity rates of open total arch replacement (OAR) have prompted surgeons to draw upon thoracic endovascular aortic repair (TEVAR) or hybrid aortic arch repair (HAR) procedures. HAR, defined as the debranching of the arch vessels and endovascular stent-grafting, assumes greater significance in patients who cannot tolerate OAR. Although long-term studies have indicated a drop in the rates

of mortality and morbidity following TEVAR, the application of this modality for the treatment of aortic arch aneurysms (more frequently in zone 0 and zone 1) is associated with such adverse effects as retrograde type A aortic dissection.^{1,2}

We herein report a case of late retrograde type A aortic dissection 3 years after hybrid TEVAR.

Case Report

The applied method in this study for a case report was

*Corresponding Author: Seyed Khalil Forouzannia, Professor of Cardiovascular Surgery, Tehran Heart Center, North Karegar Street, Tehran, Iran. 1411713138. Tel: +98 21 88029731. Fax: +98 21 88029731. E-mail: drforouzan_nia@yahoo.com.





approved by the Research Ethics Committee of Tehran University of Medical Sciences, and written informed consent was obtained from the patient before any intervention.

A 43-year-old man was referred to Tehran Heart Center with dyspnea, hoarseness, and pulsatile mass at the base of the neck. The patient had a history of hypertension, hyperlipidemia, smoking, and opium addiction, as well as a family history of heart disease. Physical examination revealed a pulsatile mass at the base of the neck. Chest X-ray showed a widening in the upper mediastinum, and electrocardiography indicated left ventricular hypertrophy due to hypertension. Transthoracic echocardiography illustrated diastolic dysfunction, a mildly dilated left atrium, mild mitral and tricuspid regurgitation, a normal aortic valve, a hypertrophic interventricular septum, and a dilated aortic arch (53 mm) (Figure 1). Computed tomography (CT) angiography showed a 65 mm aneurysm in the aortic arch and a normal ascending and descending aorta.

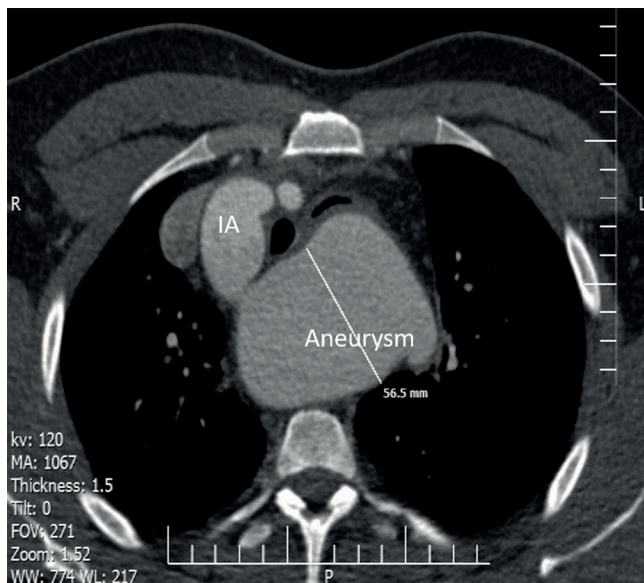


Figure 1. Preoperative computed tomography demonstrates a 6.5 cm arch aneurysm, extending from the origin of the innominate artery to the origin of the left subclavian artery.

IA, Innominate artery

The patient was candidate for the debranching of the aortic arch branches, followed by TEVAR. In the debranching procedure, through a median sternotomy, the brachiocephalic trunk and the left common carotid arteries were moved to the ascending aorta with a 16×8 mm 2-branched Dacron graft under normothermic cardiopulmonary bypass due to the displacement of the arch branches by the aneurysm.

The left subclavian artery was left alone for trans-arterial occlusion in the next stage because it originated from the top of the aneurysm and it was dangerous for debranching.

Vascular access for hybrid TEVAR was the right femoral artery. The left subclavian artery was occluded with the

device to prevent possible type II endoleaks, and it was filled from the left vertebral artery after the occlusion of the left subclavian artery/stent-graft implantation. A radiopaque marker was implanted around the aorta, 2 to 3 cm proximal to the aneurysm, as a guide for the retrograde implantation of the stent-graft (Cook Medical) into the aortic arch and the proximal descending aorta (Figure 2).

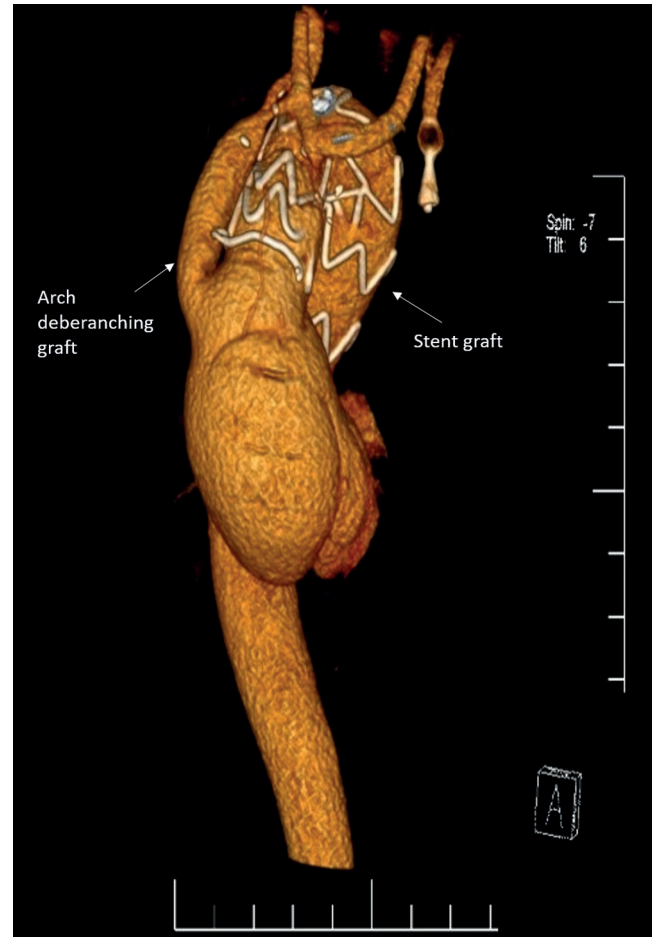


Figure 2. Postoperative computed tomography volume-rendering reconstruction demonstrates the position of the stent-graft and the patency of the debranching graft.

Three years after the hybrid TEVAR procedure, the patient returned with dyspnea on exertion and chest pain. Transthoracic echocardiography showed severe aortic valve insufficiency and aneurysmal dilatation in the ascending aorta (69 mm), resembling a dissection flap, with linear echogenicity in the ascending aorta. Computed tomography angiography showed dissection of the ascending aorta originating from the proximal edge of the previously inserted stent-graft and extending toward the left coronary sinus (Figure 3).

The patient was candidate for a redo Bentall operation via the femoral artery and radial artery cannulation. The aorta was cross-clamped at the level of the common trunk of the

debranching graft. Afterward, aortotomy was performed, followed by direct cardioplegia infusion into the ostium of the coronary arteries. The common trunk of the debranching graft was cannulated, and selective cerebral perfusion was maintained during the entire hypothermic circulatory arrest. Next, the ascending aorta was transected, and the Bentall procedure was performed (Figure 4) with a 25 mm composite graft. Afterward, the composite graft was distally anastomosed to the proximal end of the previous TEVAR stent-graft. Thereafter, the debranching graft was reinserted end-to-side into the ascending aortic graft. The patient was weaned from cardiopulmonary bypass without any problem and discharged on the seventh postoperative day.

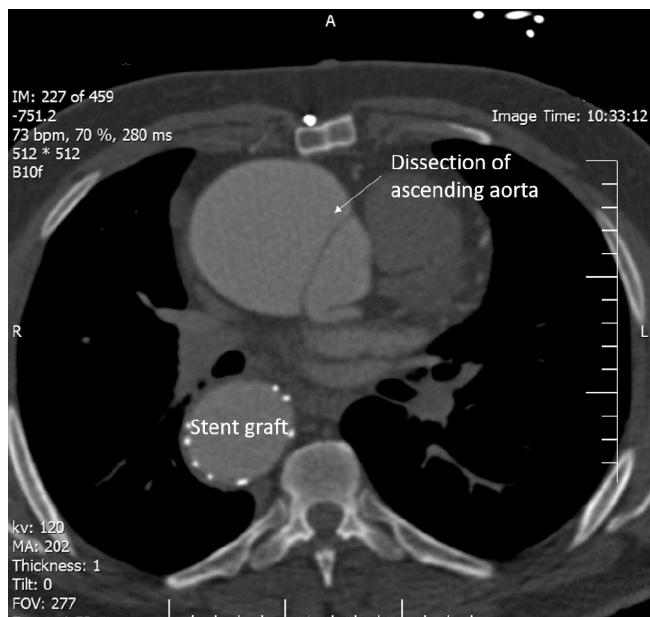


Figure 3. Computed tomography demonstrates the dissection, involving the ascending aorta and extending toward the left coronary sinus.

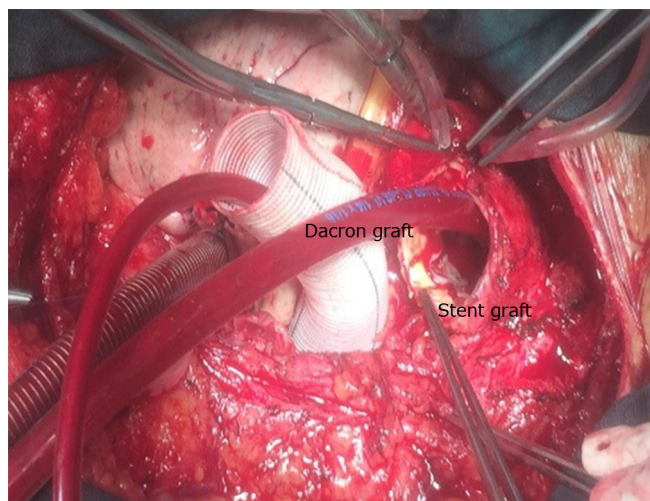


Figure 4. The image presents an intraoperative view, with the blue arrow pointing to the Dacron graft of the ascending aorta and the green

arrow pointing to the cannula for the selective cerebral perfusion of the debranching graft.

Discussion

An aortic aneurysm is defined as aortic dilatation at least 1.5 times the normal aortic diameter that can affect 1 or more sites of the thoracic aorta (aortic root, ascending aorta, aortic arch, and descending aorta). Aortic aneurysms are classified by Mitchell and Ishimaru based on the zone; however, isolated aortic arch aneurysms are rare and are usually associated with aneurysms in the ascending or descending aorta.³

Thoracic aortic arch aneurysms (TAAs) constitute a life-threatening condition given the risk of rupture. The misdiagnosis of TAAs can lead to the rupture of the aorta and result in malperfusion in extremities (25%–60%) as well as renal (23%–75%), mesenteric (10%–20%), coronary (5%–11%), cerebral (3%–13%), and spinal (2%–9%) arteries. The pathophysiology of aneurysms in the ascending aorta and the aortic arch could be due to some kinds of familial syndromes with changes in connective tissue. Additionally, some other conditions such as infection and inflammation are responsible for insufficiency in connective tissue, which may lead to aneurysm formation in the ascending aorta and the aortic arch.⁴

Most aortic aneurysms are clinically silent and could be incidentally revealed during chest X-ray or echocardiography. Nonetheless, when they are symptomatic, the most important signs are chest or back pain, hoarseness, cough, and shortness of breath. TAAs can cause unilateral vocal cord palsy, and hoarseness can be a predictor of an impending rupture.^{5, 6} Often, an unremarkable physical examination is expected for a TAA. Chest X-ray can reveal a TAA as a convex contour of the right superior mediastinum caused by an enlarged ascending aorta and a diminished retrosternal air space. Transesophageal echocardiography is an invasive imaging modality that can differentiate a TAA from dissection or intramural hematoma.⁴

The diagnosis of TAAs becomes beneficial if established before rupture. Although the growth rate and influencing factors of TAAs are still unclear, it is vital that they be diagnosed before surgery is mandated and that they be followed up meticulously via periodic CT and magnetic resonance imaging.⁷ Further, patients need education concerning not only the warning signs of TAA rupture but also the importance of life-style alteration, smoking cessation, and hypertension and hyperlipidemia control.⁸ Bickerstaff et al⁹ reported a survival rate of 13% at 5 years' follow-up of patients with untreated TAAs in comparison with a 75% rate in the control group, who had no aortic aneurysm. These results underscore the significance of appropriate management strategies for TAAs.^{4, 9}

The standard management method for aortic arch diseases



is the open surgical approach with significant improvements in the outcome. Still, this approach is associated with a mortality rate of 15% to 20%, and it is not suitable for high-risk patients.¹⁰⁻¹² The surgical technique of TEVAR was approved by the United States Food and Drug Administration (FDA) in 2005 for aneurysm repair in the descending thoracic aorta, but it was expanded to other applications including aortic dissection, trauma, and hybrid procedures.⁸ Hybrid repair was subsequently introduced as a less invasive procedure compared with OAR. The hybrid repair modality entails the debranching of the brachiocephalic, left common carotid, and left subclavian arteries with a synthetic bypass graft, followed by endovascular grafting through the aortic arch and the descending aorta.³ Despite the low rates of mortality and morbidity associated with the hybrid procedure by comparison with OAR, concerns about retrograde aortic dissection after TEVAR and hybrid procedures have yet to be assuaged.¹²⁻¹⁵ The estimated incidence of retrograde aortic dissection after the hybrid procedure for aortic arch diseases is reported to range between 1.33% and 3.5%, with 70% of the cases occurring during the first month and 29% after 30 days but mostly during the first year.¹² Joo et al¹⁶ evaluated late complications after HAR in 65 patients and reported a relatively high rate of late complications such as delayed type I endoleaks, distal stent-induced new entries, stent migration, retrograde type A dissections, aortopulmonary fistulae, aortoesophageal fistulae, stent fracture, infection, and sudden death. Tokuda et al² compared HAR with OAR in 364 patients and reported that whereas the 2 techniques were similar in terms of short-term results, HAR had a lower risk of circulatory arrest and cardiopulmonary bypass.

Other studies have also evaluated complications after both OAR and HAR. The hybrid procedure is associated with high rates of reoperations and reinterventions; however, operative complications are similar between these 2 approaches. The reported advantages conferred by HAR include reduced rates of cardiopulmonary bypass and circulatory arrest and shortened lengths of intensive care unit and hospital stay, while the rates of aortic events and reinterventions are high after HAR in comparison with OAR.^{2, 17, 18}

Conclusion

Despite high rates of reinterventions and reoperations after thoracic endovascular aortic repair in comparison with open total arch replacement, thoracic endovascular aortic repair is recommended for the treatment of aortic arch aneurysms in high-risk patients unamenable to open total arch replacement.

References

1. Gandet T, Canaud L, Ozdemir BA, Ziza V, Demaria R, Albat B, Alric

- P. Factors favoring retrograde aortic dissection after endovascular aortic arch repair. *J Thorac Cardiovasc Surg* 2015;150:136-142.
2. Tokuda Y, Oshima H, Narita Y, Abe T, Araki Y, Mutsuga M, Fujimoto K, Terazawa S, Yagami K, Ito H, Yamamoto K, Komori K, Usui A. Hybrid versus open repair of aortic arch aneurysms: comparison of postoperative and mid-term outcomes with a propensity score-matching analysis. *Eur J Cardiothorac Surg* 2016;49:149-156.
3. 1. Elhelali A, Hynes N, Devane D, Sultan S, Kavanagh EP, Morris L, Veerasingam D, Jordan F. Hybrid repair versus conventional open repair for thoracic aortic arch aneurysms. *Cochrane Database Syst Rev* 2021;6:CD012923.
4. Ghanta RK, Mery CM, Kron IL. Aortic dissection. In: Cohn LH, Adams DH, eds. *Cardiac Surgery in Adult*. 5th ed. New York: Mc Graw Hill Education; 2018. p. 1003-1037.
5. Jaafar R, Mohamad I. Hoarseness as the sole symptom of an impending thoracic aneurysm rupture? *Malays Fam Physician* 2014;9:25-27.
6. Collins JS, Evangelista A, Nienaber CA, Bossone E, Fang J, Cooper JV, Smith DE, O'Gara PT, Myrmet T, Gilon D, Isselbacher EM, Penn M, Pape LA, Eagle KA, Mehta RH; International Registry of Acute Aortic Dissection (IRAD). Differences in clinical presentation, management, and outcomes of acute type a aortic dissection in patients with and without previous cardiac surgery. *Circulation* 2004;110(11 Suppl 1):II237-242.
7. Oladokun D, Patterson BO, Sobocinski J, Karthikesalingam A, Loftus I, Thompson MM, Holt PJ. Systematic review of the growth rates and influencing factors in thoracic aortic aneurysms. *Eur J Vasc Endovasc Surg* 2016;51:674-681.
8. Booher AM, Eagle KA. Diagnosis and management issues in thoracic aortic aneurysm. *Am Heart J* 2011;162:38-46.e1.
9. Bickerstaff LK, Pairolero PC, Hollier LH, Melton LJ, Van Peenen HJ, Cherry KJ, Joyce JW, Lie JT. Thoracic aortic aneurysms: a population-based study. *Surgery* 1982;92:1103-1108.
10. Geisbüscher P, Kotelis D, Müller-Eschner M, Hyhlik-Dürri A, Böckler D. Complications after aortic arch hybrid repair. *J Vasc Surg* 2011;53:935-941.
11. De Rango P, Cao P, Ferrer C, Simonte G, Coscarella C, Cieri E, Pogany G, Verzini F. Aortic arch debranching and thoracic endovascular repair. *J Vasc Surg* 2014;59:107-114.
12. Al Jabbari O, Abu Saleh WK, Irshad A, Christensen T, Bruckner B, Bismuth J, Loebe M. Case report: delayed type A aortic dissection following complete debranching of the aortic arch and stent graft placement. *Methodist Debakey Cardiovasc J* 2016;12:45-47.
13. Mosquera VX, Marini M, Fraga-Manteiga D, Gulias D, Cuenca JJ. Repair of late retrograde type A aortic dissection after TEVAR: causes and management. *J Card Surg* 2016;31:164-167.
14. Yammine H, Briggs CS, Stanley GA, Ballast JK, Anderson WE, Nussbaum T, Madjarov J, Frederick JR, Arko FR, 3rd. Retrograde type A dissection after thoracic endovascular aortic repair for type B aortic dissection. *J Vasc Surg* 2019;69:24-33.
15. Higashigawa T, Kato N, Chino S, Hashimoto T, Shimpo H, Tokui T, Mizumoto T, Sato T, Okabe M, Sakuma H. Type A aortic dissection after thoracic endovascular aortic repair. *Ann Thorac Surg* 2016;102:1536-1542.
16. Joo HC, Youn YN, Kwon JH, Won JY, Lee DY, Ko YG, Choi D, Yoo KJ. Late complications after hybrid aortic arch repair. *J Vasc Surg* 2019;70:1023-1030.e1.
17. Xydas S, Mihos CG, Williams RF, LaPietra A, Mawad M, Wittels SH, Santana O. Hybrid repair of aortic arch aneurysms: a comprehensive review. *J Thorac Dis* 2017;9:S629-S634.
18. Bachet J. Open repair techniques in the aortic arch are still superior. *Ann Cardiothorac Surg* 2018;7:328-344.