


Orbital phlebography in idiopathic intracranial hypertension and chronic tension-type headache

Jan Hannerz¹, Kaj Ericson², Dan Greitz²,
Pernille Hanne Bro Skejo² and Gunnar Edman³

Acta Radiologica Short Reports
0(0) 1–7
© The Foundation Acta Radiologica
2013
Reprints and permissions:
sagepub.co.uk/journalsPermissions.nav
DOI: 10.1177/2047981613498861
arr.sagepub.com


Abstract

Background: Pathologic signs in orbital phlebographies have been reported in various neurological diseases.

Purpose: To study if pathologic signs in orbital phlebography may be markers of inflammation primarily affecting intracranial capillaries, which would cause intracranial hypertension.

Material and Methods: Two groups with different intracranial cerebrospinal fluid pressures (Pcsf) were compared as to inflammatory markers in serum and pathologic signs in orbital phlebographies. Nine consecutive patients with idiopathic intracranial hypertension (IIH) with bilateral papilledema and eight consecutive patients with chronic tension-type headache (CTTH) were investigated prospectively with fibrinogen, orosomucoid, haptoglobin in serum, and invasive orbital phlebograms. The angiograms were evaluated by two skilled neuroradiologists, independent of each other and without knowledge of the diagnoses or aim of the study, as to the following pathologic signs: (i) narrowing of superior ophthalmic veins; (ii) caliber changes of intraorbital veins; (iii) collaterals of intraorbital veins; (iv) flow to cavernous sinus; and (v) asymmetric drainage of cavernous sinus.

Results: Mean body mass index was $>30 \text{ kg/m}^2$ in both groups. Pcsf was $>200 < 250 \text{ mm H}_2\text{O}$ in 50% of the CTTH and $>350 \text{ mm H}_2\text{O}$ in all IIH patients. No difference in inflammatory markers in blood was found. The phlebographies of the IIH patients had more pathologic signs and were considered pathologic significantly more often than the ones of the CTTH patients ($P < 0.001$).

Conclusion: The difference as to phlebographic pathologic signs between the IIH and the CTTH patients with different Pcsf supports the hypothesis that such phlebographic signs are markers of inflammation primarily affecting intracranial capillaries, which would disturb cerebrospinal fluid regulation causing intracranial hypertension.

Keywords

Idiopathic intracranial hypertension, chronic tension-type headache, venous vasculitis, low-grade capillaritis, orbital phlebography

Date received: 21 June 2013; accepted: 2 July 2013

Introduction

Orbital phlebography appears at present to be the most sensitive method for investigation of the blood flow compartments in the intraorbital veins and the cavernous sinus. Magnetic resonance imaging (MRI) technology seems for the moment not precise enough to detect the subtle changes involved in the study of changes of small intracranial veins. We have performed >2000 orbital phlebographies (successfully in $>95\%$) without any complications. Orbital phlebography has, however,

not been much used for diagnosing since Milstein and Morretin reported pathologic signs in such angiograms in patients with episodic painful ophthalmoplegia

¹Karolinska Hospital, Solna – Neurology, Stockholm, Sweden

²Karolinska Hospital, Solna – Neuroradiology, Stockholm, Sweden

³Tiohundra AB, Norrtälje – Psychiatry, Norrtälje, Sweden

Corresponding author:

Jan Hannerz, Karolinska Hospital, Solna – Neurology, Stockholm 17176, Sweden.

Email: errata-4dx@hotmail.com

(Tolosa-Hunt syndrome [THS]) (1). In a study of orbital phlebography in THS patients compared to healthy controls the main pathologic signs in such angiograms were established (2). Since only 68% of the untreated THS patients had pathologic phlebographies and the venous outflow only tended to be impeded but not completely blocked in these phlebograms (2), the mechanism causing THS has usually not been considered satisfactorily explained by the angiographic findings. Other diseases besides THS have also been reported to display similar findings in orbital phlebographies (3–7).

Although the phlebographic changes are often bilateral in such patients, when unilateral they have been found to be ipsilateral to the neurological symptoms (2,3,8) and are also known to disappear after the neurological symptoms have vanished (8).

Blood tests in patients with pathologic orbital phlebographies have been found to show signs of low-grade inflammation that decrease when the neurological symptoms have disappeared (8–11). Such signs of inflammation have also been found in patients suffering from idiopathic intracranial hypertension (IIH) (12). Furthermore, one pathoanatomical study in a THS patient showed inflammation in the veins of the straight lateral muscle to the affected eye (2) and another pathoanatomical study in another such patient indicated that the inflammation is systemic (13), which agrees with the assumption that such inflammation may cause various neurological symptoms. For obvious reasons pathoanatomical studies are rare. Patients with pathologic signs in orbital phlebographies experience relief of the symptoms when treated with anti-inflammatory steroids (4,14–16).

It has been shown in many studies in both man and animals that cerebrospinal fluid (CSF) is absorbed mainly from the extracellular spaces of the brain by the intracranial capillaries and then transferred to the venous system (17–20) and that these capillaries also contribute to the CSF production. This implies that cerebrospinal fluid pressure (Pcsf) is dependent on the balance between fluid production and absorption in the brain capillaries.

Disturbances affecting these intracranial capillaries, like inflammation, may cause idiopathic intracranial hypertension (IIH). Studies of various inflammatory and hemostatic tests in IIH patients, compared to healthy controls, that only showed low-grade inflammation support this notion (12). In a study of patients suffering from IIH and patients suffering from chronic tension-type headache (CTTH), Pcsf was significantly greater than the intracranial venous pressure in the majority of the IIH patients, while the two pressures were similar in the CTTH patients (21), a finding that also indicates that the Pcsf-regulating intracranial capillaries were affected in IIH. These findings disagree with

the hypothesis that the flow disturbances in intracranial veins reported by Farb et al. may be stenoses causing IIH (22). It should also be stressed that flow MR is showing the flow, not the anatomy.

Larger, presumably swollen, brains were found in many obese patients with increased Pcsf compared to controls, which agrees with the notion of disturbed CSF absorption or increased fluid permeability of the capillaries, possibly related to inflammation (23).

It is hypothesized that the pathologic phlebographic signs are related to low-grade inflammation primarily affecting intracranial capillaries and that the pathologic signs in the phlebograms, besides being signs of inflammation in the veins, can be considered to be markers of intracranial capillaritis. Such a view would explain why not all untreated patients display pathologic signs in the veins during, for instance, a THS episode.

Intracranial Pcsf is 150 ± 50 mm H₂O in healthy subjects, although for obese patients Pcsf up to 250 mm H₂O has been considered normal (24).

If pathologic signs in orbital phlebographies are markers of inflammation in intracranial capillaries, IIH patients with papilledema, i.e. Pcsf > 350 mm H₂O (21), should show more pathologic signs in orbital phlebographies than patients suffering from CTTH with normal or slightly increased Pcsf (21,25,26). In order to test this hypothesis, inflammation markers in serum and orbital phlebographies were studied prospectively in IIH patients with Pcsf > 350 mm H₂O and in CTTH patients with Pcsf < 250 mm H₂O.

Material and Methods

Nine consecutive IIH patients and eight consecutive CTTH patients, diagnosed according to the IHS criteria (24), were investigated with invasive orbital phlebograms performed by one of the authors (KE). Since normal values for Pcsf are not distinct (150 ± 50 mm H₂O in non-obese and up to 250 mm H₂O in obese persons), bilateral papilledema, i.e. Pcsf > 350 mm H₂O (21), was added as inclusion criterion for the IIH patients of the present study. The medical histories and records of all patients were scrutinized to exclude known causes for intracranial hypertension. Except for case 6, who suffered from ulcerative colitis, none of the patients suffered from coagulopathy, inflammatory, or other diseases than IIH and CTTH. The IIH patients were diagnosed at the start of the present investigation and were not on any treatment, including case 6. The IIH patients had not been treated medically or surgically at the start of the investigation. All the patients were studied as to conventional inflammatory markers fibrinogen, orosomucoid, and haptoglobin in

peripheral blood (analyses performed by the chemical laboratory of the hospital), since various other inflammatory and hemostatic markers have not been shown to be more adequate (12). They were also investigated with computerized tomography of the brain and contrast-enhanced MR venography to exclude cerebral tumor, sinus venous thrombosis, and other intracranial pathology. No patients were excluded from the study after the start of the investigation.

A frontal vein was punctured using a thin Teflon cannula with an outer diameter of 0.8 mm and a length of 24 mm. Antero-posterior, semi-axial, and axial views were obtained during the manual injection of about 8 mL of Isopaque Cerebral (280 mg I/mL, Nycomed, Oslo, Norway) for each series. The injection time was 2–3 s. In the majority of the examinations the series consisted of four full size films at a speed of 0.5/s. Subtraction technique was always used. Lateral views were not usually included. During the examination, digital compression of the superficial facial veins and the supraorbital veins was applied by the patient (Fig. 1a).

The ophthalmic veins are in free communication with the cavernous sinuses via the superior orbital fissure. Since the facial veins have no valves, the flow in the ophthalmic veins can be both antegrade and retrograde. The contrast injection in combination with the digital compression causes retrograde flow in the ophthalmic veins with retrograde contrast filling of the intracranial veins, i.e. the cavernous sinuses and their venous drainage through the inferior petrosal sinuses. Orbital phlebography in a healthy person demonstrates normally appearing intraorbital veins as well as total filling and symmetrical drainage of the cavernous sinuses like in Fig. 1b.

Two skilled neuroradiologists (DG and PBS) graded, on their own, the changes in the series of orbital phlebograms of each patient without having seen the angiograms prior to their evaluation and without knowledge of the aim of the study or the clinical diagnoses of the patients. The orbital phlebograms were studied, as to: (i) narrowing of the superior ophthalmic veins; (ii) caliber changes of the veins; (iii) collaterals of the veins; (iv) flow to the cavernous sinus; and (v) asymmetric drainage of the cavernous sinus (Fig. 1). According to the findings of these parameters in the angiograms, they were evaluated on a 4-point scale: 1, normal; 2, probably normal; 3, probably pathologic; and 4, pathologic; the numbers were then used in the statistical calculations as to differences in the two groups.

The lumbar punctures were performed with 22-gauge needles with the patient lying on the left side after having rested in this position for at least 15 min.

Statistical analysis

All variables were summarized by descriptive statistics using such as means and standard deviations. Provided that the variables were approximately normally distributed, parametric tests were applied in the statistical analyses. Thus differences between IIH and CTTH patients were studied by means of Student's t-test, except for the duration of the IIH and CTTH when non-parametric Mann-Whitney test was used (exact two-tailed).

Informed consent was obtained from all patients and the study was approved by the institutional review board, the Ethics Committee of Karolinska University Hospital.

Results

The CTTH patients were significantly older (mean, 42.3 years; standard deviation, 8.3) than the IIH patients (mean, 31.4 years; SD, 10.6) ($P < 0.035$) (Table 1).

All patients in the two groups were women except for one man in the IIH group (Table 1).

The duration of the symptoms of each patient was estimated in months. In CTTH it was significantly longer (in cases 10–17) (mean, 40.5 months; SD, 30.2) than in IIH (cases 1–9) (mean, 9.6 months; SD, 6.3) ($P > 0.008$).

Almost all patients in the two groups were overweight or obese. No significant difference was found between the two groups as to BMI (mean, 31.3 kg/m²; SD, 5.3 in CTTH; mean, 31.7 kg/m²; SD, 7.4 in IIH), (BMI > 25 overweight, >30 obesity) (Table 1).

No statistical difference was found as to values of fibrinogen, orosomucoid, or haptoglobin in serum between the two groups (Table 2).

The IIH patients had significantly greater Pcsf (mean, 405 mm H₂O; SD, 32.7) than the CTTH patients (mean, 204 mm H₂O; SD, 17.7) ($P < 0.001$) (Table 1).

All IIH patients were found to have pathologic signs in their orbital phlebographies, although one of the nine patients was considered to have such signs only by one of the evaluating neuroradiologists. The eight CTTH patients were all found to have no signs of pathology in their angiograms by one evaluator while the other neuroradiologist considered one CTTH patient as having two signs and three patients one sign of pathology (Table 3). When the statistical evaluation was performed as to if an orbital phlebography was to be considered pathologic, probably pathologic, probably normal, normal, as described in Material and Methods, significant difference between the two groups was found ($t(15)06,20$; $P < 0.001$) (Table 3).

The pathologic findings were not symmetric as to their localization.

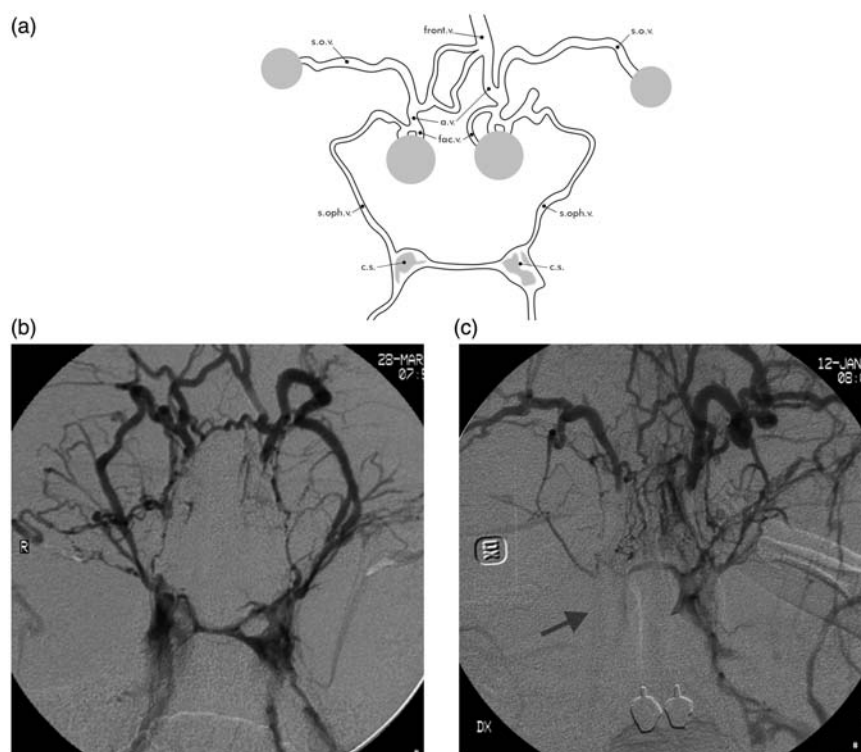


Fig. 1. (a) Schematic anatomy of veins in the orbital phlebography. Dots indicate the compression sites of the supraorbital branches of frontal veins and of superficial facial veins. a.v., angular vein; c.s., cavernous sinus; fac.v., facial vein; front.v., frontal vein; s.o.v., supraorbital vein; s.oph.v., superior ophthalmic vein. (b) Orbital phlebography in CTTH patient (case 11) with no pathologic changes. Normal width of the v-shaped superior ophthalmic veins, symmetric filling, and drainage of the cavernous sinuses. (c) Orbital phlebography in IIH patient (case 6) with marked bilateral narrowing and caliber changes of the superior ophthalmic veins, deficient flow and filling of the cavernous sinus (arrow), and asymmetric drainage of the cavernous sinus. The marked narrowing of the v-shaped right and left ophthalmic veins is easier to appreciate when relating to the width of the non-affected supraorbital veins (also compare to Fig. 1b). The pathology is thus bilateral and cannot be due to a tumor or some other compressing process, which do not display all these pathologic changes.

Discussion

The hypothesis that pathologic signs in orbital phlebography are markers of low-grade inflammation primarily affecting intracranial capillaries disturbing the CSF regulation, was tested as to such phlebographic signs in IIH patients with Pcsf > 350 mm H₂O and in CTTH patients with Pcsf < 250 mm H₂O.

All IIH patients were found to have pathologic signs in their orbital phlebograms, although one of these nine patients was only considered to have such signs by one of the evaluating neuroradiologists. One evaluator found no pathologic signs in any of the eight CTTH patients while the other neuroradiologist considered that four CTTH patients showed no pathological signs, three one such sign and one two signs (Table 3). Evaluation of orbital phlebograms is admittedly subjective as is evaluation of MR images. Although the neuroradiologists were not in complete agreement as to the pathologic signs in the

phlebograms, significant difference was found between the two groups of patients ($P < 0.001$). The difference between the two groups in the present study may reflect a more acute and pronounced pathologic process in IIH patients than in the CTTH patients with no or only slightly increased Pcsf. The almost non-existent passage of contrast to the cavernous sinus in the phlebographies in many of the IIH patients in the present study (Fig. 1c) in contrast to in the CTTH patients (Fig. 1b) illustrates the difference in communication in both veins and capillaries and in fluid absorption in the two patient groups.

King et al. reported venous hypertension in the superior sagittal sinus and the transverse sinus and also venographic filling defects in the transverse sinus in IIH patients with papilledema, defects considered to suggest mural thrombi (27). These findings were detected with MR and did not show anatomy but flow. In a later study, King et al. concluded that the

Table 1. Age, sex, body mass index, intracranial pressure, headache type, and duration of headache.

Case	Age (years)	Sex	BMI	Pcsf	Headache	Duration
1	17	F	46	380	IIH	6 months
2	18	F	27	400	IIH	1.5 years
3	22	F	40	395	IIH	1 month
4	27	F	32	435	IIH	1 year
5	30	F	35	425	IIH	1.5 years
6	31	F	25	370	IIH	4 months
7	36	F	29	420	IIH	1 year
8	38	F	27	360	IIH	3 months
9	51	M	24	460	IIH	1 year
10	30	F	25	220	CTTH	8 years
11	35	F	35	235	CTTH	2 years
12	35	F	39.5	195	CTTH	1 year
13	39	F	28	190	CTTH	2 years
14	42	F	26.5	180	CTTH	5 years
15	48	F	27	195	CTTH	6 months
16	54	F	32	235	CTTH	3.5 years
17	73	F	36	220	CTTH	5 years

BMI, body mass index kg/m²; CTTH, chronic tension-type headache; IIH, idiopathic intracranial hypertension.

Table 2. Inflammatory markers in patients with idiopathic intracranial hypertension (cases 1–9) and chronic tension-type headache (cases 10–17).

Case	Fibrinogen	Orosomuroid	Haptoglobin
1	5.3*	0.98	1.7
2	2.8	0.37	1.1
3	4.5*	1.01	2.7*
4	3.4	0.74	1.1
5	5.4*	0.90	1.8
6	3.4	0.86	1.1
7	3.7	0.90	1.2
8	–	0.61	1.1
9	2.4	0.50	0.8
10	3.1	0.84	1.3
11	4.4*	0.97	1.9
12	2.0	1.20*	1.5
13	2.6	0.68	1.3
14	3.2	0.77	1.3
15	2.5	0.78	1.2
16	3.5	0.61	1.4
17	4.2	0.73	0.6

Normal ranges: Fibrinogen 2.0–4.2 g/L, Orosomuroid 0.45–1.15 g/L, Haptoglobin 0.4–2.0 g/L.

*Increased values.

Table 3. Findings of pathologic changes in orbital phlebograms of patients with idiopathic intracranial hypertension (cases 1–9) and chronic tension-type headache (cases 10–17).

Case	A	B	C	D	E	N/P
1	+/+	+/+	+/+	0/+	0/0	PP/P
2	+/+	0/+	0/+	+/+	0/+	P/P
3	0/+	+/+	+/+	0/+	0/+	PN/P
4	0/+	0/+	0/0	+/+	0/+	N/P
5	0/0	0/0	0/0	+/+	+/+	PP/P
6	+/+	+/+	+/+	+/+	+/+	P/P
7	+/0	+/0	+/0	0/0	0/0	PP/N
8	+/0	+/0	0/0	0/+	0/0	PP/N
9	+/+	+/+	+/+	0/+	0/+	P/P
10	0/0	0/0	0/0	0/0	0/0	N/N
11	0/0	0/0	0/0	0/0	0/0	N/N
12	0/0	0/0	0/0	0/0	0/0	N/N
13	0/0	+/0	0/0	0/0	0/0	N/N
14	+/0	0/0	0/0	0/0	0/0	PN/N
15	0/0	0/0	+/0	0/0	0/0	N/N
16	0/0	0/0	0/0	0/0	0/0	N/N
17	+/0	0/0	+/0	0/0	0/0	PP/N

Changes in orbital phlebograms as to narrowing of the superior ophthalmic veins (a), caliber changes of the veins (b), collaterals of the veins (c), flow to the cavernous sinus (d), drainage of the cavernous sinus (e) compared to normal conditions as evaluated by two neuroradiologists. 0, normal; +, pathologic; N, normal; P, pathologic; PN, probably normal; PP, probably pathologic.

venous hypertension recorded in the transverse sinus was secondary to the intracranial hypertension and not to a primary obstructive process in the cerebral venous sinuses (28). It is not probable that the pathologic findings in the orbital phlebograms in the IIH patients of the present study were due to similar compression by Pcsf, as in the King reports, due to their non-symmetrical and non-uniform appearances of the phlebographic changes and also due to the differences in the localization of the changes between different IIH patients with similar Pcsf.

Furthermore, bilateral obstructions of the transverse sinuses should result in cerebral venous stasis with secondary dilation of the cerebral veins and transcranial collateral veins such as the emissary veins and ophthalmic veins. For example, a cavernous arteriovenous fistula increases the pressure in the cavernous sinus with secondary exophthalmus and dilation of the ophthalmic veins. This is contrary to our finding of narrowing of the ophthalmic veins in the IIH patients. The narrowing of the ophthalmic veins supports the notion that it is caused by primary changes in the vessel wall such as inflammation and contradicts the assumption that it is secondary to bilateral obstruction of the transverse sinuses.

Most IIH and CTTH patients suffered from overweight and obesity. Obesity is known to be pro-inflammatory (29), but it is not considered to be the primary cause of inflammation in the patients of the present study, since not all patients with pathologic orbital phlebographies have been found to be overweight or obese (30). Furthermore, no difference as to BMI was found between the two groups of patients with significant differences as to pathologic signs in their phlebographies.

The absence of a significant difference as to inflammatory markers in blood in the two groups may be due to the small number of patients in the two groups or indicate that CTTH patients also suffer from disturbed CSF regulation since 50% of such patients are known to have Pcsf above 200 mm H₂O (21,25,26).

It is hard to disregard the unilaterality of the phlebographic pathologic signs corresponding to the neurological symptoms (2,3,8), the temporal relation between such signs and the neurological deficiency (8), the findings of low-grade inflammation in blood tests in patients with pathologic phlebograms (8–12), the temporal relation between such inflammatory signs and the neurological symptoms (12), the amelioration of the symptoms of patients with the pathologic phlebographic signs, including IIH patients, on steroid treatment (4,14–16), the pathoanatomical findings in patients with such pathologic angiograms (2,13), the difference between Pcsf and intracranial venous blood pressure in IIH patients compared to CTTH patients (21), the swollen brains in IIH patients (23), and the relation between Pcsf and pathologic signs in orbital phlebograms in the present study.

In conclusion, all these findings may, besides being signs of inflammation of intracranial veins, be considered as markers of low-grade inflammation primarily affecting intracranial capillaries. Such a view explains that not all patients suffering from THS and other diseases mentioned above have pathologic orbital phlebograms. The findings of the present study that indicate systemic inflammatory disease in IIH prompt studies of the efficacy of treatment of such patients with non-steroidal anti-inflammatory drugs.

Funding

This research received no specific grant from any funding agency in the public, commercial, or not-for-profit sectors.

References

- Milstein BA, Morretin LB. Report of a case of sphenoid fissure syndrome studied by orbital venography. *Am J Ophthalmol* 1971;72:600–603.
- Hannerz J, Ericson K, Bergstrand G. Orbital phlebography in patients with Tolosa-Hunt's syndrome. *Acta Radiol Diagn* 1984;25:457–463.
- Hannerz J, Ericson K, Bergstrand G. Orbital phlebography in patients with cluster headache. *Cephalalgia* 1987;7:207–211.
- Hannerz J, Ericson K, Bergstrand G. A new aetiology for visual impairment and chronic headache. *Cephalalgia* 1986;6:59–63.
- Hannerz J, Ericson K, Bergstrand G. Chronic paroxysmal hemicrania:orbital phlebography and steroid treatment. *Cephalalgia* 1987;7:189–192.
- Hannerz J, Greitz D, Hansson P, et al. SUNCT may be another manifestation of orbital venous vasculitis. *Headache* 1992;32:384–389.
- Hannerz J. Trigeminal neuralgia with chronic paroxysmal hemicrania: the CPH-tic syndrome. *Cephalalgia* 1993;13:361–364.
- Hannerz J. Recurrent Tolosa-Hunt syndrome. *Cephalalgia* 1992;12:457–463.
- Hannerz J. Systemic symptoms associated with orbital venous vasculitis. *Cephalalgia* 1988;8:255–263.
- Hannerz J. Orbital phlebography and signs of inflammation in episodic and chronic cluster headache. *Headache* 1991;31:540–542.
- Hannerz J. Recurrent Tolosa-Hunt syndrome: a report of ten new cases. *Cephalalgia* 1999;19 (Suppl. 25):33–35.
- Hannerz J, Antovic JP, Blombäck M, et al. Haemostatic and inflammatory markers in idiopathic intracranial hypertension. *J Intern Med* 2011;270:496–499.
- Hannerz J. Pathoanatomic studies in a case of Tolosa-Hunt syndrome. *Cephalalgia* 1988;8:25–30.
- Hunt WE, Meagher JN, LeFever HE, et al. Painful ophthalmoplegia. Its relation to indolent inflammation of the cavernous sinus. *Neurology* 1961;196:56–62.
- Jammes JL. The treatment of cluster headache with prednisone. *Dis Nerv Syst* 1975;36:375–376.
- Paterson R, De Pasquale N, Mann S. Pseudotumor cerebri. *Medicine* 1961;40:85–99.
- Dandy WE, Blackfan KD. Internal hydrocephalus. An experimental, clinical and pathological study. *Am J Dis Child* 1914;8:406–481.
- Greitz D. Cerebrospinal fluid circulation and associated intracranial dynamics. A radiologic investigation using MR imaging and radionuclide cisternography. *Acta Radiol Suppl* 1993;386:1–23.
- Bulat M. Dynamics and statics of the cerebrospinal fluid: the classical and a new hypothesis. In: Avezaat CJJ, van Eijdenhoven JHM, Mass AIR, et al., eds. *Intracranial pressure VIII*. Berlin: Springer-Verlag, 1993, pp.726–730.
- Bulat M, Klarica M. Recent insights into a new hydrodynamics of the cerebrospinal fluid. *Brain Research Reviews* 2011;65:99–112.
- Hannerz J, Ericson K. The relationship between idiopathic intracranial hypertension and obesity. *Headache* 2009;49:178–184.
- Farb RI, Vanek I, Scott JN, et al. Idiopathic intracranial hypertension. The prevalence and morphology of sinovenous stenosis. *Neurology* 2003;60:1418–1424.

23. Hannerz J, Greitz D, Ericson K. Is there a relationship between obesity and intracranial hypertension? *Int J Obesity* 1995;19:240–244.
24. Headache Classification Subcommittee of the International Headache Society. The International Classification of Headache Disorders; 2nd edition. *Cephalalgia* 2004;24 (Suppl. 1):1–160.
25. Hannerz J, Jogestrand T. Is chronic tension-type headache a vascular headache? The relation between chronic tension-type headache and cranial hemodynamics. *Headache* 1998;38:668–675.
26. Hannerz J, Schnell P-O, Larsson Stig, et al. Blood pool scintigraphy of the skull in relation to head-down tilt provocation in patients with chronic tension-type headache and controls. *Headache* 2004;44:223–229.
27. King JO, Mitchell PJ, Thomson MB, et al. Cerebral venography and manometry in idiopathic intracranial hypertension. *Neurology* 1995;45:2224–2228.
28. King JO, Mitchell PJ, Thomson MB, et al. Manometry combined with cervical puncture in idiopathic intracranial hypertension. *Neurology* 2002;58:26–30.
29. Sinclair AJ, Ball AK, Burdon MA, et al. Exploring the pathogenesis of IHH: an inflammatory perspective. *J Neuroimmunol* 2008;201–202:212–220.
30. Hannerz J, Greitz D, Ericson K. Periorbital venous vasculitis, intracranial hypertension and empty sella. *Headache* 1994;34:95–98.