



COVID-associated rhinocerebral mucormycosis: a retrospective analysis of presentation and outcomes

Aditya Moorthy^{1,2,4} · Tulasi Nayak^{1,2} · Prithvi S Bachalli^{1,2,4} · Krishna Kant Tripathi³ · Sunil Narayan Dutt⁴ · Preeti Kale¹ · Prashanth Bhat^{1,2} · Praveen K Suresh^{1,2} · Rohith Gaikwad^{1,2} · Arjun Raju^{1,5} · Shreya Krishna² · Arvind Conjeevaram¹ · Sushma Mehta^{1,2} · Abhinav Anil-Kumar^{1,2} · Deepak Haldipur¹

Received: 12 May 2022 / Accepted: 5 July 2022

© The Author(s), under exclusive licence to Springer-Verlag GmbH Germany, part of Springer Nature 2022

Abstract

Objectives To comprehensively analyse the disease presentation and mortality of COVID-associated rhino-orbito-cerebral mucormycosis.

Methods A retrospective analysis of the demographics, clinical and radiographic findings was performed. A binary logistic regression analysis was performed to examine the survival of patients with mucormycosis from hypothesised predictors.

Results A total of 202 patients were included in this study. Statistical significance was demonstrated in the predilection to the male gender, recent history of SARS-COV-2, history of use of corticosteroid and hyperglycemia in this cohort of CAM. The mortality rate was 18.31%. Advanced age, raised HbA1c and intra-orbital extension were found to be predictors adversely affecting survival.

Conclusion Early diagnosis, aggressive surgical therapy, early and appropriate medical therapy can help improve outcomes.

Level of evidence Level 4.

Keywords Mucormycosis · COVID · Rhino-cerebral · Rhino-orbito-cerebral mucormycosis · ROCM · COVID-associated mucormycosis · CAM

Introduction

Mucormycosis is a devastating fungal infection with high mortality [1]. While the incidence of mucormycosis has historically been higher in the Indian subcontinent [2], there was an unprecedented surge of cases during the COVID-19 pandemic. Although cases of mucormycosis were reported during the first wave [3], the sheer numbers during the second wave was staggering—to the extent that it assumed epidemic proportions and was termed COVID-associated mucormycosis (CAM) [4].

This spurt of CAM during an ongoing pandemic stressed an already overwhelmed health care system [5]. Prior to this sudden spike, the disease was reported sporadically, mostly in patients with significant immune compromise and with late clinical presentation. The shortage of data on CAM was even more significant. With a paucity of standardised protocols to treat mucormycosis, much less CAM, we formed a multidisciplinary team to provide comprehensive management to a large cohort of patients. This paper describes the full range of disease presentation, endoscopic findings, pathway of disease spread and surgical debulking techniques. We aim to fill some of the gaps in literature about the management of the disease.

✉ Tulasi Nayak
drtulasinayak@gmail.com

¹ Trustwell Hospitals, Bengaluru, Karnataka, India
² Rangadore Memorial Hospital, Bengaluru, Karnataka, India
³ Care Institute of Medical Sciences, Ahmedabad, Gujarat, India
⁴ Apollo Hospitals, Bengaluru, Karnataka, India
⁵ Medall Diagnostics, Bengaluru, India

Materials and methods

This research was conducted as per ICH–GCP guidelines (Certificate attached). In this retrospective observational case series, all consecutive patients treated for rhino-orbito-cerebral mucormycosis (ROCM) at three tertiary care

centres between April 2021 and July 2021 were analysed. The data were derived from patient files to include a final sample of 202 patients.

As a part of a multidisciplinary treatment protocol, patients were reviewed by otorhinolaryngology, maxillofacial, ophthalmology and neurosurgical teams. A thorough clinical history was recorded along with a clinical examination consisting of an intra- and extraoral examination and nasal examination including endoscopy. An ophthalmologic evaluation included visual acuity test, slit-lamp examination and fundoscopy. Patients underwent a standard neurological examination. Suspicious tissue was evaluated for fungal elements via a KOH test. Radiological examination consisted of a computed tomography (CT) of the craniofacial skeleton and contrast enhanced Magnetic Resonance Imaging (MRI) of the brain and orbits. HbA1c was studied as a measure of glycaemic control. Appropriate surgical intervention was performed to reduce disease burden. Tissue was sent for histopathology. Following a definitive diagnosis of mucormycosis (either by microbiology or histology), systemic antifungal therapy was instituted. The patients have been followed up for a minimum of 6 month post-surgery. A univariate and multiple logistic regression analysis has been performed to analyse the influence of several predictors (age, sex, HbA1c, involvement of sinuses, maxillae, involvement of the orbital wall, involvement of the intra-orbital space and presence of any other intracranial disease) on the survival of the patients.

Statistical analysis

Binomial probabilities were calculated to examine if the distribution, determinants or sequels of the disease had a specific propensity using the following equation:

$$P(x = k) = \binom{n}{k} p^k q^{(n-k)}$$

where

$$\binom{n}{k} = \frac{n!}{k!(n-k)!}$$

k is the observed frequency, P is the probability of observed frequency ($x=k$), p is the hypothesised probability of a success or chance occurrence ($p=0.5$ in this instance). q is the hypothesised probability of not getting a success ($1-p$), n is the number of trials.

To decide on the propensity of the disease to a specific gender, we calculated probability of getting 0, 1, 2 or k male/female patients out of a total of 202, had it been a chance occurrence. All these probabilities were added to determine the probability of such an occurrence had it occurred by chance alone.

Table 1 Age and gender distribution of our cohort

AGE in years	Total no. of patients	No. of male patients	No. of female patients
0–19	1	1	0
20–29	2	2	0
30–39	35	30	5
40–49	66	51	15
50–59	44	30	14
60–69	39	29	10
70–79	11	7	4
80–89	4	3	1

The above were exact probabilities and obviated the requirement of any interval estimate.

A χ^2 test was used to examine if a specific age group was more susceptible. This was applied to decadal data.

Binary logistic regression analysis was performed to identify significant determinants and extent of their attribution to survival. For this analysis, survival was the outcome (dependent) variable and age, sex, HbA1c, involvement of sinuses, maxillae and orbital wall, intra-orbital space and intracranial disease were predictor (independent) variables. After pairwise deletion of data in some of the cases (where complete information was not available), a total of 179 cases were submitted to binary logistic regression analysis. Categorical variables were coded as—survival—1, death—0; female—1, and male—0; involvement of sinuses not present—1, present—0; involvement of maxillae not present—1, present—0; involvement of orbital wall not present—1, present—0; involvement of intra-orbital space not present—1, present—0; intracranial disease not present—1, present—0.

In general, significance level was set at $p < 0.05$. However, we have quoted exact probability of a particular (and equally extreme) occurrences.

Results

202 patients of CAM were included in the study, 153 (76%) were male and 49 (24%) were female (Table 1). The gender difference was significant with the binomial probability of such an occurrence ($p = 8.16E-14$) being less than that of mere chance occurrence ($p = 0.50$). The overall variation in the decadal occurrence of the cases was statistically significant ($\chi^2 = 245.12$, $p = 3.02E-49$) with maximum occurrence between 30 and 70 years of age (Table 1, Fig. 1). Most of the patients ($n = 189$) had a history of steroid administration in the recent past for the treatment of COVID-19. Only 11 patients presented with no history of steroid administration.

Information on steroid administration was not available for two patients. Occurrence of cases of mucormycosis with such a history of steroid administration in recent past far outnumbered that of cases without such history ($p = 1.35E-43$). The time frame, in which mucormycosis developed, after a positive RT-PCR test, was quite variable, ranging from 1 to 12 weeks (Fig. 2). Two patients were non diabetic with an HbA1c of < 5.7 , 10 patients were found to be pre-diabetic (HbA1c < 6.5) and 170 patients were found to be diabetic. No data were available in 20 patients. The association of diabetic state/glycaemic control with the disease occurrence was significant ($\chi^2 = 296.09, p = 5.07E-45$) (Table 2).

Clinical picture

The patients presented to us with one or more of the following complaints. A majority of the patients [101 patients (50%)] presented with facial pain. 51 patients (25.25%) complained of facial swelling, 41 patients (20.29%) with visual disturbance/loss of vision, 36 patients (17.82%) with headache, 36 patients (17.82%) with eye pain, 21 patients (10.4%) with cheek numbness and $< 10\%$ of patients other complaints (loose teeth, toothache, pain in the jaws, epiphora and blocked nose).

On clinical examination, intraoral tenderness was elicited in 50 patients (24.75%). Many presented with a combination of the following signs which signified underlying maxillary necrosis. 18 patients (8.9%) had boggy buccal and/or palatal tissue, 29 patients (14.35%) had a purple hue/duskiness of the hard palate, 24 patients (11.88%) had maxillary mobility, 27 patients (13.36%) had mobile teeth, mucosal erosion and exposure of necrotic bone was evident in 26 patients (12.87%) and 13 patients (6.43%) had intraoral pustules. On orbital examination, 24 patients (11.88%) presented with vision loss, 43 patients with proptosis (21.28%), 26 patients (12.87%) with a dilated pupil on the affected side, 43 patients (21.28%) with restriction in the gaze and 44 patients (21.78%) with perio-orbital swelling. Infraorbital paresthesia was elicited in 30 patients (14.85%). 4 patients (3.35%) had obvious skin necrosis (Fig. 3).

On nasal endoscopy, 77.14% of patients had purulent secretion, 39.28% of patients crusting and 14.28% of the patients had no abnormalities. The initial KOH reports in 146 patients (77.27%) showed mucorales, 8 patients (3.96%) had mixed fungal elements, 37 patients (18.31%) had no fungal elements and 11 reports were unavailable.

Fig. 1 Comparison of age distribution of our mucormycosis cohort (Black) vs. age distribution of COVID-19 patients (Grey) (x-axis—% of patient distribution, y-axis—age in years)

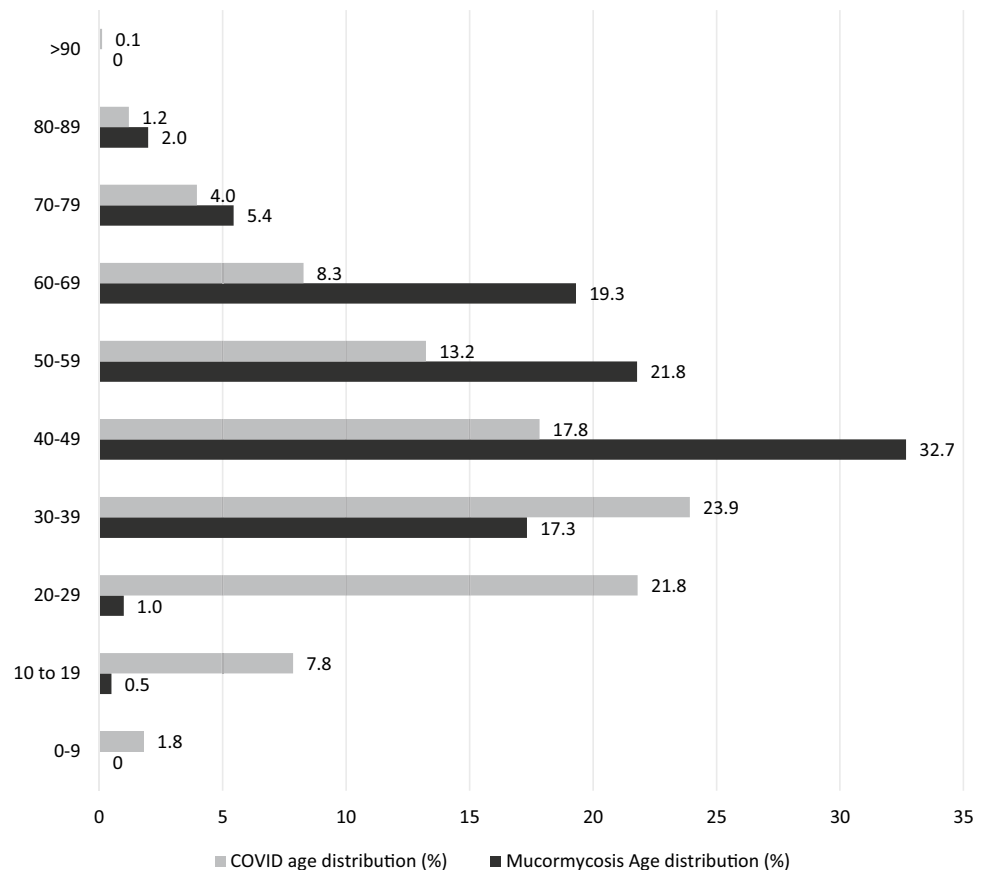
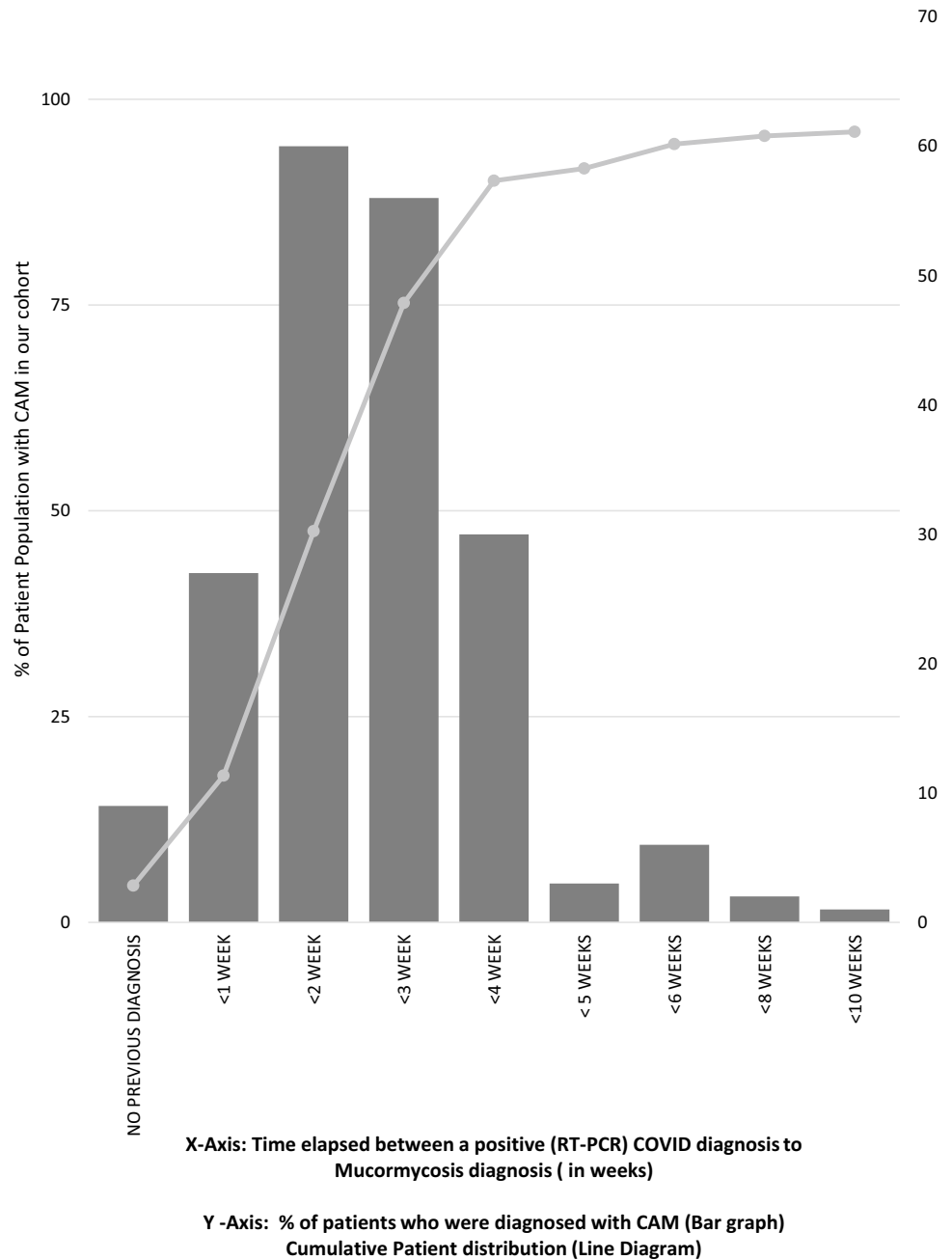


Fig. 2 Time elapsed between the occurrence of COVID-Mucormycosis after a positive RT-PCR



Imaging

CT of the craniofacial skeleton and contrast enhanced MRI of the brain and orbits were studied. Of the 202 patients, 23 preoperative scans were performed elsewhere and were unavailable for the study.

Sinus involvement

All but two patients presented with sinus involvement on the MRI. T2-weighted images showed hypointense soft tissue in the paranasal sinuses. On post-contrast sequences, it showed inhomogeneous enhancement in all patients. Two patients with isolated mandibular involvement did not have paranasal sinus involvement (Table 3).

Table 2 HbA1c of the patients at the first visit

	Hba1c	No. of patients
	Not available	20
Non-diabetic	< 5.7	2
Pre-diabetic	5.7–6.4	10
Diabetic	6.5–7	7
	7.1–8	23
	8.1–9	19
	9.1–10	35
	10.1–11	31
	11.1–12	25
	12.1–13	21
	> 13	9

Bone and soft tissue involvement

CT was useful in identifying established bony disease and the MRI scans identified early marrow edema and subperiosteal abscesses (Fig. 3).

T2Wt and T2Wt IRFSE (inversion-recovery fast spin-echo MR imaging) sequences showed edematous fat standing and inhomogeneously enhancing soft tissue thickening in the retro maxillary regions, extending into the pterygopalatine fossa medially and infratemporal fossa laterally in 38 patients (21.22%). The other significant finding was that 48 patients (26.81%) exhibited orbital cellulitis and

fat stranding and 67 patients had presented facial cellulitis (37.43%).

Based on the clinical and radiographic findings, various combinations of the following presentations were found. 36 patients were diagnosed with exclusive sinus disease, 57 patients were diagnosed with sinus disease with an extraconal component, 18 patients were diagnosed with sinus disease extending into the posterior maxillary wall, 70 patients were diagnosed with disease extension into the maxillary alveolus and palate, 21 patients were diagnosed with intraconal disease, and 2 patients presented with isolated mandibular involvement. 8 patients also had intracranial abscesses and 4 patients had disease extending into the skin. 8 patients were not completely investigated as they presented with sepsis and deteriorated rapidly.

All involved sinuses were treated with extensive endoscopic sinus debridement (EESD). Necrotic posterior maxillary wall and disease in the retromaxillary areas including pterygopalatine and infratemporal fossae were often debrided using an open approach (Caldwell Luc). Extraconal disease was treated with endoscopic debridement and decompression of the involved orbit via orbitotomy of the involved wall. The involved maxilla was debrided transversally until bleeding bone was reached. Orbital exenterations were performed in patients who presented to us with extensive intraconal disease, total blindness and imminent/existing intracranial disease spread. Exenterations were performed by a lid sparing approach. Well-defined intracranial

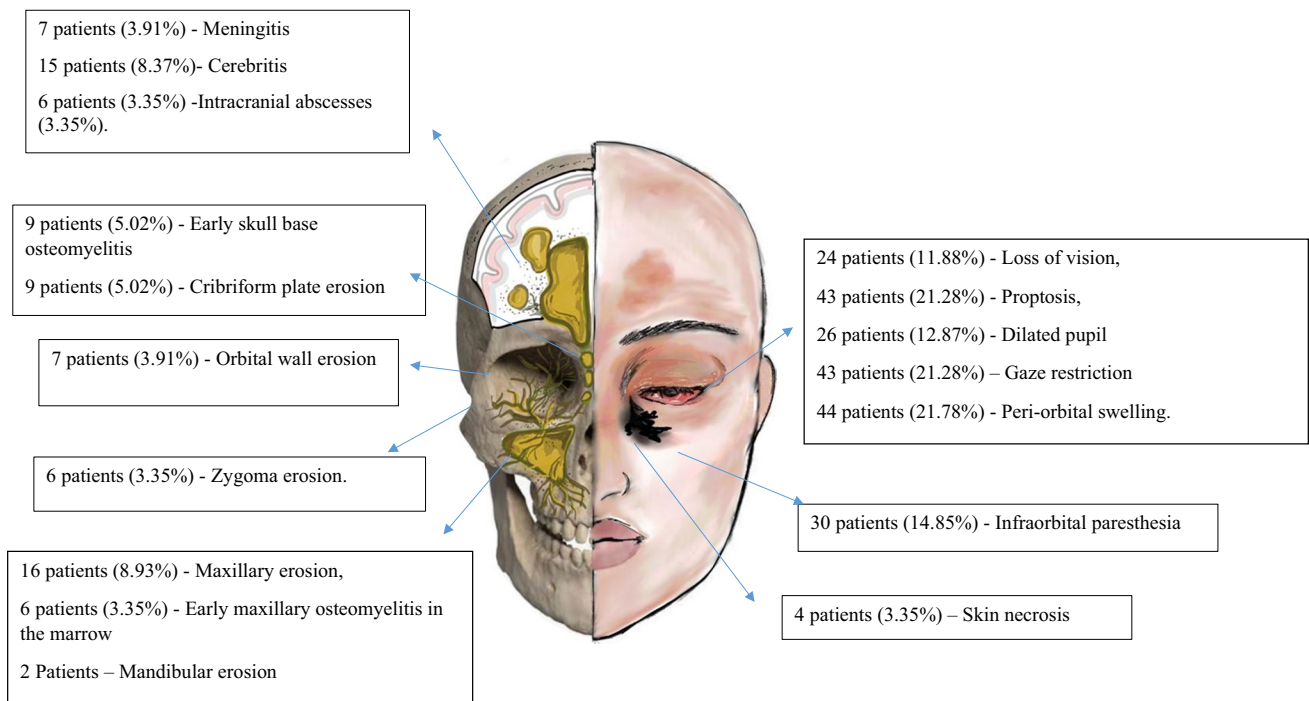


Fig. 3 Showing the clinical findings (left half) and radiographic findings of our cohort of patients with CAM (right half)

abscesses which could be excised safely were done so via a craniotomy.

Following the surgical therapy, IV Liposomal Amphotericin B (LAmB) was instituted at a dose of 3–5 mg/kg with a targeted cumulative dosage of 5 g for paranasal sinus disease and up to 10 g for intracranial disease when available. All patients received a maintenance therapy of oral gastro-resistant Posaconazole tablets. A team of nephrologists, gastroenterologists and physicians were actively involved in the medical management of the patients.

The patients have been regularly followed up till date. Scans were repeated at sequential intervals—1 week, 1, 3 and 6 months unless clinically dictated otherwise. Despite adequate therapy, some patients continued to have disease progression.

Disease progression

8 patients (of the 57 patients who had been treated endoscopic orbital decompression) progressed to develop intraconal disease with blindness and were recommended exenteration. Radiographically, two had no preoperative

intraconal disease; five of them retained light perception despite radiographic evidence of intraconal disease.

6 patients (4 of the 36 patients treated for exclusive sinus disease, 1 of the 18 patients with posterior maxillary debridement and 1 of the patient who had been treated with posterior maxillary debridement and orbital wall decompression) had disease progression into the maxilla after the primary surgery. Preoperatively, 4 of these had clinical signs without radiographic evidence of bone loss. 1 showed early maxillary erosion in the CT. One patient had no clinical or radiographic signs of disease in the maxilla during the initial assessment.

Two patients (of nine patients with cribriform erosion and seven patients with meningitis) progressed to well-formed cerebral abscesses that were excised. 4 patients of the 15 patients with cerebritis progressed to develop abscesses. Two of these patients refused intervention.

Four patients developed late skin involvement. Several patients required further bony debridement; three in the frontal bone, eight in maxilla and two in the zygoma.

Mortality

24 of the 37 deaths in the current cohort occurred in the early follow-up period (First 4 week postop) A univariate and multiple logistic regression analysis was performed to analyse the influence of several predictors on the survival of the patients.

Regression analysis of outcome from hypothesised predictors

The logistic regression model was created to examine if it would be possible to predict an outcome (survival) from age, sex, HbA1c, involvement of sinuses, maxillae, orbital wall and intra-orbital space and presence of any other intracranial disease, was statistically significant, $\chi^2 [(df=9)=26.60; p=0.001]$ Statistically Significant data has been marked in

Table 3 Table describing the involvement of sinuses in our cohort

Sinus involvement	No. of patients	%
Isolated maxillary sinus	22	12.29%
Isolated ethmoid air cells	2	1.11%
Maxillary and ethmoid sinuses	28	15.64%
Maxillary, ethmoid and sphenoid sinuses	17	9.49%
Maxillary, ethmoid and frontal sinuses	10	5.58%
Sphenoid and ethmoid sinuses	8	4.46%
Ethmoid, sphenoid and frontal sinuses	5	2.79%
Pansinusitis	85	47.48%
No sinus involvement	2	1.11%

Table 4 Variables in the regression equation (which were examined as possible determinants of survival)

	Univariate logistic regression		Multiple logistic regression	
	OR (CI)	Sig	OR (CI)	Sig
Age	0.968 (0.938–0.998)	0.047	0.958 (0.923–0.994)	0.026
Sex (male)	0.958 (0.395–2.323)	0.925	1.184 (0.424–3.307)	0.747
HbA1c	0.722 (0.584–0.892)	0.003	0.721 (0.561–0.926)	0.010
Involvement of sinuses	0.000	1.000	0.000	1.000
Involvement of maxillae	1.512 (0.632–3.615)	0.354	2.825 (0.848–9.407)	0.091
Involvement of orbital wall	1.418 (0.433–4.640)	0.564	2.944 (0.615–14.098)	0.177
Intra-orbital involvement	4.248 (1.624–11.127)	0.003	3.241 (1.058–9.926)	0.039
Presence of intra-cranial disease	1.435 (0.558–3.690)	0.454	1.107 (0.356–3.441)	0.861

Table 5 Classification table showing outcome of the disease as predicted by the model (using multiple logistic regression equation derived) and its comparison with the actual outcome

		Actual (observed)		
		+ ve (survived)	– ve (died)	
Through test (model)	+ ve (survived)	145	24	169
		TP	FP	
	– ve (died)	3	7	10
		FN	TN	
		148	31	179

bold (Table 4). The model explained 13.9% (Cox and Snell R^2) to 23.1% (Nagelkerke R^2) variance in survival and correctly classified 97.4% of survivors (Table 5).

However, only three variables (age, glycaemic control of the patient and intra-orbital involvement) out of the eight independent variables were found to be significant predictor of the survival as outcome. The multiple regression showed that for a unit increase in age, the log of odds of survival decreased by 0.043. It was equivalent to an odds ratio of 0.958. Similarly, for a unit increase in HbA1c, the log of odds of survival decreased by 0.328 which was equivalent to an odds ratio of 0.721. The absence of intra-orbital involvement improved survival by 1.176 in terms of log of its odds and it was equivalent to an odds ratio of 3.241 (Table 4).

Discussion

Mucormycosis is an uncommon fungal infection seen mostly in immunocompromised hosts [6]. Diabetes Mellitus is one of the diseases that has frequently been associated with mucormycosis. The most common mode of infection in the ROCM type is by inhalation of the spores [7]. Mucormycosis is angio-invasive in nature and progresses by causing extensive thrombosis and tissue necrosis. India has about 65 million adults with Diabetes Mellitus [8]. In addition, the COVID-19 infection has been found to cause both immune suppression [9] and insulin resistance [10]. Following the publication of the RECOVERY trial [11] which demonstrated that early steroid administration in COVID-19 patients reduced the overall mortality, steroids gained popularity as an adjuvant in COVID-19 treatment. While a single causative factor for the spurt of cases of CAM has not been identified, pre-existing diabetes and immunosuppression worsened by excessive steroid use [12, 13] during the second wave could have been major factors responsible for CAM [14].

In our cohort, a statistically significant portion of the patients were male, hyperglycemics, diagnosed with COVID-19 and had received corticosteroid therapy. While

the male predilection was significant in our cohort, it seemed to reflect the gender predilection (65.39% male, 34.61% female) [15] and age distribution [16] of COVID-19 across the country (Fig. 1). Our demographics were similar to an 18 country analysis of CAM [17], where 77.5% of the patients were male, the mean age was 55 years, 92.5% had presented with a history of COVID-19 and 82.5% were diabetic. 75% of this patient population had also received systemic corticosteroids for the treatment of COVID. Surprisingly, several pre-COVID studies also reflected similar patient demographics. A meta-analysis of 600 reports of mucormycosis (851 patients) by Jeong et al. [18], reported that 63% of their population was male, median age was 50 years and 40% had diabetes—the most common systemic illness. 33% also had a history of systemic steroid usage which was deemed an independent risk factor for mucormycosis. Another pre-COVID review of 929 patients of mucormycosis by Roden et al. [19], found that the 65% of the patients were male and the mean age was 38.8 years. Diabetes (in 36% of the patients) was again the most common underlying condition. Lanternier et al. [20], also found diabetes as the most common comorbidity in ROCM (64% of the patients).

ROCM has a characteristic pattern of spread [21]. Following inhalation, spores germinate into hyphae in the sinuses, spreading via vascular and neuronal channels towards the orbit and cranium superiorly and maxilla inferiorly via foraminae. The bone, cartilage, nerves, perineural areas and meninges are frequently involved with the pterygopalatine fossa being the largest reservoir [22]. Extension to the orbit occurs by contiguous spread via the posterior ethmoids or the roof of maxillary antrum. Infection spreads from the sphenoids to the cavernous sinus resulting in cranial nerve palsies [23, 24], proptosis [23], ophthalmoplegia [23] and cavernous sinus thrombosis [24]. Infection can extend from the orbit into the brain via a retro-orbital/middle cranial fossa route. Intracranial extension can also occur by fungal emboli and intravascular spread [22]. Hypoesthesia/paraesthesia along the V cranial nerve involvement is also well documented [24]. In our series, infraorbital paresthesia was present in 14.85% of the patients.

Clinically, Smith and Kritchner reported that the most common presentation was facial pain and swelling [25]. This was also the most common complaint in our patient population. Though reports speak of crusted nasal turbinates on nasal endoscopy [26], we found this in only 39.28% of our patients. Adjacent bone erosion occurs by the contiguous spread of infection from the sinuses. Early maxillary involvement is apparent by several intraoral signs. These signs range include purpling of the hard palate mucosa, loss of palatal rugae, pustules and boggy tissue. Advanced disease presents as maxillary mobility, tooth mobility, large mucosal erosions and exposed bone.

Radiologically, CT is a cost-effective method to detect bone erosions and a contrast enhanced MRI is useful in detecting intracranial extension, perineural spread and subtle fat stranding in the facial, orbital and retroantral regions [27]. In a study of the radiographic features of 43 patients with mucormycosis, Therakathu et al. [27] found that 79% of their population had unilateral sinus involvement and only 2% presented with pansinusitis. They also found that majority of the bony erosions were in the orbital wall. In contrast, we found that pansinusitis was the most common finding in our cohort (47.48% of the patients) and maxilla was the most commonly involved bony structure. We also encountered a lower percentage of facial cellulitis, orbital cellulitis and retroantral fat stranding. Though radiographic findings were crucial to our treatment plan, we found a significant lag between the imaging and the clinical presentation in determining the actual disease extent. This was particularly stark in patients who required maxillectomy, where 94.5% demonstrated clinical signs of disease but only 8.93% had maxillary erosion on the CT and only 3.35% had marrow edema on the MRI. Though periantral edema is a purported early radiologic indicator of aggressive disease which heralds impending bone destruction [28], it may actually represent ongoing early bone disease.

In our cohort, initial cases with minimal clinical signs of bone involvement were treated with EESD, conservative bone debridement and amphotericin therapy. However, these patients quickly progressed to have overt bone necrosis and we changed course to swiftly and aggressively treat bony disease. Similar to other reports [27], we found multiple patients with early bony involvement. Apart from the maxilla and orbit, 5.02% patients had early skull-base osteomyelitis, 5.02% patients had cribriform erosions and 3.35% patients had zygoma involvement. Despite treatment, several of our patients developed late osteonecrosis. All but one were free of fungal growth in the debrided tissue, indicating that the process was more likely avascular necrosis than residual fungal disease.

Exenterations in our population were reserved for patients with no vision, overt orbital disease on imaging, and existing or imminent intracranial spread. These signs were categorised as severe by Shah et al. [23] in their scoring system. Patients with partial vision loss with continued light perception were treated with orbital decompression. Despite this, disease in some patients progressed to need secondary orbital exenteration. Thrombosis and necrotic tissue reduce the bioavailability of systemic antifungals hence aggressive surgical debridement is vital [13, 24]. In the current logistic regression model, intraorbital disease was found to be one of the variables which adversely affected the mortality. A study of 292 patients by Hangrove et al. [24] showed that patients with orbital mucormycosis had a greater chance of survival when exenterations were performed.

A total of 37 patients (18.31%) were deceased as of December 2021. 24 of the 37 patients died within the first 4 weeks. Hoenigl et al. [17] reported a mortality of 37.3% in ROCM CAM (59.1% in cerebral vs. 24.3% without cerebral involvement). Jeong et al. [18] found a 42% mortality rate (75% in patients with sino-cerebral presentation and death rate of 33% in patients with sinus disease alone). Lantineir et al. [20] found that death occurred in 56% of patients with cerebral involvement and in 20% with sino-orbital forms, and no mortality in isolated sinusitis. Unlike these studies, our logistic regression model found that the age, HbA1c levels and intraorbital disease were positive predictors for mortality. The other factor affecting mortality is antifungal therapy. Though the DEFEAT Mucor trial [20] showed that dosage had no correlation to mortality, several reports suggested that survival is better in patients with surgical and medical therapy [12, 18, 19, 29]. Antifungal therapy was not used as a predictor in our study as Posaconazole was occasionally used as the primary antifungal agent.

Conclusion

In analysing this series, we have found that prompt diagnosis, appropriate surgery to reduce fungal burden and antifungal therapy may significantly help reduce mortality. The clinical and radiological disease assessment and a multidisciplinary approach is imperative for effective treatment planning. In spite of the inherent pitfalls of a retrospective analysis, we have a full range of clinical features to early outcomes of a relatively large cohort of patients. CAM perhaps is a distinct variant of mucormycosis with specific predictive factors, which, when treated appropriately by a multidisciplinary team, will result in improved outcomes.

Acknowledgements Dr. Athira for the illustration titled Fig. 3, Dr. Anand from Medall Labs for technical inputs regarding radiology, Dr. Asha Prabhakar (pathologist), Dr. Kishan A, Dr. Sumit Gaur, Intensivists, Anaesthetists, Physicians, Neurologists, other medical, nursing and allied staff involved in patient care

Funding The authors have not received any funding for the study.

Declarations

Conflict of interest The authors do not have any conflict of interest to declare.

References

1. Chakrabarti A, Singh R (2014) Mucormycosis in India: unique features. *Mycoses* 57:85–90

2. Chakrabarti A, Singh R (2011) The emerging epidemiology of mould infections in developing countries. *Curr Opin Infect Dis* 24(6):521–526. <https://doi.org/10.1097/QCO.0b013e32834ab21e>
3. Moorthy A, Gaikwad R, Krishna S et al (2021) SARS-CoV-2, uncontrolled diabetes and corticosteroids-an unholy trinity in invasive fungal infections of the maxillofacial region? A retrospective, multi-centric Analysis [published online ahead of print, 2021 Mar 6]. *J Maxillofac Oral Surg*. 20(3):1–8. <https://doi.org/10.1007/s12663-021-01532-1>
4. Raut A, Huy NT (2021) Rising incidence of mucormycosis in patients with COVID-19: another challenge for India amidst the second wave? *Lancet Respir Med* 9(8):e77. [https://doi.org/10.1016/S2213-2600\(21\)00265-4](https://doi.org/10.1016/S2213-2600(21)00265-4)
5. Rocha ICN, Hasan MM, Goyal S et al (2021) COVID-19 and mucormycosis syndemic: double health threat to a collapsing healthcare system in India. *Trop Med Int Health* 26(9):1016–1018. <https://doi.org/10.1111/tmi.13641>
6. Singh AK, Singh R, Joshi SR, Misra A (2021) Mucormycosis in COVID-19: a systematic review of cases reported worldwide and in India. *Diabetes Metab Syndr* 15(4):102146. <https://doi.org/10.1016/j.dsx.2021.05.019>
7. Petrikos G, Skiada A, Lortholary O, Roilides E, Walsh TJ, Kontoyiannis DP (2012) Epidemiology and clinical manifestations of mucormycosis. *Clin Infect Dis* 54(Suppl 1):S23–S34. <https://doi.org/10.1093/cid/cir866>
8. India State-Level Disease Burden Initiative Diabetes Collaborators (2018) The increasing burden of diabetes and variations among the states of India: the Global Burden of Disease Study 1990–2016. *Lancet Glob Health* 6(12):e1352–e1362. [https://doi.org/10.1016/S2214-109X\(18\)30387-5](https://doi.org/10.1016/S2214-109X(18)30387-5)
9. Tian W, Zhang N, Jin R et al (2020) Immune suppression in the early stage of COVID-19 disease. *Nat Commun* 11(1):5859. <https://doi.org/10.1038/s41467-020-19706-9>
10. Kothandaraman N, Rengaraj A, Xue B et al (2021) COVID-19 endocrinopathy with hindsight from SARS. *Am J Physiol Endocrinol Metab* 320(1):E139–E150. <https://doi.org/10.1152/ajpendo.00480.2020>
11. RECOVERY Collaborative Group, Horby P, Lim WS et al (2021) Dexamethasone in hospitalized patients with Covid-19. *N Engl J Med* 384(8):693–704. <https://doi.org/10.1056/NEJMoa2021436>
12. Ravindra K, Ahlawat A (2021) Five probable factors responsible for the COVID-associated mucormycosis outbreak in India. *Int J Infect Dis* 112:278–280. <https://doi.org/10.1016/j.ijid.2021.09.057>
13. Yasmin F, Najeem H, Naeem A et al (2021) COVID-19 associated mucormycosis: a systematic review from diagnostic challenges to management. *Diseases* 9(4):65. <https://doi.org/10.3390/diseases9040065>
14. Al-Tawfiq JA, Alhumaid S, Alshukairi AN et al (2021) COVID-19 and mucormycosis superinfection: the perfect storm. *Infection* 49(5):833–853. <https://doi.org/10.1007/s15010-021-01670-1>
15. Kushwaha S, Khanna P, Rajagopal V, Kiran T (2021) Biological attributes of age and gender variations in Indian COVID-19 cases: a retrospective data analysis. *Clin Epidemiol Glob Health* 11:100788. <https://doi.org/10.1016/j.cegh.2021.100788>
16. Department of medical health and family welfare. Government of Uttarakhand. [https://health.uk.gov.in/pages/view/155-age-wise-covid-19-cases-\(page-04\)](https://health.uk.gov.in/pages/view/155-age-wise-covid-19-cases-(page-04)). Accessed 21 Nov 2021
17. Hoenigl M, Seidel D, Carvalho A, Rudramurthy SM, Arastehfar A, Gangneux JP, Nasir N, Bonifaz A, Araiza J, Klimko N, Seris A. The emergence of COVID-19 associated mucormycosis: analysis of cases from 18 Countries
18. Jeong W, Keighley C, Wolfe R et al (2019) The epidemiology and clinical manifestations of mucormycosis: a systematic review and meta-analysis of case reports. *Clin Microbiol Infect* 25(1):26–34. <https://doi.org/10.1016/j.cmi.2018.07.011>
19. Roden MM, Zaoutis TE, Buchanan WL et al (2005) Epidemiology and outcome of zygomycosis: a review of 929 reported cases. *Clin Infect Dis* 41(5):634–653. <https://doi.org/10.1086/432579>
20. Lanternier F, Dannaoui E, Morizot G et al (2012) A global analysis of mucormycosis in France: the RetroZygo study (2005–2007). *Clin Infect Dis* 54(Suppl 1):S35–S43. <https://doi.org/10.1093/cid/cir880>
21. McLean FM, Ginsberg LE, Stanton CA (1996) Perineural spread of rhinocerebral mucormycosis. *AJNR Am J Neuroradiol* 17(1):114–116
22. Hosseini SM, Borghei P (2005) Rhinocerebral mucormycosis: pathways of spread. *Eur Arch Otorhinolaryngol* 262(11):932–938. <https://doi.org/10.1007/s00405-005-0919-0>
23. Shah K, Dave V, Bradoo R, Shinde C, Prathibha M (2019) Orbital exenteration in rhino-orbito-cerebral mucormycosis: a prospective analytical study with scoring system. *Indian J Otolaryngol Head Neck Surg* 71(2):259–265. <https://doi.org/10.1007/s12070-018-1293-8>
24. Hargrove RN, Wesley RE, Klippenstein KA, Fleming JC, Haik BG (2006) Indications for orbital exenteration in mucormycosis. *Ophthalmic Plast Reconstr Surg* 22(4):286–291. <https://doi.org/10.1097/01.iop.0000225418.50441.ee>
25. Smith HW, Kirchner JA (1958) Cerebral mucormycosis; a report of three cases. *AMA Arch Otolaryngol* 68(6):715–726. <https://doi.org/10.1001/archotol.1958.00730020739010>
26. Singh VP, Bansal C, Kaintura M (2019) Sinonasal mucormycosis: A to Z. *Indian J Otolaryngol Head Neck Surg* 71(Suppl 3):1962–1971. <https://doi.org/10.1007/s12070-018-1384-6>
27. Therakathu J, Prabhu S, Irodi A, Sudhakar SV, Yadav VK, Rupa V (2018) Imaging features of rhinocerebral mucormycosis: a study of 43 patients. *Egypt J Radiol Nuclear Med* 49(2):447–452
28. Silverman CS, Mancuso AA (1998) Periantral soft-tissue infiltration and its relevance to the early detection of invasive fungal sinusitis: CT and MR findings. *AJNR Am J Neuroradiol* 19(2):321–325
29. Prakash H, Chakrabarti A (2021) Epidemiology of mucormycosis in India. *Microorganisms*. 9(3):523. <https://doi.org/10.3390/microorganisms9030523>

Publisher's Note Springer Nature remains neutral with regard to jurisdictional claims in published maps and institutional affiliations.