

# Bulky granulomatous disease resulting in constrictive tuberculous pericarditis requiring pericardiectomy: a case report

Sumita Barua <sup>1,2\*</sup>, Bernadette Phua <sup>1</sup>, Yishay Orr<sup>3</sup>, and Michael Skinner<sup>1</sup>

<sup>1</sup>Department of Cardiology, Westmead Hospital, Hawkesbury Road, Westmead NSW 2145, Australia; <sup>2</sup>Faculty of Medicine, University of New South Wales, UNSW Sydney, NSW 2052, Australia; and <sup>3</sup>Department of Cardiothoracics, Westmead Hospital, Hawkesbury Road, Westmead NSW 2145, Australia

Received 20 February 2020; first decision 17 March 2020; accepted 5 June 2020; online publish-ahead-of-print 27 September 2020

## Background

We present a 23-year-old Nepalese migrant with mycobacterial tuberculosis (TB) pericarditis manifesting as effusive constrictive disease and subsequent rapid progression to constrictive pericarditis resulting from bulky granulomatous disease.

## Case summary

Following initial presumptive diagnosis of TB pericarditis based on presence of moderate pericardial effusion and positive polymerase chain reaction on concurrent pleural aspirate, the patient was managed with standard empiric therapy. Despite treatment, he developed progressive heart failure with New York Heart Association (NYHA) class III symptoms and had confirmation of constrictive physiology on simultaneous left and right heart catheterization. He underwent pericardiectomy 4 months after his initial diagnosis, with debridement of large necrotizing granulomas and an associated immediate improvement clinical improvement. He remains well at 6-month follow-up with no residual heart failure symptoms off diuretic therapy.

## Discussion

Tuberculous pericarditis accounts for 1–2% of presentations with TB infection, with progression to constrictive pericarditis in between 17 and 40% of cases. To date, pericardiectomy remains mainstay of treatment for constriction, albeit with high perioperative risk. In combination with anti-tuberculous therapy, prednisone and pericardiocentesis may reduce risk of progression to constriction, however, neither have shown mortality benefit. Our patient continued to progress, despite medical therapy and proceeded to pericardiectomy only 4 months after his initial diagnosis, with rapid improvement in symptoms, demonstrating the importance of close monitoring and revision of management strategy in these patients.

## Keywords

Case report • Tuberculous pericarditis • Constrictive pericarditis • Pericardiectomy • Granulomatous disease

\*Corresponding author. Tel: +61451667247, Email: sbarua88@gmail.com

Handling Editor: Domenico D'Amario

Peer-reviewers: Erik Holy and Constantinos Bakogiannis

Compliance Editor: Stefan Simovic

Supplementary Material Editor: Peregrine Green

© The Author(s) 2020. Published by Oxford University Press on behalf of the European Society of Cardiology.

This is an Open Access article distributed under the terms of the Creative Commons Attribution Non-Commercial License (<http://creativecommons.org/licenses/by-nc/4.0/>), which permits non-commercial re-use, distribution, and reproduction in any medium, provided the original work is properly cited. For commercial re-use, please contact [journals.permissions@oup.com](mailto:journals.permissions@oup.com)

## Learning points

- Multidisciplinary involvement is required for patients with tuberculous pericarditis to monitor response to therapy and assess for interval development of constriction.
- Multiple diagnostic modalities, both non-invasive and invasive, with serial evaluation may be required to identify progression to constrictive pericarditis in this setting.
- Constrictive pericarditis, particularly with bulky granulomatous disease and symptoms of heart failure, requires pericardiectomy for treatment.

## Introduction

Mycobacterial *tuberculosis* (TB) infection remains rare in the Australian population, with an estimated incidence of 6.8 per 100 000 population.<sup>1</sup> Tuberculous pericarditis accounts for 1–2% of presentations with TB infection,<sup>2</sup> progressing to constrictive pericarditis in between 17% and 40% of cases.<sup>3</sup> We present a case of effusive constrictive TB pericarditis as the first manifestation of TB infection in a 23-year-old Nepalese migrant, with rapid progression to constrictive pericarditis due to bulky granulomas requiring pericardiectomy.

## Timeline

September 2018	First presentation. Newly diagnosed moderate pericardial and pleural effusion. Transthoracic echocardiogram is suggestive of effusive constrictive disease. Pleural aspirate Mycobacterial tuberculosis (TB) polymerase chain reaction (PCR) positive. Commenced on standard anti-TB therapy and prednisone.
October 2018	Discharged from hospital, however, rapid progression to New York Heart Association class III symptoms.
November 2018–January 2019	Readmission with bilateral pleural effusions. Pleural biopsy TB PCR positive. Refractory pleural effusions with prolonged drain requirements.
January 2019	Simultaneous left and right heart catheterization consistent with constriction. Pericardial thickening without calcification on computed-tomography chest. Proceeded to pericardiectomy.
February 2019	All diuretics ceased. Discharged from hospital.
May 2019	Anti-TB therapy ceased following completion of 36-week course.
June 2019	No residual heart failure symptoms at follow-up

## Case presentation

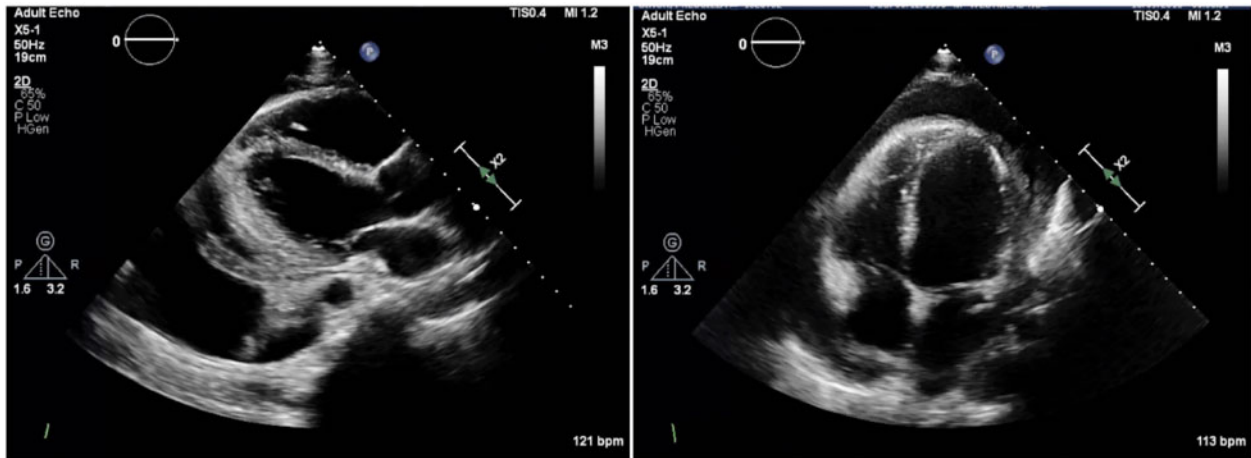
The patient is a 23-year-old university student, recently emigrated from Nepal, with no known medical history. His sister was treated for presumed TB lymphadenitis 10 years prior. He initially presented

in September 2018 with a 1-month history of pleuritic chest pain, dry cough, fevers, and night sweats. On clinical examination, he was found to be tachycardic, with reduced air entry at both lung bases. There were no other clinical signs of tamponade.

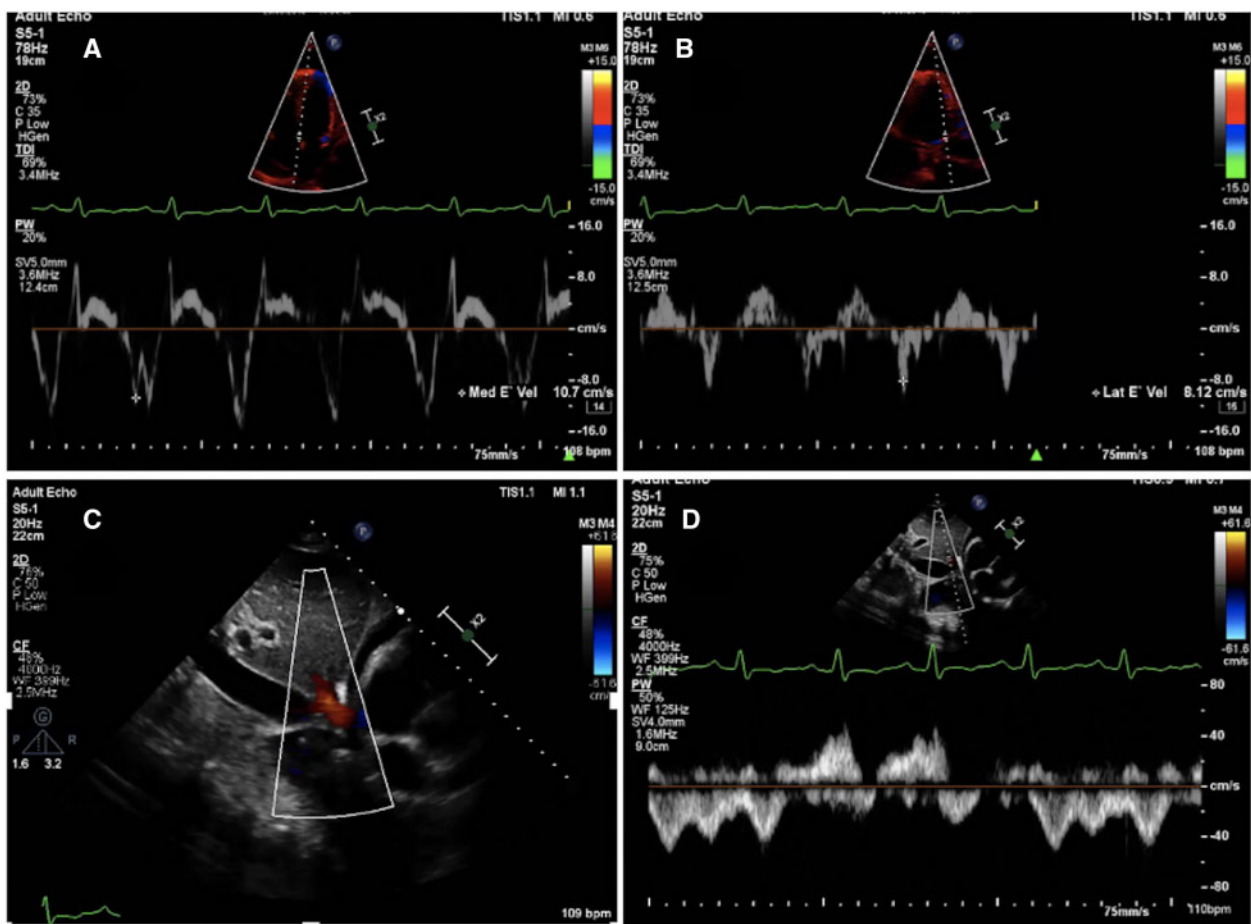
Electrocardiogram demonstrated sinus tachycardia with no electrical alternans. Serology showed an elevated C-reactive protein (52 mg/L), and D-dimer (>10 mg/L). All other laboratory values were within normal range. Computed tomography (CT) chest imaging demonstrated pleural and pericardial effusions and subsequent targeted transthoracic echocardiogram (TTE) confirmed a moderate-to-large global pericardial effusion up to 20 mm in maximal dimension. The lateral left ventricular wall appeared tethered to the visceral pericardium with echodense fibrinous material throughout the pericardial space (Figure 1). Respiratory inflow variations were significant at 42% for mitral and 67% for tricuspid valves, respectively. There was paradoxical interventricular septal motion despite absence of right atrial and right ventricular collapse (Video 1). The inferior vena cava (IVC) was dilated with only 30% variation on inspiration. There was expiratory hepatic vein flow reversal and tissue annulus reversus with septal mitral annular E' 11 cm compared with lateral mitral annular E' 7 cm, suggestive effusive constriction (Figure 2). Overall left ventricular function was normal, and high sensitivity troponins were negative, suggesting no myocardial involvement. Induced sputum aspirates were negative, however, diagnostic pleurocentesis demonstrated an exudative effusion (pleural to serum protein ratio 0.6) with a positive TB polymerase chain reaction (PCR) result.

He was commenced on empiric therapy for effusive constrictive TB pericarditis, with once daily Rifampicin 600 mg, Isoniazid 300 mg, Ethambutol 800 mg, Pyrazinamide 1.5 g, and weaning course of Prednisone. He was additionally noted to have a CD4 lymphopaenia (CD4 count 137 cells/mm<sup>3</sup>) despite negative Human Immunodeficiency Virus (HIV) serology and commenced on Sulfamethoxazole/Trimethoprim 400/80 mg daily prophylaxis.

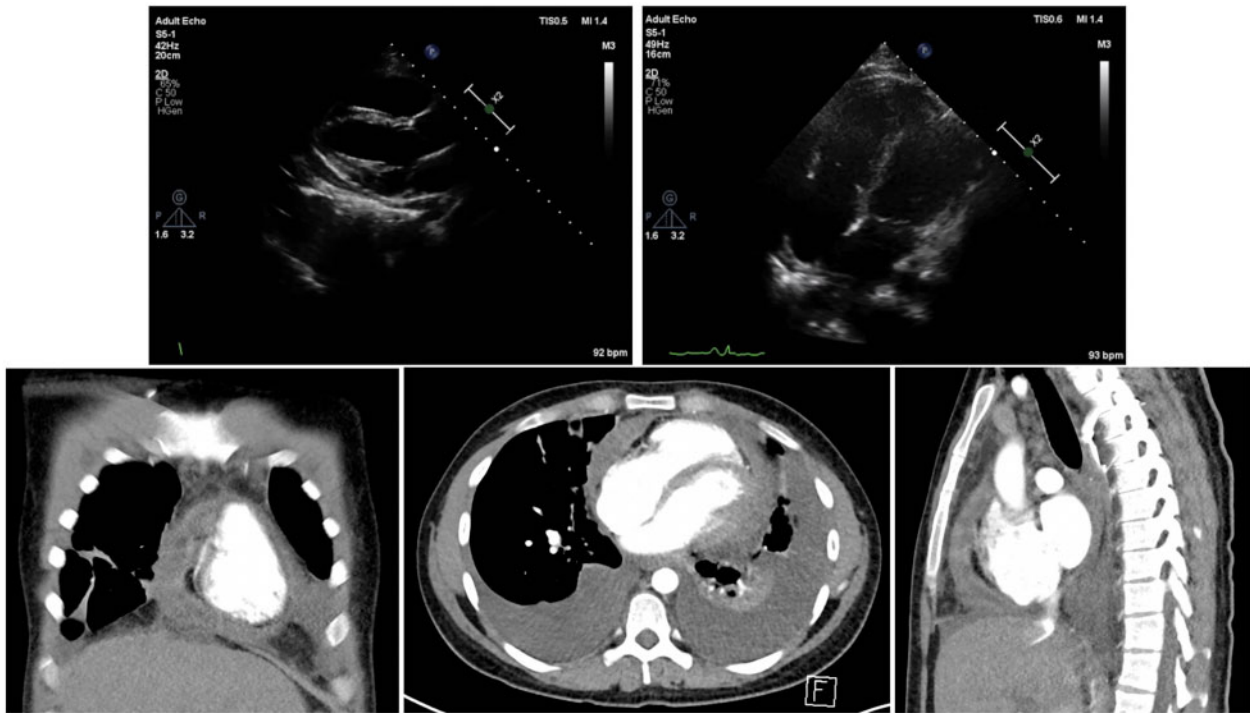
Over the subsequent 1 month, he developed New York Heart Association (NYHA) class III symptoms with an exertional tolerance of 5 m, despite continuing to work as a cleaner 6 days per week prompting re-admission in November 2018. Prednisone was ceased and TB treatment rationalized as per current guidelines. He underwent left-sided video-assisted thoracoscopic surgery. Inspected pleura showed small nodularities throughout, with positive biopsy for TB on PCR. He had continuously high pleural drain outputs bilaterally for almost 2 months prior to both drains being removed. Unfortunately, he was readmitted 3 days following discharge in January 2019 with reaccumulation of pleural effusions and dependent lower limb oedema refractory to escalating doses of furosemide and



**Figure 1** Parasternal long axis and apical four chamber images on transthoracic echocardiogram demonstrating moderate-to-large pericardial effusion, with basal lateral wall left ventricular wall adherent to visceral pericardium. Scale 23.11 cm × 8.57 cm.



**Figure 2** Mitral annulus reversus of tissue Doppler velocities (A and B). Hepatic vein flow reversal with expiration (C and D). Scale 16.58 cm × 12.24 cm.



**Figure 3** Progress transthoracic echocardiogram showing resolution of pericardial fluid and replacement with heterogenous echodense material, degradation of imaging quality due to pericardial thickening, and increased adherence of ventricular cavities to visceral pericardium (A and B). Computed tomographic images showing air-filled cavities within pericardial space and pericardial thickening (C–E). Scale 38.63 cm × 21.98 cm.

spironolactone (40 mg BD intravenous and 25 mg oral daily, respectively).

Repeat TTE showed marked degradation of acoustic windows, presumed due to pericardial thickening. The pericardial effusion had resolved, replaced by heterogenous echodense material within the pericardial space. The entire left ventricular mass appeared adherent to the pericardium (Figure 3). Marked septal bounce was seen, and the IVC remained dilated without respiratory variation. CT chest showed gross pericardial thickening without calcification. Interestingly, there were air-filled cavities present within the pericardial space, which in conjunction with the heterogenous echodense material seen on TTE suggests possible necrotic granulomas (Figure 3).

The patient proceeded to simultaneous left and right heart catheterization, which demonstrated diastolic equalization of pressures with diastolic ‘dip-and-plateau’, and discordance of ventricular pressures during the respiratory cycle confirming presence of constrictive physiology (Figure 4).

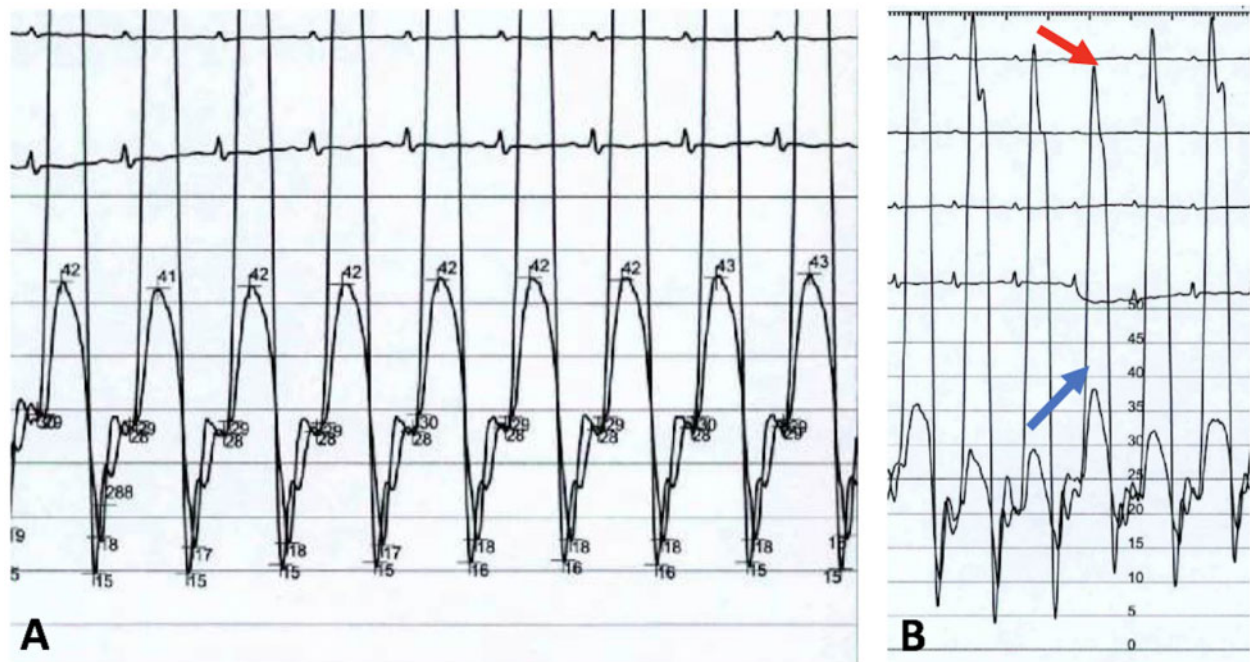
Following multidisciplinary discussion of his progression despite corticosteroids and anti-tuberculous treatment, he proceeded to pericardiectomy. There was clear constriction of the heart, with ventricular cavities much more filled once the pericardium was excised. The pericardium was grossly thickened. Additionally, there were several caseating abscess cavities, the largest measuring 4 cm in its maximal dimension (Figure 5). These were all debrided and all involved pericardium excised with instantaneous improvement in central

venous pressures from 30 cm at the beginning to 16 cm at the end of the case. The patient was extubated that evening and subsequently discharged 2 weeks later off all diuretic therapy. He has now completed his 36-week course of anti-tuberculous therapy and remains well at follow-up to 6 months. He has no residual heart failure symptoms, has resumed his studies, and is seeking employment as a nursing assistant.

## Discussion

For established TB constrictive pericarditis, pericardiectomy remains the mainstay of treatment, albeit with high perioperative risk. In a case series of 110 patients with presumed or confirmed TB constriction, 22% of cases had myocardial wall or major vessel injury, 66% had low-output cardiac failure in the post-operative period, and 14% did not survive.<sup>4</sup> Conversely, in those who did survive, there was significant improvement in NYHA class symptoms, with most patients shifting from Class II–III symptoms pre-operatively to Class I symptoms post-operatively.<sup>4</sup>

In view of the high perioperative morbidity and mortality associated with pericardiectomy, less invasive therapies have been sought to reduce the risk of progression to constrictive pericarditis in these patients. Prednisone, combined with anti-tuberculous therapy, is the most commonly used first line therapy for tuberculous pericarditis. The largest trial of its use to date, the IMPI trial, showed no significant difference in the primary outcome, a composite of death, cardiac



**Figure 4** (A) Diastolic equalization of right and left ventricular pressures with 'dip-and-plateau' morphology. (B) Discordance in ventricular pressures with respiration. Scale 19.05 cm × 10.23 cm.

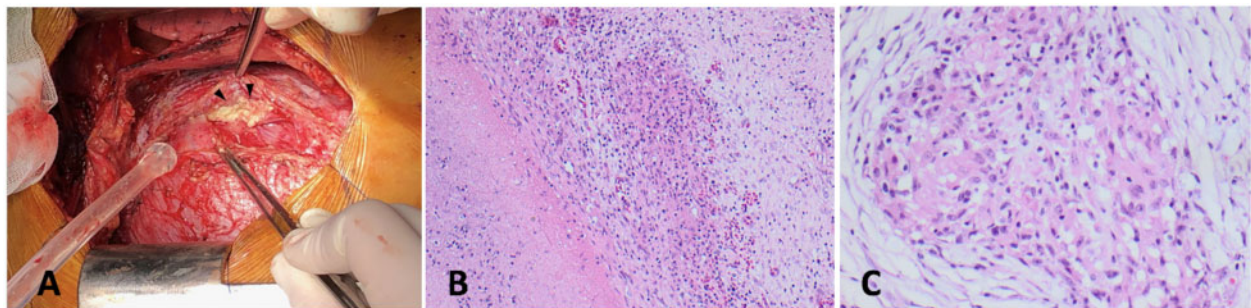
tamponade, and constriction, with prednisone use compared to placebo. There was however a significant difference in progression to constriction, with 7.8% following prednisone compared with 4.4% following placebo, as well as repeat hospitalization with 20.7% following prednisone and 25.2% following placebo.<sup>5</sup>

Intradermal injection of *Mycobacterium indicus pranii*, also evaluated in the IMPI trial, did not show reduction in the composite of death, cardiac tamponade, and constriction, nor a reduction in progression to constriction.<sup>5</sup> The use of colchicine in a subset of patients with concomitant HIV infection and TB pericarditis did not show improvement in development of constriction.<sup>6</sup> Interestingly, pericardiocentesis appeared to reduce the risk of progression to constriction in this small group. This finding was supported by a series of 162

patients undergoing pericardiocentesis for pericardial TB, of whom 11 went onto to further pericardial surgery, although only 1 was suspected to have pericardial constriction.<sup>7</sup>

Contemporary observational studies have shown best results with anti-tuberculous and prednisone combined with pericardiocentesis in terms of progression to constriction, with 93% in one series showing no effusion or thickening, or <1 cm effusion with some pericardial thickening on CT following this treatment regime.<sup>8</sup>

Our patient had progressive heart failure related to constrictive pericarditis, despite medical therapy and proceeded to pericardiectomy 4 months after his initial diagnosis. This was associated with rapid improvement in symptoms, demonstrating the importance of close monitoring and revision of management strategy in these patients. This case



**Figure 5** (A) Photo taken at the time of surgery demonstrating high vascular pericardium with arrowheads showing unroofed caseating granuloma. (B) Haematoxylin and Eosin (H&E) stain (100×) Granuloma with dirty necrosis (bottom left) and palisading histiocytes. (C) H&E (200×) Well formed epithelioid granuloma. Scale 23.6 cm × 5.89 cm. Haematoxylin and Eosin (H&E) stain

was unique given large necrotizing granulomas, which were difficult to appreciate on imaging, as TTE image quality is often degraded due to pericardial thickening, with limited pericardial tissue characterization on CT imaging. These granulomas were unlikely to resolve with medical therapy alone and in themselves contributed to constrictive physiology due to their mechanical compression on the cardiac chambers, again highlighting the importance of multimodality assessment of the patient with concerns of TB-related constrictive pericarditis.

## Lead author biography



Dr. Sumita Barua is a cardiologist having recently completed cardiology advanced training at Westmead Hospital. Her interests include coronary intervention and advanced heart failure therapies.

## Supplementary material

Supplementary material is available at *European Heart Journal - Case Reports* online.

## Acknowledgements

The authors would like to express their appreciation to Dr Jen Kok for giving permission to present this case and his ongoing care of the patient, as well as to Dr Winny Varikatt for assistance with the histopathology slides.

**Slide sets:** A fully edited slide set detailing this case and suitable for local presentation is available online as [Supplementary data](#).

**Consent:** The authors confirm that written consent for submission and publication of this case report including images and associated text has been obtained from the patient in line with COPE guidance.

**Conflict of interest:** none declared.

## References

1. World Health Organisation. TB burden estimates and country-reported TB data. [https://worldhealthorg.shinyapps.io/tb\\_profiles/?\\_inputs\\_&lan=%22EN%22&iso2=%22AU%22&main\\_tabs=%22est\\_tab%22](https://worldhealthorg.shinyapps.io/tb_profiles/?_inputs_&lan=%22EN%22&iso2=%22AU%22&main_tabs=%22est_tab%22) (30 June 2020).
2. Mayosi BM, Burgess LJ, Doubell AF. Tuberculous pericarditis. *Circulation* 2005;**112**:3608–3616.
3. Syed FF, Mayosi BM. A modern approach to tuberculous pericarditis. *Prog Cardiovasc Dis* 2007;**50**:218–236.
4. Mutyaba AK, Balkaran S, Cloete R, Du Plessis N, Badri M, Brink J et al. Constrictive pericarditis requiring pericardiectomy at Groote Schuur Hospital, Cape Town, South Africa: causes and perioperative outcomes in the HIV era (1990–2012). *J Thorac Cardiovasc Surg* 2014;**148**:3058–3065.e1.
5. Mayosi BM, Ntsekhe M, Bosch J, Pandie S, Jung H, Gumedze F et al. Prednisolone and Mycobacterium indicus pranii in tuberculous pericarditis. *N Engl J Med* 2014;**371**:1121–1130.
6. Liebenberg JJ, Dold CJ, Olivier LR. A prospective investigation into the effect of colchicine on tuberculous pericarditis. *Cardiovasc J S Afr* 2016;**27**:350–355.
7. Reuter H, Burgess LJ, Louw VJ, Doubell AF. The management of tuberculous pericardial effusion: experience in 233 consecutive patients. *Cardiovasc J S Afr* 2007;**18**:20–25.
8. Li H, Liu FY, Li XL, Zhu L, Zhou H. Clinical observation on pericardiocentesis and glucocorticoid in the treatment of tuberculous pericarditis. *Eur Rev Med Pharmacol* 2016;**20**:1130–1134.