



The Overlap between Fibromyalgia Syndrome and Myotonia Congenita

Tai-Seung Nam^{a,b}

Seok-Yong Choi^c

Dong-Jin Park^d

Shin-Seok Lee^d

Young-Ok Kim^e

Myeong-Kyu Kim^a

^aDepartments of Neurology,

^bBiomedical Sciences,

^cRheumatology, and

^dPediatrics, Chonnam National University Medical School, Gwangju, Korea

^eDepartment of Neurology, Chonnam National University Hwasun Hospital, Hwasun, Korea

Background Fibromyalgia syndrome (FMS) is a complex disorder characterized by chronic widespread pain (CWP), multiple areas of tenderness, sleep disturbance, fatigue, and mood or cognitive dysfunction. Myotonia congenita (MC) is an inherited myopathic disorder that is caused by mutations in the gene encoding the skeletal muscle chloride channel, which can infrequently manifest as generalized muscle cramps or myalgia.

Case Report The first case was a 33-year-old woman who complained of CWP and chronic headache occurring during pregnancy, and the second case was a 37-year-old man with CWP and depression who suffered from cold-induced muscle cramps. These two patients were initially diagnosed with FMS by rheumatologists, based on CWP of longer than 3 months duration and mechanical tenderness in specific body regions. However, these two FMS patients were subsequently also diagnosed with MC.

Conclusions These two cases are the first report of an overlap of CWP between FMS and MC.

Key Words fibromyalgia, chronic pain, myotonia congenita.

INTRODUCTION

Fibromyalgia syndrome (FMS) is the most common cause of chronic widespread pain (CWP) in the musculoskeletal system, and is characterized by chronic pain lasting longer than 3 months and diffuse muscle pain, with the presence of ≥ 11 tender points in the absence of well-defined underlying organic disease.¹ The prevalence of FMS reported in the general population is 2–4.7%, with a female predominance.^{2,3}

Myotonia is a symptom of inherited or acquired neuromuscular disorders and arises from impaired relaxation after muscular contraction.⁴ Myotonia congenita (MC) is an inherited, rare myopathic disorder of sarcolemmal hyperexcitability caused by mutations in the gene encoding the chloride ion channel (*CLCN1*) on the human skeletal muscle membrane, and is divided into autosomal-dominant myotonia (ADM) and recessive generalized myotonia (RGM).⁴ Patients with MC may often complain of painful muscle cramps or myalgia as well as transient muscle weakness following myotonic stiffness.^{4,5} Myotonic muscle stiffness and pain in MC may be temporarily worsened by emotional stress, cold exposure, sleep disturbance, dietary habit, excessive physical activity, and pregnancy.^{4,6}

Myotonia congenita can be clinically suspected by taking a detailed history from the patient and by performing needle electromyography (EMG), and can be confirmed genetically by DNA sequence analysis of *CLCN1*.⁴ In general, the symptoms and signs of MC may be unfamiliar to many clinicians, and it may thus be frequently overlooked or be attributed to other medical conditions. We describe herein two patients with geni-

Received June 26, 2013

Revised October 21, 2013

Accepted October 24, 2013

Correspondence

Myeong-Kyu Kim, MD, PhD
Department of Neurology,
Chonnam National University
Medical School, 42 Jebong-ro,
Dong-gu, Gwangju 501-757, Korea

Tel +82-62-220-6161

Fax +82-62-236-0839

E-mail mkkim@jnu.ac.kr

© This is an Open Access article distributed under the terms of the Creative Commons Attribution Non-Commercial License (<http://creativecommons.org/licenses/by-nc/3.0>) which permits unrestricted non-commercial use, distribution, and reproduction in any medium, provided the original work is properly cited.

cally confirmed MC who had been initially diagnosed with FMS.

CASE REPORT

Case 1

A 33-year-old woman with a history of FMS lasting more than 1 year was referred to our neurology clinic for the management of chronic headache and myalgia, which had initially developed during pregnancy at the age of 31 years. She had been treated with an antidepressant (duloxetine) and antiepileptic (gabapentin) for FMS, which was diagnosed on the basis of CWP lasting at least 3 months in the absence of underlying rheumatic diseases at the age of 32 years, according to the new diagnostic criteria for FMS. Her scores for widespread pain index, symptom severity, and the Fibromyalgia Impact Questionnaire (FIQ) were 10, 7, and 50.24 points, respectively. She also had 11 positive mechanical tender points at that time. Magnetic resonance imaging of the brain and cervical spine for evaluation of the chronic headache produced unremarkable findings, but she had a history of transient muscle weakness lasting for periods of no

more than several seconds in her legs when she suddenly had to walk at a pedestrian crossing or a bus stop. Moderate muscular hypertrophy was seen on a physical examination, but grip release- or percussion-myotonia, or warm-up phenomenon were not at the same time. However, needle EMG revealed myotonic discharges in some of the muscles studied, although she did not have physical evidence of myotonia.

Direct DNA sequence analysis of *CLCN1* revealed a heterozygous G-to-A substitution in exon 8 at position 950, causing an amino acid change at codon 317 (c.950G>A, p.Arg-317Gln) (Fig. 1A, B, and C). This previously identified mutation was found in her asymptomatic mother, but was not in her sister. However, other family members including asymptomatic father and grandparents did not agree to undergo mutation analyses. Further genetic studies were carried out to evaluate for other causes of myotonic syndrome, but no mutations were found in the genes encoding the sodium channel, voltage-gated, type IV, alpha subunit (*SCN4A*) or dystrophin myotonia-protein kinase (*DMPK*). She was diagnosed clinically with a case of RGM, because the family history was negative for clinical and electrical myotonia. However, the possibility of ADM could not be excluded due to a failure to

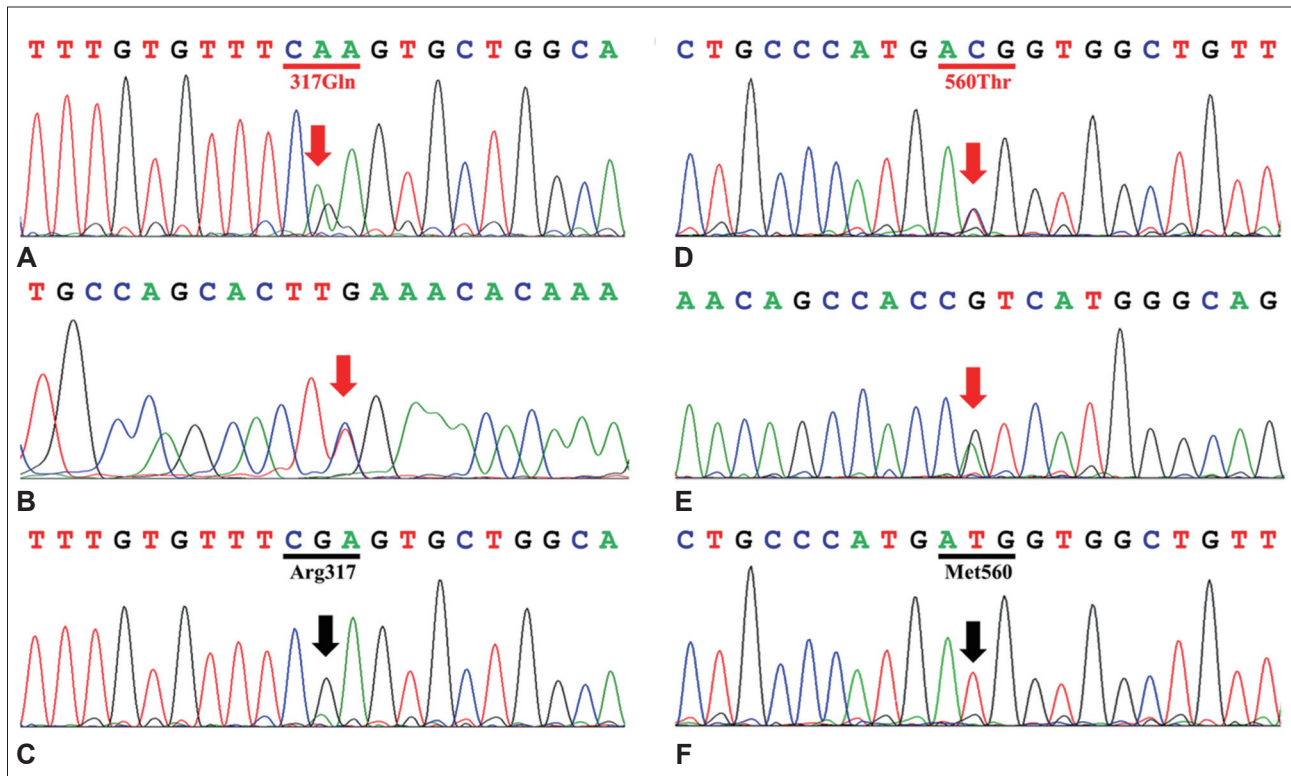


Fig. 1. Representative electropherograms of the mutations of *CLCN1* found in the patients and controls. The mutated sequences are indicated by red arrows, and black arrows indicate the wild-type sequences at the corresponding location. A and B: Forward and reverse complement electropherograms of case 1 reveal a heterozygous G-to-A substitution at position 950 (c.950G>A, p.Arg317Gln). D and E: Forward and reverse complement electropherograms of case 2 reveal a heterozygous T-to-C substitution at position 1679 (c.1679T>C, p.Met560Thr). C and F: Representative electropherograms of 200 normal South Korean controls.

identify a second mutation in her mutation analysis. Her headache as well as CWP improved after the administration of sodium channel blockers (lacosamide or carbamazepine) and amitriptyline.

Case 2

A 37-year-old man with a history of FMS and depression was referred to the neurology clinic for the evaluation of cold-induced muscle cramps. He suffered from CWP with multiple tender points on 14 of the 18 specific regions, and had experienced psychological symptoms including insomnia, fatigue, and depression from the age of 34 years. His FIQ score was 88.8 points, and he reported a pain score of 80 mm on a visual analogue scale at that time (range, 0–100 mm). A neurologic examination revealed normal motor, sensory, and deep tendon reflexes in both arms and legs, but cold-water testing aggravated the muscle stiffness and cramps in his forearm. Needle EMG for the evaluation of muscle cramps revealed the continued presence of provoked positive sharp waves lasting for up to several seconds, and waning-only myotonic discharges in a part of his leg muscles. A detailed examination of his medical history revealed that he suffered from transient muscle weakness in his arms and legs in childhood, but that these muscle symptoms had improved with age. His younger sister had a history of episodic muscle weakness, but his elder sister and parents had not.

Mutation analysis of *CLCN1* revealed a heterozygous mutation (c.1679T>C, p.Met560Thr) (Fig. 1D and E) that was not found in the asymptomatic mother and elder sister of the patient as well as in normal controls from South Korea (Fig. 1F). He was clinically diagnosed as a case of RGM with a single recessive mutation. However, the possibility of a sporadic MC or ADM could not be excluded, because mutational analyses for his father and symptomatic younger sister were not performed. Further, no additional study was carried out for identifying a second mutation such as exon deletions or duplications in *CLCN1*. The patient is still being treated with antiepileptic drugs (carbamazepine, pregabalin, and valproic acid), antidepressants (duloxetine and mirtazapine), mexiletine, and tramadol, but his physical and psychological symptoms have not been ameliorated.

DISCUSSION

The two cases presented herein, which were initially diagnosed as FMS clinically, were ultimately confirmed via genetic testing to be suffering from MC. It is believed that FMS is a multifactorial disease caused by interactions between genetic susceptibility and environmental factors,⁷ whereas MC is a monogenic

disease caused by mutations of a single gene (*CLCN1*).⁴ To date there have been no reports of FMS related to MC, and it has been demonstrated that MC typically presents with transient muscle weakness following myotonic stiffness, but not chronic muscle pain.⁵ Therefore, we initially considered that patients with MC may be simply misdiagnosed as having FMS, because the diagnosis of FMS is basically clinical without the evidence of laboratory abnormalities.

However, it is known that myotonic symptoms can sometimes vary with the situation, even within affected family members carrying the same mutation.⁴ Furthermore, non-dystrophic myotonias including MC or myotonic dystrophy type 2 (DM2) may atypically present with myotonic muscle stiffness and cramps,^{4,5,8,9} which might be associated with repeated firing of the muscle action potentials that induce the continuous muscle contraction.^{4,5} Götze et al.¹⁰ recently reported a family with FMS and hyperkalemic periodic paralysis accompanied by myotonia, but they did not conduct DNA sequence analysis of *SCN4A*. In addition, Auvinen et al.¹¹ reported finding DM2—which is caused by CCTG expansion in the gene encoding CCHC-type zinc finger, nucleic acid binding protein (*CNBP*) in 2 of the 63 patients with FMS. In this context, the possibility that MC may atypically present as CWP, which can be seen in FMS, cannot be excluded. The clinical symptoms experienced by the patient comprising case 2 in the present study actually changed from transient muscle weakness in his youth to CWP in adulthood.

It is known that pregnancy may worsen muscle symptoms in some patients with FMS or MC,^{12–14} which is consistent with the pregnancy-induced CWP and myotonia experienced by the patient comprising case 1. The patient comprising case 2 complained of cold-induced muscle pain, which may be explained by the pain sensitivity in FMS increasing in cold temperatures,^{15,16} or it may be attributable to MC worsening in a cold environment, similar to cold-induced paramyotonia congenita caused by a mutation in *SCN4A*.^{6,17} Our cases indicate that FMS and MC share similar factors that aggravate symptoms. Therefore, when a clinician first sees a patient with CWP, FMS may first be considered as a clinical diagnosis, but MC, which is relatively rare, may not. After all, MC could have been overlooked in our two cases if we had not examined the clinical history in detail or carried out needle EMG.

In conclusion, these cases represent the first report of an overlap of CWP between FMS and MC. The results of this study suggest that MC can be considered as the causative disease for FMS, given that MC can atypically present with chronic muscle pain similar to that seen in FMS. Further clinical and genetic studies are needed to explore their relationship.

Conflicts of Interest

The authors have no financial conflicts of interest.

Acknowledgements

Supported by Korea 21 R&D Project, Ministry of Health, Welfare & Family Affairs, Republic of Korea (A100402) and a grant (CRI13002-1) Chonnam National University Hospital Biomedical Research Institute.

We thank Jenna Mast for providing inspiration for the association between fibromyalgia and myotonia congenita, and Hee-Ju Kim for technical assistance in DNA sequence analysis.

REFERENCES

1. Wolfe F, Smythe HA, Yunus MB, Bennett RM, Bombardier C, Goldenberg DL, et al. The American College of Rheumatology 1990 Criteria for the Classification of Fibromyalgia. Report of the Multicenter Criteria Committee. *Arthritis Rheum* 1990;33:160-172.
2. Wolfe F, Ross K, Anderson J, Russell IJ, Hebert L. The prevalence and characteristics of fibromyalgia in the general population. *Arthritis Rheum* 1995;38:19-28.
3. Branco JC, Bannwarth B, Failde I, Abello Carbonell J, Blotman F, Spaeth M, et al. Prevalence of fibromyalgia: a survey in five European countries. *Semin Arthritis Rheum* 2010;39:448-453.
4. Amato AA, Russell JA. Nondystrophic myotonias and periodic paralysis. In: Amato AA, Russell JA, editors. *Neuromuscular Disorders*. New York: McGraw, 2008;655-680.
5. Lossin C, George AL Jr. Myotonia congenita. *Adv Genet* 2008;63:25-55.
6. Moon IS, Kim HS, Shin JH, Park YE, Park KH, Shin YB, et al. Novel CLCN1 mutations and clinical features of Korean patients with myotonia congenita. *J Korean Med Sci* 2009;24:1038-1044.
7. Becker RM, da Silva VK, Machado Fda S, dos Santos AF, Meireles DC, Mergener M, et al. Association between environmental quality, stress and APOE gene variation in fibromyalgia susceptibility determination. *Rev Bras Reumatol* 2010;50:617-624.
8. Day JW, Ricker K, Jacobsen JF, Rasmussen LJ, Dick KA, Kress W, et al. Myotonic dystrophy type 2: molecular, diagnostic and clinical spectrum. *Neurology* 2003;60:657-664.
9. Udd B, Meola G, Krahe R, Thornton C, Ranum LP, Bassez G, et al. 140th ENMC International Workshop: Myotonic Dystrophy DM2/PROMM and other myotonic dystrophies with guidelines on management. *Neuromuscul Disord* 2006;16:403-413.
10. Götze FR, Thid S, Kyllerman M. Fibromyalgia in hyperkalemic periodic paralysis. *Scand J Rheumatol* 1998;27:383-384.
11. Auvinen S, Suominen T, Hannonen P, Bachinski LL, Krahe R, Udd B. Myotonic dystrophy type 2 found in two of sixty-three persons diagnosed as having fibromyalgia. *Arthritis Rheum* 2008;58:3627-3631.
12. Saad S, Many A, Jacob G, Ablin JN. High prevalence of fibromyalgia symptoms among healthy full-term pregnant women. *Rheumatol Int* 2013;33:1555-1560.
13. Schwartz IL, Dingfelder JR, O'Tuama L, Swift M. Recessive congenital myotonia and pregnancy. *Int J Gynaecol Obstet* 1979;17:194-196.
14. Basu A, Nishanth P, Ifaturoti O. Pregnancy in women with myotonia congenita. *Int J Gynaecol Obstet* 2009;106:62-63.
15. Berglund B, Harju EL, Kosek E, Lindblom U. Quantitative and qualitative perceptual analysis of cold dysesthesia and hyperalgesia in fibromyalgia. *Pain* 2002;96:177-187.
16. Smith BW, Tooley EM, Montague EQ, Robinson AE, Cospser CJ, Mullins PG. Habituation and sensitization to heat and cold pain in women with fibromyalgia and healthy controls. *Pain* 2008;140:420-428.
17. Lee SC, Kim HS, Park YE, Choi YC, Park KH, Kim DS. Clinical diversity of SCN4A-mutation-associated skeletal muscle sodium channelopathy. *J Clin Neurol* 2009;5:186-191.