



Contents lists available at ScienceDirect

International Journal of Surgery Case Reports

journal homepage: www.casereports.com

Use of Vacuum-assisted closure in management of open abdominal wound with multiple enterocutaneous fistulae during chemotherapy: A case report



Shiki Fujino^a, Norikatsu Miyoshi^{a,*}, Masayuki Ohue^a, Shingo Noura^a, Tadafumi Fukata^b, Toshiya Yagi^c, Yoshiyuki Fujiwara^a, Masahiko Yano^a

^a Department of Surgery, Osaka Medical Center for Cancer and Cardiovascular Diseases, 1-3-3 Nakamichi, Higashinari-ku, Osaka 537-8511, Japan

^b Department of Gastroenterological Surgery, Osaka University Graduate School of Medicine, Suita, Yamadaoka 2-2, Osaka 565-0871, Japan

^c Department of Clinical Oncology, Osaka Medical Center for Cancer and Cardiovascular Diseases, 1-3-3 Nakamichi, Higashinari-ku, Osaka 537-8511, Japan

ARTICLE INFO

Article history:

Received 16 September 2015

Received in revised form 28 October 2015

Accepted 4 November 2015

Available online 10 November 2015

Keywords:

Vacuum-assisted closure

Colorectal cancer

Perforation

Open abdomen

Intestinal perforation

Bevacizumab

ABSTRACT

INTRODUCTION: Vacuum-assisted closure (VAC) is useful for treating complex wounds because it promotes granulation. In the present report, a successful case of VAC used for an open abdominal wound with enterocutaneous fistulae after multiple intestinal perforations during chemotherapy is described.

PRESENTATION OF CASE: A 73-year-old man was admitted to our hospital with severe abdominal pain. He underwent surgical resection for ascending colon cancer 4 years ago and was administered chemotherapy with bevacizumab for recurrence. Physical examination and computed tomography revealed perforation of the intestine, and an emergency operation was performed. Following this procedure, other intestinal perforations occurred, resulting in an open abdominal wound at postoperative day (POD) 10. To isolate enteric contents and promote granulation, VAC was applied to the abdominal wound with enterocutaneous fistulae. Oral intake started at POD 21 and the wound size became smaller. Further, an ostomy bag was directly attached to the most oral perforation site. The patient recovered from life-threatening events without severe infection and was transferred to another hospital close to his home at POD 180.

DISCUSSION: Gastrointestinal perforation is known to be one of the fatal adverse events of bevacizumab. In this case four gastrointestinal perforations were observed. Isolation of enteric contents is important to heal the wound and VAC is an effective therapy for the management of open abdominal wounds even with enterocutaneous fistulae.

CONCLUSION: Innovative VAC use for the management of open abdominal wounds can improve the nutritional status and overall wound healing of the patient.

© 2015 The Authors. Published by Elsevier Ltd. on behalf of IJS Publishing Group Ltd. This is an open access article under the CC BY-NC-ND license (<http://creativecommons.org/licenses/by-nc-nd/4.0/>).

1. Introduction

Vacuum-assisted closure (VAC) was first reported in 1997 [1,2]. It aids in secondary wound healing and has become the most common treatment modality for complex wounds. An open-cell foam dressing placed into the wound cavity and applying controlled negative pressure decrease bacterial colonization, tissue edema, and wound tension and increase blood flow. Using these strategies, VAC promotes wound granulation [2,3]. VAC has been recently used

in gastrointestinal surgery field and for open abdominal wounds [4–6]. It can shorten time for reconstruction. However there are a few reports regarding the use of VAC for open abdominal wounds with enterocutaneous fistula [7,8]. Exposure to enteric contents results in wound inflammation and infection, with the further effect of protracted wound healing. Therefore the drainage system is the most critical management factor in wounds with enterocutaneous fistula. In addition the patient was treated with bevacizumab which is reported to increase wound healing complications. Herein we report the successful case to be treated by VAC for an open abdominal wound with enterocutaneous fistulae, and the present report is the first successful case of multiple gastrointestinal perforations.

1.1. Presentation of case

A 73-year-old man was admitted to our hospital with severe abdominal pain in March 2014. He had a medical history of surgical resection for ascending colon cancer at another hospital in

Abbreviations: VAC, vacuum-assisted closure.

* Corresponding author. Tel: +81 6 6972 1181 Fax: +81 6 6981 8005.

E-mail addresses: fujino-si@mc.pref.osaka.jp (S. Fujino),

miyosi-no@mc.pref.osaka.jp, norim0529@gmail.com, miyosi-no@mc.pref.osaka.jp

(N. Miyoshi), ohue-ma@mc.pref.osaka.jp (M. Ohue), noura-si@mc.pref.osaka.jp

(S. Noura), fukatfukat0722@gmail.com (T. Fukata), yagi-to@mc.pref.osaka.jp

(T. Yagi), fujiwara-yo@mc.pref.osaka.jp (Y. Fujiwara), yano-ma@mc.pref.osaka.jp

(M. Yano).

<http://dx.doi.org/10.1016/j.ijscr.2015.11.003>

2210-2612/© 2015 The Authors. Published by Elsevier Ltd. on behalf of IJS Publishing Group Ltd. This is an open access article under the CC BY-NC-ND license (<http://creativecommons.org/licenses/by-nc-nd/4.0/>).

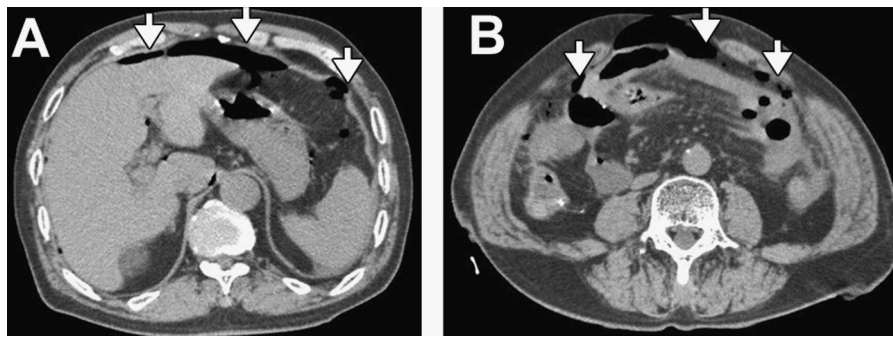


Fig. 1. Abdominal computed tomography (CT) images of an intestinal perforation. CT image revealed free air (arrows) in the upper space of the abdomen (A) and also in the lower space of the abdomen (B).

June 2010. The right iliopsoas muscle and right femoral nerve were partially resected as part of the cancer treatment. The final stage was IIIb (T4bN1bM0) according to the UICC TNM classification [9], and the cancer microscopically remained at the surgical excision site around the right external iliac artery. Therefore, 5-fluorouracil-based chemotherapy, UFT (300 mg/m²/day × 28 days/5 weeks) and radiotherapy (50 Gy to the right external iliac artery) were post-operatively administered. In October 2012, there was a clear recurrence of the cancer at the surgical site, and the patient was admitted to the Department of Clinical Oncology at Osaka Medical Center for Cancer and Cardiovascular Diseases. Due to recurrence, several chemotherapies (CapeOX, mFOLFOX6, FOLFIRI) with bevacizumab had been administered according to the guidelines provided by the Japanese Society for Cancer of the Colon and Rectum [10] in the outpatient clinic.

Abdominal computed tomography (CT) revealed perforation of the intestine (Fig. 1), and an emergency operation was performed. At surgery, perforation of the sigmoid colon was detected; it was sutured and a diverting ileostomy was performed. On POD 8, a new perforation of the small intestine occurred and a second emergency operation was performed. At that time, there were severe adhesions of the small intestine; therefore a suture or resection of the intestine with the perforation could not be performed. To isolate the enteric contents, a drainage tube was positioned in the perforation site, and the abdominal wall was sutured. However, drainage of enteric contents through the drainage tube was not effective, and the abdominal wound reopened 2 days later (POD 10 after the first operation) (Fig. 2). In general, enteric contents prevent the wound healing, and it was difficult to manage the drainage at this time. Therefore we introduced VAC therapy (VAC; KCI Inter-

national, San Antonio, TX, USA) to minimize abdominal wound infection by isolating enteric contents as well as to promote wound granulation. VAC therapy was administered using a VAC system. The entire wound surrounding the fistulae was treated with VAC therapy (Fig. 3). First, the open wound was washed by saline and an atraumatic contact layer, either Mepitel One (Mölnlycke Health Care, Norcross, GA, USA) and GranuFoam (KCI international), was cut to the shape of the abdominal wound, excluding the fistula holes. The intestinal wall, except the perforation sites, was covered with the atraumatic contact layer as bleeding or perforation of the intestine can occur when the intestine directly contacts GranuFoam [11,12]. Next, GranuFoam was positioned on the atraumatic contact layer. These layers were then covered with a polyurethane drape (VAC drape), and continuous negative pressure was applied (75 mm Hg). Enteric contents were suctioned using a Continuous Suction Unit MERA Sucuum (Senko Medical Instrument Manufacturing CO, Tokyo, Japan) set to 50 mm Hg continuous negative pressure. Although two additional perforations of the small intestine were observed on POD 11 and POD 14, the additional enteric contents were effectively isolated by the VAC system, and it was continued. An ostomy bag was attached to the VAC drape at the most oral perforation site of the intestine, and oral intake started on POD 21 (Fig. 4). The VAC system was considered effective in promoting the granulation tissue covering both the intestinal wall and wound bed. Three months after the administration of VAC, enteric contents could be separated into an ostomy bag without suction using MERA Sucuum at the most oral perforation site.

Although the wound granulated well over the exposed intestine, the VAC system was still required to anchor the ostomy bag for drainage of enteric contents. In order to directly attach an ostomy

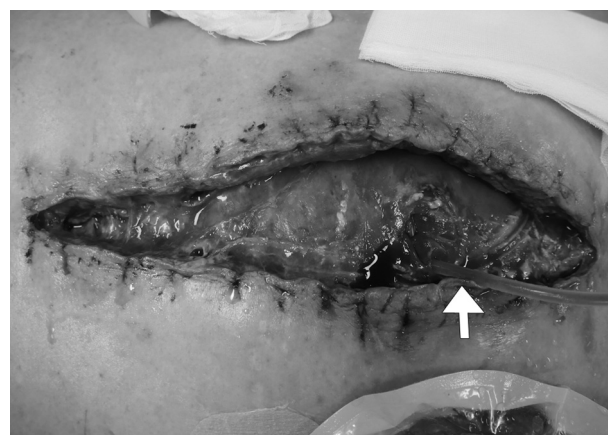

Fig. 2. Photograph of the open abdominal wound with intestinal perforation at POD 10. A drainage tube (arrow) was placed into the small intestine through a perforation site in the second emergency operation.

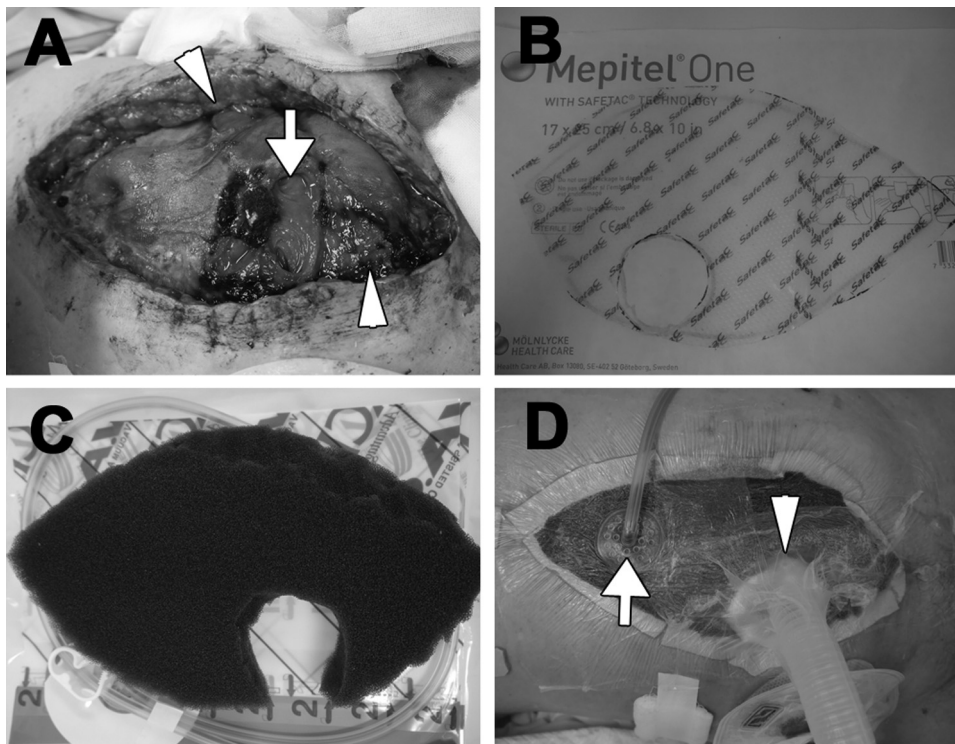


Fig. 3. Photographs of VAC therapy for open abdominal wound with fistulae. (A) Open abdominal wound at POD 11. An arrow shows the most oral perforation site, which is the same site showed in Fig. 2. Arrowheads show other perforations. (B) Mepitel one was cut to the shape of the open abdominal wound and a hole was created for the drainage of enteric contents. (C) GranuFoam was also cut to the shape of the open abdominal wound with a hole for drainage of enteric contents. (D) The wound was covered with a film and a VAC connecting tube (arrow) was affixed to it. Controlled negative pressure was then applied and another suction tube (arrowhead) was positioned at the most oral perforation site for the suction of enteric contents at a pressure of 50 mmHg.

bag, an operation was performed to cover the granulation tissue with skin. A portion of the skin around the most oral perforation site was then cut and rotated to cover the granulation tissue at POD 102, and the wound contracted (Fig. 5). Change and replacement of VAC was necessary approximately once a week. At POD 180, the rotated skin around the most oral perforation site healed well and appeared to be “a uniforate stoma,” allowing an ostomy bag to be directly attached without the VAC system. The patient was then transferred to another hospital close to his home.

2. Discussion

A humanized anti-vascular endothelial growth factor monoclonal antibody, bevacizumab, has been reported to be useful for several cancer therapies and also for colorectal cancer ther-

apy [10,13]. However, gastrointestinal perforation was observed in 0.9% of patients who underwent chemotherapy with bevacizumab for colorectal cancer, and bevacizumab was reported to increase wound healing complications [14,15]. High dose of bevacizumab (5.0 mg/kg/week) or concurrent use with chemotherapy, such as oxaliplatin, was reported to increase gastrointestinal perforation [14]. In the present case, oxaliplatin was used as part of chemotherapy, and 5.0 mg/kg/week bevacizumab was administered when the perforation occurred. Gastrointestinal perforation is one of the fatal adverse events of bevacizumab [16–18]. The mortality of gastrointestinal perforation was 21.7% in cancer patients treated with bevacizumab, whereas it was 15.7% without bevacizumab [19]. The mechanism of bowel perforation with bevacizumab is poorly understood, but it increases the risk of arterial thromboembolic events and venous thromboembolism

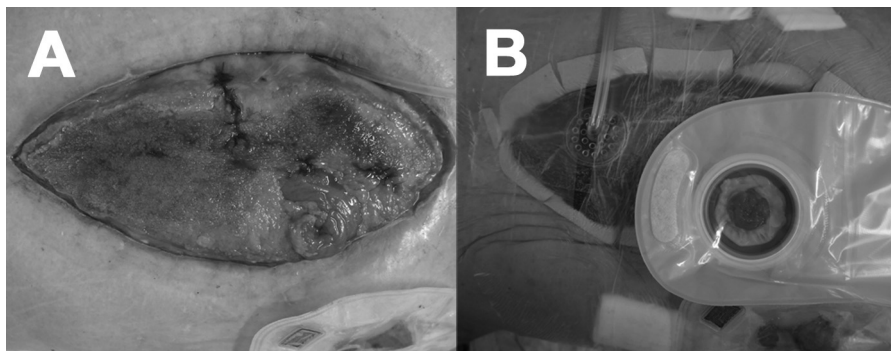


Fig. 4. Photographs of the open abdominal wound on POD 21. (A) The wound was almost covered with healthy granulation tissue. (B) The ostomy bag was attached to the most oral perforation site instead of the suction tube depicted in Fig. 3D, and suction pressure of 50 mmHg was continued to drain intestinal contents.

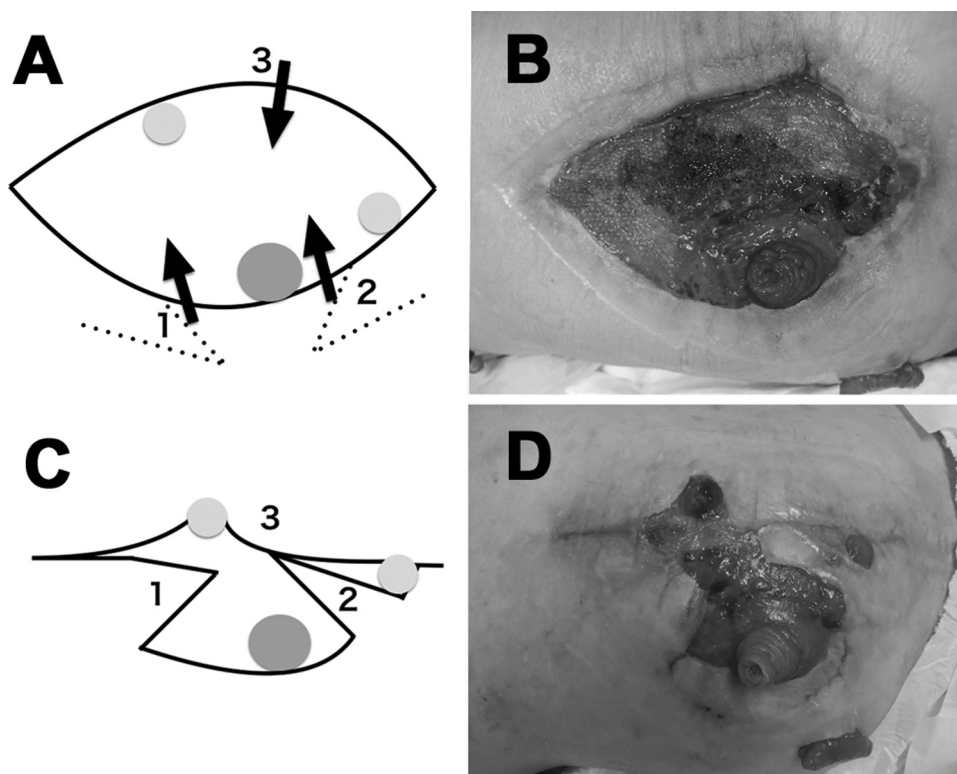


Fig. 5. Scheme of the skin rotation and photographs of the open abdominal wound on POD 102 and POD 174. (A) The dark gray closed circle indicates the most oral perforation site and white gray closed circles indicate the other perforation sites. The skin was cut along the dotted line, and two skin flaps (star and rhomboid) were created. The left side skin was cut and rotated (3). (B) Two skin flaps (star and rhomboid) were rotated onto the granulation tissue. (C) Healthy granulation tissue was observed on POD 102 prior to skin rotation. (D) The skin flap adhered to the healthy granulation tissue on POD102.

[20,21]. It suggests that bevacizumab damages gastrointestinal vessels, resulting in ischemic perforation of the normal bowel wall. Therefore, an appropriate treatment is necessary on the case. In this case all perforations occurred within 6 weeks following the final administration of bevacizumab; to the best of our knowledge, this is the first report of multiple intestinal perforations related to bevacizumab. Gastrointestinal perforations and open abdomen were life-threatening events; therefore, we controlled the infection and promoted secondary wound healing with VAC.

In a case of open abdomens with enterocutaneous fistulae, extensive wound care such as negative pressure wound therapy is effective, and mortality rates and recovery can be improved by nutritional support [22]. Therefore isolating enteric contents is the most important factor in the prevention of infection and promotion of wound healing. A few studies reported the usefulness of VAC for open abdomens with enterocutaneous fistula, and VAC has not been reported to confer any additional morbidity or risk of new fistula formation [7,8,23]. It was reported that VAC therapy with silicone fistula plug and platelet gel, and low intestinal pressure are effective to manage the fistula [24–26]. In the present case, there were multiple fistulae and we made “a uniforate stoma” at the most oral fistula by suction using MERA Sucuum. Enteric contents were almost entirely isolated, leading to early oral intake for nutritional recovery.

The patient recovered from life-threatening gastrointestinal perforations and open abdomen, which are difficult to manage. VAC and isolation of enteric contents using MERA Sucuum enabled to prevent infection and early oral intake. Therefore, VAC was one of the useful treatments of open abdomen with enterocutaneous fistulae.

3. Conclusions

VAC is an effective therapy for the management of an open abdominal wound with enterocutaneous fistulae during the treatment of bevacizumab and improves the nutritional status of the patient in addition to providing appropriate wound treatment.

Conflict of interests

The authors declare that they have no competing interests.

Funding

We have no funding sources to declare.

Ethical approval

To use a patient's surgical information for a paper is approved by Osaka Medical Center for Cancer and Cardiovascular Diseases ethical committee (ref No. 1408185104).

Consent

Written informed consent was obtained from the patient for publication of this case report and any accompanying images.

Author contribution

SF and NM designed the report. SF, NM, MO, SN, TF and TY were attending doctors for the patient. NM, MO, YF and MY organized the report and SF wrote the paper. All authors read and approved the final manuscript.

Guarantor

The guarantor of this manuscript is Norikatsu Miyoshi, corresponding author.

Acknowledgement

We would like to thank Dr. Yoichiro Homma for the critical advice regarding the usage of VAC treatment.

References

- [1] L.C. Argenta, M.J. Morykwas, Vacuum-assisted closure: a new method for wound control and treatment: clinical experience, *Ann. Plast. Surg* 38 (1997) 563–577.
- [2] M.J. Morykwas, L.C. Argenta, E.I. Shelton-Brown, W. McGuirt, Vacuum-assisted closure: a new method for wound control and treatment: animal studies and basic foundation, *Ann. Plast. Surg* 38 (1997) 553–562.
- [3] V. Saxena, C.W. Hwang, S. Huang, Q. Eichbaum, D. Ingber, D.P. Orgill, Vacuum-assisted closure: microdeformations of wounds and cell proliferation, *Plast. Reconstr. Surg.* 114 (2004) 1086–1096.
- [4] A.J. DeFranzo, K. Pitzer, J.A. Molnar, M.W. Marks, M.C. Chang, P.R. Miller, et al., Vacuum-assisted closure for defects of the abdominal wall, *Plast. Reconstr. Surg.* 121 (2008) 832–839.
- [5] C.C. Cothren, E.E. Moore, J.L. Johnson, J.B. Moore, J.M. Burch, One hundred percent fascial approximation with sequential abdominal closure of the open abdomen, *Am. J. Surg.* 192 (2006) 238–242.
- [6] S. Fujino, N. Miyoshi, M. Ohue, S. Noura, Y. Fujiwara, M. Yano, et al., Vacuum-assisted closure for open perineal wound after abdominoperineal resection, *Int. J. Surg. Case Rep.* 11 (2015) 87–90.
- [7] J. Gorman, J.A. Yelon, J.J. Platz, R.C. Singson, M. Turcinovic, The Fistula VAC: a technique for management of enterocutaneous fistulae arising within the open abdomen: report of 5 cases, *J. Trauma* 60 (2006) 428–431.
- [8] K. Boulanger, V. Lemaire, D. Jacquemin, Vacuum-assisted closure of enterocutaneous fistula, *Acta Chir. Belg.* 107 (2007) 703–705.
- [9] M. Gospodarowicz, L.H. Sobin, C. Wittekind, *TNM Classification of Malignant Tumors*, 7th ed., Wiley-Blackwell, Oxford, 2010.
- [10] T. Watanabe, M. Itabashi, Y. Shimada, S. Tanaka, Y. Ito, Y. Ajioka, et al., Japanese society for cancer of the Colon and Rectum (JSCCR) guidelines 2010 for the treatment of colorectal cancer, *Int. J. Clin. Oncol.* 17 (2012) 1–29.
- [11] L. Heller, S.L. Levin, C.E. Butler, Management of abdominal wound dehiscence using vacuum assisted closure in patients with compromised healing, *Am. J. Surg.* 191 (2006) 165–172.
- [12] D. Kaufman-Rivi, A.C. Hazlett, M.A. Hardy, J.M. Smith, H.B. Seid, Provider experiences with negative-pressure wound therapy systems, *Adv. Skin Wound Care* 26 (2013) 311–318.
- [13] J.A. Sparano, R. Gray, B. Giantonio, P. O'Dwyer, R.L. Comis, The eastern cooperative oncology group portfolio of clinical. Evaluating antiangiogenesis agents in the clinic: the eastern cooperative oncology group portfolio of clinical trials, *Clin. Cancer Res.* 10 (2004) 1206–1211.
- [14] W.X. Qi, Z. Shen, L.N. Tang, Y. Yao, Bevacizumab increases the risk of gastrointestinal perforation in cancer patients: a meta-analysis with a focus on different subgroups, *Eur. J. Clin. Pharmacol.* 70 (2014) 893–906.
- [15] F.A. Scappaticci, L. Fehrenbacher, T. Cartwright, J.D. Hainsworth, W. Heim, J. Berlin et al, Surgical wound healing complications in metastatic colorectal cancer patients treated with bevacizumab, *J. Surg. Oncol.* 91 (2005) 173–180.
- [16] V. Ranpura, S. Hapani, S. Wu, Treatment-related mortality with bevacizumab in cancer patients: a meta-analysis, *JAMA* 305 (2011) 487–494.
- [17] S.E. Borofsky, M.S. Levine, S.E. Rubesin, J.L. Tanyi, C.S. Chu, A.S. Lev-Toaff, Bevacizumab-induced perforation of the gastrointestinal tract: clinical and radiographic findings in 11 patients, *Abdom. Imaging* 38 (2013) 265–272.
- [18] M.W. Saif, A. Elfiky, R.R. Salem, Gastrointestinal perforation due to bevacizumab in colorectal cancer, *Ann. Surg. Oncol.* 14 (2007) 1860–1869.
- [19] S. Hapani, D. Chu, S. Wu, Risk of gastrointestinal perforation in patients with cancer treated with bevacizumab: a meta-analysis, *Lancet Oncol.* 10 (2009) 559–568.
- [20] V. Ranpura, S. Hapani, J. Chuang, S. Wu, Risk of cardiac ischemia and arterial thromboembolic events with the angiogenesis inhibitor bevacizumab in cancer patients: a meta-analysis of randomized controlled trials, *Acta Oncol.* 49 (2010) 287–297.
- [21] S.R. Nalluri, D. Chu, R. Keresztes, X. Zhu, S. Wu, Risk of venous thromboembolism with the angiogenesis inhibitor bevacizumab in cancer patients: a meta-analysis, *JAMA* 300 (2008) 2277–2285.
- [22] D.E. Wainstein, V. Tungler, C. Ravazzola, O. Chara, Management of external small bowel fistulae: challenges and controversies confronting the general surgeon, *Int. J. Surg.* 9 (2011) 198–203.
- [23] M. D'Hondt, D. Devriendt, F. Van Rooy, F. Vansteenkiste, A. D'Hoore, F. Penninckx, et al., Treatment of small-bowel fistulae in the open abdomen with topical negative-pressure therapy, *Am. J. Surg.* 202 (2011) e20–e24.
- [24] M.T. Ozer, H. Sinan, N. Zeybek, Y. Peker, A simple novel technique for enterocutaneous fistulae: silicone fistula plug, *Int. Wound J.* 11 (2014) 22–24.
- [25] D.I. Cattoni, C. Ravazzola, V. Tungler, D.E. Wainstein, O. Chara, Effect of intestinal pressure on fistula closure during vacuum assisted treatment: a computational approach, *Int. J. Surg.* 9 (2011) 662–668.
- [26] M. Scala, F. Spagnolo, M. Trapasso, P. Strada, L. Moresco, P. Santi, Association of vacuum-assisted closure and platelet gel for the definitive surgical repair of an enterocutaneous fistula: a case report, *In Vivo* 26 (2012) 147–150.

Open Access

This article is published Open Access at sciedirect.com. It is distributed under the [IJSCR Supplemental terms and conditions](#), which permits unrestricted non commercial use, distribution, and reproduction in any medium, provided the original authors and source are credited.