

Molluscum Contagiosum in a 12-Year-Old Child – Report of a Case and Review of LiteratureG Nandhini¹, K Rajkumar², K Sudheer Kanth³, Priyadharsini Nataraj⁴, Pavithra Ananthakrishnan⁵, M Arunachalam⁶**Contributors:**

¹Reader, Department of Oral Pathology, SRM Dental College, Chennai, Tamil Nadu, India; ²Professor & Head, Department of Oral Pathology, SRM Dental College, Chennai, Tamil Nadu, India; ³Reader, Department of Oral Pathology, Mamata Dental College, Khammam, Telangana, India; ⁴Lecturer, Department of Oral Pathology, SRM Dental College, Chennai, Tamil Nadu, India; ⁵Tutor, Department of Oral Pathology, SRM Dental College, Chennai, Tamil Nadu, India; ⁶Post-graduate Student, Department of Oral Pathology, SRM Dental College, Chennai, Tamil Nadu, India.

Correspondence:

Dr. Nandhini G. 186/2, Nallantha Flats, 4th Avenue, Anna Nagar West, Chennai - 600 040, Tamil Nadu, India. Phone: +91-9840192610. Email: drnandhuguna@gmail.com

How to cite the article:

Nandhini G, Rajkumar K, Kanth KS, Nataraj P, Ananthakrishnan P, Arunachalam M. Molluscum contagiosum in a 12 year old child – Report of a case and review of literature. J Int Oral Health 2015;7(1):63-6.

Abstract:

Molluscum contagiosum (MC) is an infection of the skin and mucous membrane caused by a DNA virus from the poxvirus family. It usually affects any part of the body and presents as pearly, flesh colored dome shaped nodule with a central umbilication. Clinical diagnosis can be supplemented with histopathology for the confirmed diagnosis of MC. This article presents a case of 12-year-old male child afflicted with MC along with a review of the literature on MC.

Key Words: Henderson–Paterson bodies, mollusca, molluscum contagiosum, pearly nodule

Introduction

Molluscum contagiosum (MC) is a common and self-limiting viral infection of the skin and mucous membrane, caused by molluscipox virus gene of the poxvirus family. MC infection usually affects children and also adults who are sexually active and those who are immunocompromised. Clinically MC appears as small bumps, which are called as “mollusca” on the skin or mucous membrane.¹

The clinical appearance of MC in most cases is diagnostic and, histopathology examination can be used as an aid in the diagnosis of cases that are not clinically obvious.

Here, we report a case of MC in a male child with its clinical and histopathological findings.

Case Report

A 12-year-old male child reported to the Oral Medicine Department with a complaint of sudden eruptive papules in the right side of the face for the past 2 months. History revealed that the papules were noticed by his parents 2 months ago, which were small in size and not associated with any pain or discomfort.

Extra-oral examination revealed two large papules measuring 4 mm in diameter and three small papules measuring 2 mm in diameter, which were seen on the right side of the skin of the face near the angle of the mouth. The surface of the lesions appeared smooth, round, blanched and pinkish with a dimple in the middle, and they were soft in consistency and non-tender (Figure 1).

Routine blood investigations revealed no abnormality in any of the parameters. HIV 1 and HIV 2 testing were also done, which was found to be negative. Fluorescent antinuclear antibody testing was done to check for autoimmune infection, and was found to be negative. On the basis of clinical examination, provisional diagnosis of MC was made, along with the differential diagnosis of Herpes simplex infection. Under local anesthesia, the two larger lesions were surgically excised, and the biopsied tissues were fixed in 10% formalin and sent for histopathological examination (Figure 2).

Microscopic examination of the excised tissue by routine hematoxylin and eosin (H and E) staining revealed hyperplastic epidermis in the form of lobules invaginating into the dermis (Figure 3). The basal layer showed enlarged basophilic nuclei and mitotic figures. Progressing toward the center of the lobule, the spinous cells showed cytoplasmic vacuolization and large intra-cytoplasmic, basophilic viral inclusions called Molluscum bodies or Henderson-Paterson bodies, which compress the keratinocyte nucleus (Figure 4).

Along with H and E, special stains such as Gram's, Giemsa, and Papanicolaou (Figure 5) were also done to demonstrate the viral inclusion bodies within the host cell. Correlating the clinical and histopathological findings the lesion was diagnosed as MC.

Since MC is self-limiting condition, the smaller lesions were allowed to resolve spontaneously and the patient was reviewed after a month, and showed no recurrence or scarring in the excised area.

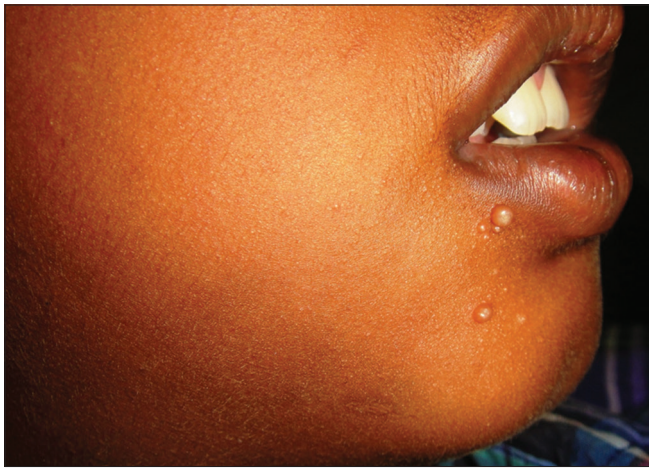

Figure 1: Multiple smooth, round, and pinkish papules on the skin of the face near the angle of the mouth.



Figure 2: Gross picture of the excised specimens.

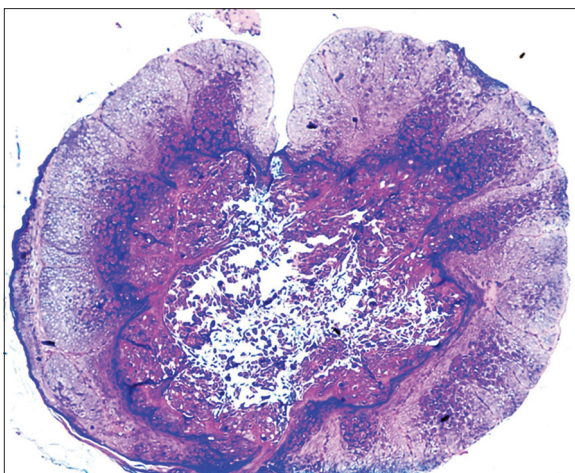


Figure 3: Lobular hyperplasia of epidermis resulting in a cup shaped invagination into the dermis (H and E, $\times 4$).

Discussion

MC is a superficial, viral infection, which is characterized by single, discrete or multiple papular or nodular lesions on the skin and mucous membrane. MC was first described by Bateman in year 1817.² MC is caused by Molluscum

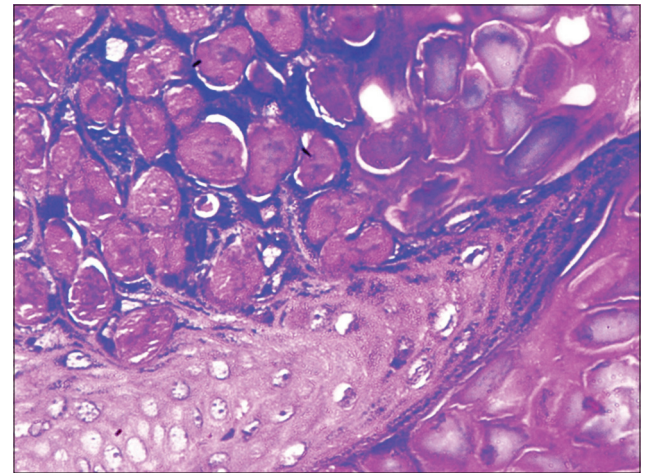


Figure 4: Henderson–Paterson/molluscum bodies appearing eosinophilic in the spinous layer and basophilic in the granular layer (H and E, $\times 20$).

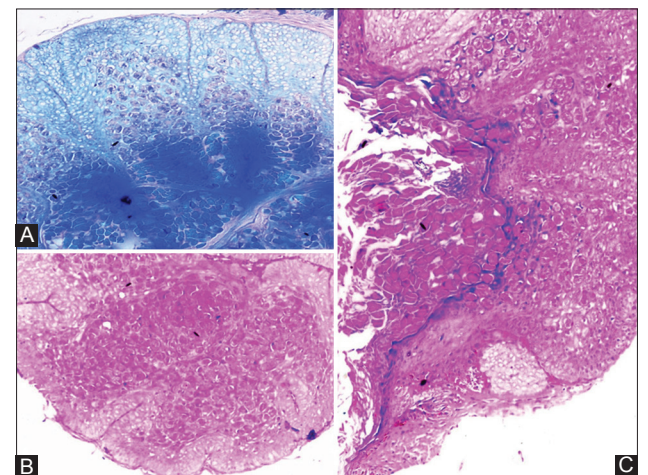


Figure 5: Special stains used to demonstrate molluscum bodies; (a) Molluscum bodies appearing basophilic with gram stain ($\times 10$), (b) molluscum bodies appearing eosinophilic with giemsa stain ($\times 10$), (c) molluscum bodies appearing eosinophilic with papanicolaou stain ($\times 10$).

contagiosum virus (MCV), which is a DNA virus belonging to the poxvirus family. MCV is of four types; MCV I to MCV IV of which MCV I is most prevalent and MCV II is usually seen in adults.¹

MC is a common infection in children between the ages of 1-12 years. It is also seen in sexually active adults and those who are immunocompromised, such those with HIV.

MCV is transmitted either via direct contact with infected people or indirectly through infected fomites. The virus also spreads through sexual contact or by autoinoculation. Traumatic inoculation such as that caused by tattoos can also transmit the virus.³ The incubation period usually varies from 2 to 8 weeks, and sometimes may extend upto 6-18 months.²

In children, MCV lesions are frequently seen in the skin of the face, neck, armpits, arms and hands;⁴ and mucous membrane of lips, tongue and buccal mucosa.² In sexually active adults and immunocompromised individuals such as those with AIDS, the lesions are commonly seen in the genital, abdomen and the inner part of the thigh.

In children and immunocompetent adults, the lesion is self-limiting, but in patients with HIV the lesions are more extensive and cause disfigurement. Studies have suggested that in patients with severe immunodeficiency MC may be used as a cutaneous marker and could be a first indicator of HIV infection.⁵

Clinically the lesion begins as a painless, small papule, which later becomes raised to a pearly, flesh colored dome shaped nodule with a central depression like a small pit or umbilication. These dome shaped nodules are called as "mollusca." The central pit contains central plug of waxy, cheesy, white material in which virus is present. The papules or nodules can be either solitary or multiple, and they measure about 2-5 mm and sometimes grow to as large as 10 mm.

MCV lesions are generally painless, but they may itch or become irritated. Scratching or picking the papules or nodules can lead to secondary bacterial infection or can cause scarring. Scratching or picking the papules or nodules can also cause the spread of the virus to the neighboring skin in a process called as autoinoculation. Children usually develop widespread cluster of lesion due to autoinoculation.

The differential diagnosis for MC in HIV patients includes Basal cell carcinoma, Keratocanthoma, Darier's disease, Epithelial nevi, Atopic dermatitis, Cryptococcosis, and Histoplasmosis.⁵

Diagnosis of the lesion is presumptively based on the distinctive, central umbilication of the dome shaped lesion, and the lesion can be further confirmed by biopsy and examining it under the microscope.

Histological section stained with H and E reveals inverted lobular hyperplasia of the epidermis in the form of a cup shaped nodule with central cellular and viral debris. The inverted epidermis exhibits acanthosis, and the basal layer shows enlarged basophilic nuclei and mitotic figures. Progressing upward, the keratinocyte cells of the spinous and granular layer exhibit intra-cytoplasmic, eosinophilic, granular viral inclusions called Molluscum bodies or Henderson-Paterson bodies.

These intra-cytoplasmic inclusion bodies were first described by Hendrson and Paterson in the year 1841.⁶ Ultrastructural studies of the molluscum bodies show membrane bound sacs that contain MCV. These inclusion bodies measure

approximately 35 μ in diameter and are formed by the virus within the cytoplasm of the cell. Initially, the virion is formed as a small particle in the cytoplasm of the cells of the suprabasal layer, and they increase in size from the spinous to the granular layer. In the granular layer, these inclusion bodies compress the nucleus to the periphery of the infected cells. Near the granular cell layer the staining reaction of the molluscum bodies changes from eosinophilic to basophilic. The stratum corneum in the center of the lesion disintegrates and releases the molluscum bodies into the central crater. Usually the dermis is relatively unremarkable, but when the contents of the lesion are discharged into it, the dermis shows inflammatory reaction composed of histiocytes, lymphocytes, neutrophils, and occasional foreign body giant cells. The large brick-shaped Molluscum bodies can also be demonstrated microscopically by squash preparation. This is a technique, wherein the cellular material within the central umbilication is extracted manually by an incision with a 16 gauge needle, and flattened between two microscopic slides to release the virions, and stained with 5-7 drops of Giemsa stain and observed under microscope to see the inclusion bodies.⁷ Gram, Wright, 10% KOH, and, Papanicolaou stains can also use to stain the smear to demonstrate the inclusion bodies. In our case, instead of the smear, the excised tissue sections were stained with geimsa, gram, and papanicolaou to demonstrate the inclusion bodies.

Studies have shown that most patients with MCV produce anti-cellular antibodies and virus-specific antibodies of the immunoglobulin M class, and they can be demonstrated by immunofluorescence.⁸ MCV can be detected and categorized by polymerase chain reaction assay in skin lesions.

MC lesions spontaneously resolve when left untreated within 6-18 months in children and immunocompetent adults. In immunocompromised and HIV infected adults the lesions can get protracted if left untreated. Treatment is recommended for aesthetic reasons and to prevent autoinoculation based on the patient's age, immune status, and site of lesion.

An easy home treatment is to gently scrub the affected area either with betadine surgical scrub or retin-A 0.025% gel for 5 min daily until the lesions resolves. The most common, quick, and efficient method to remove individual lesions is by cryosurgery using liquid nitrogen, dry ice, or frigiderm.⁹ Other methods include curettage with or without electrodesiccation,¹⁰ or by pulsed laser surgery¹¹ or by the use of adhesive tape.¹²

Surgical removal of the individual lesions may result in scarring. An effective method is to remove the lesions by using sharp instruments such as sharp tooth pick, scalpel, or the edge of a glass slide to eviscerate the central core.¹⁰ Topical agents such as trichloro acetic acid, potassium hydrochloride, cantharidium, 10% benzyl peroxide, imiquimod, retinoid

and similarly, essential oils like Australian lemon myrtle and tea tree oil with organically bound iodine can be used over the bumps.² Extensive lesions can also be treated by antiviral drugs such as cidofovir, either applied topically or administered by intralesional injections.¹³ Diphencyprone is a contact immunotherapy, which produces complete or partial regression in generalized MC in HIV patients.¹⁴ The complications of MC include irritation, inflammation, secondary bacterial infections, and cellulitis in patients who are HIV infected. The prognosis in healthy patients after treatments is usually effective, although lesions can cause disfiguring and scarring in generalized lesions.

Conclusion

Though clinical appearance of the lesion is sufficient for the diagnosis, microscopic examination of the excised tissue can be an adjuvant aid in the diagnosis of MC, and routine H and E stain can be supplemented with special stains like Geimsa, gram, and papanicolaou to demonstrate the molluscum bodies.

References

- Basak S, Rajurkar MN. Molluscum contagiosum - An update. *Indian Med Gaz* 2013;CXLVII(7):276-8.
- Bateman F. Molluscum contagiosum. In: Shelley WB, Crissey JT, (Editors). *Classics in Dermatology*, Springfield, IL: Charles C Thomas; 1953. p. 20.
- Molina L, Romiti R. Molluscum contagiosum on tattoo. *An Bras Dermatol* 2011;86; 352-4.
- A.D.A.M. Medical Encyclopedia [Internet]. Atlanta, GA: A.D.A.M.; 2013.
- Schwartz JJ, Myskowski PL. Molluscum contagiosum in patients with human immunodeficiency virus infection. A review of twenty-seven patients. *J Am Acad Dermatol* 1992;27(4):583-8.
- Brown ST, Nalley JF, Kraus SJ. Molluscum contagiosum. *Sex Transm Dis* 1981;8:227-34.
- Eleftheriou LI, Kerr SC, Stratman EJ. Diagnosis of atypical molluscum contagiosum: The utility of a squash preparation. *Clin Med Res* 2011;9(1):50-1.
- Shirodaria PV, Matthews RS, Samuel M. Virus-specific and anticellular antibodies in molluscum contagiosum. *Br J Dermatol* 1979;101(2):133-40.
- Janniger CK, Schwartz RA. Molluscum contagiosum in children. *Cutis* 1993;52(4):194-6.
- Epstein WL. Molluscum contagiosum. *Semin Dermatol* 1992;11(3):184-9.
- Hammes S, Greve B, Raulin C. Molluscum contagiosum: Treatment with pulsed dye laser. *Hautarzt* 2001;52(1):38-42.
- Arndt KA. *Manual of Dermatologic Therapeutics*, 5th ed. Boston: Little Brown; 1995. p. 339-40.
- Zabawski EJ Jr. A review of topical and intralesional cidofovir. *Dermatol Online J* 2000;6(1):3.
- Chularojanamontri L, Tuchinda P, Kulthanan K, Manuskiatti W. Generalized molluscum contagiosum in an HIV patient treated with diphencyprone. *J Dermatol Case Rep* 2010;4(4):60-2.