

A Case of Sub-Diaphragmatic Abscess after Injection of Botulinum Toxin to Treat Achalasia

Constantine Fisher, MD¹, Frances Puello, MD², Samson Ferm, MD², Moshe Rubin, MD¹, and H. Alan Schnall, MD¹

¹Division of Gastroenterology, New York Presbyterian-Queens, Flushing, NY

²Department of Internal Medicine, New York Presbyterian-Queens, Flushing, NY

ABSTRACT

Achalasia is a disorder of the esophagus characterized by decreased lower esophageal sphincter (LES) relaxation and absence of esophageal peristalsis. Botulinum toxin (BT) injection targeting the LES has been used in the treatment of achalasia and other esophageal motility disorders, and it is considered to be safe and effective for short-term symptomatic relief. Serious adverse events of this procedure are rare. We report the case of an 83-year-old woman treated with BT injection for achalasia who subsequently developed a subdiaphragmatic abscess.

INTRODUCTION

Achalasia is a disorder of the esophagus characterized by decreased lower esophageal sphincter (LES) relaxation and absence of peristalsis. LES is the target of various therapeutic modalities. Decreasing LES pressure by pharmacologic intervention (botulinum toxin), mechanical intervention (dilation), surgical intervention (Heller myotomy), or per-oral endoscopic myotomy provides functional and symptomatic improvement. Type I achalasia (minimal esophageal pressurization on manometry) and type II achalasia (pressurization on $\geq 20\%$ of swallows) respond well to both myotomy and dilation.¹ Myotomy is more effective for type III achalasia (premature spastic contractions of the distal esophagus) compared to dilation (86% vs 40% success rate, respectively).^{1,2} With a relatively high perforation rate and decreasing clinical experience with pneumatic dilation, botulinum toxin (BT) has become increasingly used in the treatment of achalasia and esophageal motility disorders in patients who are not considered ideal surgical candidates. It is safe and effective for short-term symptomatic relief in high-risk patients.^{3,4}

The most common physiologic improvement associated with BT injection is a reduction in resting LES pressure. BT injection is associated with early symptomatic and functional improvement, with multiple prospective studies demonstrating immediate remission in 70–90% of patients.⁵ However, relapse within 6 months is common, and the vast majority of patients require a second injection within 6–12 months. The most common complications include heartburn and epigastric pain. Serious complications such as mediastinitis and esophageal perforation are rare, having been reported in case series only.^{6–8} Due to its favorable safety profile, intra-sphincteric BT injections have been used more frequently in elderly patients and in patients with multiple comorbidities with high surgical risk.

CASE REPORT

An 83-year-old woman with a past medical history of insulin-dependent diabetes mellitus, hypertension, hyperlipidemia, diastolic heart failure, diabetic gastroparesis, and chronic kidney disease presented to our institution with complaints of nausea and substernal epigastric abdominal discomfort associated with belching and poor oral intake

ACG Case Rep J 2017;4:e119. doi:10.14309/crj.2017.119. Published online: November 22, 2017.

Correspondence: Constantine Fisher, Division of Gastroenterology, New York Presbyterian-Queens, 56-45 Main St, Flushing, NY 11375 (fisher.constantine@gmail.com).



Copyright: © 2017 Fisher et al. This work is licensed under a Creative Commons Attribution-NonCommercial-NoDerivatives 4.0 International License. To view a copy of this license, visit <http://creativecommons.org/licenses/by-nc-nd/4.0>.

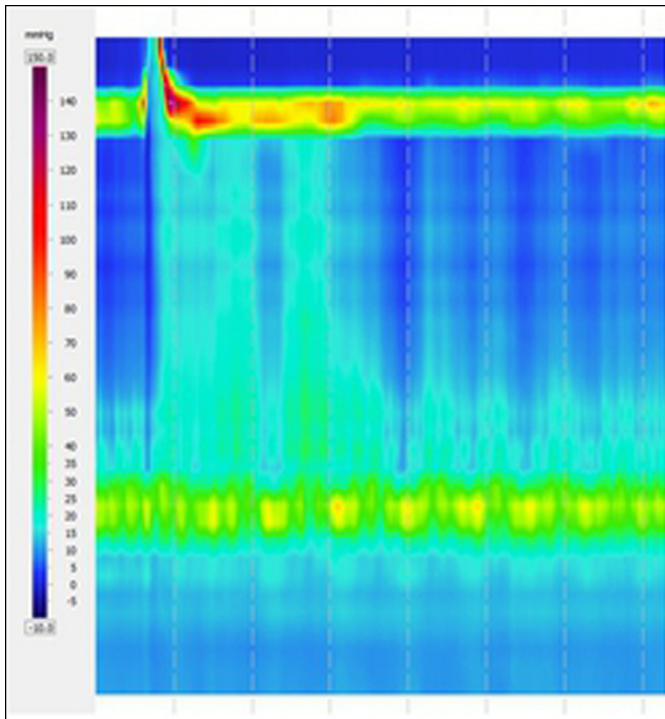


Figure 1. High-resolution esophageal manometry showing lack of esophageal peristalsis and incomplete lower esophageal sphincter relaxation consistent with type 1 achalasia. Image shows a mean of 11 swallows.

for 3 days. Physical examination was significant for mild right upper quadrant tenderness without rebound or guarding. Diagnostic manometry revealed aperistalsis of the esophageal body with elevated LES pressure consistent with type I achalasia (Figure 1). Endoscopic examination suggested decreased motility of the esophagus without dilation or lesions.

The patient underwent esophagogastroduodenoscopy (EGD) with BT injections targeting the LES, and she was subsequently discharged after immediate improvement in her symptoms. After 3 weeks, she presented to her primary care physician with a chief complaint of right shoulder pain. She was given NSAIDs for pain relief. Her symptoms persisted, and she was referred to a pain specialist, who administered right shoulder intra-articular steroid injections and again prescribed NSAIDs. Her symptoms continued despite therapy, and 2 days later she presented to our emergency department.

In the emergency department, she was found to have a white blood cell count of 30.7 K/ μ L, and a computed tomography (CT) scan of the abdomen revealed a 5.8 cm x 6.9 cm x 2.3 cm fluid collection (Figure 2) near the diaphragm suspicious for an abscess. She was started on vancomycin and piperacillin/tazobactam. The abscess was drained, and fluid cultures grew *Streptococcus intermedius*. In the interim, a

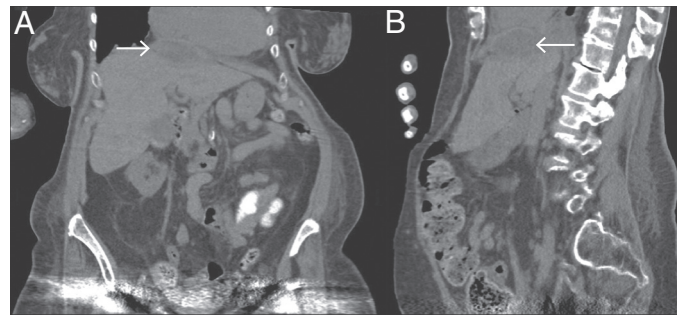


Figure 2. (A) Coronal and (B) sagittal abdominal computed tomography (CT) showing subdiaphragmatic collection (arrows).

vancomycin trough after the third dose was 32 μ g/ml. Vancomycin and piperacillin/tazobactam were discontinued, and the patient was started on ampicillin/sulbactam 3 g every 12 hours. Her leukocytosis subsequently improved, and a repeat abdominal CT revealed interval decrease in abscess size (Figure 3). However, the patient developed generalized edema secondary to acute kidney injury and hemodialysis was initiated.

During one of her hemodialysis sessions, she became unresponsive and required endotracheal intubation. She was admitted to the medical intensive care unit with septic shock requiring vasopressor support, at which time antibiotics were

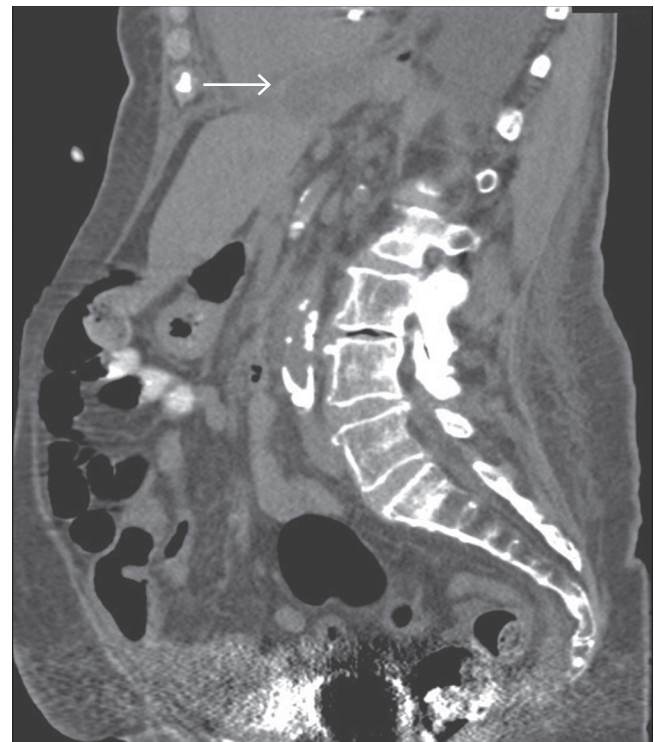


Figure 3. Sagittal abdominal CT showing interval improvement in collection (arrow).

escalated to meropenem and vancomycin. Her course was complicated by ischemic hepatopathy, a large left pleural effusion requiring the placement of a chest tube, and atrial fibrillation with rapid ventricular response. On hospitalization day 20, she was placed on comfort care measures by her family and she died on hospitalization day 21.

DISCUSSION

BT injection of the LES is an effective alternative to dilation or myotomy in the treatment of achalasia.^{4,9} Use of BT injections has increased rapidly over the past 15 years, as its utility has expanded to include other motility disorders of the gastrointestinal tract.¹⁰

The successful performance of BT injection is dependent on the operator. Typically, the approximate location is gauged using endoscopic visualization with subsequent “blind” delivery of BT into 4 quadrants of the LES. Endoscopic ultrasound and manometry have been used to more accurately deliver the injection to the appropriate site, although this practice is uncommon.^{11,12}

In spite of this, BT injection has been shown to be safe, with mild complications of post-procedural chest pain or reflux symptoms most commonly reported.^{4,13} Rarely, more severe adverse events have been documented, such as esophageal perforation, mediastinitis, and sinus tract formation.⁶⁻⁸ In a recent multi-institution study including 386 patients who underwent BT injections between 2008 and 2014, 7.9% experienced mild complications. Younger age was predictive of complications (odds ratio 1.43, 95% CI 1.03–1.96). Interestingly, an increased number of injections and an increased amount of injected toxin were not associated with higher complication rates.¹⁴

To our knowledge, subdiaphragmatic abscess formation after intersphincteric BT injection has never been reported in the literature. In our patient, it is probable that bacteria tracked along an injection site, with subsequent abscess formation. We believe this to be an unfortunate and otherwise rare complication occurring in the setting of a chronically ill patient with many comorbidities and immunologic compromise. The downward trajectory of the patient’s clinical course may have been determined by the prior steroid and NSAID use, which contributed to her renal failure and led to fluid overload, respiratory failure, and intubation.

With the increasing use of BT injections in achalasia and other gastrointestinal motility disorders, it is important to consider the complication of abscess formation. Although exceedingly

rare, our case demonstrates the serious adverse events that can occur with this simple procedure.

DISCLOSURES

Author contributions: C. Fisher wrote and edited the manuscript, and is the article guarantor. F. Puello, S. Ferm, and HA Schnall wrote and edited the manuscript. M. Rubin revised the manuscript.

Financial disclosure: None to report.

Informed consent was obtained for this case report.

Received June 26, 2017; Accepted September 13, 2017

REFERENCES

1. Rohof WO, Salvador R, Annese V, et al. Outcomes of treatment for achalasia depend on manometric subtype. *Gastroenterol*. 2013;144:718–25.
2. Ihara E, Muta K, Nakamura K. Diagnosis and treatment strategy of achalasia subtypes and esophagogastric junction outflow obstruction based on high resolution manometry. *Digestion*. 2017;95:29–35.
3. Allescher HD, Storr M, Seige M, et al. Treatment of achalasia: Botulinum toxin injection vs. pneumatic balloon dilation. A prospective study with long-term follow-up. *Endoscopy*. 2001;33(12):1007.
4. Pasricha PJ, Ravich WJ, Hendrix TR, et al. Intraspincteric botulinum toxin for the treatment of achalasia. *N Engl J Med*. 1995;332(12):774.
5. Lake JM, Wong RK. Review article: The management of achalasia: A comparison of different treatment modalities. *Aliment Pharmacol Ther*. 2006;24(6):909.
6. Maclver R, Liptay M, Johnson Y. A case of mediastinitis following botulinum toxin type a treatment for achalasia. *Nat Clin Pract Gastroenterol Hepatol*. 2007;4(10):579.
7. Chao CY, Raj A, Saad N, et al. Esophageal perforation, inflammatory mediastinitis and pseudoaneurysm of the thoracic aorta as potential complications of botulinum toxin injection for achalasia. *Dig Endosc*. 2015;27(5):618–21.
8. Fitzgerald JF, Troncone R, Sukerek H, Tolia V. Clinical quiz. Sinus tract between esophagus and fundus. *J Pediatr Gastroenterol Nutr*. 2002;35(1):38–98.
9. Fishman VM, Parkman HP, Schiano TD, et al. Symptomatic improvement in achalasia after botulinum toxin injection of the lower esophageal sphincter. *Am J Gastroenterol*. 1996;91(9):1724.
10. Lacy BE, Weiser K, Kennedy A. Botulinum toxin and gastrointestinal tract disorders. Panacea, placebo or pathway to the future?. *Gastroenterol Hepatol (N Y)*. 2008;4(4):283–95.
11. Hoffman BJ, Knapple WL, Bhutani MS, et al. Treatment of achalasia by injection of botulinum toxin under endoscopic ultrasound guidance. *Gastrointest Endosc*. 1997;45(1):77.
12. Wehrmann T, Schmitt T, Dietrich CF, et al. Manometrically-guided endoscopic injection of botulinum toxin for esophageal achalasia: A pilot trial. *Z Gastroenterol*. 2000;38(11):899–903.
13. Rollan A, Gonzalez R, Carvajal S, Chianale J. Endoscopic intraspincteric injection of botulinum toxin for the treatment of achalasia. *J Clin Gastroenterol*. 1995;20(3):189.
14. van Hoeij FB, Tack JF, Pandolfino JE, et al. Complications of botulinum toxin injections for treatment of esophageal motility disorders. *Dis Esophagus*. 2017;30(3):1–5.