

# Savannah roars: The vocal anatomy and the impressive rutting calls of male impala (*Aepyceros melampus*) – highlighting the acoustic correlates of a mobile larynx

Roland Frey,<sup>1</sup> Ilya A. Volodin,<sup>2,3</sup> Elena V. Volodina,<sup>3</sup> Kseniya O. Efremova,<sup>4</sup> Vera Menges,<sup>5</sup> Ruben Portas,<sup>5</sup> Jörg Melzheimer,<sup>5</sup> Guido Fritsch,<sup>1</sup> Christina Gerlach<sup>6</sup> and Katja von Dörnberg<sup>6</sup>

<sup>1</sup>Department of Reproduction Management, Leibniz Institute for Zoo and Wildlife Research, Berlin, Germany

<sup>2</sup>Faculty of Biology, Department of Vertebrate Zoology, Lomonosov Moscow State University, Moscow, Russia

<sup>3</sup>Scientific Research Department, Moscow Zoo, Moscow, Russia

<sup>4</sup>Pirogov Russian National Research Medical University, Moscow, Russia

<sup>5</sup>Department of Evolutionary Ecology, Leibniz Institute for Zoo and Wildlife Research, Berlin, Germany

<sup>6</sup>Hannover Zoo, Hannover, Germany

## Abstract

A retractable larynx and adaptations of the vocal folds in the males of several polygynous ruminants serve for the production of rutting calls that acoustically announce larger than actual body size to both rival males and potential female mates. Here, such features of the vocal tract and of the sound source are documented in another species. We investigated the vocal anatomy and laryngeal mobility including its acoustical effects during the rutting vocal display of free-ranging male impala (*Aepyceros melampus melampus*) in Namibia. Male impala produced bouts of rutting calls (consisting of oral roars and interspersed explosive nasal snorts) in a low-stretch posture while guarding a rutting territory or harem. For the duration of the roars, male impala retracted the larynx from its high resting position to a low mid-neck position involving an extensible pharynx and a resilient connection between the hyoid apparatus and the larynx. Maximal larynx retraction was 108 mm based on estimates in video single frames. This was in good concordance with 91-mm vocal tract elongation calculated on the basis of differences in formant dispersion between roar portions produced with the larynx still ascended and those produced with maximally retracted larynx. Judged by their morphological traits, the larynx-retracting muscles of male impala are homologous to those of other larynx-retracting ruminants. In contrast, the large and massive vocal keels are evolutionary novelties arising by fusion and linear arrangement of the arytenoid cartilage and the canonical vocal fold. These bulky and histologically complex vocal keels produced a low fundamental frequency of 50 Hz. Impala is another ruminant species in which the males are capable of larynx retraction. In addition, male impala vocal folds are spectacularly specialized compared with domestic bovids, allowing the production of impressive, low-frequency roaring vocalizations as a significant part of their rutting behaviour. Our study expands knowledge on the evolutionary variation of vocal fold morphology in mammals, suggesting that the structure of the mammalian sound source is not always human-like and should be considered in acoustic analysis and modelling.

**Key words:** Bovidae; Felidae; formants; fundamental frequency; larynx retraction; mammal; polygyny; roaring; ruminant; sexual selection; vocal fold; vocal posture; vocal tract.

## Introduction

Anatomical adaptations for the production of rutting calls that reflect body size and caller quality have been reported for harem and lekking males of different taxa of mammals (Fitch & Reby, 2001; Reby & McComb, 2003; Charlton et al. 2011b; Toth & Parsons, 2018). Certain species of cervids, bovids, marsupials, felids and primates independently evolved a descended and mobile larynx in combination with an elongated pharynx (Sonntag, 1921; Negus, 1949;

### Correspondence

Roland Frey, Leibniz Institute for Zoo and Wildlife Research (IZW), P.O. Box 700430, D – 10324 Berlin, Germany. E: frey@izw-berlin.de

Accepted for publication 10 October 2019

Article published online 28 November 2019

[Correction added on, 31 October after first online publication: Projekt Deal funding statement has been added.]

Fitch & Reby, 2001; Weissengruber et al. 2002; Frey & Gebler, 2003; Frey et al. 2008a,b, 2011, 2012, 2018; McElligott et al. 2006; Efremova et al. 2016; Volodin et al. 2017a). A potential role of an elongated pharynx in respiration, deglutition or rumination has not been identified so far. Therefore, it is generally agreed that a descended and mobile larynx and the resulting elongation of the vocal tract serves an acoustic function; in particular, it affects the vocal tract resonances (formants) of male rutting calls (Fitch & Reby, 2001; Frey et al. 2008a,b, 2011, 2012, 2018; McElligott et al. 2006; Volodin et al. 2017a, 2019).

Call fundamental frequency ( $f_0$ ) and its harmonics, produced by vibration of the vocal folds in the larynx (the source), are filtered by the oral or nasal vocal tract up to emission of the sound *via* the mouth or nostrils (Fant, 1960; Taylor & Reby, 2010). The longer the supraglottal vocal tracts (the filter), the lower the resulting resonance frequencies or formants (Fant, 1960; Fitch, 1997; Reby & McComb, 2003; Frey et al. 2007, 2011, 2012; Taylor & Reby, 2010; Volodin et al. 2014, 2017a; Sibiryakova et al. 2017). Rutting calls with lower formants are perceived as more threatening by rival males (Reby et al. 2005; Charlton et al. 2013b) and as more attractive by potential female mates (Charlton et al. 2007, 2008, 2012). Anatomical constraints are thought to impose limits on the apparent body size exaggeration by vocal tract elongation (Fitch & Reby, 2001; Reby & McComb, 2003). That is why the lowered formants still correlate with body size and honestly communicate male quality (Reby et al. 2005; Charlton et al. 2007, 2008, 2011b, 2012, 2013a; Briefer et al. 2010; Wyman et al. 2012).

Low-frequency calls with densely spaced harmonics reveal formants better than high-frequency calls with widely spaced harmonics (Fitch, 1997; Fitch & Reby, 2001; Frey & Riede, 2013; Volodin et al. 2013, 2017b). Therefore, high-frequency, narrowband, tonal male rutting calls are the exception rather than the rule (Reby et al. 2016; Golosova et al. 2017). In contrast, low-frequency, wideband, noisy male rutting calls occur much more often, e.g. in koala *Phascolarctos cinereus* (Charlton et al. 2011a), striped possum *Dactylopsila trivirgata* (Volodin & Volodina, 2002), red deer *Cervus elaphus* (Fitch & Reby, 2001), fallow deer *Dama dama* (McElligott et al. 2006), saiga *Saiga tatarica* (Frey et al. 2007), goitred gazelle *Gazella subgutturosa* (Frey et al. 2011) and impala *Aepyceros melampus* (Murray, 1982; Oliver et al. 2006) (Fig. 1).

Adaptations of the larynx and vocal tract that evolved under a selection pressure for rutting calls with lower  $f_0$  and/or lower formants occur in various combinations among species. For example, a greatly enlarged and retractable, highly mobile larynx is characteristic of male Mongolian gazelle *Procapra gutturosa* (Frey & Riede, 2003; Frey et al. 2008a,b), goitred gazelle (Frey et al. 2011) and fallow deer (McElligott et al. 2006). A moderately enlarged, permanently descended, mostly stationary larynx is characteristic of male humans *Homo sapiens* (Negus, 1949). A non-



**Fig. 1** A rutting impala male with harem in the early morning sun at the Okambara Elephant Ranch, Namibia.

enlarged, permanently descended, retractable and highly mobile larynx is characteristic of both male red deer (Fitch & Reby, 2001; Frey et al. 2012) and koala (Sonntag, 1921; Charlton et al. 2013a; Frey et al. 2018).

A permanently descended, unenlarged, probably retractable and mobile larynx is also characteristic of the large roaring Pantherine felids (see Supporting Information, Fig. S3). As in koala, these features occur in both sexes (Luckhaus, 1969; Weissengruber et al., 2002, 2008). In lions, this might have evolved in the context of acoustically marking and defending the pride territory by male and female roaring choruses (McComb & Clutton-Brock, 1994; Grinnell, 2002; Ramsauer, 2005; Pfefferle et al. 2007).

To the human ear, the roars of male impala superficially resemble the roars of lions and can be confused with the latter by an inexperienced listener. However, the structure of the vocal organs of lions is clearly different from that of male impala. Apparently, as both taxa are not closely related phylogenetically, they independently and convergently evolved different specialisations for roaring vocalisations in a savannah habitat. Therefore, a comparison with the vocal organs of lions is presented in the Supporting Information, Fig. S3.

The common impala is a sexually dimorphic polygynous ruminant (Jarman, 1979; Murray, 1982; Oliver et al. 2006) with a body mass of 49–63 kg in males and 38–45 kg in females (Skinner, 1971; Fairall & Braack, 1976; Murray, 1982; Fig. 1). Shoulder height is about 885 mm in males and about 837 mm in females (Fairall & Braack, 1976). Impala are abundant on farmland across the southern African sub-region (Skinner & Chimimba, 2005; Schwab et al. 2012). In Namibia, however, common impala is sparsely distributed across farmland and is usually restricted to ranches associated with hunting and tourist business, but they are abundant in the north-eastern protected areas of the country (Estes, 2012).

During the rutting season, which lasts from the beginning of May until mid-June depending on the area (Dasmann & Mossman, 1962; Child, 1965, 1968; Schenkel, 1966; Skinner, 1971; Warren, 1974; Jarman, 1979; Murray, 1982; Favreau et al. 2013), impala males compete for females and regularly produce loud, low-frequency roars at both phases of

respiration (Schenkel, 1966; Murray, 1982; Oliver et al. 2006). Previously, the male impala rutting roars have only been described onomatopoeically (Schenkel, 1966; Murray, 1982).

According to observations and video recordings of the authors, male impala roaring is accompanied by retraction of the larynx from a slightly lowered resting position in the upper neck region, just below the lower jaw down to a transient almost mid-neck position. Apparently, this roar-synchronous retraction of the larynx has not been noticed or described in the literature so far.

The aim of this study is to provide a detailed vocal anatomy of male impala, to describe the vocal posture of rutting male impala and to create a 2D graphical reconstruction of the potential mechanism of laryngeal mobility and vocal tract elongation during call-synchronous movements of the larynx. In addition, we estimate the effects of laryngeal mobility on the acoustics of male impala rutting roars. Finally, we discuss differences of the vocal anatomy between impala and a roaring felid, the African lion *Panthera leo* (see Supporting Information, Fig. S3).

## Materials and methods

### Sites, subjects and dates of work

Audio and video recordings of vocalisations and rutting behaviour of at least a few dozen unmarked rutting male common impala (*Aepyceros melampus melampus*) were conducted at the fenced 15 000-ha Okambara Elephant Ranch (22.68°S, 18.16°E), located about 130 km east of Windhoek, Namibia, during the highest rutting activity from 1 to 28 May 2015. The Okambara Elephant Ranch is a native Namibian habitat with approximately 60% bush cover and open areas around artificial watering places, where introduced free-ranging adult male impala during the rut are subjected to irregular selective legal hunting. In addition to natural feeding resources (herbs, grass, shrubs, trees), hay is provided as supplementary food near the watering places during drought periods. The entire population of impala during the data collection amounted to approximately 800 individuals. This population originated from a herd of about 100 individuals of common impala, which were released on Okambara Elephant ranch in 1994. Since then, this population has been growing and currently counts more than 1000 individuals.

The vocal anatomy was investigated using two head-and-neck Specimens (#1 and #2) of adult male common impala. Specimen #1 was deep frozen postmortem at Hannover Zoo (Germany) in 2013 and macroscopically dissected at the Leibniz Institute for Zoo and Wildlife Research, Berlin, Germany (IZW) in 2016. Specimen #2, a legally hunted male, was macroscopically dissected about 1 h after death at the Okambara Elephant Ranch, Namibia, in May 2015. After the dissection, the hyoid apparatus and the sagittally cut larynx of Specimen #2 were preserved in 5% formalin, exported under permit number 145827, and later dissected and investigated histologically at the IZW in 2018.

### Audio recording

Audio recordings of male impala rutting calls were collected both automatically and manually. For the automated audio

recordings (22.05 kHz, 16-bit, stereo), we used four Song Meter SM2+ devices (Wildlife Acoustics Inc., Maynard, MA, USA). Each device was equipped with two omnidirectional microphones, fixed horizontally at 180° to each other. The devices were set at maximum sensitivity and potentially recorded male impala rutting calls within 100 m around the device in places of most active rut, identified by the presence of multiple fresh impala tracks and faeces. One device was placed on the ground within a large wire-mesh cage, protecting it from damage by baboons *Papio ursinus*. The remaining three devices were mounted on trees at a height of 2–2.5 m and protected against baboons by thorn bush branches.

The automated audio recordings were set to 9-min recording, interrupted by a 1-min pause (the minimum possible pause for this equipment), from 14:00 to 10:00 h of the next day, providing 120 audio wav-files of 9 min length each per device for each 24-h period. Each device was checked every 2–3 days during daytime to replace the cards and batteries and either left in place for further recordings or transferred to another site to cover a larger territory and record as many rutting males as possible. In total, 11 030 9-min wav-files (1655 h of recording time) were automatically collected in 22 different recording locations at distances of 0.5–12 km from each other between 1 and 28 May 2015.


Manual audio recordings (48 kHz, 16-bit, mono, distance to animals 10–100 m) were collected using two Marantz PMD-660 solid state recorders (D&M Professional, Kanagawa, Japan) with Sennheiser K6-ME66 cardioid electret condenser microphones (Sennheiser electronic, Wedemark, Germany). In total, we manually collected 207 wav-files of 1–11 min duration (about 8 h of recording time) between 1 and 28 May 2015.

The automated recordings provided the highest-quality calls appropriate for detailed acoustic analyses, as the animals were not afraid of the recording devices and often vocalised close to them. The manual audio recordings with hand-held recording devices were of lower quality and were only used as reference data for comparison with the calls from the automated devices, to validate the automatically recorded calls as indeed belonging to male impala.

### Video recording and analyses

Video clips of male rutting behaviour were recorded during the morning (05:00–10:00 h) and evening (15:00–19:00 h) hours of highest rutting vocal activity from curtain-covered chairs used as temporal hides at 20 different recording locations at distances of 0.5–12 km from each other. A total of 406 video clips of low resolution (about 8 h of total recording time, from distances of 30–150 m to the animals), were made with two Canon PowerShot SX50HS digital cameras (Canon USA, Melville, NY, USA). Video clips of high resolution (over 10 h of total recording time, 50–200 m from the animals) were made with a Sony FDR-AX100 Camcorder (Sony, Konan Minato-ku, Tokyo, Japan) on a tripod fluid head (Fluid Drag System MVH500AH) set on a 190CXPRO3 carbon fibre tripod (Manfrotto, Cassola, Italy).

Both high- and low-resolution video clips served for selecting video single frames for analyses of vocal posture and changes of vocal tract length during the roars (Fig. 2). Video single frames and subsequent analyses were selected using Adobe PREMIERE PRO, 1.5 AOO License ALL software (Adobe Systems Inc., San Jose, CA, USA). Two videos (Supporting Information Video S1 and Video S2), illustrating calling posture and larynx retraction, are available in the Supporting Information.



**Fig. 2** Oral vocal tract length estimation in video single frames of the same individual: (A) resting length, (B) maximally extended length during roar production. Green arrowhead: resting position of the larynx. Red arrowhead: maximally retracted position of the larynx. Blue line, turquoise end bars: tip of the nose/middle of the eye calibration line that allowed the introduction of an absolute measure in the single frames; this distance was 200 mm in the two dissected adult males. Yellow line, red end bars: oral vocal tract length; left red bar: lips; right red bar: assumed position of the vocal keels close to the externally visible laryngeal prominence. The inserted skull is that of the dissected Specimen #1. In this example, roaring was produced while the rutting male was in galloping locomotion.

### Vocal tract length estimation

Estimation of male impala oral vocal tract length (Fig. 2) was necessary to establish the settings of Linear Predictive Coding (LPC) for measuring the formants of the impala roars with PRAAT DSP software (Boersma & Weenink, 2013). For estimating the resting oral vocal tract length, we selected video single frames of silent individuals in which the larynx was definitely in its resting position (Fig. 2A). For estimating the elongated oral vocal tract length, we selected video single frames of roaring individuals where the larynx was at its maximally retracted position (Fig. 2B). We could not use single frame pairs during one roaring sequence to identify the highest and lowest respective positions of the larynx because the larynx rarely fully ascends between roars in quick succession.

Absolute vocal tract length estimation required introduction of an absolute measure into the body contours. For this we used the distance from the tip of the nose to the middle of the eye,

determined by skull size, which was 200 mm in both Specimen #1 and Specimen #2 (see below). The eye and the tip of the nose are easily identifiable in most of the video footage.

### Call samples and analyses

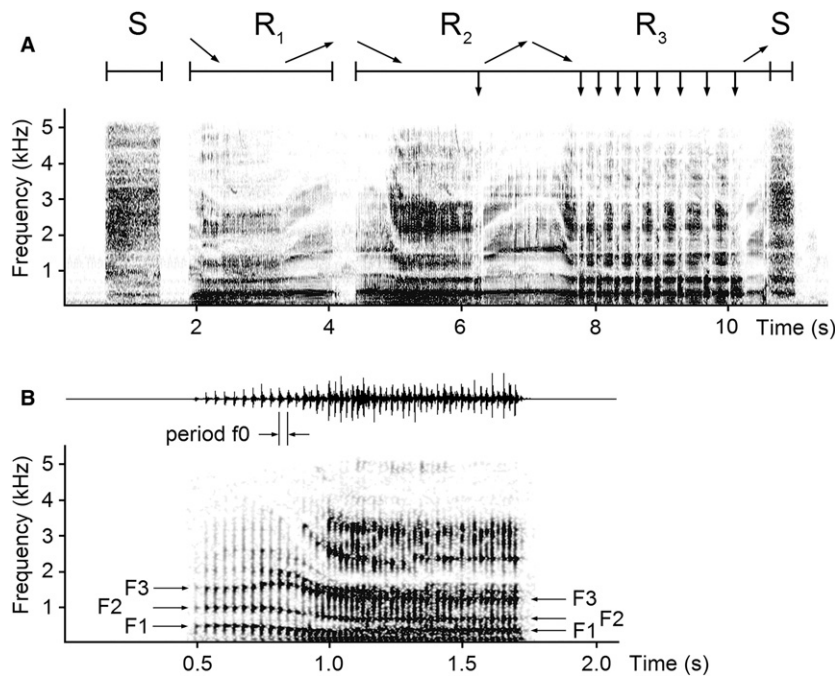
For creating call samples for acoustic analyses, we used Avisoft SASLAB PRO software (Avisoft Bioacoustics, Berlin, Germany). We checked the automatically recorded calls and selected 202 high-quality bouts of rutting calls with high signal-to-noise ratios, not disrupted by wind, overlapped by calls of other animals or clipped due to overmodulation. Of these 202 bouts, we further selected 72 bouts where the descending and ascending formant tracks acoustically reflected the downward and upward movements of the larynx during the roars (Fig. 3).

The 72 bouts were evenly selected over the entire rutting period and originated from seven recording places, separated from each other by distances of 0.5–12 km. This can be expected to decrease thoroughly potential pseudoreplication by repeatedly taking bouts of the same individual.

In one roar per bout we measured the fundamental frequency period (period  $f_0$ ) and the first three formants (F1–F3). The mean period  $f_0$  (i.e. the mean distance from a previous pulse to the following pulse) was measured from the screen with the standard marker cursor in the main window of Avisoft, displaying the spectrogram and the waveform (following Volodin et al. 2011, 2014). We used the following settings: Hamming window, FFT 512, frame 100%; frequency resolution of the spectrographic analysis was 43 Hz, time resolution varied between 0.3 and 0.5 ms, depending on call duration. We then calculated the mean  $f_0$  of each roar as the inversed value of the mean period  $f_0$  of the roar (Fig. 3).

The three first formants (F1, F2 and F3) were tracked with PRAAT at two portions within a roar, corresponding to the highest and the lowest position of the larynx during the roar: the portion with the highest formants and the portion with the lowest formants (Fig. 3). Formants were measured within call parts with nearly horizontal formants and their positions were verified by superposition on the narrowband spectrogram. Point values of formant tracks were extracted, exported to EXCEL (Microsoft Corp., Redmond, WA, USA) and the values of each formant for a given roar at both the highest and lowest positions of the larynx were calculated as the average values from the point values. The LPC-settings were Burg analysis, window length 0.04 s, time step 0.01 s, maximum number of formants 3–4. The upper limits of the frequency range of 1800–2000 Hz for the highest formants and of 1400–1700 Hz for the lowest formants were selected on the basis of the estimated lengths of the resting and maximally elongated vocal tract (Fig. 2, Supporting Information Table S1).

We used two different methods for calculating the formant dispersion (dF, the mean distance between neighbouring formants), to select the method providing the closest possible accordance with the oral vocal tract length estimates based on the anatomical dissections and based on the video single frames. Following Riede & Fitch (1999), we calculated dF as  $dF = (F3 - F1)/2$  for each roar, by applying the model of a straight uniform tube closed at one end. Following Reby & McComb (2003), we calculated dF for the average formant values of the roars using linear regression. Then, for each method, the lengths of the resting and elongated vocal tract were calculated by the equation: vocal tract length =  $c/2dF$ , where  $c$  is the speed of sound in air, approximated as  $350 \text{ ms}^{-1}$  (Fitch & Reby, 2001; Reby & McComb, 2003).



**Fig. 3** Male impala rutting calls: (A) spectrogram of a rutting bout comprising snorts (S) and roars ( $R_1$ – $R_3$ ) – a purely exhalatory roar (continuous roar,  $R_1$ ), an exhalatory roar with one interspersed inhalation (interrupted roar,  $R_2$ ) and a roar with rapidly repeated ex- and inhalations (pant roar,  $R_3$ ). Calls and between-call intervals within this bout are demarcated by the sections above ( $R_2$  turns into  $R_3$  without interval). The inclined arrows indicate the downward and upward movements of the larynx during the roars; the vertical down arrows indicate the inspiratory phases of roaring. The spectrogram was created with sampling frequency 11.025 kHz, Hamming window, Fast Fourier Transform (FFT) 512, frame 50% and overlap 75%. (B) Spectrogram (below) and waveform (above) of a continuous roar taken from a different bout. The formants (F1, F2, F3) at the start and end of the roar reflect the movements of the larynx from its uppermost position to its maximally retracted position. Period  $f_0$  – the fundamental frequency period of the roar. The spectrogram was created with sampling frequency 11.025 kHz, Hamming window, FFT 512, frame 50% and overlap 93.75%. An audio file with an example rutting bout and a continuous roar is available as Supporting Information Audio S1.

### Computer tomographic investigation

The deep frozen head and neck of Specimen #1 were scanned in a 64-slice spiral Computer Tomograph (CT) Aquilion CX (Toshiba Medical Systems Corp., Tochigi, Japan) at the IZW. The postmortem *in situ* positions of the vocal organs were registered in black and white virtual serial sections (MPRs) and in 3D-reconstructions with VITREA 2 software (Toshiba Medical Systems Corp., Shimoshigami, Japan) and Osirix 64-bit mac (Pixmeo Sàrl, Bernex, Switzerland). These data were compared with the postmortem *in situ* positions of the vocal organs of Specimen #2 and used to reconstruct the resting state of the vocal apparatus in the video single frame pairs. A 3D-reconstruction of the excised left half of the larynx of Specimen #1 was made with VITREA 2 software to illustrate the spatial structure of the vocal keel.

### Anatomical investigation

Specimen #1 was dissected using the in-water-method (Frey & Hofmann, 2000; Frey et al. 2018). Specimen #2 was dissected in air on a metal table. Both dissections involved overnight cooling in a refrigerator. For Specimen #1, the consecutive dissection steps were photographed with a Nikon D70S digital camera (Nikon Corp., Tokyo, Japan) on Compact Flash cards. For Specimen #2, the dissection steps were photographed using a Panasonic Lumix DMC-FZ72 digital camera (Panasonic Corporation, Kadoma, Osaka, Japan) on

SDXC memory cards. The images were fed to a PC and graphically processed (Adobe PHOTOSHOP 5.5 and CS4) to identify the individual components of the vocal organs, including the associated muscles, and to clarify mutual anatomical relationships.

The lengths of the individual parts of the hyoid apparatus of both specimens were measured along the respective centre lines (Supporting Information Table S2). The right larynx half of Specimen #1 and the left larynx half of Specimen #2, including the intrinsic laryngeal muscles, were separately dissected in detail and photographed. In addition, the right larynx half of Specimen #2 was frontally cut in five macroscopical sections and their rostral and caudal surfaces were photographed (Fig. 22).

The skeletal parts, the hyoid apparatus and the dissected larynges of both specimens were stored in the morphological collection of the IZW. Anatomical terms are in accordance with *Nomina Anatomica Veterinaria* (NAV, 2005, 2012) and Constantinescu & Schaller (2012).

### Histological investigation

For investigation of the peculiar vocal keel of male impala, frontal and sagittal samples of the macroscopic sections 2–5 of the right larynx half were taken and processed histologically (Fig. 26). We used Haematoxylin-Eosin staining for a general overview, Azan staining for collagen fibres and Elastica Van Gieson staining for elastic fibres. Photographs of representative histological slides were taken with a Keyence VHX-5000 Digital Microscope (Keyence Deutschland, Neu-

Isenburg, Germany) using a VH-Z00R, RZ-50, Zoom 5-50x lens. Adobe PHOTOSHOP version CS4 was used to process the images.

### Graphical reconstructions and 2D-model

To document the typical calling posture, we selected video single frame pairs, where the larynx was in its high resting position and in its low, maximally retracted position during the roars, respectively. Externally visible landmarks (mouth opening, nostrils, eye, laryngeal prominence, ear base, angle of the lower jaw, hyoid prominence, rostral end of the sternum) were used to reconstruct graphically the positions of the skull, the hyoid apparatus, the larynx, the rostral thorax and vocal tract length in the resting and maximally retracted state. Related soft tissue structures (pharynx, muscles, etc.) were gradually added to obtain a comprehensive reconstruction of both the resting and maximally extended state of the vocal organs. We thus obtained two overlays of the anatomical structures involved in the production of the rutting roars: the first for the resting, pre-roaring posture and the second for the extended, roaring posture. These two overlays integrate video information of the vocal postures of live rutting impala males and different larynx positions, the CT investigation of Specimen #1 and the results of the anatomical dissections of Specimens #1 and #2. Combined with video documentation of calling behaviour, this overlay pair, each overlay separated into four successive layers for improving clarity, provided a 2D model illustrating the potential mechanisms of the pronounced roar-synchronous downward and upward movements of the larynx and of concomitant tongue protrusion (Fig. 27).

### Abbreviations

Adit. lar.	Aditus laryngis	Laryngeal entrance
App. hyo.	Apparatus hyoideus	Hyoid apparatus
Arc. cart. cric.	Arcus cartilagineus cricoideae	Cricoid arc
Arc. palatphar.	Arcus palatopharyngeum	Palatopharyngeal arc
Art. cricaryt.	Articulatio cricoarytenoidea	Cricoarytenoid articulation
Art. crithyr.	Articulatio cricothyroidea	Cricothyroid articulation
Bas. epigl.	Basis epiglottica	Base of the epiglottis
Basih.	Basihyoideum	Basihyoid
Bul. thy.	Bulla thyroidea	Thyroid bulla
Car. voc.*	Carina vocalis	Vocal keel
Cart. aryt.	Cartilago arytenoidea	Arytenoid cartilage
Cart. cric.	Cartilago cricoidea	Cricoid cartilage
Cart. epigl.	Cartilago epiglottica	Epiglottic cartilage
Cart. thy.	Cartilago thyroidea	Thyroid cartilage
Cav. infrglott.	Cavum infraglotticum	Infraglottic cavity
Ceratoh.	Ceratohyoideum	Ceratohyoid
conn. tissue		Connective tissue
Cont. M.	Contura M.	Contour of M.
thyraryt.	thyroarytenoideae	thyraryt.
Corn. caud.	Cornu caudale	Caudal horn
Corn. rostr.	Cornu rostrale	Rostral horn
Epigl.	Epiglottis	Epiglottis
Epih.	Epihyoideum	Epihyoid
Fac. art.	Facies articularis	Articular surface (for Cart. cric.)
For. thy.	Foramen thyroideum	Thyroid foramen
Gl. thy.	Glandula thyroidea	Thyroid gland
Gll. lar.	Glandulae laryngeae	Laryngeal glands

(continued)

Ham. pteryg.	Hamulus pterygoideus	Pterygoid hamulus
Incis. thy.	Incisura thyroidea rostralis	Rostral thyroid notch
Intsect. tend.	Intersectio tendineae	Tendinous intersection
IPO	Ostium intrapharyngeum	Intra-pharyngeal ostium
IT		Tendinous intersection (inset)
Lam. cart. cric.	Lamina cartilagineus cricoideae	Lamina of cricoid cartilage
Lam. cart. thy.	Lamina cartilagineus thyroideae	Lamina of the thyroid cartilage
Lar.	Larynx	Larynx
lat. space		Lateral space
Lig. arycorn.	Ligamentum arycorniculatum	Arycorniculate ligament
Lig. aryt. transv.	Ligamentum arytenoideum transversum	Transverse arytenoid ligament
Lig. voc.	Ligamentum vocale	Vocal ligament
Lig. crithyr.	Ligamentum cricothyroideum	Cricothyroid ligament
Lig. thyroh.	Ligamentum thyrohyoideum	Thyrohyoid ligament
Ling.	Lingua	Tongue
Membr. thyroh.	Membrana thyrohyoidea	Thyrohyoid membrane
Muc. lar.	Mucosa laryngis	Laryngeal mucosa
M. aryt. transv.	Musculus arytenoideus transversus	Transverse arytenoid muscle
M. cricaryt. dors. dexter	Musculus cricoarytenoideus dorsalis dexter	(Right) Dorsal cricoarytenoid muscle
M. cricaryt. lat.	Musculus cricoarytenoideus lateralis	Lateral cricoarytenoid muscle
M. crithyr.	Musculus cricothyroideus	Cricothyroid muscle
M. genioh.	Musculus geniohyoideus	Geniohyoid muscle
M. hyoepigl.	Musculus hyoepiglotticus	Hyoepiglottic muscle
M. myloh.	Musculus mylohyoideus	Mylohyoid muscle
M. occiph.	Musculus occipitohyoideus	Occipitohyoid muscle
M. omoh.	Musculus omohyoideus	Omohyoid muscle
M. palat.	Musculus palatinus	Palatine muscle
M. palatphar.	Musculus palatopharyngeus	Palatopharyngeal muscle
M. sternoh. (dex.)	Musculus sternohyoideus (dexter)	(Right) Sternohyoid muscle
M. sternthyr.	Musculus sternothyroideus	Sternothyroid muscle
M. styloh.	Musculus stylohyoideus	Stylohyoid muscle
M. thyraryt.	Musculus thyroarytenoideus	Thyroarytenoid muscle
M. thyroh.	Musculus thyrohyoideus	Thyrohyoid muscle
Mm. constr. phar. caud.	Musculi constrictores pharyngis caudales	Caudal pharyngeal constrictor muscles
Nasophar.	Nasopharynx	Nasal part of pharynx
N. hypogl.	Nervus hypoglossus	Hypoglossal nerve
Orophar.	Oropharynx	Oral part of pharynx
OCH		Occipitohyoid muscle (inset)
Oesoph.	Oesophagus	Oesophagus
OMH		Omohyoid muscle (inset)
Palat. mol.	Palatum molle	Soft palate (velum)
Plic. aryepigl.	Plica aryepiglottica	Aryepiglottic fold
Plic. voc. (dex., sin.)	Plica vocalis (dextra, sinistra)	(Right, left) Vocal fold
Proc. corn.	Processus corniculatus	Corniculate process
Proc. med.	Processus medialis	Medial process

(continued)

Proc. musc.	Processus muscularis	Muscular process
Proc. voc.	Processus vocalis	Vocal process
Rec. pirif.	Recessus piriformis	Piriform recess
roof Nasophar.		Roof of the nasopharynx
SH		Sternohyoid muscle (inset)
ST		Sternothyroid muscle (inset)
STH		Stylohyoid muscle (inset)
Styloh.	Stylohyoideum	Stylohyoid
TH		Thyrohyoid muscle (inset)
Thyroh.	Thyrohyoideum	Thyrohyoid
Trach.	Trachea	Trachea
Tub. corn.	Tuberculum corniculatum	Corniculate tubercle
Vest. lar.	Vestibulum laryngis	Laryngeal vestibule
1. Cart. trach.	1. Cartilago tracheae	1. Tracheal cartilage

\* Newly created term to designate the peculiar uniform complex of canonical vocal fold plus arytenoid cartilage in male impala.

## Results

### Rutting behaviour


Male impala frequently emitted their bouts of rutting vocalisations while defending one or several females against rival males. Rutting activities mostly occurred in areas with vegetation cover, between shrubs and trees, but sometimes also on open areas, allowing video recording. Fights between males and intense stabbing of the ground with their horns by single males were often observed and documented on video. Both behaviours might explain why some males had one or two broken horns.

### Vocal posture

Impala males produced their bouts of rutting calls in a low-stretch posture, i.e. head and neck were extended and kept in a low, horizontal position, with nostrils widely opened and tongue frequently protruded (Fig. 4). The hyoid prominence, indicating the position of the basihyoid, and the larynx prominence, indicating the position of the bulla of the thyroid cartilage, were externally visible (Fig. 4).

### Larynx position and tongue protrusion

According to CT images and dissection photographs, the resting position of the larynx was at the level of the first cervical vertebra or slightly lower. At roar-synchronous larynx retraction and vocal tract extension, the larynx descends to its lower position in the upper third of the ventral neck region. In this stage, reconstructions of the vocal organs (see below) suggest a larynx position at the level of the second and third cervical vertebra. The larynx re-ascends to its resting position, at the end of a roaring bout (Fig. 5), but larynx ascent between roars within a bout may be



**Fig. 4** Low-stretch vocal posture of roaring male impala. The indicated landmarks were used for reconstruction of the vocal organs and their associated musculature.

incomplete. Often, but not always, males protrude the tongue while emitting their rutting roars (Figs 4 and 5).

In the videos, the larynx in its resting position was visible externally as a small prominence at about 50 mm ventral to the angle of the lower jaw. During roar-synchronous vocal tract extension, the larynx partly slides into the cleft between left and right ventral neck muscles, thus decreasing its external visibility. The distance from the laryngeal prominence to the rostral tip of the sternal manubrium was about 350 mm (Figs 4 and 5).

### Vocal tract length estimates in video single frames

The absolute measure used for estimating vocal tract length in video single frame pairs was the distance from the middle of the eye to the tip of the nose that had been consistently ascertained to be 200 mm in Specimen #1 and Specimen #2. Estimation of the vocal tract length in video single frames yielded an average resting vocal tract length of  $292.8 \pm 3.1$  mm ( $n = 12$  estimates, three males) and an average maximally extended vocal tract length of  $400.8 \pm 6.6$  mm ( $n = 15$  estimates, three males) (Table S1). The maximal vocal tract elongation was 108.0 mm, or approximately 37% (Table S1).

### Acoustic correlates of larynx retraction

Bouts of rutting calls included nasal snorts and oral roars, comprising continuous, interrupted and pant roars (Fig. 3). Snorts were explosive noisy calls without visible  $f_0$ . The roars were broadband low-frequency tonal calls with visible pulses of  $f_0$ . The mean  $f_0$  of the roars ( $n = 72$ , one per bout) was  $50.0 \pm 4.6$  Hz. The snorts were always produced at expiration, whereas the roars could be produced solely at expiration [continuous roars, interspersed with few inspirations (interrupted roars) or at rapidly alternating ex- and inspirations (pant roars; Fig. 3)]. In the latter case, roar



**Fig. 5** Mobile larynx in male impala during emission of the rutting roars. From its resting position just below the lower jaw (A), the larynx is forcefully retracted down towards the sternum for about one-third of the neck length (B). From this maximally retracted position, the larynx gradually ascends while roaring emission proceeds (C–E) until it again reaches the resting position at the end of roaring (F). Roars are produced without lip rounding, the tongue is protruded and the nostrils are widely open.

duration was not constrained by the volume of exhaled air. The substantial variation in roar duration was not considered in this study. A detailed description and analysis of the different roar types of impala will be presented elsewhere.

We selected 72 roars of superb quality from 72 different bouts, in which measurement of the formants was possible at the two extremes of vocal tract length: (1) at the shortest vocal tract length (corresponding to the resting position of the larynx or close to it) and (2) at the maximally elongated vocal tract length (corresponding to the most retracted position of the larynx) (Fig. 3). To this end, we selected two nearly horizontal portions from each roar spectrogram, the one with the highest formants and the one with the lowest formants, corresponding to the highest and lowest larynx positions, and tracked the three first formants along these two parts of a roar. These values served to calculate formant dispersion (dF) and then oral vocal tract length (vtl) at the highest and lowest positions of the larynx during the roars (Table 1).

Calculation from formant dispersion by the dividing method (Riede & Fitch, 1999) yielded a resting oral vocal tract length of 297.2 mm and a maximally extended oral vocal tract length of 388.3 mm (Table 1). Thus, according to the dividing method, roar-synchronous larynx retraction in male impala produced an extension of the oral vocal tract by 91.1 mm (31%).

Calculation from formant dispersion by the regression method (Reby & McComb, 2003) yielded a resting oral vocal tract length of 276.5 mm and a maximally extended oral vocal tract length of 342.5 mm (Table 1). Thus, according to the regression method, roar-synchronous larynx retraction in male impala produced an extension of the oral vocal tract by 66 mm (24%). Therefore, the value of oral vocal tract extension calculated by the dividing method (Riede & Fitch, 1999) was rather close to that estimated in video single frame pairs (108 mm, 37% vtl extension), whereas the degree of oral vocal tract extension calculated by the regression method (Reby & McComb, 2003) was substantially less.



**Table 1** Values (mean  $\pm$  SD) of the three first formants (F1, F2, F3) of male impala rutting roars, the formant dispersion (dF) and the vocal tract length (vtl) calculated on the basis of formant dispersion. Roar portions with the highest and lowest formants within roars ( $n = 72$ ) corresponded to the shortest vocal tract length (highest larynx position) and the longest vocal tract length (lowest, maximally retracted larynx position). Formant dispersion was calculated following two methods: the dividing method (Riede & Fitch, 1999) and the linear regression method (Reby & McComb, 2003).

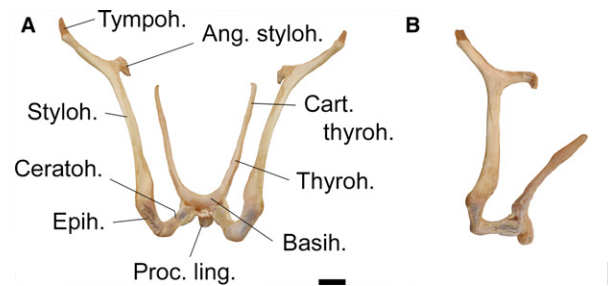
Variable	Formants at highest position	Formants at lowest position
F1 (Hz)	408 $\pm$ 46	354 $\pm$ 25
F2 (Hz)	906 $\pm$ 65	761 $\pm$ 52
F3 (Hz)	1591 $\pm$ 63	1261 $\pm$ 69
dF (Hz), dividing method	592 $\pm$ 39	454 $\pm$ 37
vtl (mm), dividing method	297.2 $\pm$ 19.9	388.3 $\pm$ 31.5
dF (Hz), regression method	633	511
vtl (mm), regression method	276.5	342.5

### Hyoid apparatus

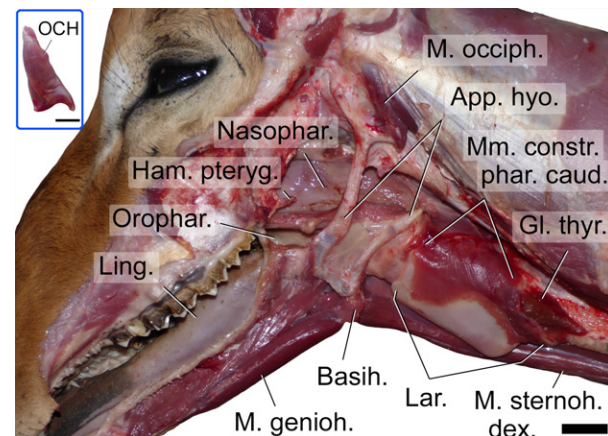
The hyoid apparatus consists of the hyoid in the strict sense, which rostrally connects to the tongue through the unpaired basihyoid and caudally, via the paired thyrohyoids, to the larynx. The connection to the skull is achieved by a double suspension consisting of the paired cerato-, epi-, stylo- and tympanohyoids. The cerato-, epi- and stylohyoids are ossified, whereas the tympanohyoids are cartilaginous (Fig. 6). Ventrally, the basihyoid has a prominent lingual process. Together with the basihyoid, the thyrohyoids form sort of a V-shaped osseous fork, which fixes the rostral part of the larynx between its prongs. The caudal third of the thyrohyoids is cartilaginous and thus more flexible. Both the osseous and the cartilaginous part of the thyrohyoids are connected to the rostral edge of the thyroid cartilage by a resilient thyrohyoid membrane. Dorsally, towards the tip of the thyrohyoid, the thyrohyoid ligament (see below) blends into the thyrohyoid membrane. In the *in situ* position, the hyoid apparatus appears as a hook-like structure with multiple connections to the skull dorsally, the pharynx laterally, the tongue and oral cavity rostrally and the larynx and sternum caudally. The occipitohyoid muscle terminates dorsally on the tip of the stylohyoid angle (Fig. 7). For the lengths of the individual parts, see Table S2.

### Thyrohyoid ligament

In addition to the thyrohyoid membrane, the connection between the hyoid apparatus and the larynx is established by a paired thyrohyoid ligament. On each side this extends between the cartilaginous end of the thyrohyoid and the rostral horn of the thyroid cartilage. The resting length was around 15 mm; its length at maximal artificial extension in



**Fig. 6** Hyoid apparatus of an adult male impala. (A) Rostral view; (B) left lateral view. Scale bars: 10 mm.



**Fig. 7** Hyoid apparatus and occipitohyoid muscle of an adult male impala. Inset: the excised occipitohyoid muscle. Left lateral view. Scale bar: (main figure) 20 mm; (inset) 10 mm.

the excised hyoid apparatus and larynx was about 50 mm (Figs 11, 14 and 15). The maximally extended length during larynx retraction was estimated in the reconstruction of the extended vocal tract using video single frames taken from footage of live individuals. Here, the maximally extended length of the thyrohyoid ligament was about 45 mm.

### Muscles involved in larynx retraction and vocal tract extension

#### Occipitohyoid muscle

In addition to the tympanohyoid, the small occipitohyoid muscle establishes a second, muscular connection between the hyoid apparatus and the skull. This fusiform muscle originates from the curved caudal edge of the paracondylar process of the occipital bone and terminates on the caudal tip of the stylohyoid angle, where it covers the origin of the stylohyoid muscle (Fig. 7).

#### Omohyoid muscle

The omohyoid muscle establishes a connection between the hyoid apparatus and the cervical spine. This muscle originates from the deep neck fascia lateral to cervical vertebrae

2–5, courses obliquely over the strap muscles in cranial direction and terminates on the basihyoid, where it covers the termination of the sternohyoid muscle (Fig. 8).

*Sternothyroid, sternohyoid and thyrohyoid muscles*

These so-called strap muscles connect the larynx to the sternum and to the hyoid apparatus. In addition, they establish a connection between the sternum and the hyoid apparatus. The long, strap-like muscles comprise the sternothyroid muscle, the thyrohyoid muscle and the sternohyoid muscle. The caudal portions of the sternothyroid and sternohyoid muscles are fused from their origin at the sternal manubrium up to a tendinous intersection at the level of the 4th–5th cervical vertebrae, approximately. From the tendinous intersection onwards, the sternothyroid and sternohyoid portions diverge. The sternothyroid portion goes to the larynx and terminates on the caudal edge of the thyroid cartilage. The sternohyoid portion goes to the hyoid apparatus and terminates on the basihyoid. The thyrohyoid muscle originates from the thyroid cartilage at the termination of the sternothyroid muscle and goes to the hyoid apparatus, where it terminates on the thyrohyoid (Fig. 9). The thyroid cartilage of the larynx protrudes ventrally between left and right sternohyoid muscles and causes a slight bulging of the skin, which is externally visible.

*Stylohyoid muscle*

The stylohyoid muscle connects the stylohyoid angle to the basihyoid. This muscle originates ventrally from the tip of the stylohyoid angle by a slender tendon that comprises about one-quarter of the entire muscle length. The fusiform muscle belly is single and terminates on the basihyoid (Fig. 10).

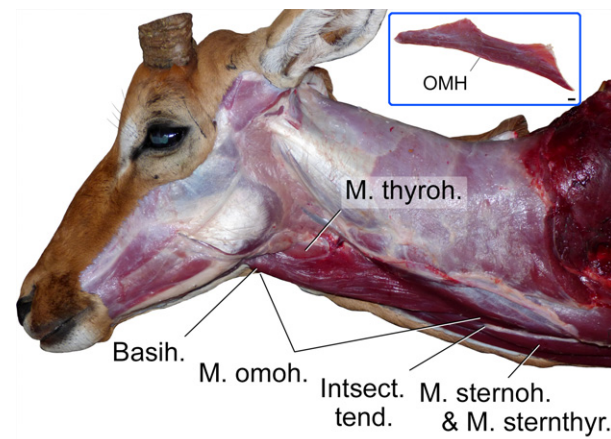
*Hyoepiglottic muscle*

This V-shaped muscle establishes a mid-ventral muscular connection between the larynx and the hyoid apparatus.

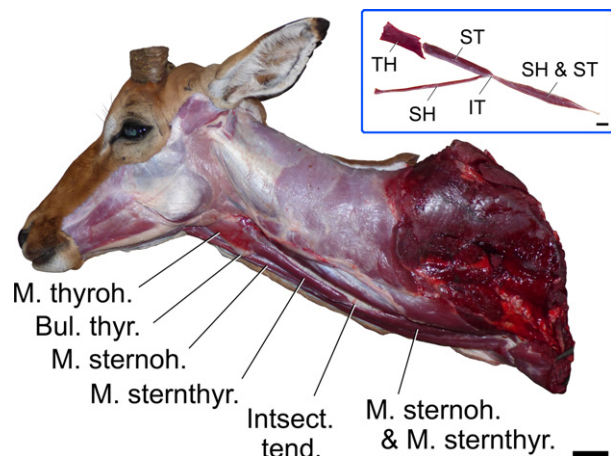
The hyoepiglottic muscle has a bifurcated origin rostrally, from the ceratohyoids and the basihyoid, but then merges and continues as a single bundle towards its termination on the rostroventral surface of the epiglottis. After the excision of the connected hyoid apparatus and larynx, the hyoepiglottic muscle can be artificially extended to double its resting length (Fig. 11).

**Soft palate and intra-pharyngeal ostium**

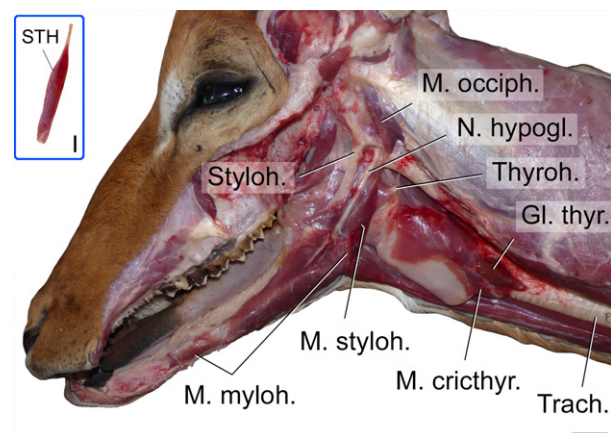
The soft palate completely separates the nasal portion of the pharynx (dorsally) from the oral portion of the pharynx (ventrally), except at the intra-pharyngeal ostium, an opening in the soft palate across which both parts communicate. The caudal edge of the intra-pharyngeal ostium, i.e. the caudal end of the pharynx wall including the vestibule of the oesophagus, is fixed to the larynx by connective tissue and by the caudal constrictor muscles of the pharynx. The resting length of the soft palate, from the choanae to the



**Fig. 8** Omohyoid muscle of an adult male impala. Inset: the excised omohyoid muscle. Left lateral view. Scale bar: (main figure) 20 mm; (inset) 10 mm.



**Fig. 9** Strap muscles of an adult male impala. Inset: the excised strap muscles. Left lateral view. Scale bar: (main figure) 40 mm; (inset) 20 mm.



**Fig. 10** Stylohyoid muscle of an adult male impala. Inset: the excised stylohyoid muscle. Left lateral view. Scale bar: (main figure) 20 mm; (inset) 10 mm.

rostral edge of the intra-pharyngeal ostium, is 65 mm. The edge of the intra-pharyngeal opening is not noticeably specialised; its dimensions are 18 mm (rostrocaudal length)  $\times$  15 mm (transverse width).

The palatopharyngeal arc, a mucosal fold along the circumference of the intra-pharyngeal ostium surrounding the laryngeal entrance during quiet respiration, is thick and prominent, and the palatopharyngeal muscle appears to be strong (Fig. 12A). The mucosa of the nasal part of the pharynx that is merging into the caudal edge of the intra-pharyngeal ostium, and the palatopharyngeal arc are finely plicated (Fig. 12B).

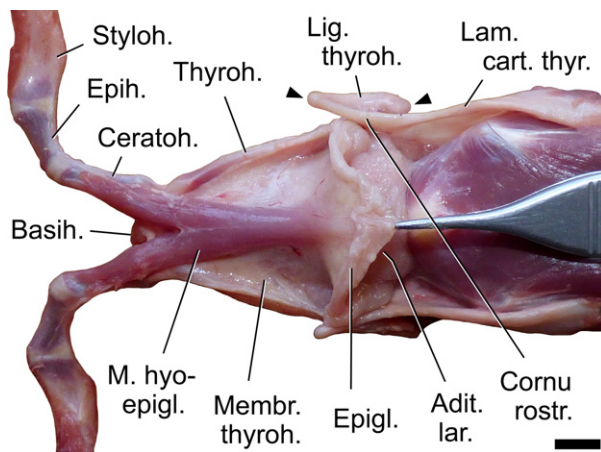
## Larynx and vocal folds

### Larynx overall view

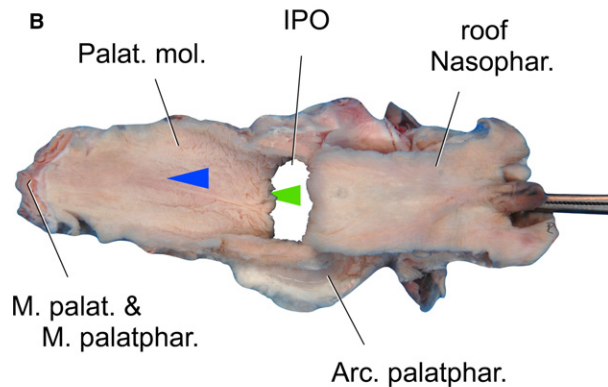
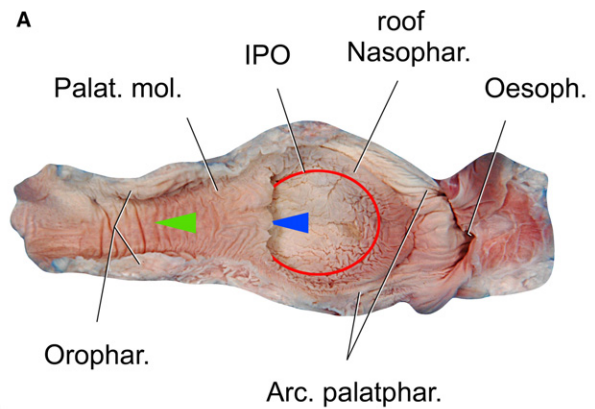
The larynx possesses a moderate thyroid bulla, i.e. the caudal part of the thyroid cartilage bulges out ventrally beyond the tip of the cricoid arch. As a consequence, the cricoid cartilage (and the cricothyroid muscle) take on very oblique positions – about 45° relative to the longitudinal axis of the trachea (Fig. 13). The overall length of the larynx was 101/105 mm, the maximal height 45/45 mm and the maximal transverse width 39/45 mm ( $n = 2$ ).

### Laryngeal entrance

A characteristic feature of the laryngeal entrance of impala is a prominent, thin and flexible aryepiglottic fold (Fig. 14). The region of the laryngeal entrance, comprising the epiglottis, the aryepiglottic folds, the ventral epiglottis/thyroid cartilage-connection up to the level of the corniculate processes of the arytenoid cartilages dorsally, can be considerably extended. Ventrally and laterally, the laryngeal



**Fig. 11** Hyoepiglottic muscle of an adult male impala. Hyoid apparatus and larynx are still connected and the epiglottis is caudally retracted with forceps. The hyoepiglottic muscle is relatively short and its origin is rostrally bifurcated, extending from the ceratohyoids and the basihyoid to the rostral surface of the epiglottis. The two arrowheads mark the attachments of the thyrohyoid ligament. Dorsal view. Scale bar: 10 mm.

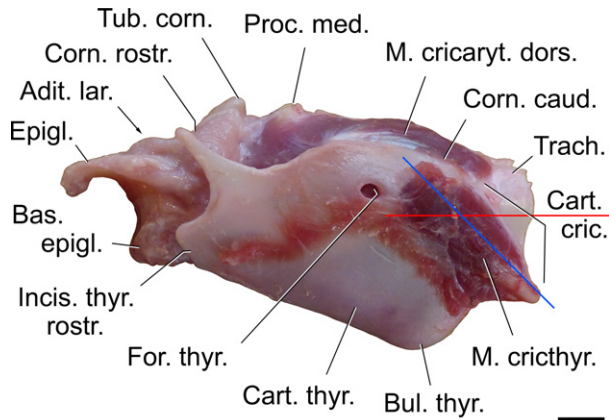


**Fig. 12** Soft palate of an adult male impala: (A) ventral view; (B) dorsal view. The palatopharyngeal arc, a mucosal fold surrounding the intra-pharyngeal ostium and locking the laryngeal entrance inside the nasopharynx during quiet respiration, is prominent. Rostral is to the left. Blue arrowhead indicating nasopharynx points towards the nostrils; green arrowhead indicating oropharynx points towards the mouth opening. Scale bar: 10 mm.

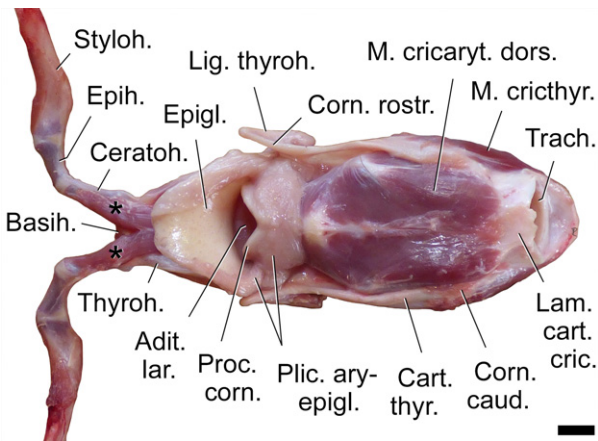
entrance is engirded by the thyrohyoid membrane plus the thyrohyoid ligament, which both have a similar resilience (Fig. 15).

### Laryngeal cartilages

The shape and relative size of the laryngeal cartilages are presented in Fig. 16. The epiglottis is comparably small; its dorsoventral height and rostrocaudal length are approximately the same. In the two dissected specimens the epiglottis was not engaged in the intra-pharyngeal ostium but resided, ventrally adjacent to it, in the oropharynx. The thyroid cartilage has a moderate caudoventral thyroid bulla to the inside of which the vocal ligament and fibres of the thyroarytenoid muscle attach. The ventral contour of the arytenoid cartilage is uniformly convex from the corniculate process up to the broad vocal process (Fig. 17). Thereby, the intermediate surface, ventral to the medial and muscular



**Fig. 13** Larynx of an adult male impala. Caudoventrally, the larynx has a moderate thyroid bulla. The cricoid cartilage and the cricothyroid muscle are very obliquely oriented. Red line: longitudinal axis of the trachea; blue line: longitudinal axis of cricothyroid muscle and cricoid arc. Left lateral view. Scale bar: 10 mm.

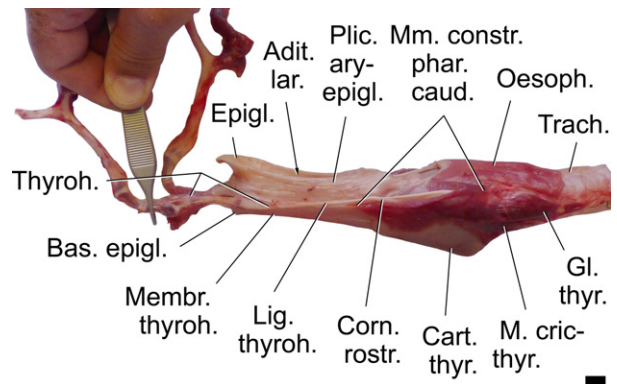


**Fig. 14** Laryngeal entrance of an adult male impala. The thin and flexible aryepiglottic fold is very prominent. Two asterisks: the double origin of the hyoepiglottic muscle. Dorsal view. Scale bar: 10 mm.

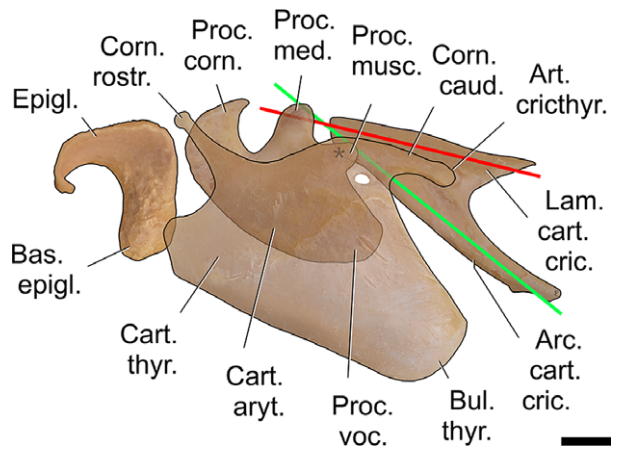
processes, is of considerable dorsoventral height, serving as an extended site of termination of the thyroarytenoid muscle laterally and as a surface of attachment for the mucosa of the vocal keel medially (see below). Laterally, below the muscular process, there is an additional smaller prominent knob on which caudal fibres of the thyroarytenoid muscle terminate (Fig. 17). Owing to the presence of a thyroid bulla, the arch of the cricoid cartilage is bent dorsocaudally. The angle between the long axes of the cricoid lamina and the cricoid arch is about 25° (Fig. 16).

*Vocal folds*

The ‘vocal folds’ of male impala stand out because of their unusual structure, large volume and massive shape (Figs 18 and 19). They occupy almost the entire laryngeal cavity and are set in a very oblique position. Their orientation relative to the longitudinal axis of the trachea is about 150° (central



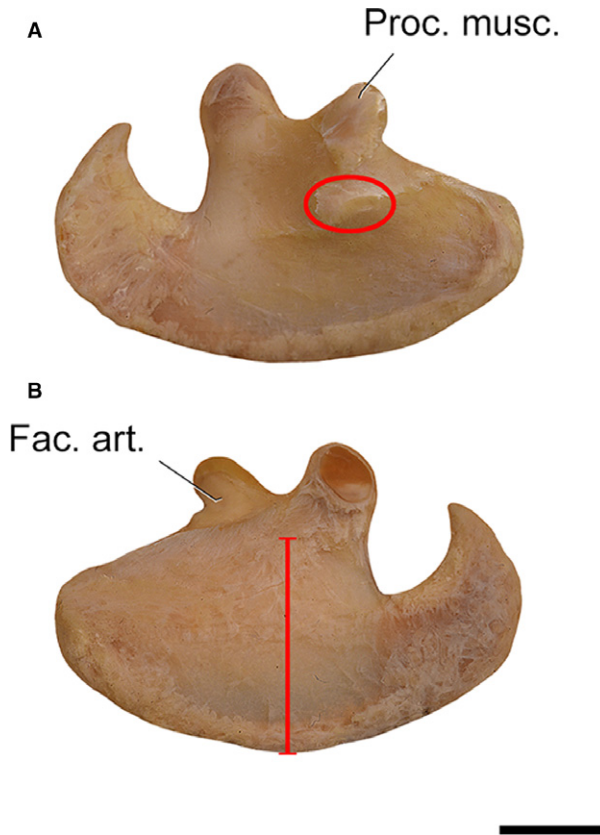
**Fig. 15** Artificial extension of the laryngeal entrance of an adult male impala demonstrating its remarkable resilience. The hyoid apparatus is still connected with the larynx. The trachea was fixed and pull was exerted on the left ceratohyoid. Left lateral view. Scale bar: 10 mm.



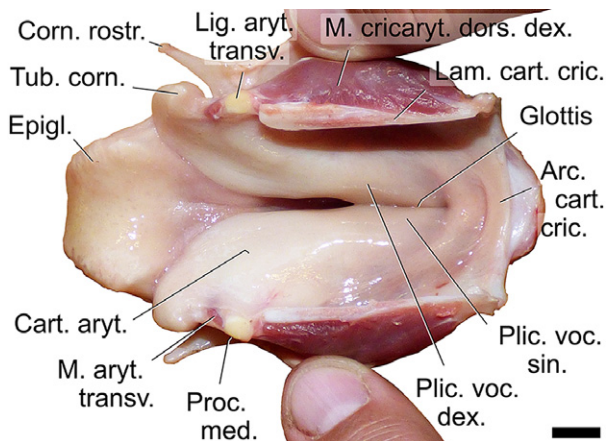
**Fig. 16** Overlay of the laryngeal cartilages of an adult male impala, assembled close to *in situ* positions; the thyroid cartilage has a moderate thyroid bulla and the vocal process of the arytenoid cartilage is broad and ventrally extended; asterisk: cricoarytenoid articulation; the arch of the cricoid cartilage is bent caudodorsally; the angle between the cricoid lamina and the cricoid arch is ≈ 25° (between red and green line). Left lateral view. Scale bar: 10 mm.

axis) or 155° (ventral edge) caudoventrally to rostror dorsally (Fig. 20). However, what at first glance appears as the ‘vocal fold’ is not a vocal fold in the canonical sense, for the following reasons.

A canonical vocal fold extends between the inner caudodorsal surface of the thyroid cartilage and the cricothyroid ligament and the vocal process of the arytenoid cartilage and, typically, there is a pronounced angle between the longitudinal axis of the arytenoid cartilage and the vocal fold. Yet, in adult male impala, an arytenoid cartilage and the corresponding vocal fold in the canonical definition form one entity with a common longitudinal axis. There is no distinct angle between the longitudinal axes of the arytenoid cartilage and of the vocal fold.

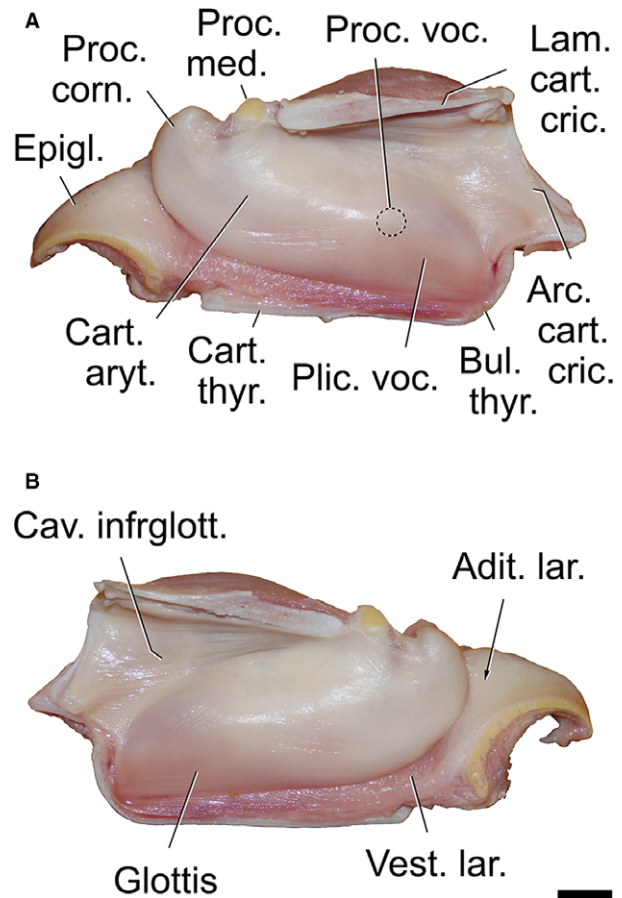


**Fig. 17** Left arytenoid cartilage of an adult male impala: (A) lateral view, (B) medial view. The red ellipse marks the prominent knob below the muscular process on which caudal fibres of the thyroarytenoid muscle terminate. The vertical red bar indicates the considerable dorsoventral height of the arytenoid body. Scale bar: 10 mm.



**Fig. 18** The bulky 'vocal folds' of an adult male impala. The larynx has been opened dorsally along the mid-sagittal plane and the thyroid laminae are pulled laterally. Dorsal view. Scale bar: 10 mm.

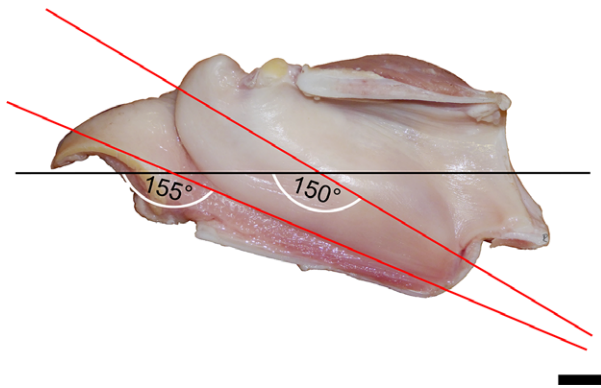
Rostrally, the ventral contour of a vocal fold continues into the ventral contour of the corresponding corniculate process along a straight line without any visible discontinuity (Figs 19–21). The rostrocaudal length of this entire



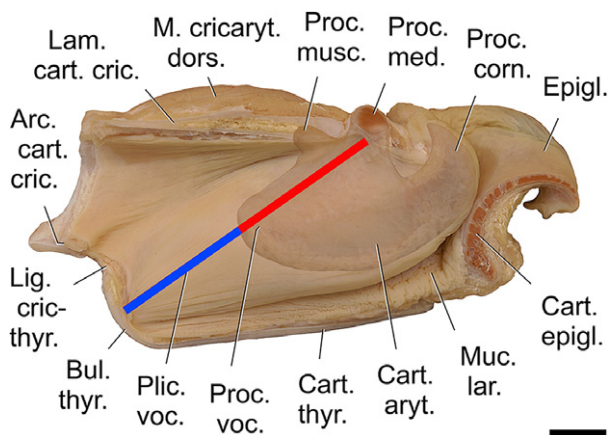
**Fig. 19** Right (A) and left (B) 'vocal fold' of an adult male impala. The arytenoid cartilage with its mucosal cover and the conventional vocal fold form an entity. These unusual bulky vocal keels occupy almost the entire space of the laryngeal cavity. The broken circle marks the position of the vocal process of the arytenoid cartilage. Scale bar: 10 mm.

complex is 70 mm and its dorsoventral height is 26 mm. Caudal attachment of this complex is to the inner surface of the thyroid bulla and the cricothyroid ligament. To reflect this remarkable structure of the sound source terminologically and to distinguish it from the canonical vocal fold, we created a new term for the entire complex (arytenoid cartilage plus canonical vocal fold): vocal keel, or *Carina vocalis* (because the complex resembles the long keel of a sailing boat).

As a consequence of the peculiar structure, measurement of the canonical vocal folds of male impala is not straightforward. The position of the vocal process must first be ascertained by palpation prior to the measurement and then the conventional dimensions can be estimated: maximal rostrocaudal length of the canonical vocal folds (along the glottis) is 25 mm, maximal dorsoventral length 20 mm, and maximal transverse width 8–9 mm (in their dorsal third, close to the vocal process of the arytenoid cartilage).



**Fig. 20** Very oblique orientation of the right vocal keel of an adult male impala. The bulky, uniform structure, from the bottom of the thyroid bulla up to the corniculate process, is set against the longitudinal axis of the trachea at an angle of about 150° (central axis) or about 155° (ventral edge). Medial view. Scale bar: 10 mm.



**Fig. 21** Overlay of the left vocal keel and arytenoid cartilage of an adult male impala. There is no distinct angle between the longitudinal axes of the arytenoid cartilage and the canonical vocal fold. The ventral contour of the canonical vocal fold continues into the ventral contour of the corniculate process along a straight line without any visible discontinuity. Blue-red bar: glottis, blue: intermembranous part, red: intercartilaginous part. Medial view. Scale bar: 10 mm.

Another unusual structure of the sound source consists in a free space between the lateral surface of the vocal keel and the wall of the laryngeal cavity. This lateral space extends furrow-like from the edge of the corniculate process rostrally up to the caudal end of the vocal keel. Maximal dorsal extension, from the ventral edge of the vocal keel to the apex of the furrow, is 15 mm at the level of the medial process of the arytenoid cartilage. From there, the lateral space fades steadily in a caudal direction (Figs 22 and 23). Lateral and ventral to the vocal keels this lateral space is lined with a reddish, soft and flabby mucous membrane.

Probably related to the existence of a lateral space and the correspondent folding of the laryngeal mucosa, there is

a pronounced medioventral curving of thyroarytenoid muscle fibres down into that fold, up to their termination on the extended lateral surface of the arytenoid cartilage (Fig. 22, Supporting Information Figs S1 and S2).

Along the region of the canonical vocal fold, i.e. between the vocal process and the thyroid cartilage, extends a thick whitish structure, spindle-shaped in cross-section, which we consider to be a vocal ligament. Its medial surface is covered by laryngeal mucosa (Fig. 22). In this region, the medially concave thyroarytenoid muscle flanks the vocal ligament laterally, ventrally extending into the lateral wall of the lateral space (Fig. 22).

When defining the glottis (glottic cleft) as the distance between the attachment of the canonical vocal fold to the thyroid cartilage caudally up to the fusion of the medial processes of the left and right arytenoid cartilages rostrally, the intercartilaginous and intermembranous parts of the glottis are arranged in a straight line (Fig. 21). The entire rostrocaudal length of this glottic cleft is 52.2 mm; the intermembranous part covers 24.8 mm, and the intercartilaginous part 27.4 mm. The corresponding ratio is 1 : 1.1.

A 3-dimensional impression of the vocal keel of male impala is presented in Fig. 23, based on a CT scan of the left half of the larynx of Specimen#1.

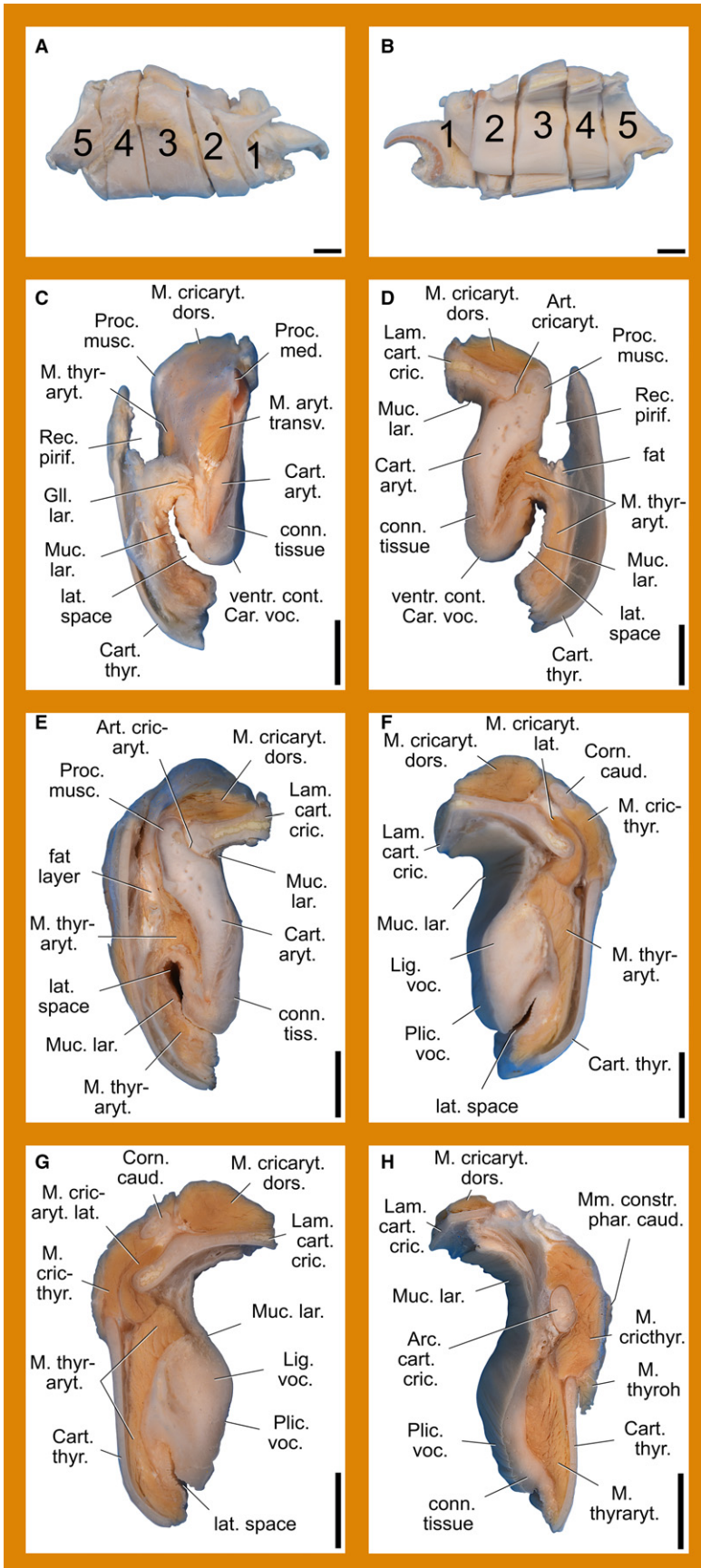
#### *Intrinsic laryngeal muscles*

The *cricothyroid muscle* takes its origin from the arc of the cricoid cartilage and terminates on the concave caudal edge of the thyroid cartilage and on its caudal horn (Fig. 13). The arc of the cricoid cartilage has a lateral ridge that is embraced by the cricothyroid muscle and gives it a roof-like shape. Unlike in red deer, for example, the area of termination does not extend onto the medial surface of the thyroid cartilage but is restricted to its caudal edge and caudal horn. The rostral third of the cricothyroid muscle is covered by the thyropharyngeus muscle and the caudal two-thirds are covered by the sternothyroid muscle. The rostral third of the cricothyroid muscle itself covers the lateral cricoarytenoid muscle.

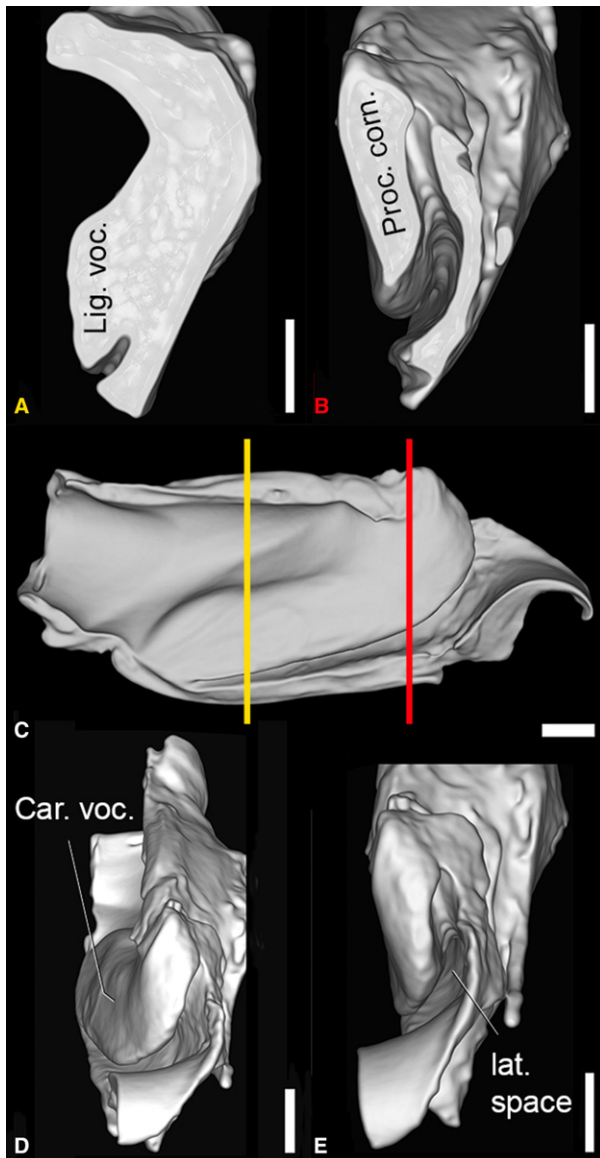
The *lateral cricoarytenoid muscle* takes its origin from the rostradorsal edge of the cricoid arc and terminates on the caudoventral surface of the muscular process of the arytenoid cartilage (Fig. 24). Dorsomedially, the lateral cricoarytenoid muscle touches the dorsal cricoarytenoid muscle and ventrally it touches the thyroarytenoid muscle.

The *dorsal cricoarytenoid muscle* takes its origin from the ipsilateral half of the cricoid plate and terminates on the caudodorsal surface of the muscular process of the arytenoid cartilage and, medially adjacent, on the medial process of the arytenoid cartilage (Fig. 24). Laterally, the dorsal cricoarytenoid muscle touches the lateral cricoarytenoid muscle and rostrally it touches the transverse arytenoid muscle.

The *transverse arytenoid muscle* takes its origin from the dorsolateral surface of the body of the arytenoid cartilage,



**Fig. 22** Transverse sections of the right half of the larynx of an adult male impala. (A) Lateral view of sectioned larynx half, (B) medial view of sectioned larynx half, (C) Part 2, rostral view, (D) Part 2, caudal view, (E) Part 3, rostral view, (F) Part 3, caudal view, (G) Part 4, rostral view, (H) Part 4, caudal view. The arytenoid cartilage is mostly separated from the laryngeal wall, dorsally by the piriform recess and ventrally by a lateral space (C,D). This space, although narrowing and getting less deep in caudal direction, also separates the entire vocal keel from the laryngeal wall. In the region of the arytenoid cartilage, fibres of the thyroarytenoid muscle course ventrally along the medial wall of the lateral space to terminate on a large area of the lateral surface of the arytenoid cartilage (D). Scale bars: 10 mm.



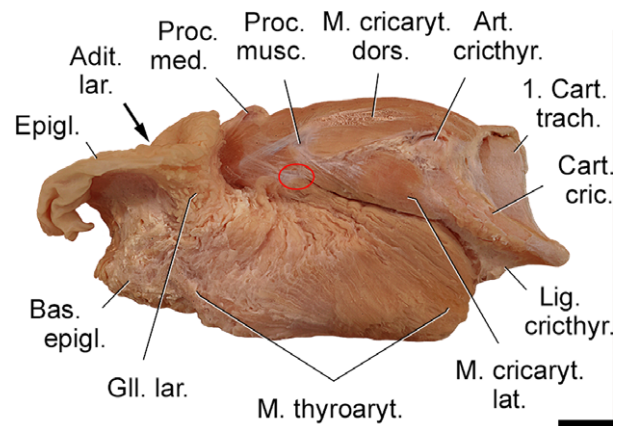
**Fig. 23** Three-dimensional representation of the left larynx half of Specimen #1 to provide an impression of the spatial structure of the vocal keel and the lateral space between it and the larynx wall. It must be noted that this male suffered from a prolonged heavy inflammation of the right lower jaw, ultimately ending in a jaw fracture and euthanasia. Probably for this reason, the vocal keel is much less voluminous and impressive than that of Specimen #2. Virtual cut caudally (A), virtual cut rostrally (B), medial view (C), oblique rostral view (D), rostral view (E). Scale bars: 10 mm.

including the muscular process, and terminates medial and caudal to the corniculate processes of the arytenoid cartilage, on its contralateral counterpart (Fig. 24 and 25). Caudally it touches the dorsal cricoarytenoid muscle and lateroventrally it touches the thyroarytenoid muscle.

The *thyroarytenoid muscle* takes its origin from the medioventral surface of the thyroid cartilage, lateral to the vocal ligament along a paramedian line, starting from the

cricothyroid ligament and the caudodorsal end of the thyroid bulla up to the ventrorostral edge of the thyroid cartilage, caudally adjacent to the base of the epiglottis. The caudal fibres take an oblique rostradorsal course and converge to terminate on the short vocal process and, ventral to the muscular process, on the body of the arytenoid cartilage and on the prominent knob below the muscular process (Figs 17A, 24 and Fig. S1). Ventrally, the middle fibres take a rostradorsal course and then turn dorsally and converge to terminate on the body of the arytenoid cartilage at the level of the dorsomedial process. The rostral fibres take a caudodorsal course and converge to terminate on the body of the arytenoid cartilage at its transition to the corniculate process (Fig. 24). Caudodorsally, the caudal-most fibres of the thyroarytenoid muscle touch the lateral cricoarytenoid muscle. Rostradorsally, the termination of the thyroarytenoid muscle touches the origin of the transverse arytenoid muscle. Ventrally, a superficial longitudinal band of muscle fibres takes its origin from the thyroid cartilage at the level of the muscular process, coursing rostrally to terminate laterally on the base of the epiglottis and, partly, on the thyroid cartilage (Figs 24, 25 and Fig. S2).

Taken together, the attachment sites of the thyroarytenoid muscle are (from caudal to rostral): (1) the concave inner surface of the thyroid bulla, (2) the vocal process, the prominent knob and the ventrally adjacent, expanded body area of the arytenoid cartilage and (3) the base of the epiglottis. The fibres of the caudal portion of the thyroarytenoid muscle run more or less parallel to the longitudinal axis of the vocal keel (rostradorsally), whereas the fibres of



**Fig. 24** Dorsal and lateral cricoarytenoid muscles and thyroarytenoid muscle of an adult male impala. The thyroid cartilage has been removed. The large thyroarytenoid muscle forms a continuous muscular mass from the cricothyroid ligament and the bottom of the thyroid bulla up to the level of the corniculate process. In particular, the caudal portion of this muscle is very massive. Its fibres terminate not only on the vocal process but also on an extended area of the arytenoid body ventral to the muscular process including the prominent knob below the muscular process (red ellipse). Left lateral view. Scale bar: 10 mm.



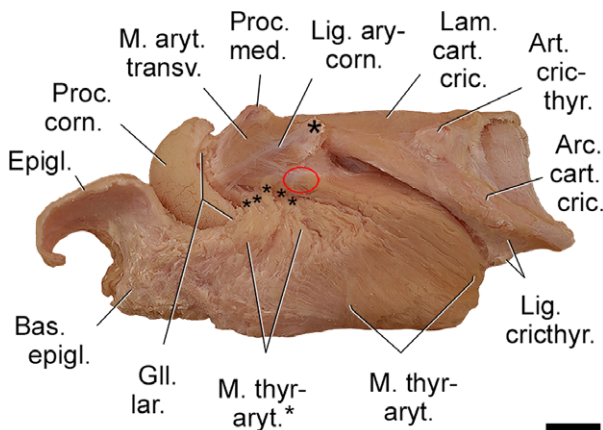
the rostral portion run more or less perpendicular to this axis (caudodorsally).

Our definitions of the vocal keel of male impala as a complex consisting of the arytenoid cartilage plus the canonical vocal fold arranged in line, covered by a common mucosa and separated from the laryngeal wall by a caudally fading lateral space, has consequences when assessing participation of the thyroarytenoid muscle in the structure of the vocal keel. Rostrally, along the arytenoid cartilage, the fibres of the thyroarytenoid muscle curve ventrally, insert on the arytenoid cartilage and thus are part of the free portion of the vocal keel, protruding into the laryngeal lumen and separated from the laryngeal wall by the capacious lateral space (Fig. 22C–E). Caudally, along the canonical vocal fold region, where the size of the lateral space decreases, the fibres of the thyroarytenoid muscle course, laterally adjacent to the vocal ligament, in the laryngeal wall and thus are not part of the free portion of the vocal keel (Fig. 22F–H). At its origin, the thyroarytenoid muscle, the vocal ligament and the covering mucosa attach the vocal keel to the bottom of the thyroid bulla. In short, the thyroarytenoid muscle is part of the free portion of the vocal keel rostrally but not caudally.

Therefore, the thyroarytenoid muscle reflects the longitudinal oblique orientation of the vocal keel itself, which is clearly separate from the laryngeal wall rostrally, but gradually fuses with it in caudal direction.

### Histology of the vocal keels of male impala

Medially and throughout its entire rostrocaudal length, the vocal keel is covered by a non-keratinised stratified squamous epithelium (mostly consisting of five layers), which



**Fig. 25** Transverse arytenoid and thyroarytenoid muscles of an adult male impala. The thyroid cartilage, the cricothyroid muscle and the lateral and dorsal cricoarytenoid muscles have been removed. The large single asterisk marks the muscular process of the arytenoid cartilage; the small asterisks mark fibres of the thyroarytenoid muscle, which do not terminate on the vocal process but on the body of the arytenoid cartilage. The red ellipse marks the prominent knob below the muscular process. Left lateral view. Scale bar: 10 mm.

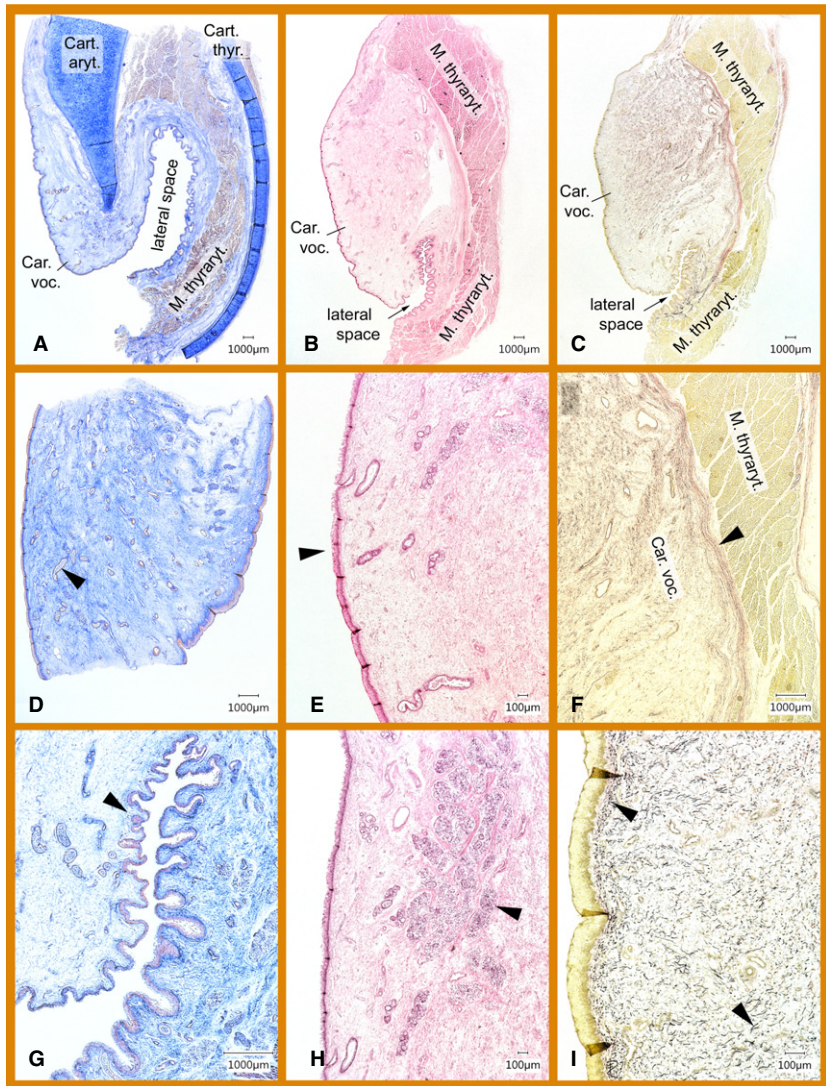
continues into the lateral space, the surface of which is strongly plicated (Fig. 26). Rostrally (Fig. 22 – macroscopic section 2 and transition to 1), the soft tissue of the vocal keel wraps around the ventral part of the arytenoid cartilage. In this region, this soft tissue is made up of collagenous loose connective tissue with few elastic fibres. The loose connective tissue is interspersed with holocrine, seromucous glands. Sections of their thick-walled, undulating excretory ducts are visible in transverse and sagittal sections over the entire area of the vocal keel soft tissue (Fig. 26). Correspondingly, the glands are not concentrated in a subepithelial layer but occur throughout the bulk of the vocal keel soft tissue and, far from the epithelium, even close to the connective tissue lining of the arytenoid cartilage. Hence, there is a high length variation of the excretory ducts depending on the respective position of the glands.

Lipocytes occur interspersed in the loose connective tissue but mostly they form well-defined adipose sheaths around the lymph and blood vessels inside the vocal keel soft tissue. Dorsal and medial to the lateral space, the thyroarytenoid muscle attaches to the arytenoid cartilage. The loose connective tissue surrounding the lateral space contains glands of the same type as the vocal keel. In the lateral wall of the lateral space the amount of elastic fibres is higher than in the rostral vocal keel portion.

In the middle portion of the vocal keel (Fig. 22 – macroscopic section 3 and transition to 4), a cartilaginous support is lacking and the entire vocal keel is made up of collagenous loose connective tissue. In this region the amount of elastic fibres is definitely higher than in the rostral vocal keel portion and their arrangement is uneven. In the subepithelial region they are mostly longitudinally aligned, whereas in the remaining bulk of the vocal keel they are irregularly oriented. In this portion of the vocal keel there is a local dorsomedial concentration of holocrine seromucous glands (Fig. 26). Dorsolaterally, a few larger blood vessels run longitudinally along the vocal keel (Fig. 26).

Laterally, between the vocal keel and the thyroarytenoid muscle, there is a ribbon-like stratified layer of tangential, lamina-arranged thick collagen fibres connecting the medial loose connective tissue to the lateral muscular tissue (Fig. 26). Possibly, this intermediate layer is a functional equivalent of the arytenoid cartilage in the rostral vocal keel portion in terms of transmitting the tensile forces from the contracting thyroarytenoid muscle onto the vocal keel. In transverse sections of the middle vocal keel portion, the thyroarytenoid muscle extends from the dorsal edge of the vocal keel along its bulky central portion down to the ventral end of the lateral space, so that the concave surface of the crescent-shaped thyroarytenoid muscle flanks the vocal keel laterally. A moderate adipose layer separates the thyroarytenoid muscle from the laterally positioned thyroid cartilage (Fig. 26).

In its caudal portion (Fig. 22 – macroscopic sections 4 and transition to 5) the vocal keel narrows and no longer consists of loose connective tissue. Instead, the connective



**Fig. 26** Microscopic vocal keel structure of male impala. (A) Rostral surface of macro-section 3, overview. (B) Caudal surface of macro-section 3, overview. (C) Rostral surface of macro-section 4, overview. (D) Close to medial surface of macro-section 2. (E) Detail of subfigure B. (F) Detail of subfigure C (laterally). (G) Detail of subfigure C (ventrally). (H) Detail of subfigure B (dorsomedially). (I) Detail of subfigure C (medially). Arrowheads: (D) excretion duct of seromucous gland, (E) non-keratinized stratified squamous epithelium, (F) layer of tangential, laminae arranged thick collagen fibres connecting the medial loose connective tissue to the lateral muscular tissue, (G) plicated epithelium and lumen of the lateral space, (H) dorsomedial concentration of holocrine seromucous glands, (I) elastic fibres mostly longitudinally aligned in the subepithelial region but irregularly oriented in the bulk of the vocal keel. Macro-section numbers refer to Fig. 22. (A–C, E–H) Frontal sections. (D) Sagittal section. (A, D, G) Azan staining. (B, E, H) Haematoxylin-Eosin staining. (C, F, I) Elastica Van Gieson staining.

tissue in this region is very compact, made up of thick collagen fibres, which, in oblique section, are arranged in circular, spiral- or ellipsoid-like structures reminiscent of the primary bundles of a tendon or a ligament. In addition, this ligament-like structure is intimately interlocked with the adjacent medial surface of the thyroarytenoid muscle. Seromucous glands, braided with elastic fibres, and longitudinally running lymph and blood vessels also occur in this caudal region of the vocal keel.

As an additional result of the histological analysis, we identified numerous sarcocysts (*Sarcocystis* sp.) around and inside the thyroarytenoid muscle.

### Trachea

The trachea consisted of 60 tracheal cartilages between the larynx and the bifurcation. The internal diameters of the trachea remained almost the same from the 2nd to the 58th tracheal ring: 17 mm dorsoventrally, 21 mm transversely.


### Reconstruction of the vocal organs (resting and maximally extended posture)

The complete set of the reconstructed vocal organs and relevant adjacent parts of male impala in the resting posture and in the extended posture are presented in Fig. 27. These reconstructions represent a graphical 2D two-step model of roar-synchronous downward and upward movements of the larynx and corresponding vocal tract extensions and shortenings in rutting male impala.

### Discussion

#### Species with a mobile larynx

The discovery of a mobile larynx involved in the production of rutting roars in male impala, extends the number of polygynous ruminant species capable of pronounced larynx



**Fig. 27** Reconstructions of the vocal organs and relevant adjacent organs of an adult male impala: (A,C,E,G) resting posture, (B,D,F,H) extended posture. During roar production, structures rostral to the larynx become extended (e.g. pharynx, hyoid apparatus, thyrohyoid ligament), the larynx itself is retracted, and structures caudal to the larynx either shorten (sternothyroid muscle) or are pushed caudally (trachea). Body contour and background: video single frames of the same individual. Skeletal parts are those of Specimen #1. From top to bottom, increasingly deeper layers of the vocal organs are exposed.

retraction to five: red deer (Fitch & Reby, 2001; Frey et al. 2012; Frey & Riede, 2013; Volodin et al. 2019), fallow deer (Fitch & Reby, 2001; McElligott et al. 2006), Mongolian gazelle (Frey et al. 2008a,b), goitred gazelle (Frey et al. 2011) and impala (this study). Structures responsible for laryngeal mobility in male impala are strap muscles apparently homologous to those of other larynx-retracting ruminants (Frey et al. 2008a,b, 2011, 2012; Frey & Riede, 2013). However, the large phylogenetic distance between impala and the other larynx-retracting species (Bärman et al. 2013) suggests independent evolution of a mobile larynx in male impala. Multiple convergent

evolution of this feature indicates strong selection pressure for effective male rutting calls and their importance for male reproductive success. It should be mentioned that slight retraction of the larynx, synchronous to the emission of oral calls, was found in all mammals so far examined via X-ray (Fitch, 2000). Slight call-synchronous movements of the larynx are typical for most mammals as a consequence of neck extension and moderate strap muscle contraction. Apparently, the pronounced larynx retraction of some ruminant species arose by expanding the function of a pre-existing feature under the evolutionary pressure of sexual selection.

### Anatomical adaptations for larynx retraction

Impala males have an extendible pharynx and a resilient thyrohyoid ligament and thyrohyoid membrane that allow larynx retraction upon caudal muscular pulling by the contracting narrow ribbon-like strap muscles (Fig. 9), connecting the larynx to the hyoid apparatus rostrally (thyrohyoid muscle, sternohyoid muscle) and to the sternum caudally (sternohyoid muscle, sternothyroid muscle). These strap muscles are similar to those of males of the other larynx-retracting ruminant species (Frey et al. 2008a,b, 2011, 2012; Frey & Riede, 2013). In addition, the entrance region of the larynx, including the flexible aryepiglottic fold, possesses an amazing resilience, certainly contributing to laryngeal mobility of male impala (Fig. 15). As the epiglottis is not tightly joined to the remaining parts of the larynx, it can be expected to stay high, relatively close to the hyoid apparatus, whereas the laryngeal entrance undergoes considerable stretching, and the middle and caudal parts of the larynx descend in a pronounced manner during larynx retraction. As the caudal edge of the intra-pharyngeal ostium and the caudal end of the pharynx are both dorsally fastened to the larynx, we may further expect a corresponding elongation and closure of the intra-pharyngeal ostium to a slit by the tensile forces acting on the larynx, pharynx and soft palate during larynx retraction. A similar extensibility of the laryngeal entrance region has been documented in male goitred gazelle (Efremova et al. 2016).

In male impala, the sternohyoid muscle retains its ancestral termination on the basihyoid, unlike red and fallow deer, in which this muscle is evolutionarily shortened (red deer: Frey et al. 2012; fallow deer: Reby et al. 2018). In male impala, the caudal halves of the sternohyoid and sternothyroid muscles have a common origin from the rostral tip of the sternum and are connected to the rostral halves by a tendinous intersection. Presumably, this tendinous intersection establishes a functional separation of the rostral and caudal muscle portions, enabling differential contraction and extension. Whereas the common caudal portion strongly contracts to effect larynx retraction, the rostral portions of the same muscles can simultaneously be extended to a certain extent by counteracting pulling forces (Fig. 27). Regarding the rostral portion of the sternothyroid muscle, a counteracting pull might come from the progressive and finally maximal extension of the thyrohyoid muscle. Regarding the sternohyoid muscle, a counteracting pull might be exerted by the tongue muscles responsible for roar-synchronous tongue protrusion. Probably, this construction increases the flexibility of the mobility system of the larynx and reduces stress in the attachment areas of the strap muscles.

We think that the occipitohyoid muscle of impala is involved in flexibly adjusting the overall caudal and rostral deflections of the hyoid apparatus during roar-synchronous downward and upward movements of the larynx. This action would be supported and enhanced by the wide span

between the fixation of the tympanohyoid to the skull rostrally and the tip of the stylohyoid angle caudally, constituting a favourable leverage (Figs 6 and 7).

During maximal retraction of the larynx and roar production, the basihyoid bulges out from the fine skin of the throat region (Figs 4 and 27). Contraction of the omohyoid muscle probably assists larynx retraction by preventing too much rostral and ventral excursion of the basihyoid. The omohyoid muscle appears to stabilise the overall configuration of the hyoid apparatus by counteracting both the rostral pulling of contracting tongue muscles (genioglossus and geniohyoid muscles) and the caudal pulling of the long strap muscles (sternohyoid and sternothyroid muscles). Thus, throughout the frequent roar-synchronous descents and ascents of the larynx, the position of the hyoid apparatus relative to the neck vertebrae seems to be under dynamic control of the omohyoid muscle (Fig. 8).

By position and attachments to the stylohyoid angle dorsally and to the basihyoid ventrally, the stylohyoid muscle is ideally suited for flexible regulation of the dorsoventral length of the multisectional suspension chain of the hyoid apparatus (Fig. 10). This function is required during roar-synchronous descents and ascents of the larynx, when the throat region either expands when approaching the roaring posture or shrinks when returning to its resting shape, and the configuration of the hyoid apparatus changes accordingly from its folded resting state towards maximal extension and back.

The prominent lingual process of the basihyoid might improve the leverage for the geniohyoid and genioglossus muscles rostrally and the omohyoid and sternohyoid muscles caudally (Figs 6 and 7). Retraction of the larynx is mostly effected by strong contraction of the joint portion of the sternohyoid and sternothyroid muscles. Simultaneously, the downward movement of the larynx will cause an extension of the entire hyoid apparatus and a caudal deflection of the thyrohyoid. This is achieved by dorsal pulling of the thyrohyoid ligament on the thyrohyoid tip. Ventrally, this deflection of the thyrohyoid is favoured by contraction of the geniohyoid and genioglossus muscles and protrusion of the tongue, simultaneously causing an extension of the rostral portion of the sternohyoid muscle (Fig. 27).

### Acoustic correlates of larynx retraction

The acoustics of the rutting roars indicate that male impala begin to produce their rutting roars during the downward movement of the larynx, resulting in vocal tract elongation, similar to red deer (Fitch & Reby, 2001; Frey et al. 2012; Volodin et al. 2019), fallow deer (McElligott et al. 2006) and goitred gazelle (Frey et al. 2011). In contrast to other ruminants with a retractable larynx, male impala sometimes continue with roaring during the ascending movement of the larynx, i.e. when the vocal tract is re-shortening (Fig. 3A). As the formant frequencies primarily depend on the length of

the vocal tract (Fitch & Reby, 2001; Taylor & Reby, 2010), changes of vocal tract length are noticeably reflected in the positions of the formants of male impala roars (Table 1). Thus, formant frequencies of the roars rose at shortening and fell at elongation of the vocal tract (Fig. 3B; Table 1). Calculations of the vocal tract length based on formant dispersion of the roars according to the dividing method (Riede & Fitch, 1999) produced values close to those estimated from video single frames (Fig 2; Table S1). As calculations of vocal tract length based on the regression method produced much lower values (Reby & McComb, 2003), we are assuming that the video single frame method and the dividing method approach the real vocal tract length in male impala more reliably than the regression method. The dividing method also provided a better coincidence between the anatomical and acoustical calculations of vocal tract length for rutting male Pannonian red deer (Volodin et al. 2019). However, the regression method provided a good coincidence between the anatomical and acoustical calculations for Iberian red deer (Frey et al. 2012), goitred gazelle (Frey et al. 2011) and saiga (Volodin et al. 2014).

The repeated, short inspiration phases within the pant roars of rutting male impala (Fig. 3) might promote sustained vocalisations, i.e. extend potential roaring time, even over changing positions of the larynx. The insertion of these short inspiration phases during roars with repetitive, bidirectional airflow is unique to impala among the other ruminants with a mobile larynx, in which the volume of the expiratory airflow strongly determines the duration of the uninterrupted roars with unidirectional airflow (red deer: Frey et al. 2012; Volodin et al. 2015, 2019; fallow deer: McElligott et al. 2006; goitred gazelle: Frey et al. 2011).

### Tongue protrusion behaviour

Rutting impala males frequently, but not always, protrude the tongue during roar emission. We are not aware of any acoustic function of this tongue protrusion behaviour. Possibly, exposing the warm and moist surface of the tongue during strong serial exhalations and inhalations during the roaring contributes to thermoregulation via evaporative cooling and heat dissipation from the oral vocal tract surfaces, as was suggested for rutting male Iberian red deer *Cervus elaphus hispanicus* (Frey et al. 2012).

### Acoustic correlates of larynx size

In impala males, larynx size does not correspond with the size of the sound-producing structures inside. Impala males have a typically sized larynx but a considerably enlarged sound source. This was achieved by combining two structures, the arytenoid cartilage and the canonical vocal fold, in one entity. The resulting sound source of male impala, the vocal keel, represents an evolutionary novelty, as the

vocal fold and the arytenoid cartilage are functionally separate in other species of ruminants (Frey et al. 2008a,b, 2011; Frey & Riede, 2013). In contrast to other species, in male impala the entire vocal keel (i.e. the vocal fold in the canonical sense plus the arytenoid cartilage) might be set into oscillation by purely exhalatory airstreams or by rapidly alternating exhalatory and inhalatory airstreams during the roars. The particularly large thyroarytenoid muscle might support the oscillatory movements of the vocal keel.

The low fundamental frequency of male impala rutting roars (50 Hz) is comparable to that produced by the large and massive vocal folds inside the enlarged larynx of rutting male goitred gazelles (23 Hz; Frey et al. 2011). Unlike those of the much noisier male rutting calls of Mongolian and goitred gazelles (Frey et al. 2008a, 2011; Volodin et al. 2017c), the fundamental frequency of male impala calls is clearly visible and measurable in the spectrograms (Fig. 3). In male Mongolian and goitred gazelles, vocal ontogenetic development starts from clearly tonal calls shortly after birth to culminate in the noisy calls of mature males, involving prominent changes in the anatomy and histology of the vocal folds (Efremova et al. 2011, 2016; Volodin et al. 2017a,c). Further studies are required to reveal the vocal ontogenetic development from birth to adulthood in male impala.

### Vocal fold anatomy

For a better understanding of the divergent structure of the male impala vocal fold, the corresponding features in a typical bovid, as exemplified by sheep and goat (cf. Nickel et al. 2004), are briefly summarised:

- (contrary to impala vocal keels) vocal fold orientation is more or less perpendicular to the longitudinal axis of the larynx and trachea, i.e. to the airflow;
- thereby, the longitudinal axis of the arytenoid cartilage and that of the vocal fold form a right angle, approximately (whereas they are in line in impala);
- the position of the ventral attachment of the vocal ligament to the thyroid cartilage is roughly at the level of the cricoarytenoid articulation (whereas it is caudally shifted in impala);
- therefore, this site, the laryngeal prominence, has a position at about half-way along the ventral midline of the thyroid cartilage (whereas, in impala, it is located at the caudal end of the thyroid cartilage);
- the free edge of the vocal fold protruding into the laryngeal lumen is thin and flexible, and rostrally directed, i.e. away from the expiratory airflow (whereas it is thick and tough and ventrally directed in impala);
- the dorsoventral length of the vocal fold is pronouncedly larger than its rostrocaudal length (whereas this proportion is reversed in impala);

- accordingly, the rostrocaudal dimension of the glottis is relatively small (whereas it is large in impala) (see textbook illustrations, e.g. in Nickel et al. 2004).

Compared with this typical vocal fold structure in bovids, the vocal fold of male impala is remarkable in several respects:

- the vocal fold in the canonical sense is fused to the arytenoid cartilage and its covering soft tissues along a straight axis, thus forming a new large entity that fills almost the entire supraglottal laryngeal cavity. To designate this new structure, we created a new term: vocal keel, or *Carina vocalis*;
- as a consequence of the in-line orientation of the two parts of the vocal keel and their uniform mucosal covering, the dimensions of the canonical vocal fold are not readily visible but have to be indirectly accessed by palpation of the vocal process;
- the vocal keel is connected to the lateral laryngeal wall solely via a narrow longitudinal ridge (a stalk in cross-section), whereas dorsally and ventrally the vocal keel is separated from the lateral laryngeal wall, dorsally by the deep piriform recess and ventrally by a specific lateral space (Fig. 22C,D);
- owing to the linear arrangement of the arytenoid cartilage and the vocal fold in the canonical sense and their strongly oblique orientation, the two parts of the glottis are also set longitudinally one after another, the cartilaginous part rostrally and the membranous part caudally. Therefore, the glottic cleft, from the bottom of the thyroid bulla up to the medial connection of the arytenoid cartilages via their medial processes, is rather long (more than 50 mm, Fig. 21);
- between the vocal process and the bottom of the thyroid bulla a sort of a hypertrophied vocal ligament extends, forming the caudal part of the vocal keel (Fig. 22F,G);
- the thyroarytenoid muscle is very large and covers the entire lateral region of the vocal keel, from the bottom of the thyroid bulla up to the level of the corniculate process, also invading the medial wall of the lateral space. In cross-section, it is crescent-shaped, medially concave and has extensive attachments not only on the vocal process but also on the body of the arytenoid cartilage, including a prominent lateral knob ventral to the muscular process, on the thyroid cartilage and on the base of the epiglottis (Figs 17A and 24).

It appears that the sound source of male impala underwent an internal evolutionary enlargement without any enlargement of the larynx itself. This uncoupling of larynx size and vocal fold size occurred by the fusion of two adjacent laryngeal structures: the arytenoid cartilage and the canonical vocal fold.

The large rostrocaudal length of the thyroarytenoid muscle and its oblique orientation, being part of the vocal keel rostrally but merely flanking the vocal ligament caudally, and the different fibre directions in its rostral and caudal portions, suggest the following functions: (1) adduction of the ventral parts of the arytenoid cartilages by ventral pulling of the rostral fibres, (2) closure of the glottis by joint ventral and caudal pulling of the rostral and caudal fibres, (3) closure of the lateral space by the same action, (4) longitudinal shortening of the vocal keel, thereby increasing its bulging into the laryngeal lumen by contraction and caudal pulling of the caudal fibres.

As the bulky vocal keels of male impala occupy much more space in the laryngeal cavity (Figs 18, 19 and 21) than typical small, slender and flexible mammalian vocal folds, they might act as obstacles for normal breathing, particularly during the rut when reaching maximal dimensions. Apparently, this danger is prevented by opening the glottis through relaxation of the thyroarytenoid muscle and contraction of the large dorsal cricoarytenoid muscles (Fig. 14), thereby pulling the vocal keels laterally. The left and right lateral spaces and their restricted, ridge-like attachment to the larynx wall (Fig. 22C,D) provide the space and mobility of the vocal keels necessary for this movement.

In certain features, the vocal fold anatomy of male impala is reminiscent of the vocal fold anatomy of whales, in particular that of mysticete whales (*cf.* Reidenberg & Laitman, 1988, 2007): (1) the orientation of the vocal fold is at an acute angle to the longitudinal axis of the larynx and trachea, i.e. more or less in parallel with the direction of the airflow (Reidenberg & Laitman, 2007, fig. 1, p. 749); (2) the structure of the vocal keel resembles the U-fold of mysticete whales insofar as the arytenoid cartilage and the canonical vocal fold form a continuous entity arranged one after the other along a common longitudinal axis (*cf.* Reidenberg & Laitman, 2007, fig. 4, p. 752); (3) the vocal ligament is thick and tough and its attachment to the thyroid cartilage lies pronouncedly caudal to the cricoarytenoid articulation (*cf.* Reidenberg & Laitman, 2007, fig. 5, p. 755).

One mechanism of low-frequency sound production in mysticete whales is assumed to be U-fold vibration (*cf.* Reidenberg & Laitman, 2007, p. 757), i.e. vibration of a vocal keel-like structure consisting of a linearly arranged entity of arytenoid cartilage and a vocal fold homologue. Considering the similarly organised vocal keel structure of rutting male impala and the low-frequency pulses of their rutting roars, it is conceivable that, in contrast to a typical mammalian larynx but in agreement with the above-cited mechanism suggested for mysticetes, the entire bulky vocal keel is set into oscillation by rapidly repeated exhalations and inhalations during rutting roar production.

However, excised larynx experiments along the lines of earlier studies (Titze et al. 2010; Herbst et al. 2012) will be

necessary to clarify the precise functioning and vibratory modes of this novel structure.

### Vocal fold angle

Typically, the orientation of the vocal fold in artiodactyls and primates is more or less perpendicular to the longitudinal axis of the larynx, whereas the vocal fold of carnivores is set at an acute angle to it (Schneider, 1964). Given the peculiar structure of the male impala vocal keel, which clearly differs from a typical artiodactyl vocal fold, we used the approximated central axis of the vocal keel to determine vocal fold orientation (150°: Fig. 20). If we had used the same method as Schneider (1964) and used the rostral edge of the vocal fold, which corresponds to the ventral edge of the impala vocal keel, for measuring, the angle would even be more obtuse (155°: Fig. 20). Compared with the smallest value (17.5°) reported by Schneider (1964, p. 70/71) for a pinniped, the California sea lion (*Zalophus californianus*), the orientation of the male impala vocal keel is obviously quite different: in the California sea lion (and most other pinnipeds) the vocal fold is rostroventrally inclined (Schneider, 1962, 1963, 1964, figs 70 and 76), whereas the male impala vocal keel, corresponding to the orientation of the longitudinal arms of the U-fold in mysticete whales (Reidenberg & Laitman, 2007), is caudoventrally inclined. As a consequence, the vocal fold in the California sea lion is almost parallel (approaching 0°) to the longitudinal axis of the arytenoid cartilage (Schneider, 1962, 1964, fig. 76) whereas the ventral attachment of the canonical vocal fold in male impala has been shifted caudally so that it is now in line (180°) with the long axis of the arytenoid cartilage.

In contrast to pinnipeds, which temporarily leave the water and haul themselves out on land, whales and dolphins have evolved a permanent aquatic lifestyle. After more or less prolonged dives, when surfacing, they effect their respiratory gas exchange by rapid exhalations and inhalations. Possibly, the vocal folds of cetacea, which are oriented more or less in parallel with the airflow (Reidenberg & Laitman, 1988, 2007), are advantageous to manage this temporarily constrained and violent respiration by reducing resistance to the rapid exchange of large air volumes.

Similarly, the vocal keels of male impala, which have a comparable orientation, might be advantageous in producing rutting roars, particularly pant roars, in rapid succession.

### Vocal fold histology

Like the human vocal folds (Bucher & Wartenberg, 1997, p. 249), the vocal keels of male impala are covered with non-keratinized stratified squamous epithelium, probably to withstand the mechanical stresses occurring during

oscillation and sound production. In contrast to the human vocal fold (Bucher & Wartenberg, 1997, p. 249), the vocal keel of male impala is extensively equipped with seromucous glands over its entire rostrocaudal length. Probably, the voluminous massive vocal keels, medially facing each other across a very large glottis region, require copious lubrication already in the resting state and even more so when intermittently contacting each other in the oscillating state during sound production.

Most probably, the vocal keel portion between the vocal process of the arytenoid cartilage and the thyroid bulla corresponds to a typical mammalian larynx's canonical vocal fold and the bulky ligament-like structure within to the vocal ligament. Provided this interpretation is correct, the vocal ligament inside the vocal keel of male impala differs from the delicate human vocal ligament, which is mostly made up of parallel-arranged elastic fibres (Bucher & Wartenberg, 1997, p. 122). In contrast, the vocal ligament of male impala mostly consists of thick collagen fibres arranged in bundles. Functionally, this might indicate a lesser resilience of the gross vocal ligament in male impala than in a vocal ligament of a typical mammalian larynx (e.g. the human larynx, Bucher & Wartenberg, 1997). However, as in humans (Hirano & Kakita 1985), the thyroarytenoid muscle appears to be tightly fastened to the vocal ligament by collagenous fibres (Fig. 26C,F).

Taken together, this would coincide with the compact structure of the entire vocal keel, which certainly cannot be set under tension in the same way as a typical delicate and flexible mammalian vocal fold, i.e. by leverage of the laryngeal cartilages alone. Instead, contraction of the extensive, obliquely oriented and (in cross-section) crescent-shaped thyroarytenoid muscle additionally appears to increase the bulge of the vocal keel and shift it medially, thereby closing the glottis by a modified mechanism compared with a typical mammalian larynx, in which closure of the glottis is effected by pivoting the arytenoid cartilages medially through muscle action. We suggest, therefore, that the unique structure of the vocal keel of male impala involves a modified closure mechanism of the glottis.

### Larynx parasite infestation

Our histological sections documented infestation of the larynx, particularly the thyroarytenoid muscle, with sarcocysts (genus *Sarcocystis*). Species identification was beyond the scope of this work. Potentially, such an infestation can affect vocalisation of rutting males in some way; however, such effects have not yet been reported. A similar infestation of the oesophagus and larynx with sarcocysts of three species of the genus *Sarcocystis* has been reported earlier for Mongolian gazelle (Odening et al. 1996).

## Convergent evolution of larynx-retracting ruminant species

The anatomy of the male impala vocal keel clearly differs from a typical ruminant vocal fold as found in the domestic ruminants (goat, sheep, cow) (Nickel et al. 2004). The two cervid and three bovid, larynx-retracting species are phylogenetically not closely related, all belonging to different genera (Emerson & Tate, 1993; Bärmann et al. 2013). The relevant features of the sound source are different in each species. This strongly implies that they evolved convergently, because the resonance frequencies of the vocal tract can be better exposed with low sound source frequencies. In the larynx-retracting species, a large male vocal source is achieved by different evolutionary pathways: (1) in male red deer, the vocal fold is already large because of the size of the larynx; (2) in the smaller fallow deer male, the vocal fold is enlarged by the enlargement of the larynx (R. Frey, D. Reby, M. Wyman, personal observation); (3) in male Mongolian gazelle, the larynx is greatly enlarged and the structure of the vocal fold does not conform to a typical bovid vocal fold; it is supported by a large vocal pad and caudally directed ('vocal bow'); (4) in male goitred gazelle, the larynx is enlarged and the vocal fold is supported by a vocal pad and rostrally directed; (5) in male impala, the larynx is not enlarged but the sound source has been enlarged by a combination and in-line arrangement of the arytenoid cartilage and the canonical vocal fold, whose common edge is ventrally directed leading to a structure that we have termed 'vocal keel'.

Polygynous ruminants have diverse mating systems in which the males may defend a larger territory with resources, or a small territory inside a lek, or may defend a harem of females or use combinations of these strategies. The mating system may not be fixed across a population (Apollonio et al. 1992). The decisive feature is that there is male–male competition and female choice, and in both contexts male rutting vocalisations are critically important.

Both males and females react to the rutting vocalisations of other males. Fights between unequal males can be prevented acoustically by the size-related features of the vocal organs. Males matching in body size react either by retreat or by aggressive encounters towards a rival male's vocalisations, and female mates are attracted by the vocalisations of dominant males and probably avoid mating with young males.

Therefore, male rutting vocalisations contribute decisively to male reproductive success. This is why the anatomy of the vocal organs and the related acoustic vocal features are under strong selection pressure, which might also explain why such features as a mobile larynx and the extreme variability of the enlarged vocal folds, which are disadvantageous and costly from the perspective of natural selection, could have evolved in these larynx-retracting species. The advantages of these features in male reproductive success

clearly outweigh the disadvantages, so there is a trade-off between natural and sexual selection.

## Acknowledgements

We would like to thank Christian Schmitt, the owner of the Okambara Elephant Ranch, Namibia, for providing the possibility to investigate impala on his farm, for his interest in our work and continuous support. We further thank Jakob HaiHáb for his invaluable help and advice while we were conducting our research at the Okambara Elephant Ranch, Namibia. We are very grateful to veterinary Rebekka Müller, a former doctoral student of the IZW, working at Okambara Elephant Ranch. She provided invaluable support in exporting the dissected and preserved laryngeal parts of impala from Windhoek to Berlin, thereby enabling their histological processing and analysis. Doris Krumnow, technical assistant in the IZW Department of Wildlife Diseases, kindly did the sectioning and staining of the histological samples of the vocal folds, and Gudrun Wibbelt, pathologist in the same department, provided crucial support in evaluating the slides. We thank Bernhard Blaszkiewicz, former director of Berlin Zoo and Tierpark Berlin, Germany, and Richard Østerballe, director of Givskud Zoo, Denmark, for providing the two lionesses used for the comparison between lion roaring and male impala roaring in the Supporting Information. We thank Alan McElligott, W. Tecumseh Fitch and David Reby, who disclosed their identities to us, for their constructive and inspiring comments. Supported by RFBR grant 19-04-00133 (to I.V. and E.V.). Open access funding enabled and organized by Projekt DEAL

## Data availability statement

The data that support the findings of this study are available on request from the corresponding author. The data are not publicly available due to privacy or ethical restrictions.

## References

- Apollonio M, Festa-Bianchet M, Mari F, et al. (1992) To lek or not to lek: mating strategies of male fallow deer. *Behav Ecol* 3, 25–31.
- Bärmann EV, Rössner GE, Wörheide G (2013) A revised phylogeny of Antilopini (Bovidae, Artiodactyla) using combined mitochondrial and nuclear genes. *Mol Phylogenetics Evol* 67, 484–493.
- Boersma P, Weenink D (2013) Praat: doing phonetics by computer. *Version 5(3)*, 51. <http://www.praat.org/>.
- Briefer E, Vannoni E, McElligott AG (2010) Quality prevails over identity in the sexually selected vocalisations of an ageing mammal. *BMC Biol* 8, 35.
- Bucher O, Wartenberg H (1997) *Cytologie, Histologie und mikroskopische Anatomie des Menschen*. 12, vollständig überarbeitete Auflage. Göttingen: Huber.
- Charlton BD, Reby D, McComb K (2007) Female red deer prefer the roars of larger males. *Biol Lett* 3, 382–385.
- Charlton BD, Reby D, McComb K (2008) Effect of combined source (F0) and filter (formant) variation on red deer hind responses to male roars. *J Acoust Soc Am* 123, 2936–2943.
- Charlton BD, Ellis WAH, McKinnon AJ, et al. (2011a) Perception of male caller identity in koalas (*Phascolarctos cinereus*):



- acoustic analysis and playback experiments. *PLoS ONE* **6**, e20329.
- Charlton BD, Ellis WAH, McKinnon AJ, et al. (2011b) Cues to body size in the formant spacing of male koala (*Phascolarctos cinereus*) bellows: honesty in an exaggerated trait. *J Exp Biol* **214**, 3414–3422.
- Charlton BD, Ellis WAH, Brumm J, et al. (2012) Female koalas prefer bellows in which lower formants indicate larger males. *Anim Behav* **84**, 1565–1571.
- Charlton BD, Frey R, McKinnon AJ, et al. (2013a) Koalas use a novel vocal organ to produce unusually low-pitched mating calls. *Curr Biol* **23**, R1035–R1036.
- Charlton BD, Whisson DA, Reby D (2013b) Free-ranging male koalas use size-related variation in formant frequencies to assess rival males. *PLoS ONE* **8**, e70279.
- Child G (1965) Behaviour of large mammals during the formation of Lake Kariba. Dissertation thesis, National Museum, Bulawayo, Rhodesia (now Zimbabwe), 140 pp. Published by the University of Cape Town, South Africa. (Part on impala: 79–94).
- Child G (1968) *Behaviour of Large Mammals during the Formation of Lake Kariba*. Salisbury: Trustees of the National Museums of Rhodesia.
- Constantinescu GM, Schaller O (eds.) (2012) *Illustrated Veterinary Anatomical Nomenclature*. 3rd, revised edn. Stuttgart: Enke.
- Dasmann RF, Mossman AS (1962) Population studies of impala in southern Rhodesia. *J Mammal* **43**, 375–395.
- Efremova KO, Volodin IA, Volodina EV, et al. (2011) Developmental changes of nasal and oral calls in the goitred gazelle *Gazella subgutturosa*, a nonhuman mammal with a sexually dimorphic and descended larynx. *Sci Nat* **98**, 919–931.
- Efremova KO, Frey R, Volodin IA, et al. (2016) The postnatal ontogeny of the sexually dimorphic vocal apparatus in goitred gazelles (*Gazella subgutturosa*). *J Morph* **277**, 826–844.
- Emerson BC, Tate ML (1993) Genetic analysis of evolutionary relationships among deer (subfamily Cervinae). *J Hered* **84**, 266–273.
- Estes RD (2012) *The Behaviour Guide to African Mammals – Including Hoofed Mammals, Carnivores, Primates*, Twentieth Anniversary edn. Berkeley: The University of California Press.
- Fairall N, Braack HH (1976) Growth and development of the impala *Aepyceros melampus*. *Koedoe* **19**, 83–88.
- Fant G (1960) *Acoustic Theory of Speech Production*. The Hague: Mouton.
- Favreau F-R, Pays O, Goldizen AW, et al. (2013) Short-term behavioural responses of impalas in simulated antipredator and social contexts. *PLoS ONE* **8**, e84970.
- Fitch WT (1997) Vocal tract length and formant frequency dispersion correlate with body size in rhesus macaques. *J Acoust Soc Am* **102**, 1213–1222.
- Fitch WT (2000) The phonetic potential of nonhuman vocal tracts: comparative cineradiographic observations of vocalizing animals. *Phonetica* **57**, 205–218.
- Fitch WT, Reby D (2001) The descended larynx is not uniquely human. *Proc R Soc Lond B* **268**, 1669–1675.
- Frey R, Gebler A (2003) The highly specialized vocal tract of the male Mongolian gazelle (*Procapra gutturosa* Pallas, 1777 – Mammalia, Bovidae). *J Anat* **203**, 451–471.
- Frey R, Hofmann RR (2000) Larynx and vocalization of the takin (*Budorcas taxicolor* Hodson, 1850 – Mammalia, Bovidae). *Zool Anz* **239**, 197–214.
- Frey R, Riede T (2003) Sexual dimorphism of the larynx of the Mongolian gazelle (*Procapra gutturosa* Pallas, 1777) (Mammalia, Artiodactyla, Bovidae). *Zool Anz* **242**, 33–62.
- Frey R, Riede T (2013) The anatomy of vocal divergence in North American elk and European red deer. *J Morphol* **274**, 307–319.
- Frey R, Volodin IA, Volodina EV (2007) A nose that roars: anatomical specializations and behavioural features of rutting male saiga. *J Anat* **211**, 717–736.
- Frey R, Gebler A, Olson KA, et al. (2008a) Mobile larynx in Mongolian gazelle: retraction of the larynx during rutting barks in male Mongolian gazelle (*Procapra gutturosa* Pallas, 1777). *J Morph* **269**, 1223–1237.
- Frey R, Gebler A, Olson KA, et al. (2008b) Head anatomy of male and female Mongolian gazelle – a striking example of sexual dimorphism. In: *Anatomical Imaging – Towards a New Morphology* (eds Endo H, Frey R), pp. 1–13. Tokyo: Springer.
- Frey R, Volodin I, Volodina E, et al. (2011) Descended and mobile larynx, vocal tract elongation and rutting roars in male goitred gazelles (*Gazella subgutturosa* Gldenstaedt, 1780). *J Anat* **218**, 566–585.
- Frey R, Volodin I, Volodina E, et al. (2012) Vocal anatomy, tongue protrusion behaviour and the acoustics of rutting roars in free-ranging Iberian red deer stags (*Cervus elaphus hispanicus*). *J Anat* **220**, 271–292.
- Frey R, Reby D, Fritsch G, et al. (2018) The remarkable vocal anatomy of the koala (*Phascolarctos cinereus*): insights into low-frequency sound production in a marsupial species. *J Anat* **232**, 575–595.
- Golosova OS, Volodin IA, Isaeva IL, et al. (2017) Effects of free-ranging, semi-captive and captive management on the acoustics of male rutting calls in Siberian wapiti *Cervus elaphus sibiricus*. *Mammal Res* **62**, 387–396.
- Grinnell J (2002) Modes of cooperation during territorial defense by African lions. *Human Nat* **13**, 85–104.
- Herbst CT, Stoeger AS, Frey R, et al. (2012) How low can you go? Physical production mechanism of elephant infrasonic vocalizations. *Science* **337**, 595–599.
- Hirano M, Kakita Y (1985) *Cover-body theory of vocal fold vibration*. *Speech Science: Recent Advances*. (ed Daniloff RG), pp. 1–46. San Diego: College Hill Press.
- Jarman MV (1979) Impala social behaviour – territory, hierarchy, mating, and the use of space. *Advances in Ethology* No 21. Supplements to Journal of Comparative Ethology Berlin, Hamburg, Paul Parey, 92 pp. ISBN 3-489-60936-0
- Luckhaus G (1969) Vergleichend-anatomische Betrachtungen ber den Pharynx des Lwen mit Bercksichtigung der mikroskopischen Anatomie seiner Tonsilla palatina. *Zentralblatt Veterinrmed Reihe A* **16**, 240–256.
- McComb K, Clutton-Brock T (1994) Is mate choice copying or aggregation responsible for skewed distributions of females on leks? *Proc R Soc B* **255**, 13–19.
- McElligott AG, Birrer M, Vannoni E (2006) Retraction of the mobile descended larynx during groaning enables fallow bucks (*Dama dama*) to lower their formant frequencies. *J Zool* **270**, 340–345.
- Murray MG (1982) The rut of impala: aspects of seasonal mating under tropical conditions. *Z Tierpsychol* **59**, 319–337.
- NAV (2005) Nomina anatomica veterinaria [online]. World Assoc Vet Anat. Available at: [http://www.wava-amav.org/Download/s/nav\\_2005.pdf](http://www.wava-amav.org/Download/s/nav_2005.pdf) [accessed 1 February 2006].

- NAV (2012) Nomina anatomica veterinaria [online]. 5th edn. (revised version – only typographic errata corrected). World Assoc Vet Anat. Available at: [http://www.wava-amav.org/Downloads/nav\\_2012.pdf](http://www.wava-amav.org/Downloads/nav_2012.pdf) [accessed 14 August 2015].
- Negus VE (1949) *The Comparative Anatomy and Physiology of the Larynx*. New York: Grune and Stratton.
- Nickel R, Schummer A, Seiferle E (2004) Lehrbuch der Anatomie der Haustiere. Bd. 2 *Eingeweide*. (eds Frewein J, Gasse H, Leiser R, Roos H, Thomé H, Vollmerhaus B, Waibl H), p. 482, 9. unveränderte Auflage. Stuttgart: Parey.
- Odening K, Stolte M, Lux E, et al. (1996) The Mongolian gazelle (*Procapra gutturosa*, Bovidae) as an intermediate host of three *Sarcocystis* species in Mongolia. *Appl Parasitol* 37, 54–65.
- Oliver CM, Skinner JD, Van der Merwe D (2006) Territorial behaviour in southern impala rams (*Aepyceros melampus* Lichtenstein). *Afr J Ecol* 45, 142–148.
- Pfefferle D, Peyton M, Grinnell J, et al. (2007) Do acoustic features of lion, *Panthera leo*, roars reflect sex and male condition? *J Acoust Soc Am* 121, 3947–3953.
- Ramsauer S (2005) Acoustic communication in lions and its use in territoriality. *Cogn Brain Behav* 9, 539–550.
- Reby D, McComb K (2003) Anatomical constraints generate honesty: acoustic cues to age and weight in the roars of red deer stags. *Anim Behav* 65, 519–530.
- Reby D, McComb K, Cargnelutti B, et al. (2005) Red deer stags use formants as assessment cues during intra-sexual agonistic interactions. *Proc R Soc Lond B* 272, 941–947.
- Reby D, Wyman MT, Frey R, et al. (2016) Evidence of biphonation and source-filter interactions in the bugles of male North American wapiti (*Cervus canadensis*). *J Exp Biol* 219, 1224–1236.
- Reby D, Wyman MT, Frey R, et al. (2018) Vocal tract modelling in fallow deer: are male groans nasalized? *J Exp Biol* 221, 221 (Pt 17): pii: jeb179416.
- Reidenberg JS, Laitman JT (1988) Vocal folds in the larynx of Odontoceti (toothed whales). *Anat Rec* 221, 884–891.
- Reidenberg JS, Laitman JT (2007) Discovery of a low frequency sound source in Mysticeti (baleen whales): anatomical establishment of a vocal fold homolog. *Anat Rec* 290, 745–759.
- Riede T, Fitch T (1999) Vocal tract length and acoustics of vocalization in the domestic dog (*Canis familiaris*). *J Exp Biol* 202, 2859–2867.
- Schenkel R (1966) On sociology and behaviour in impala (*Aepyceros melampus* Lichtenstein). *Afr J Ecol* 4, 99–114.
- Schneider R (1962) Vergleichende Untersuchungen am Kehlkopf der Robben (Mammalia, Carnivora, Pinnipedia). *Morph Jb* 103, 177–262.
- Schneider R (1963) Morphologische Anpassungserscheinungen am Kehlkopf einiger aquatiler Säugetiere. *Z Säugetierk*, 28, 257–267.
- Schneider R (1964) Der Larynx der Säugetiere. *Handb Zool* 5, 1–128.
- Schwab P, Debes PV, Witt T, et al. (2012) Genetic structure of the common impala (*Aepyceros melampus melampus*) in South Africa: phylogeography and implications for conservation. *J Zool Syst Evol Res* 50, 76–84.
- Sibiryakova OV, Volodin IA, Frey R, et al. (2017) Remarkable vocal identity in wild-living mother and neonate saiga antelopes: a specialization for breeding in huge aggregations? *Sci Nat* 104, 11.
- Skinner JD (1971) The sexual cycle of the impala ram *Aepyceros melampus* Lichtenstein. *Zool Afr* 6, 75–84.
- Skinner JD, Chimimba CT (2005) *The Mammals of the Southern African Sub-region*. Cambridge: Cambridge University Press.
- Sonntag CF (1921) The comparative anatomy of the koala (*Phascolarctos cinereus*) and Vulpine phalanger (*Trichosurus vulpecula*). *Proc Zool Soc Lond* 39, 547–577.
- Taylor AM, Reby D (2010) The contribution of source-filter theory to mammal vocal communication research. *J Zool* 280, 221–236.
- Titze IR, Fitch WT, Hunter EJ, et al. (2010) Vocal power and pressure-flow relations in excised tiger larynges. *J Exp Biol* 213, 3866–3873.
- Toth CA, Parsons S (2018) The high-output singing displays of a lekking bat encode information on body size and individual identity. *Behav Ecol Sociobiol* 72, 102. <https://doi.org/10.1007/s00265-018-2496-4>.
- Volodin IA, Volodina EV (2002) uninterrupted vocalization in the striped possum *Dactylopsila trivirgata* (Marsupialia, Petauridae) during the whole respiratory cycle. *Zool Zh* 81, 1526–1529. [in Russian].
- Volodin IA, Lapshina EN, Volodina EV, et al. (2011) Nasal and oral calls in juvenile goitred gazelles (*Gazella subgutturosa*) and their potential to encode sex and identity. *Ethology* 117, 294–308.
- Volodin I, Volodina E, Frey R, et al. (2013) Spectrographic analysis points to source-filter coupling in rutting roars of Iberian red deer. *Acta Ethol* 16, 57–63.
- Volodin IA, Sibiryakova OV, Kokshunova LE, et al. (2014) Nasal and oral calls in mother and young trunk-nosed saiga antelopes, *Saiga tatarica*. *Bioacoustics* 23, 79–98.
- Volodin IA, Matrosova VA, Volodina EV, et al. (2015) Sex and age-class differences in calls of Iberian red deer during rut: reversed sex dimorphism of pitch and contrasting roars from farmed and wild stags. *Acta Ethol* 18, 19–29.
- Volodin IA, Efremova KO, Frey R, et al. (2017a) Vocal changes accompanying the descent of the larynx during ontogeny from neonates to adults in male and female goitred gazelles (*Gazella subgutturosa*). *Zoology* 120, 31–41.
- Volodin IA, Volodina EV, Frey R (2017b) Bull bellows and bugles: a remarkable convergence of low and high-frequency vocalizations between male domestic cattle *Bos taurus* and the rutting calls of Siberian and North American wapiti. *Bioacoustics* 26, 271–284.
- Volodin IA, Volodina EV, Frey R, et al. (2017c) Unusually high-pitched neonate distress calls of the open-habitat Mongolian gazelle (*Procapra gutturosa*) and their anatomical and hormonal predictors. *Sci Nat* 104, 50.
- Volodin IA, Náhlik András, Tari Tamás, et al. (2019) Rutting roars in native Pannonian red deer of Southern Hungary and the evidence of acoustic divergence of male sexual vocalization between Eastern and Western European red deer (*Cervus elaphus*). *Mammal Biol* 94, 54–65.
- Warren HB (1974) Aspects of the behaviour of the impala male *Aepyceros melampus* during the rut. *Arnoldia, Rhodesia* 6, 1–9.
- Weissengruber GE, Forstenpointner G, Peters G, et al. (2002) Hyoid apparatus and pharynx in the lion (*Panthera leo*), jaguar (*Panthera onca*), tiger (*Panthera tigris*), cheetah (*Acinonyx jubatus*) and domestic cat (*Felis silvestris* f. *catus*). *J Anat* 201, 195–209.
- Weissengruber GE, Forstenpointner G, Petzhold S, et al. (2008) Anatomical peculiarities of the vocal tract in felids, 15–21. In:

*Anatomical Imaging – Towards a New Morphology* (eds Endo H, Frey R), p. 105. Tokyo: Springer.

Wyman MT, Mooring MS, McCowan B, et al. (2012) Acoustic cues to size and quality in the vocalizations of male North American bison, *Bison bison*. *Anim Behav* **84**, 1381–1391.

## Supporting Information

Additional Supporting Information may be found in the online version of this article:

**Fig. S1.** The excised left thyroarytenoid muscle of an adult male impala.

**Fig. S2.** Contour of the thyroarytenoid muscle after its removal to show relationships to other laryngeal structures.

**Fig. S3.** Permanently descended hyoid apparatus and larynx in two adult lionesses.

**Video S1.** Rutting male impala, walking and producing several roars. Roar-synchronous larynx retraction is faintly visible at the ventral neck contour. The tongue is temporarily protruded.

**Video S2.** Rutting male impala, slowly galloping and producing several roars. Roar-synchronous movements of the larynx along the ventral neck contour faintly visible.

**Audio S1.** Male impala rutting calls: one rutting bout comprising snorts and continuous, interrupted and pant roars, and one continuous roar taken from a different bout.

**Table S1.** Vocal tract length (vtl) estimates in rutting adult male impala based on single video frames.

**Table S2.** Lengths of the individual parts of the hyoid apparatus of adult male impala.