



OPEN ACCESS

Low-dose transscleral cyclophotocoagulation with subsequent phacoemulsification in the treatment of prolonged acute primary angle closure

Yan Shi,¹ Julius Oatts ,² Jiaxin Tian,¹ Chunyan Qiao,¹ Qing Zhang,¹ Ying Han,² Ningli Wang

¹Department of Ophthalmology, Beijing Tongren Eye Center, Beijing Institute of Ophthalmology, Beijing Tongren Hospital, Capital Medical University, Beijing, China
²Department of Ophthalmology, University of California, San Francisco School of Medicine, San Francisco, California, USA

Correspondence to

Professor Ningli Wang, Beijing Tongren Eye Center, Beijing 100730, China; wningli@vip.163.com

YH and NW contributed equally.

Received 19 January 2021
Accepted 15 August 2021
Published Online First
30 August 2021

ABSTRACT

Background To explore the outcomes and mechanisms of intraocular pressure (IOP) control using low-dose transscleral cyclophotocoagulation (LDTSCP) followed by phacoemulsification in patients with prolonged acute primary angle closure (APAC).

Methods Patients with prolonged APAC refractory to all other treatment modalities were prospectively recruited, and underwent LDTSCP (10 shots, 2 s duration, 120° treatment with the energy starting at 1500 mW and titrated to the level with audible burst but not exceeding 2000 mW) and anterior chamber paracentesis 1 week prior to phacoemulsification with intraocular lens implantation and viscogoniosynechiolysis. Postoperative IOP, vision, anatomic changes on anterior segment optical coherence tomography and complications were recorded.

Results Twenty eyes with prolonged APAC were recruited. Median follow-up was 12 months (range 9–18), at which point the vision in all eyes had improved and IOP was ≤ 17 mm Hg on no antiglaucoma medications. Following LDTSCP at postoperative day (POD) 1, IOP decreased in all eyes to a median 15 mm Hg (range: 6–28 mm Hg). Post-LDTSCP supraciliary effusion (SCE) occurred in 90% of eyes on POD1 or POD7 and ciliary body defect (CBD) was detected in 30% of eyes and resolved in all cases by postoperative month 1. Lower post-LDTSCP IOP was associated with more number of bursts ($r=-0.558$, $p=0.011$) and higher grade of SCE ($r=-0.877$, $p<0.001$), but not with total energy ($p=0.240$). Eyes with CBD ($p=0.018$) and a higher number of bursts ($r=0.657$, $p=0.002$) had higher grade SCE.

Conclusions LDTSCP-induced SCE may explain the post-LDTSCP IOP reduction seen in eyes with prolonged APAC. LDTSCP instead of traditional more extensive treatment, was sufficient to provide a relatively safe and effective bridge therapy prior to phacoemulsification.

Trial registration number Chinese Clinical Trials Registry (ChiCTR1900023567).

than what we would expect in the western world.⁴ Typical emergency treatment options for those with prolonged APAC, including topical and systemic intraocular pressure (IOP)-lowering medications, anterior chamber paracentesis, followed by laser peripheral iridoplasty and/or iridotomy, may not always be possible due to corneal oedema and fixed dilated pupil, and is not effective in the prolonged cases with extensive synechial angle closure.^{3,5} Urgent surgical intervention such as cataract removal with or without an additional glaucoma procedure may be required.^{3,6,7} Of note, performing intraocular surgery on an inflamed eye with prolonged high IOP and corneal oedema poses a high risk of surgical failure and complications.^{3,7-9} In addition, these surgeries may be delayed due to the lack of availability of an operating room or experienced surgeon, particularly for those in rural areas. All these factors lead to increased rates of blindness in patients with prolonged APAC.⁴

Transscleral cyclophotocoagulation (TSCP) is a non-incisional laser procedure which can be performed easily by junior surgeons. TSCP has been described as a safe and effective treatment to provide some degree of IOP control in patients with APAC refractory to medical therapies before lens extraction in order to avoid emergent surgery in inflamed eyes and achieve a more favourable outcome.¹⁰⁻¹⁴ The treatment protocols reported in these studies vary widely, though evaluating the specific treatment parameters is important to maximise IOP control and minimise the risk of vision-threatening complications.¹⁵ Additionally, the mechanism of TSCP IOP lowering in APAC is not well understood. In this study, we performed fixed low-dose transscleral cyclophotocoagulation (LDTSCP) prior to phacoemulsification in patients with prolonged APAC and report the outcomes and mechanism of IOP control using this new surgical paradigm.

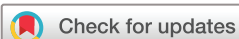MATERIALS AND METHODS

Patients

This prospective study recruited consecutive patients with prolonged APAC undergoing LDTSCP and sequential phacoemulsification by the same experienced surgeon (NW) between June 2019 and March 2020 at the Beijing Tongren Eye Center. The diagnosis of prolonged APAC was based on the presence of the following clinical features: (1) presence of at least two of the following symptoms: an antecedent

INTRODUCTION

Acute primary angle closure (APAC) is a leading cause of blindness in East Asian people, and timely management of the acute attack is important not only for preventing visual loss from the high-pressure episode but also for preventing progression to chronic angle closure glaucoma.¹⁻³ Regarding the current ophthalmic care in China, the average time from symptom to treatment was much longer



© Author(s) (or their employer(s)) 2023. Re-use permitted under CC BY-NC. No commercial re-use. See rights and permissions. Published by BMJ.

To cite: Shi Y, Oatts J, Tian J, et al. *Br J Ophthalmol* 2023;**107**:221–226.

history of ocular or periocular pain, nausea and/or vomiting, intermittent blurring of vision with haloes; (2) IOP >30 mm Hg by Goldmann applanation tonometry which lasted longer than 7 days after maximum topical and systemic medical therapy (including systemic acetazolamide and mannitol); (3) at least one anterior chamber paracentesis, attempted laser iridotomy/iridoplasty or surgical peripheral iridectomy; (4) the presence of all of the following signs: conjunctival injection, persistent corneal epithelial oedema, mid-dilated unreactive pupil, shallow anterior chamber and (5) the presence of a completely occluded angle, verified by gonioscopy, which was defined as areas of the angle where pigmented trabecular meshwork could not be visualised even with gonioscopy indentation. In patients who had bilateral prolonged APAC, only the eye with higher IOP was included. Patients meeting any of the following criteria were excluded: presence of additional ocular pathology, prior intraocular surgery (except surgical peripheral iridectomy), history of intraocular inflammation, trauma, congenital malformation or secondary angle closure, such as lens subluxation.

Clinical characteristic evaluation

All patients underwent an ophthalmic examination 1 day before LDTSCP and 1 and 7 days after LDTSCP. Postoperative follow-up after phacoemulsification was performed on postoperative day (POD) 1, 7 and month 1, 3, 6, 9, 12, 15 and 18. Patients whose clinical condition required closer follow-up were evaluated more frequently as determined by the treating physician. IOP was measured by Goldmann applanation tonometry. Best corrected visual acuity was measured using a Snellen acuity chart and was converted to logarithm of the minimum angle of resolution (logMAR) for analysis. The vertical cup-to-disc ratio (VCDR) was acquired by indirect ophthalmoscopic examination. Corneal endothelial cell density was measured by non-contact specular microscopy (Tomey EM-3000 NCSM, Tomey, Nagoya, Japan) and axial length was measured by IOLMaster (V.5, Carl-Zeiss Meditec, Dublin, California, USA). All surgical complications were recorded.

Low-dose transscleral cyclophotocoagulation

LDTSCP was performed by the same surgeon (YS) using the OcuLight SLx 810 nm diode laser photocoagulator and the handheld fiberoptic G-probe (Iris Medical Instruments, Mountain View, California, USA) in the operating room under standard sterile conditions.^{10–12} All treatments were performed under retrobulbar anaesthesia, a 2 mL injection of 2% lidocaine. The treatment was set at an initial power of 1500 mW with a duration of 2 s for the first shot and the treatment power was titrated upwards in 100 mW increments in the following shots until an audible ‘burst’ was heard, after which the treatment was completed using that power, no higher than 2000 mW. The total number of shots administered during the procedure (including shots during titrating without burst) was 10. Ten applications were spaced evenly over 120° at inferior hemifield, sparing the 3-o’clock and 9-o’clock regions. The probe was placed on the sclera corresponding to the location of ciliary body determined by transillumination. After LDTSCP, an anterior chamber paracentesis was performed and 0.5 mg of triamcinolone acetonide (TA, 40 mg/mL) was injected into the anterior chamber. Postoperatively, topical IOP-lowering medications excluding pilocarpine, were continued based on the IOP. Tobramycin-dexamethasone and pranopfen eye drops were prescribed four times per day until phacoemulsification.

Phacoemulsification with intraocular lens implantation and viscogoniosynechiolysis

One week following LDTSCP, phacoemulsification with intraocular lens (IOL) implantation and viscogoniosynechiolysis was performed under topical anaesthesia. After standard phacoemulsification and IOL implantation into the capsular bag, viscogoniosynechiolysis was performed by injecting viscoelastic near the circumferential angle to separate the peripheral synechia without making direct contact with the adjacent angle or iris. Postoperatively, patients were prescribed tobramycin-dexamethasone and pranopfen eye drops four times per day for 2 weeks.

Anterior segment optical coherence tomography acquisition and image analysis

Anterior segment imaging was obtained using anterior segment optical coherence tomography (AS-OCT) (SS-1000 CASIA, Tomey, Nagoya, Japan) performed by a single experienced investigator (YS) with patients in a seated position and identical room lighting conditions. Anterior chamber depth (ACD) was measured using anterior chamber mode and generated automatically after identification of the scleral spur using the built-in measurement software with manual correction.¹⁶ Ciliary body defects (CBD) and supraciliary effusion (SCE) were evaluated using angle-analysis mode. CBD were identified as hyporeflexive regions in the ciliary body in areas of prior LDTSCP treatment (figure 1). When assessing for SCE, AS-OCT was performed as posteriorly as possible beyond the scleral spur and SCE was defined as a clear space between the ciliary body and the sclera measured 3 mm posterior to the scleral spur on radial scans.¹⁷ SCE grading was performed as previously described,¹⁸ representative images are shown in figure 2. For eyes with different grades of SCE, the highest grade was used for analysis. All AS-OCT measurements including identification of the scleral spur, evaluation of CBD detection and SCE grading were confirmed by a second experienced observer (JT).

Statistical analysis

All statistical analyses were performed using SPSS (V.16.0) with $p < 0.05$ considered significant. IOP, number of medications, LogMAR visual acuity, ACD, degrees of occluded angle under gonioscopy and VCDR were presented by the median (range), and their differences at each time point were analysed using a linear mixed model with time as the repeated measurement. Bonferroni correction was used to counteract multiple comparisons. Spearman’s rank correlation was used to analyse the associations between parameters.

RESULTS

Patient characteristics

Twenty eyes of 20 consecutive prolonged APAC patients were enrolled in this study. Before referral to our clinic, all eyes had uncontrolled IOP after anterior chamber paracentesis, and corneal oedema and a fixed dilated pupil in the inflamed eyes prevented successful laser peripheral iridotomy/iridoplasty in all cases, and 10 patients underwent anterior chamber paracentesis two times, 5 had undergone surgical peripheral iridectomy. The time interval between onset of the first acute attack and LDTSCP ranged from 7 to 17 days, and all eyes underwent LDTSCP on the day of recruitment. Detailed patient characteristics are listed in table 1.

Clinical outcomes after LDTSCP

Table 2 shows outcomes following LDTSCP. Energy range was 35–38 J and there were no complications. Several ‘burst’ sounds were heard in each patient (median: 4.5, range: 2–8). Median

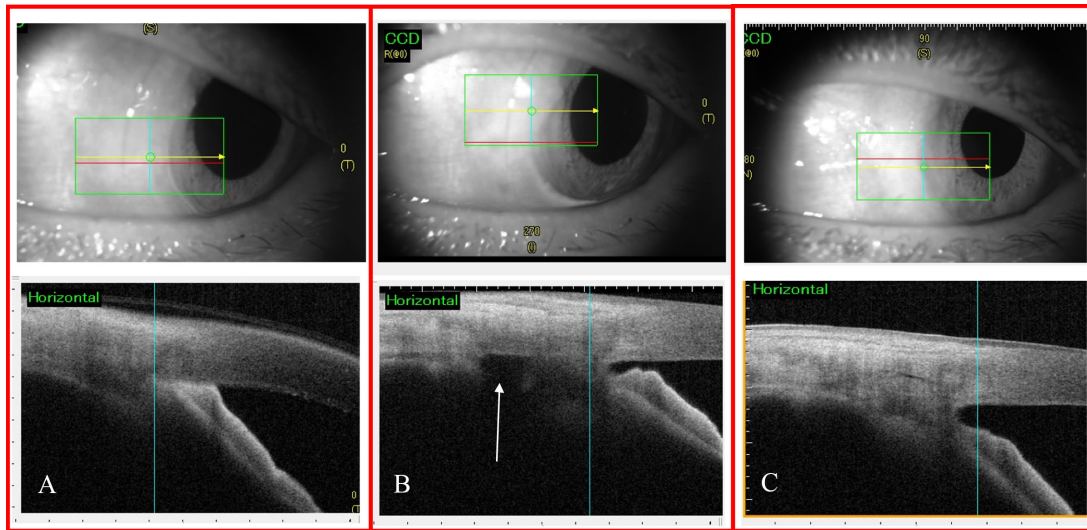


Figure 1 Evaluation of angle closure and ciliary body defect using anterior segment optical coherence tomography (AS-OCT) before and after intervention. (A) Preoperative angle closure with nasal irido-cornea contact. (B) Postoperative day 1 following low-dose transscleral cyclophotocoagulation demonstrating angle opening as well as a ciliary body defect (white arrow). (C) Postoperative 1 month following phacoemulsification showing persistent open angle and resolution of the ciliary body defect. The red line in each infrared image localises the corresponding AS-OCT scan below.

IOP decreased from baseline of 41.5 mm Hg (range: 33–54) to 15 mm Hg (range: 6–28) at POD1, and to 15 mm Hg (range: 10–26) on POD7. The median number of medications has changed from 5 (range: 3–5) before LDTSCP to 0 (range: 0–3) on POD7. Corneal oedema had resolved in all eyes on POD7. No patient experienced significant anterior chamber inflammation following the procedure.

We further explored the mechanism of IOP lowering following LDTSCP, and found that more number of bursts ($r = -0.558$, $p = 0.011$) and higher grade of SCE ($r = -0.877$, $p < 0.001$) were associated with lower POD1 IOP (figure 3A,C). There was no association between total energy and POD1 IOP ($p = 0.240$). SCE occurred in 16 eyes (80%) on POD1 and 15 eyes (75%) on POD7 and high-grade SCE was associated with lower IOP on POD7 ($r = -0.496$, $p = 0.026$) (figure 3B). Two eyes with no SCE on POD1 developed grade 1 SCE on POD7. The eight eyes which demonstrated improvement in SCE between POD1 and

POD7 had a corresponding increase in IOP (figure 3A,B). Ciliary body defect (CBD) was detected in 6 (30%) eyes on POD1. ACD increased at 1 and 7 days after LDTSCP, though ACDs at the two time points were not statistically significant compared with ACD measured at pre-LDTSCP (both $p > 0.05$). Median degrees of occluded angle reduced to 300° on POD7 (range 0–360), though this did not correlate with IOP or ACD change from baseline at that time point ($p > 0.05$). Higher grade SCE on POD1 was associated with CBD ($p = 0.018$) and a higher number of bursts ($r = 0.657$, $p = 0.002$) (figure 3D).

Clinical outcomes after phacoemulsification with IOL implantation and viscogoniolysis

IOP and number of medications decreased after phacoemulsification (table 2). At postoperative month 1 (POM1), no SCE or CBD were detected. Compared with pre-LDTSCP, AS-OCT measured ACD increased significantly in all eyes longitudinally along the total follow-up period ($p < 0.001$) (table 2). The median extent of occluded angle was 240° (range: 0–330), which remained stable through the last follow-up. Median VCDR

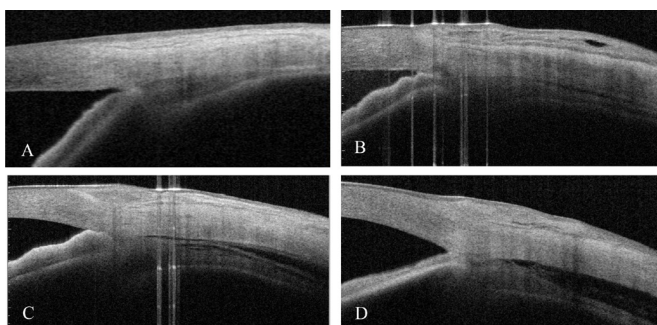


Figure 2 Grading of supraciliary effusion (SCE) using anterior segment optical coherence tomography. SCE was defined as a clear space between the ciliary body and sclera measured 3 mm posterior to the scleral spur on radial scans. (A) grade 0, no effusion; (B) grade 1, slit-like effusion with supraciliary space less than half the ciliary body thickness; (C) grade 2, band-like effusion with supraciliary space greater than half the ciliary body thickness; (D) grade 3, obvious effusion with supraciliary space greater than the ciliary body thickness.

Table 1 Summary of patient characteristics

Characteristics		
Number of patients (female/male)		20 (18/2)
Age (years, median (range))		66 (40–80)
Number of eyes (OD/OS)		20 (9/11)
Eyes with previous surgical peripheral iridotomy		5 (25%)
Days to LDTSCP (days, median (range))		10 (7–17)
LDTSCP settings	Energy (J, median (range))	38 (35–38)
	Number of bursts (median (range))	4.5 (2–8)
Corneal endothelial cell density (cells/mm ² , median (range))		2073.4 (569.1–2986.4)
Axial length (mm, median (range))		22.18 (20.96–23.66)
Follow-up duration (months, median (range))		12 (9–18)
Corneal endothelial cell density was measured 1 day prior to phacoemulsification. LDTSCP, low-dose transscleral cyclophotocoagulation; OD, right eye; OS, left eye.		

Table 2 Main clinical outcomes after LDTSCP and phacoemulsification in all patients

Time	1 day before LDTSCP	1 day after LDTSCP	7 days after LDTSCP	1 month after phacoemulsification	Last follow-up	P value
IOP (mm Hg; median, range)	41.5 (33–54)	15 (6–28)	15 (10–26)	11.5 (8–21)	13 (11–17)	<0.001*
logMAR VA (median, range)	CF (LP–1)	1.5 (LP–0.3)	1.4 (LP–0.3)	0.7 (1.7–0.1)	0.7 (1.7–0.1)	<0.001*
No. of Meds (median, range)	5 (3–5)	0	0 (0–3)	0	0	<0.001*
No. of eyes with SCE (grade 0/1/2/3)	20/0/0/0	4/9/5/2	5/13/2/0	20/0/0/0	20/0/0/0	–
ACD (mm; median, range)	1.508 (1.090–2.037)	1.675 (1.333–2.060)	1.713 (1.286–2.057)	3.599 (3.338–3.913)	3.598 (3.449–3.945)	<0.001*
VCDR (median, range)	–	–	0.65 (0.3–0.9)	0.8 (0.5–0.9)	0.8 (0.7–0.9)	0.010*
Degrees of occluded angle (degree, median, range)	360	–	300 (0–360)	240 (0–330)	240 (0–330)	<0.001*

*Statistical significance.

ACD, anterior chamber depth; CF, count finger; IOP, intraocular pressure; LDTSCP, low-dose transscleral cyclophotocoagulation; LP, light perception; Meds, medications; VA, visual acuity; VCDR, vertical cup-to-disc ratio.

increased from 0.65 (range: 0.3–0.9) before phacoemulsification to 0.8 (range: 0.5–0.9) at POM1 and 0.8 (range 0.7–0.9) at last visit ($p=0.010$). Of note, eight eyes had preoperative peripapillary oedema (defined as peripapillary retinal nerve fibre layer thickness greater than normal control database), which may have negatively skewed preoperative VCDR. At final follow-up, all patients had improved visual acuity from baseline and required no additional surgical interventions.

The only complication was posterior capsule rupture, which occurred in one eye with preoperative corneal endothelial cell density of $569.1/\text{mm}^2$ with recurrent intraoperative corneal oedema. In this case, the IOL was successfully implanted into the sulcus, and the corneal oedema resolved at POM1. Apart from this case, all other eyes had mild corneal oedema on POD1 which resolved 3–7 days after surgery. No residual TA was detected at POM1 and no patient had prolonged post-phacoemulsification inflammation.

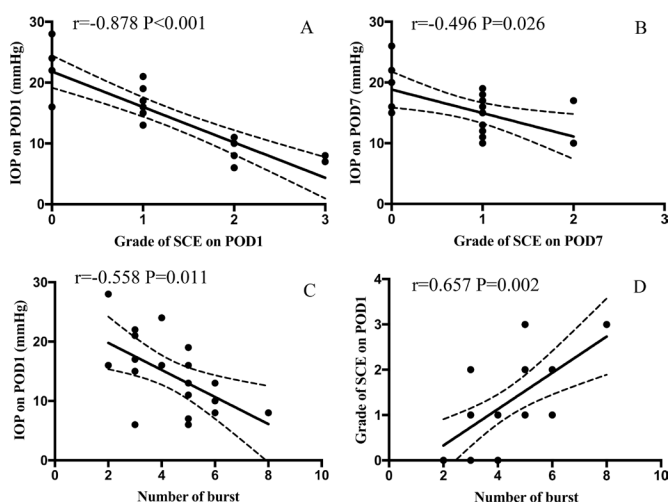


Figure 3 The association of intraocular pressure (IOP), supraciliary effusion (SCE) and number of bursts following low-dose transscleral cyclophotocoagulation by Spearman analysis. (A) The relationship of IOP and grade of SCE on postoperative day 1 (POD1) with mean and 95% prediction limits. (B) The relationship of IOP and grade of SCE on POD7 with mean and 95% prediction limits. (C) The relationship of IOP on POD1 and number of bursts with mean and 95% prediction limits. (D) The relationship of grade of SCE on POD1 and number of bursts with mean and 95% prediction limits. r , correlation coefficients, p , p values of the slopes of the Spearman analysis.

DISCUSSION

In this study, we describe a novel treatment protocol of LDTSCP followed by phacoemulsification in eyes with prolonged APAC and demonstrated excellent anatomic and functional outcomes. The goal behind this staged procedure was to lower IOP and increase the interval between the acute attack and phacoemulsification, allowing for safer phacoemulsification. LDTSCP leads to quick and sustainable IOP reduction, does not require an incision, and can be done by junior ophthalmologist as an emergency treatment, making it a promising bridge therapy for subsequent safer phacoemulsification.^{10–14}

All of our cases had a quick IOP reduction after LDTSCP. The mechanism of IOP control following LDTSCP in APAC is likely multifactorial. The primary mechanism of IOP reduction following TSCP is thought to be a reduction in the secretion of aqueous humour by ablation of ciliary body epithelium,¹⁹ though it is unlikely that this low-dose approach destroyed enough epithelium to significantly contribute to this mechanism, particularly when compared with the response in patients with neovascular, traumatic and uveitic glaucoma.²⁰ Another proposed mechanism of IOP lowering with this procedure is ciliary body process shrinking contributing to posterior movement of the peripheral iris and decreased angle crowding.²¹ While we did find angle opening after LDTSCP, this did not correlate with IOP at that time point, and even eyes with 360° of angle closure after LDTSCP showed a significant IOP reduction. These findings call into question the mechanism of IOP control in this group.

In this study, we found that higher grade SCE following LDTSCP was associated with lower IOP, and improvement in SCE had a corresponding increase in IOP, which suggested that SCE may importantly contribute to the IOP reduction following LDTSCP. Uveal effusion is frequently observed in eyes with APAC, which is usually associated with hypotony.^{17, 18, 22} The mechanisms of this phenomenon were thought to be caused by the sudden decrease of IOP due to ciliary body shutdown induced by the prolonged attack, and alteration in the capillary permeability after ischaemia of ciliary body.^{23–25} And it was reported that the suppression of aqueous humour may persist for 1 week in most cases after the halt on aqueous suppressants, thus causing the transient IOP reduction.¹⁷ In the present study, we did not find SCE in our patients prior LDTSCP, and we found that eyes with more audible ‘bursts’ and CBD had more severe SCE and greater levels of IOP reduction. We speculate that the direct tissue disruption of the ciliary body and LDTSCP-induced inflammation might be critical to cause ciliary body shutdown and subsequently the SCE

in these already susceptible eyes. Meanwhile, the relationship between IOP reduction and uveal effusion is well known and may be related to an increase in uveoscleral outflow,^{26 27} but the exact mechanism is still controversial.²⁸ Although the anterior chamber paracentesis performed after LDTSCP could have contributed to SCE and IOP lowering, this seems less likely considering that all patients underwent at least one previous anterior chamber paracentesis which did not treat the refractory angle closure or lower IOP.

Despite our lack of understanding of the dynamics of the APAC eye during SCE, it seems logical to conclude from the physiological relations that a pathological cycle is operative: the IOP reduction seems to perpetuate the effusion and the effusion seems to perpetuate the IOP reduction in our patient.²⁶ In any case, the LDTSCP-induced SCE was sufficient to provide a short period of IOP control as a relatively safe and effective bridge strategy for a safe sequential phacoemulsification in our patients.

In normal eyes, SCE is typically associated with shallow anterior chambers and angle crowding due to forward rotation of the ciliary body, relaxation of the zonules and lens thickening.¹⁷ On the contrary, our study found that post-LDTSCP SCE was associated with stable ACD and paradoxically, angle opening, suggesting a possible difference compared with traditional SCE. LDTSCP-induced damage or inflammation may change the structure of the anterior vitreous, which could lower posterior pressure and cause a backward movement of the lens-iris diaphragm leading to anterior chamber deepening and reopening of angle as seen in the malignant glaucoma and angle closure glaucoma.^{29–31} This also corresponds with the surgeon's anecdotal experience of less posterior pressure during phacoemulsification in eyes following LDTSCP. Also retention of aqueous humour in the vitreous body has been reported in eyes during an attack of APAC.³² Though more research is needed, this study suggests that understanding the effect of TSCP on anterior vitreous is of fundamental pathological interest for APAC.^{29 30}

Compared with our parameters, previous studies of TSCP have applied a higher total energy (68–110 J) with lower shot duration (power 1700 mW, duration 1 s) and report less IOP reduction.¹⁰ Other studies with similar effect of IOP reduction had variable settings, but all have 15–40 (mostly ≥ 20) shots with higher total energy.^{12–14} In this study, although we titrated power to burst level, we set maximum power at 2000 mW and the total number of shots as 10, which is half the number of shots classically reported.^{10–14} In fact, the number of bursts for each patient ranged from 2 to 8 with median number of burst as 4.5 (about 50% of total number of shots). The total energy used for each patient in this study did not exceed 38 J, which is much lower than the energy used with traditional treatment protocols. None of our patients developed severe hypotony or inflammation, and CBD all recovered within 1 month. Given our results, more aggressive treatment with 20 or more shots may be unnecessary and could increase the incidence of complications including severe and persistent hypotony and inflammation in this subset of eyes.^{10 14}

Our controlled LDTSCP protocol, using only 10 shots, may be still associated with anterior chamber inflammation. Postoperative inflammation control is crucial to prevent the formation of further peripheral anterior synechiae in these APAC eyes. Using an intracameral injection of 0.5 mg TA in all of our patients, none had obvious postoperative inflammation and this technique has been used widely by anterior-segment surgeons to control the inflammation after surgery as well.^{33 34} Other less invasive options, such as a more frequent using of topical steroid eyedrops, may be considered and evaluated in the future studies.

Although the IOP improved significantly in all patients following LDTSCP, phacoemulsification was recommended both to improve vision and maintain long-term IOP control following SCE resolution,¹⁷ particularly in those with closed angles. In our study, even eyes with more than 180° of angle closure and IOP >21 mm Hg after LDTSCP demonstrated good IOP control following phacoemulsification with IOL implantation and viscogoniosynechiolysis. This is likely because lens extraction in APAC can further deepen the anterior chamber, decrease angle crowding and improve the position of anteriorly displaced ciliary body processes, thus widening the angle.³⁵ Due to our treatment algorithm, the long-term effects of LDTSCP alone are difficult to ascertain. However, previous studies showed that the IOP can rise again in eyes without subsequent lens extraction,¹³ which supported the necessity of phacoemulsification in managing APAC eyes.

This study has several limitations. First, it was a non-comparative case series with a small sample size. Ideally, evaluation of alternative strategies for disease management is based on randomised clinical trials; however, we believe this treatment strategy has the advantage of creating time to find an experienced surgeon to perform delayed phacoemulsification, particularly useful in communities where access to tertiary care is limited. Second, one of the purported benefits of LDTSCP, as mentioned earlier, is that it is non-incisional, but an anterior chamber paracentesis and injection of intracameral steroid was performed at the time of LDTSCP. Other non-incisional methods to control post-LDTSCP inflammation should be further investigated. Third, although our study attempted to elucidate the underlying mechanisms for successful IOP control with this treatment strategy, further studies are needed to more completely understand this. Finally, only Chinese patients were recruited in this study, which may limit its application to other ethnic groups.

In conclusion, LDTSCP followed by phacoemulsification was a successful treatment algorithm for patients with prolonged APAC. The mechanism of IOP lowering may be due to SCE observed after LDTSCP in these eyes. Though more research is needed, this study sheds light on the underlying mechanisms behind the successful treatment of APAC. Understanding these mechanisms in the context of continued optimisation of treatment can provide better outcomes for patients with APAC.

Contributors NW conceived and designed the study, advised on the research and final approved the version to be published. YS conceived and designed the study, acquired and analysed data, drafted and revised the paper. YH conceived and designed the study, advised on the research and revised the paper. JO read and analysed documents, and edited the paper critically for intellectual content. JT, CQ and QZ acquired and analysed data. All these authors take responsibility for the content of the paper and are accountable for all aspects of the work in ensuring that questions related to the accuracy or integrity of any part of the work are appropriately investigated and resolved. YH and NW contributed equally as colist authors.

Funding This work was supported by Capital's Funds for Health Improvement and Research (No.2020-4-2059).

Competing interests None declared.

Patient consent for publication Not required.

Ethics approval This study was approved by the Ethics Committee of Beijing Tongren Hospital, adhered to the tenets of the Declaration of Helsinki. Informed consent was obtained from each patient.

Provenance and peer review Not commissioned; externally peer reviewed.

Data availability statement Data are available upon reasonable request. The deidentified participant data are available from Ningli Wang (email address: wningli@vip.163.com). Reuse is permitted when all the authors agree to do so. Protocols and statistical analysis plans are available as well.

Open access This is an open access article distributed in accordance with the Creative Commons Attribution Non Commercial (CC BY-NC 4.0) license, which permits others to distribute, remix, adapt, build upon this work non-commercially, and license their derivative works on different terms, provided the original work is properly cited, appropriate credit is given, any changes made indicated, and the use is non-commercial. See: <http://creativecommons.org/licenses/by-nc/4.0/>.

ORCID iDs

Julius Oatts <http://orcid.org/0000-0002-3945-2077>
Ningli Wang <http://orcid.org/0000-0002-8933-4482>

REFERENCES

- Lam DSC, Tham CCY, Lai JSM, *et al.* Current approaches to the management of acute primary angle closure. *Curr Opin Ophthalmol* 2007;18:146–51.
- Tan AM, Loon SC, Chew PT. Outcomes following acute primary angle closure in an Asian population. *Exp Ophthalmol* 2009;37:467–72.
- Boey PY, Singhal S, Perera SA, *et al.* Conventional and emerging treatments in the management of acute primary angle closure. *Clin Ophthalmol* 2012;6:417–24.
- Li S, Tang G, Fan SJ. Blindness short after treatment of acute primary angle closure in China. *Br J Ophthalmol* 2020;105:502–6.
- Aung T, Chew PT. Review of recent advancements in the understanding of primary angle-closure glaucoma. *Curr Opin Ophthalmol* 2002;13:89–93.
- Aung T, Tow SL, Yap EY, *et al.* Trabeculectomy for acute primary angle closure. *Ophthalmology* 2000;107:1298–302.
- Shi Y, Wang NL. Management of acute primary angle closure. In: Tham CCY, ed. *Primary angle closure glaucoma (PACG): a logical approach in management*. Singapore: Springer Nature, 2021: 121–9.
- Speaker MG, Guerriero PN, Met JA, *et al.* A case-control study of risk factors for intraoperative suprachoroidal expulsive hemorrhage. *Ophthalmology* 1991;98:202–10.
- Li S-W, Chen Y, Wu Q, *et al.* Angle parameter changes of phacoemulsification and combined phacotrabeculectomy for acute primary angle closure. *Int J Ophthalmol* 2015;8:742–7.
- Liu W, Chen Y, Lv Y, *et al.* Diode laser transscleral cyclophotocoagulation followed by phacotrabeculectomy on medically unresponsive acute primary angle closure eyes: the long-term result. *BMC Ophthalmol* 2014;14:26.
- Lai JSM, Tham CCY, Chan JCH, *et al.* Diode laser transscleral cyclophotocoagulation in the treatment of chronic angle-closure glaucoma: a preliminary study. *J Glaucoma* 2003;12:360–4.
- Yusuf IH, Shah M, Shaikh A, *et al.* Transscleral cyclophotocoagulation in refractory acute and chronic angle closure glaucoma. *BMJ Case Rep* 2015;2015:bcr2015209552.
- Chiam PJ, Sung VCT. The outcome of transscleral cyclophotocoagulation for the management of acute angle closure. *Eur J Ophthalmol* 2018;28:188–92.
- Manna A, Foster P, Papadopoulos M, *et al.* Cyclodiode laser in the treatment of acute angle closure. *Eye* 2012;26:742–5.
- Ishida K. Update on results and complications of cyclophotocoagulation. *Curr Opin Ophthalmol* 2013;24:102–10.
- Cumba RJ, Radhakrishnan S, Bell NP, *et al.* Reproducibility of scleral spur identification and angle measurements using fourier domain anterior segment optical coherence tomography. *J Ophthalmol* 2012;2012:487309.
- Yang J-G, Li J-J, Tian H, *et al.* Uveal effusion following acute primary angle-closure: a retrospective case series. *Int J Ophthalmol* 2017;10:406–12.
- Sakai H, Morine-Shinjo S, Shinzato M, *et al.* Uveal effusion in primary angle-closure glaucoma. *Ophthalmology* 2005;112:413–9.
- Dastiridou AI, Katsanos A, Denis P, *et al.* Cyclodestructive procedures in glaucoma: a review of current and emerging options. *Adv Ther* 2018;35:2103–27.
- Schlote T, Darse M, Rassmann K, *et al.* Efficacy and safety of contact transscleral diode laser cyclophotocoagulation for advanced glaucoma. *J Glaucoma* 2001;10:294–301.
- Schuman JS, Jacobson JJ, Puliafito CA, *et al.* Experimental use of semiconductor diode laser in contact transscleral cyclophotocoagulation in rabbits. *Arch Ophthalmol* 1990;108:1152–7.
- Gazzard G, Friedman DS, Devereux J, *et al.* Primary acute angle closure glaucoma associated with suprachoroidal fluid in three Chinese patients. *Eye* 2001;15:358–60.
- Fricke TR, Mantziros N, Vingrys AJ. Management of patients with narrow angles and acute angle-closure glaucoma. *Clin Exp Optom* 1998;81:255–66.
- Rao A, Gupta V, Garudadri CS. Atypical ocular ischaemia in angle-closure glaucoma and anaemia. *Int Ophthalmol* 2013;33:295–7.
- Amerasinghe N, Aung T. Angle-closure: risk factors, diagnosis and treatment. *Prog Brain Res* 2008;173:31–45.
- Pederson JE, Gaasterland DE, MacLellan HM. Experimental ciliochoroidal detachment. Effect on intraocular pressure and aqueous humor flow. *Arch Ophthalmol* 1979;97:536–41.
- Pederson JE. Outflow facility in acute experimental ciliochoroidal detachment. *Invest Ophthalmol Vis Sci* 1984;25:1231–2.
- Brubaker RF, Pederson JE, Ophthalmol S. Ciliochoroidal detachment. *Surv Ophthalmol* 1983;27:281–9.
- Quigley HA, Friedman DS, Congdon NG. Possible mechanisms of primary angle-closure and malignant glaucoma. *J Glaucoma* 2003;12:167–80.
- Shi Y, Tian J, Han Y, *et al.* Pathogenic role of the vitreous in angle-closure glaucoma with autosomal recessive bestrophinopathy: a case report. *BMC Ophthalmol* 2020;20:271.
- Shahid H, Salmon JF. Malignant glaucoma: a review of the modern literature. *J Ophthalmol* 2012;2012:852659.
- Epstein DL, Hashimoto JM, Anderson PJ, *et al.* Experimental perfusions through the anterior and vitreous chambers with possible relationships to malignant glaucoma. *Am J Ophthalmol* 1979;88:1078–86.
- Karalezli A, Borazan M, Kucukerdonmez C, *et al.* Effect of intracameral triamcinolone acetonide on postoperative intraocular pressure after cataract surgery. *Eye* 2010;24:619–23.
- Karalezli A, Borazan M, Akova YA. Intracameral triamcinolone acetonide to control postoperative inflammation following cataract surgery with phacoemulsification. *Acta Ophthalmol* 2008;86:183–7.
- Nonaka A, Kondo T, Kikuchi M, *et al.* Angle widening and alteration of ciliary process configuration after cataract surgery for primary angle closure. *Ophthalmology* 2006;113:437–41.