Dose-Response:
An International Journal
October-December 2021:1–17

DOI: 10.1177/15593258211056199
journals.sagepub.com/home/dos
SAGE

A Systematic Review on the Role of the Perfusion Computed Tomography in Abdominal Cancer

Nunzia Garbino[1], Valentina Brancato[1], Marco Salvatore[1], and Carlo Cavaliere[1]

Abstract

Background and purpose: Perfusion Computed Tomography (CTp) is an imaging technique which allows quantitative and qualitative evaluation of tissue perfusion through dynamic CT acquisitions. Since CTp is still considered a research tool in the field of abdominal imaging, the aim of this work is to provide a systematic summary of the current literature on CTp in the abdominal region to clarify the role of this technique for abdominal cancer applications.

Materials and Methods: A systematic literature search of PubMed, Web of Science, and Scopus was performed to identify original articles involving the use of CTp for clinical applications in abdominal cancer since 2011. Studies were included if they reported original data on CTp and investigated the clinical applications of CTp in abdominal cancer.

Results: Fifty-seven studies were finally included in the study. Most of the included articles (33/57) dealt with CTp at the level of the liver, while a low number of studies investigated CTp for oncologic diseases involving UGI tract (8/57), pancreas (8/57), kidneys (3/57), and colon–rectum (5/57).

Conclusions: Our study revealed that CTp could be a valuable functional imaging tool in the field of abdominal oncology, particularly as a biomarker for monitoring the response to anti-tumoral treatment.

Keywords

computed tomography perfusion, abdominal imaging, perfusion parameter, abdominal cancer

Introduction

Perfusion Computed Tomography (CTp) is a minimally invasive technique which allows quantitative and qualitative evaluation of tissue perfusion by injecting an iodinated contrast agent and performing dynamic CT acquisitions to estimate time enhancement curves within organs and tissues.[1-3] Physiological parameters, such as flow rate or local blood volume, can subsequently be calculated from the time enhancement curves by means of mathematical perfusion models. From a technical standpoint, CTp is the result of the development of new multi-slice CT systems and post-processing software and consists in a rapid serial images acquisition after bolus injection of a high flow (4–10 mL/s) iodinated contrast with a low contrast media volume (generally 40 to 50 mL).[4] The contrast injection with a high iodine concentration allows to increase the enhancement of the examined tissues. Then, by means of post-processing software, it is possible to obtain attenuation curves based on kinetic models and perfusion algorithms which vary depending on the organ investigated. Time attenuation curves are then analyzed to quantify color maps that represent the functional state of the vascular system such as blood flow (BF), blood volume (BV),

[1]IRCCS SDN, Naples, Italy

Received 2 August 2021; revised 6 October 2021; accepted 7 October 2021

Corresponding Author:
Valentina Brancato, IRCCS SDN, via E.Gianturco 113, Naples 80143, Italy.
Email: valentina.brancato@synlab.it

and contrast transit measurements such as mean transit time (MTT) and time to peak (TTP). Among the innovations that lead to the CTp development, there are the increase in the number of detectors, which allows to investigate larger body areas and reduce the thickness of the individual slices, improving the spatial resolution of the CT and consequently the image quality and information obtained. Moreover, the increase in the rotation frequency of the X-ray tube-detector complex improved the temporal resolution of the CT and reduced the duration of the scan, thus allowing to perform the breath examination suspended and reduce breath artifacts thanks also to the introduction of new filters for the noise attenuation and the use of special software for correction of patient movements. Finally, with the development of new image processing software, it is possible to calculate perfusion parameters with the creation of color maps relating to each pixel of tissue analyzed.[5] Based on these technical evolutions, CTp has been well established in the study of brain perfusion and has turned out to be the modality of choice for applications in this field.[6] In particular, CTp is largely used to assess acute stroke,[7,8] as well as to explore the tissue viability highlighting the changes in the mechanisms of self-regulation following an acute ischemia.[9] In the field of oncology, there has been an increasing interest in the use of CTp, with a wide range of clinical applications, including lesion detection and characterization, identification of metastases, prediction of prognostic information based on tumor vascularity, and prediction and assessment of response to chemoradiation treatments and antiangiogenetic drugs.[2]

In the field of abdominal imaging, CTp is still considered a research tool.[10] This is mainly because it requires the acquisition of multiple samples of the same anatomical region with relatively high temporal resolution, and this is generally associated with relatively high radiation exposure. Furthermore, results of CTp studies depend on the choice of acquisition parameters, mathematical perfusion model, software implementation, and the anatomical region.[11] However, the increasing availability and simplicity of CTp, together with its ability in quantification of the abnormal vasculature within tumors (thus allowing the assessment of tumor aggressiveness) led to a growing interest in CTp imaging method to examine several oncologic diseases associated with abdominal organs.[4,10] In particular, the ability of CTp to study microvascular changes in angiogenesis reflecting tumor perfusion in vivo could be of particular interest for investigating liver and pancreatic lesions.[12-15] In the management of hepatocarcinoma (HCC), CTp is considered a safe and specific imaging tool for diagnosis, choosing a therapeutic procedure, and evaluating response to therapy by showing changes in various perfusion parameters such as BV and TTP.[16] Moreover, in case of liver metastases, CTp allows the visualization of occult lesions in comparison to other imaging methods, thanks to the hemodynamic changes highlighted by an increase in the enhancement of the liver parenchyma during CT acquisition[17] and resulted useful for survival prediction and response to treatment.[18] CTp was also able to assess changes in liver cancer perfusion in response to a specific anticancer therapy.[19] CTp can help in the evaluation of malignant pancreatic tumors.[20] In fact, it was observed that extrapolated values from CTp, such as BF and BV, provided optimal sensitivity and specificity to differentiate pancreatic adenocarcinoma from mass-forming chronic pancreatitis.[21,22] Other studies have shown promising results concerning the role of CTp for colorectal cancer applications, such as diagnosis, angiogenesis evaluation, and pre-operative pathological grading.[23-26] The role of CTp was also investigated for diagnosis of kidney carcinoma.[27]

Based on these results, and thanks to the development of advanced equipment and the availability of commercial software platforms, CTp may provide a solid basis for obtaining additional functional imaging information, as an integral part of a conventional CT exam that could change the diagnostic and therapeutic process of patients with tumors involving abdominal district tumors.[6] However, the still present drawbacks, mainly related with the lacking consensus on which CT protocol to use and the fact that published literature is based on small studies with different perfusion algorithms, have resulted in the missing integration of CTp into routine clinical practice protocols for abdominal imaging.[28] In this context, we performed a systematic literature review on the application of CTp in abdominal cancer to provide a systematic overview of the application of CTp in abdominal cancer and clarify the role of this technique for abdominal imaging in clinical practice.

Materials and Methods

Search Strategy and Selection Criteria

A systematic literature research was performed to identify all original articles investigating the role of CTp for oncological applications in the abdominal district. The most relevant scientific electronic databases (PubMed, Web of Science, and Scopus) were explored and used to build the literature search. Studies published from 2011 to April 2021 were selected. The search strategy included keywords listed in Supplementary Materials-S1 section. The literature search was limited to English language publications and studies on human subjects. Two reviewers, after having independently screened identified titles and abstracts, assessed the full text of articles that evaluated the use of CTp in the abdominal district and that were original articles (not review articles, case studies). For articles meeting these criteria with full text available, the following further selection criteria had to be fulfilled: involvement of adult patients (age > 18); missing information on the CTp parameters investigated.

Data Extraction and Study Planning

After selection procedure, the following data were extrapolated from selected articles and collected in a table: author names; publication year; study type (retrospective and/or prospective); clinical purpose (diagnosis, grading, prognosis, response to treatment); sample number; info on study group analyzed in the study; anatomic district of interest; perfusion acquisition details;

information on placement of regions of interest (ROIs), namely the segmentation method (manual, semi-automatic, automatic) and the ROI type (2D or 3D); main results; and conclusions. The articles were classified and analyzed according to the abdominal area investigated in the study.

This systematic review was conducted in accordance with the Preferred Reporting Items for Systematic Reviews and Meta-Analyses (PRISMA) statement[29] (See Supplementary Materials-S2 section-for PRISMA Checklist).

Quality Assessment

The quality of the included studies was assessed through the QUADAS-2 tool for diagnostic studies and the QUIPS tool for prognostic studies. Two reviewers independently assessed the quality of each study, and any disagreements were resolved by consensus. For the QUADAS-2 tool, four domains were evaluated: (1) patient selection, (2) index test, (3) reference standard, and (4) flow and timing. At each domain, the quality of the elements was classified as "low," "high," or "unclear."[30] For QUIPS, six domains were evaluated: (1) study participant selection, (2) study dropout, (3) prognostic factor measurement, (4) outcome measurement, (5) study confusion, and (6) statistical analysis and reporting. The bias risk assessment was obtained using the answers "yes," "partial," "no," or "don't know" for 3 to 7 elements within each domain and were combined to assign an overall rating for each domain as "high," "moderate," or "low" risk of bias.[31,32]

Results

Study Selection

A total of 544 articles were retrieved from the PubMed, Web of Science, and Scopus databases. Following the removal of 72 duplicate articles, was performed a screening based on titles and abstracts of the remaining 472 articles. 364 records in this step were excluded for the following reasons: 100 were case reports and 264 were off-topic/review articles. The screening by titles and abstracts produced 108 articles, potentially usable for the systematic review description, of which the full text was evaluated. Of these articles, 17 records were excluded because they were not in English and 34 articles were off-topic and/or review articles. Among articles that were out of topic, 4 studies were excluded because they had a methodological purpose, while 3 were excluded because they aimed at investigated repeatability and reproducibility of CTp parameters. Finally, 57 records were included for the qualitative synthesis. The PRISMA flowchart of studies included according to the inclusion and exclusion criteria was reported in Figure 1.

Characteristics of Included Studies

Characteristics of the 57 selected articles are summarized in Table 1. The median number of individuals (range) was 37 (7-126). Study designs were 68.4% (39/57) prospective

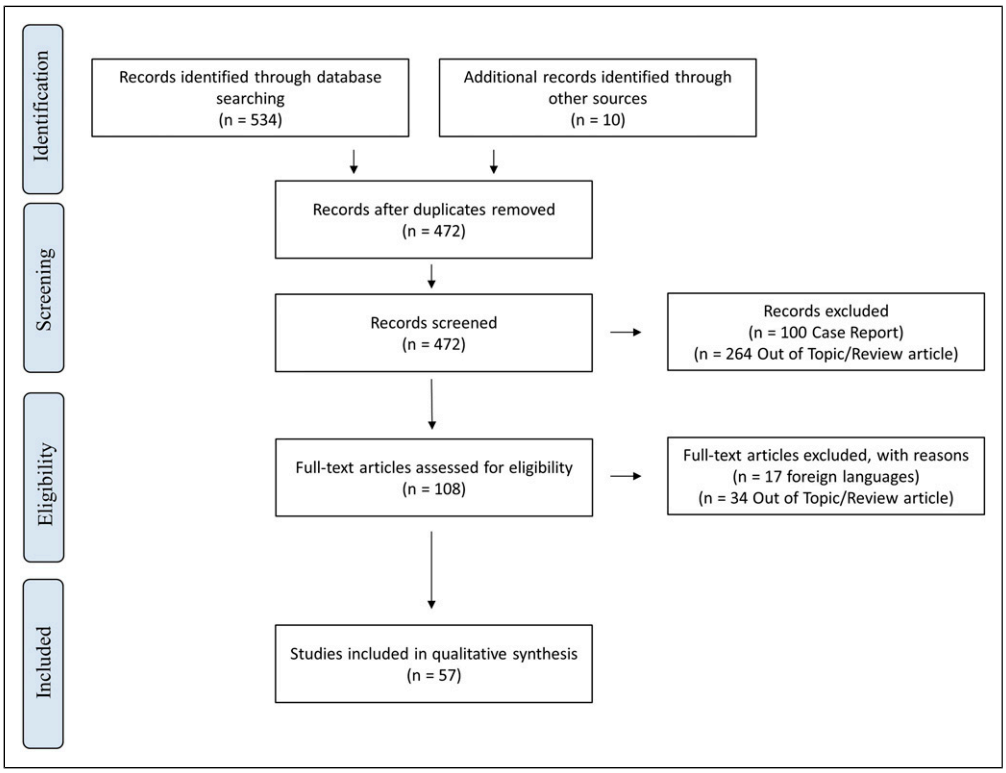

Figure 1. Preferred reporting items for systematic reviews and meta-analyses (PRISMA) flow diagram.

Table 1. Characteristics of Included Studies. R = retrospective; P = prospective; FOV = field of view; M = manual; S = semi-automatic; A = automatic; mVI = microvascular invasion; MVD = microvessel density; HCC = Hepatocellular carcinoma; PDAC = pancreatic ductal adenocarcinoma; mNET = neuroendocrine tumors; PanNETs = pancreatic neuroendocrine tumors; AP = acute pancreatitis; CP = chronic pancreatitis; AML = angiomyolipoma; NASH = Non-Alcoholic SteatoHepatitis; CRC = colorectal cancer; pRCC = papillary renal cell carcinoma; ccRCC = clear cell RCC; CRLM = colorectal cancer liver metastases; CCRT = concurrent chemoradiotherapy; GEJ = gastroesophageal junction; GIST = Gastrointestinal stromal tumor; AGC = Advanced Gastric Cancer; LAGC = locally advanced gastric cancer; RFA = radiofrequency ablation; IL-8 = interleukin 8; FU1 = after TACE; FU2 = follow-up; TACE = transarterial chemoembolization; TARE = transarterial radioembolization; TACLI = transarterial chemo-lipiodol infusion; CR = complete response; PR = partial response; SD = stable disease; PD = progressive disease; SBRT = Stereotactic body radiotherapy; TZ = transition zone; CZ = central zone; PZ = surrounding parenchymal zone; DEB-TACE = doxorubicin-eluted bead-TACE; AUC = area under the curve; MFCP = mass-forming chronic pancreatitis.

Author	Y	Study type	Aim	Clinical purpose	Patients	Zone	Acquisition details	ROI Info	CTp parameters	Results	Conclusion
Delrue et al[33]	2011	R	Compare perfusion parameters in different pancreatic diseases with a control population	Diagnosis	54 [21 healthy population; 19 adenocarcinomas; 3 AP; 3 CP; 2 Neuroendocrine tumors; 3 (Pseudo)cystic lesions]	Pancreas	Tube voltage: 100 kVp; tube current-time product: 145 mAs; slice thickness: 5 mm; FOV: 376 mm; total duration of acquisition: 51 s	M; 2D ROI	BV, BF and PS	BF and BV are significantly lower in AP and CP compared to the control group. In adenocarcinoma tumors, BF and BV are lower but gradually increasing toward the tumor rim	Compared to the control population, significant decreases in perfusion values were observed in all pancreatic pathologies under study, except in neuroendocrine tumors
Delrue et al[34]	2011	R	Evaluate CTp characteristics in the normal pancreas and in patients with pancreatic adenocarcinoma	Diagnosis	40 [20 healthy subjects and 20 patients with pancreatic adenocarcinoma]	Pancreas	Tube voltage: 100 kVp; tube current-time product: 145 mAs; slice thickness: 5 mm; FOV: 376 mm; total duration of acquisition: 51 s	M; 2D ROI	BV, BF and PS	Compared with the normal pancreas, a 60% reduction in BF and BV was observed in the tumor tissue. Perfusion values gradually increased toward the tumor rim	CTp allows non-invasive assessment of vascularization in the tumor tissue
Lu et al[35]	2011	R	Investigate CTp in patients with pancreatic cancer and mass-forming CP	Diagnosis	112 [64 with Pancreatic Adenocarcinoma; 15 with ass-forming CP and 33 healthy volunteers]	Pancreas	Tube voltage: 80 kV; tube current: 100 mA; matrix: 512 x 512 pixels; total duration of acquisition: 50 s	M; 2D ROI	BV, BF, TTP, PEI, PS	BF and BV lower in patients with pancreatic adenocarcinoma than in controls. PS is higher in pancreatic adenocarcinoma than in controls and in CP than in controls and lower in cancer than CP. PEI is lower and TTP is longer in pancreatic adenocarcinoma than CP	CTp can provide additional quantitative hemodynamic information of pancreatic adenocarcinoma and mass-forming CP
Petralia et al[36]	2011	P	Evaluate the role of CTp for monitoring and predicting therapy response in patients with HCC treated with thalidomide	Prognosis/ response to treatment	24 with HCC	Liver	Tube voltage: 100 kVp; tube current: 240 mA; perfusion scan delay: 9 s	M; 2D ROI	BV, BF; MTT and PS	BF and BV are higher in patients with progressive disease with cut-off values for BF and BV predicting progressive disease in 83.3% and 77.8%	Baseline BF and BV predict response to therapy
Schlemmer et al[37]	2011	R	Evaluation of CTp patterns in metastatic GIST lesions with sunitinib or imatinib in responders and non-responders	Response to treatment	24 [46 lesions (31 in the liver and 15 in the peritoneal cavity)]	UGI tract	Tube voltage: 100 kV; tube current-time product: 80 mAs; slice thickness: 4 mm × 7.2 mm; perfusion scan time: 6 s/10 s	M; 2D ROI	BF, BV, PS and HAPI	In the extrahepatic and intrahepatic lesions good responders show significant lower perfusion values than poor responders	Characteristic perfusion patterns of metastatic GIST lesions show a good or poor response to molecular pharmacotherapy
Yao et al[38]	2011	P	Evaluate relationship between CTp and gastric tumor angiogenesis	Prognosis	37 with gastric adenocarcinoma	UGI tract	Tube voltage: 120 kV; tube current-time product: 100 mAs; matrix: 512 x 512; perfusion scan delay: 5 s	M; 2D ROI	Perfusion, PEI, TTP and BV	MVD of gastric adenocarcinoma is significantly correlated with BV	BV reflect the angiogenesis in gastric adenocarcinoma
Curvo-Semedo et al[39]	2012	P	Evaluate changes in colorectal cancer vascularity following chemotherapy and correlate baseline perfusion and post-treatment using CTp	Response to treatment	20 affected by colon–rectal cancer	Colon	Tube voltage: 120 kVp; tube current: 300 mA; perfusion scan delay: 5 s	M; 2D ROI	BV, BF; MTT and PS	Baseline BF is significantly lower and MTT is significantly higher in respondents. Baseline BV and PS are not significantly different in responders and non-responders. BF, BV and PS decreased after chemotherapy compared to baseline, while MTT increased	Baseline BF and MTT may discriminate responders from non-responders to chemotherapy
Ippolito et al[40]	2012	P	Assess the role of CTP in detection of BF changes related to the therapeutic effects in HCC lesion treated with RFA.	Response to treatment	14 cirrhotic patients with known HCC	Liver	Tube voltage: 120 kV; tube current: 120 mA; matrix: 512 x 512; slice thickness: 3 mm; perfusion scan delay: 7 s	M; 2D ROI	Perfusion, HAP, BV, HPI and TTP	Significant difference is observed in mean values of Perfusion, HAP, and HPI, calculated between treated lesions with residual tumor and those successfully treated	CTp enables assessment of HCC vascularity after RFA treatment
Jiang et al[41]	2012	P	Investigate the CTp as a biomarker and monitor and predict long-term outcome in advanced HCC treated	Response to treatment/ survival prediction	23 with HCC	Liver	Tube voltage: 100 to 120 kVp; tube current: 200 to 240 Ma; perfusion scan delay: 8 to 10 s; total duration of acquisition: 25 to 30 s	M; 2D ROI	BV, BF; MTT and PS	After bevacizumab, there is a significant decrease in CTp parameters. Furthermore, tumors with higher baseline MTT values on CTp correlate with favorable clinical outcome and had better 6 months progression-free survival	CTp is a sensitive biomarker for monitoring early antiangiogenic treatment effects as well as in predicting outcome at the end of treatment and progression-free survival

(continued)

Table 1. (continued)

Author	Y	Study type	Aim	Clinical purpose	Patients	Zone	Acquisition details	ROI Info	CTp parameters	Results	Conclusion
Kanda et al[42]	2012	P	Evaluation of liver diseases and therapeutic effects with perfusion measurement of 320-detector row CT	Diagnosis/ response to treatment	38 [30 (normal group) and 8 (disease group)]	Liver	Tube voltage: 80 kV; tube current-time product: 210 or 250 mA; slice thickness: .5 mm; matrix: 512 × 512;; perfusion scan delay: 7-120 s	M; 2D ROI	HAP, HPP and APF	There are no significant differences in the normal group except, APF for the third and fifth hepatic segments, fundus and antrum. Mean HAP and APF in disease are significantly higher of the normal group	Perfusion values have the potential for evaluation of liver disease and therapeutic effects
Khan et al[43]	2012	R	Determine the feasibility of vascular quantification for different anatomical segments of the colorectum	Diagnosis	39 with colorectal cancer	Colon	Tube voltage: 120 kV; tube current-time product: 60 mAs; perfusion scan delay: 5 s; total duration of acquisition: 65 s	M; 2D ROI	BV, BF, MTT and PS	Mean BF is higher in the proximal than distal colorectum. Mean BV is higher, MTT shorter, and PS measurements lower for the proximal colon but this is not statistically significant	The colorectum demonstrates segmental differences in perfusion
Kim et al[44]	2012	P	Compare pre-operative CTp parameters with tumor grade from CRC and with MVD to evaluate angiogenesis	GRADING	27 [8 with differentiated; 15 with moderately differentiated and 4 poorly differentiated]	Colon	Tube voltage: 80 kVp; tube current: 200 mA; slice thickness: 5 mm; FOV: 33 cm; matrix: 512 x 512 mm; perfusion scan delay: 5 s	M; 2D ROI	BV, BF, MTT and PS	BF is higher in moderately differentiated CRC than well-differentiated and poorly differentiated CRCs. MTT is shorter in moderately differentiated than well-differentiated and poorly differentiated CRCs. There is no significant correlation between other perfusion parameters and tumor grade	BF and MTT measurement by perfusion CT is effective in predicting moderately differentiated CRCs
Yang et al[45]	2012	p	Evaluate CTp in the therapeutic response of chemoembolization for HCC	Response to treatment	24 [12 with a solitary tumor, and 12 with multiple tumors]	Liver	Tube voltage: 120 kV; tube current: 150 mA; FOV: 320 mm; perfusion scan delay: 6 s	M; 2D ROI	HAP, HPP, TLP and HAPI	The values of HAP, TLP, and HAPI in tumors 4 weeks after chemoembolization are significantly decreased than those before chemoembolization	CTp evaluate the perfusion changes in HCC after chemoembolization and it can assess the therapeutic response of chemoembolization
Chen et al[46]	2013	P	Evaluate relationships between BF of HCC measured by CTp and four circulating angiogenic factors	Prognosis	21 [12 with solitary HCC and 9 with multiple HCCs]	Liver	Tube voltage: 100 kVp; tube current: 240 mA; perfusion scan delay: 7 s	M; 2D ROI	BF	The HCC-parenchyma ratio of arterial BF showed a significantly positive correlation with the level of circulating IL-8	IL-8, provides a non-invasive tool for assessment of BF in HCC
Morsbach et al[18]	2013	P	Assess CTp to predict the morphologic response and survival after TARE	Response to treatment/ survival prediction	38 with liver metastases	Liver	Tube voltage: 100 kVp; tube current-time product: 150 mAs; perfusion scan delay: 5 s	M; 3D ROI	HAP	Significant difference in HAP is found on pre-treatment CTp between the responders and the non-responders to the TARE and a significantly higher 1-year survival after the TARE is found in the patients with a pre-treatment HAP	HAP of liver metastases enables prediction of short-term morphologic response and 1-year survival to TARE
Bai et al[47]	2014	P	Evaluate relationship between CTp and histopathologic findings in the periphery of HCC lesions	DIAGNOSIS	77 [47 with HCC and 30 controls]	Liver	Tube voltage: 120 kV; tube current: 280 mA; matrix: 512×512; perfusion scan delay: 5 s	M; 2D ROI	HAP, HPP, HBF and HAFr	BF, HAFr, HAP and HPP are significantly increased in the tumor edges of HCC patients compared to those of the controls	CTp of tumor edges may be helpful in revealing histopathological features and reflect angiogenic changes of HCCs
Bayraktutan et al[48]	2014	P	Evaluate the role of CTp in patients with HCC	Diagnosis	17 with HCC	Liver	Tube voltage: 120 kV; tube current: 150 mA; FOV: 320 mm	M; 2D ROI	BV, BF, HAP, HPP and HAPI	BF, BV, HAP, and HAPI are shown to be significantly higher in the HCC lesions than in the surrounding liver parenchyma and HPP is found to be significantly lower in HCC relative to liver parenchyma	CTp has the ability to evaluate tumor assessment, characterization, and neoangiogenesis in HCC
Chen et al[27]	2014	P	Investigate microcirculatory differences between pathologic types of kidney tumor using CTp	Diagnosis	85 [66 with ccRCC; 7 with pRCC; 5 affected by chromophobe and 7 AML with minimal fat]	Kidney	Tube voltage: 100 kV; tube current: 100 mA; perfusion scan delay: 8 s	M; 2D ROI	BF, Equiv BV and PS	Equiv BV is significantly different between RCC and AML with minimal fat and between ccRCC and AML with minimal fat. Mean Equiv BV and BF are significantly higher in ccRCC than in pRCC and mean Equiv BV is higher in ccRCC than in chromophobe RCC	CTp evaluate hemodynamic features of the whole kidney and kidney tumors useful in the differential diagnosis of these four pathologic types of kidney tumor
Hansen et al[49]	2014	P	Assess reductions in CT perfusion parameters can predict response to pre-operative chemotherapy prior to surgery for GEJ and gastric cancer	Response to treatment	28 affected by adenocarcinoma of the GEJ and stomach	UGI tract	Tube voltage: 100 kV; tune current: 100 mA; 7.5 and 13.5 s; total duration of acquisition: 55 to 60 s	M; 2D ROI	BF, BV and PS	Significant changes in PS and tumor volume are apparent after 3 series of chemotherapy in both clinical and histological responders	Early decrease in permeability is correlated with the likelihood of clinical response to pre-operative chemotherapy in GEJ and gastric cancer

(continued)

Table 1. (continued)

Author	Y	Study type	Aim	Clinical purpose	Patients	Zone	Acquisition details	ROI Info	CTp parameters	Results	Conclusion
Ippolito et al[50]	2014	P	Determine the value of CTp for the diagnosis and treatment of HCC	Diagnosis/ response to treatment	47 [21 with hepatitis B; 17 affected by hepatitis C; 6 alcohol-related and 3 with hepatitis C and alcohol-related]	Liver	Tube voltage: 100 kV; tube current: 120 mA; matrix: 512 × 512; slice thickness: 3 mm; Perfusion scan delay: 7 s; total duration of acquisition: 50 s	M; 2D ROI	Perfusion, HAP, BV, HAPI and TTP	Significantly lower perfusion values are obtained in correctly treated lesions or surrounding parenchyma than in viable hepatocellular carcinoma tissue	CTp contribute to a non-invasive quantification of tumor blood supply related to the formation of new arterial structures and evaluates the therapeutic response
Nishikawa et al[51]	2014	R	To find the relationship between prognosis in pancreatic cancer and perfusion in tissue surrounding pancreatic tumor through perfusion CT	Prognosis	17 with inoperable pancreatic adenocarcinoma	Pancreas	Tube voltage: 80 kVp; tube current: 40 mA; perfusion scan delay: 3 s	M; 2D ROI	BF	There is a significant correlation between peritumoral AUC or BF and survival days. Higher AUC or BF values are associated with shorter survival but there isn't any significant correlation between tumoral AUC or BF and survival	The perfusion in pancreatic tissue within proximal pancreatic parenchyma may be useful in predicting prognosis
Reiner et al[52]	2014	P	Evaluate CTp for assessment of early treatment response after TARE	Response to treatment/ survival prediction	40 [27 with liver metastases and 13 affected by HCC]	Liver	Tube voltage: 100 Kv; tube current: 150 mAs; perfusion scan delay: 5 s	M; 3D ROI	HAP	Liver metastases show significant differences in HAP before and after TARE in responders but not in non-responders and in HCC, HAP before and after TARE are not significantly different in responders and non-responders	In patients with liver metastases, a decrease of HAP after TARE is Associated with a higher 1-year overall survival rate
Singh et al[53]	2014	P	Determine the role of CTp in differentiating hemangiomas from malignant hepatic lesions	Diagnosis	45 [27 cases of metastases; 9 cases of HCC and 9 cases of hemangiomas]	Liver	Tube voltage: 80-100 kV; tube current: 150-300 mAs/Auto mAs; perfusion scan delay: 5 s; total duration of acquisition: 45 s	M; 2D ROI	BV, BF, MTT, PS, HAFr and IRFTO	Significant changes are observed in the perfusion parameters at the periphery of different lesions. Above all BF, HAFr, and IRFTO show most significant changes	CTp is a helpful tool in differentiating hemangiomas from hepatic malignancy
Wang et al[54]	2014	P	Observe the change in blood perfusion of liver cancer following argon-helium knife treatment with CTp	Response to treatment	27 patients with liver cancer	Liver	Tube voltage: 120 kV; tube current: 40 mA; matrix: 1024 x 1024 mm; slice thickness: 5 mm; Perfusion scan delay: 5 s; Total duration of acquisition: 50 s	M; 2D ROI	HBF, HBV, HAP, HPP and HAFr	All parameters in liver cancer are significantly decreased after argon-helium knife treatment and there is a significant decrease in HAP observed in pericancerous liver tissue while other parameters kept constant	CTp is able to detect decrease in blood perfusion of liver cancer post-argon-helium knife therapy
Du et al[55]	2015	P	Evaluate the clinical value of CT in TACE treatment for HCC	Response to treatment	64 with HCC	Liver	Tube voltage: 80 kV; tube current-time product: 100 mA; FOV: 300 mm × 350 mm; perfusion scan delay: 5 s	M; 2D ROI	HAP, HAPI and HPP	Mean HAP, PVP and HAPI for the tumor ARE significantly higher than for the normal liver tissue. Before TACE, the values of HAP and HAPI are significantly reduced, and there is a statistically significant difference	CT one-stop examination can display the abnormal perfusion of HCC tissues and postoperative active tissues
Kaufmann et al[56]	2015	P	Characterize HCC in terms of perfusion parameters using CTp and two different calculation methods	Prognosis	79 [38 with HBV and HCV; 23 alcohol induced; 12 patients with cryptogenic; 4 with NASH and 2 with hemochromatosis]	Liver	Tube voltage: 100 kV; tube current-time product: 120 mAs; perfusion scan delay: 7 s; total duration of acquisition: 40 s	M; 2D ROI	HAP, HPP, HAPI, BF, BV and k-trans	Best correlation between calculation methods is achieved for measurements of BF	CTp can measure tumor volume perfusion non-invasively and enables quantification of the degree of HCC arterialization
Kaufmann et al[57]	2015	P	Response monitoring of TACE with CTp	Response to treatment	45 [14 with HBV or HCV; 13 with alcohol abuse; 1 with hemochromatosis; 8 affected by liver disease of mixed etiology and 9 with cryptogenic liver disease]	Liver	Tube voltage: 80 kV; tube current-time product: 100–120 mAs; perfusion scan delay: 7 s; total duration of acquisition: 40 s	M; 3D ROI	HAP, HPP and HAPI	There is a significant increase of the HAP between baseline and FU1 in the liver parenchyma coupled by a significant subsequent decrease of HAP and HPI between FU1 and FU2	CTp accurately measures impact of TACE on liver tumor and hepatic parenchymal perfusion
Lv et al[58]	2015	P	Evaluate CTp in predicting the early response to TACLI and survival of patients with CRLM	Response to treatment/ survival prediction	61 with CRLM	Liver	Slice thickness: 5 mm; matrix: 512 x 512 pixels; perfusion scan delay: 5 s	M; 2D ROI	HAP, HBV, HBF, HPP, HAFr, MTT and PS	The best cut-off value was −21.5% and patients who exhibited a ≥ 21.5% decrease in HAP had a significantly higher overall survival rate than those who exhibited a < 21.5% decrease	CTp predict the early response to TACLI and survival of patients with CRLM
Reiner et al[59]	2015	P	Assess if analysis of the HCC heterogeneity by CTp helps predicting response to TARE	Prognosis/ response to treatment	16 with HCC	Liver	Tube voltage: 100 kVp tube current-time product: 150 mAs; perfusion scan delay: 5 s	M; 3D ROI	HAP	The histogram analysis of AP values reveals significantly higher values for responders compared to non-responders for the 50th and 75th percentile of AP values. No significant difference between HAP of responders and non-responders	CTp indicates tumor heterogeneity of HCC and improves the pre-treatment prediction of response to TARE

(continued)

Table 1. (continued)

Author	Y	Study type	Aim	Clinical purpose	Patients	Zone	Acquisition details	ROI Info	CTp parameters	Results	Conclusion
Sun et al[60]	2015	P	CTp for the prognosis assessment of gastric cancer	Grading	50 [17 lesions located in cardia, 13 in body, and 20 in the gastric antral]	UGI tract	Tube voltage: 120 kV; tube current-time product: 100 mAs; FOV: 4.8 mm; perfusion scan delay: 7 s	M; 2D ROI	BF, BV, PS and MTT	BF, BV, and PS are statistically significant between the well-differentiated group and the moderate differentiation group; BF, BV, and PS are statistically significant between the well-differentiated group and the poor differentiation group. MTT value show no statistical difference among the 3 groups	BF, BV and PS values could serve as indicators of the degree of malignancy and aid in prognostic assessment of gastric cancer
Sun et al[61]	2015	R	Explore characteristics of different gastric cancers on CTp	Grading	50 [17 lesions located in cardia, 13 in body, and 20 in the gastric antral]	UGI tract	Tube voltage: 120 kV; tube current-time product: 100 mAs; FOV: 4.8 mm; perfusion scan delay: 7 s	M; 2D ROI	BF, BV, PS and MTT	Differences between the well-differentiated and the moderate differentiation group are statistically significant for BF, BV, and PS. Differences between the well-differentiated and the poor differentiation group are statistically significant for BF, BV, and PS	BV and PS values could serve as indicators of the degree of malignancy and aid in prognostic assessments of gastric cancer
Wu et al[62]	2015	R	Examine mVI in patients with HCC tith CTp parameters	Prognosis	56 [18 patients have sHCC with mVI and 38 patients have sHCC without mVI]	Liver	Tube voltage: 100 kVp; tube current: 100 mA; total duration of acquisition: 66 s	M; 2D ROI	HAF, PVF and PEI	The tumor PVF, difference in PVF between tumor and liver tissue and the PVF/liver PVF ratio are significantly higher in sHCC with mVI than in sHCC without mVI	CTp parameters can predict mVI in patients with sHCC
Xu et al[63]	2015	R	Predict the grade of colorectal adenocarcinoma through CTp	Grading	34 affected by sigmoid colon cancer; 7 lesions in descending colon; 3 with transverse colon tumor; 3 patients with a lesion in ascending colon and 5 in cecum	Colon	Tube voltage: 100 kV; tube current: 80 mA; matrix: 512 × 512; FOV: 500	M; 2D ROI	BV, BF, TTP and PEI	There are significant differences in BF and TTP between low and high tumors	BF and TTP parameters can reflect tumor grade in colorectal adenocarcinoma
Marquez et al[64]	2016	R	Assess CTp to examine the treatment response in patients undergoing RFA of focal liver lesions	Response to treatment	20 [10 patients with liver metastases and 10 with HCC]	Liver	Total duration of acquisition: 43 s	M; 2D ROI	HAPI, HPP, HAP	Mean HAP/HPP/HAPI are 4.8/15.4/61.2 for the CZ, 9.9/16.8/66.3 for the TZ and 20.7/29.0/61.8 for the PZ. Inter-reader agreement of HAPI is fair for the CZ, good for the TZ, and excellent for the PZ. Furthermore, there are significant differences in HPI of the CZ and TZ between responders and non-responders	Increased HAPI of the necrotic TZ after RFA might evaluate residual tumor in patients with focal liver lesions
Su et al[65]	2016	P	Assess the role of CTp to predict response to TACE in patients with HCC	Prognosis/ response to treatment	39 patients (46 HCC lesions)	Liver	Tube voltage: 100 kV; tube current: 120 mA; perfusion scan delay: 7 s; total duration of acquisition: 48 s	M; 2D ROI	HAP, HPP and HAPI	The responders demonstrate higher HAP and HAPI and lower HPP compared with the non-responders in lesions without portal vein or portal branch thrombosis	HAP and HAPI Are good prognostic values
Yadav et al[21]	2016	R	Differentiate pancreatic adenocarcinoma from MFCP	Diagnosis	42 with pancreatic adenocarcinoma; 13 affected by MFCP and 25 control group	Pancreas	Tube voltage: 100 kVp; tube current: 100 mA; slice thickness: 5 mm; FOV: 300 mm	M; 2D ROI	BF, BV, MTT, TTP and PEI	BF and BV are the most reliable for differentiating between adenocarcinoma and mass-forming pancreatitis. Although they are reduced in both pancreatic adenocarcinoma and MFCP as compared to normal controls	CTp may serve as an additional paradigm for differentiating pancreatic adenocarcinoma from mass-forming CP
Zongqiong et al[66]	2016	P	The role of CTp in gastric cancer	Grading	70 [20 control group and 50 with gastric cancer]	UGI tract	Tube voltage: 120 kV; tube current-time product: 100 mAs; FOV: small; slice thickness: 4.8 mm; perfusion scan delay: 7 s; total duration of acquisition: 30 s	M; 2D ROI	BV, BF and PS	Differences between the well-differentiated and the moderately differentiated group or the poorly differentiated are all statistically significant for BF, BV, and PS	BF, BV and PS can be indicators to discriminate the gastric cancer malignancy
D'Onofrio et al[67]	2017	P	Perfusion changes in patients affected by liver metastases from PanNETs during everolimus therapy	Response to treatment	9 patients (33 liver metastases)	Liver	Tube voltage: 120 kVp; tube current: 100 mAs; slice thickness: 5 mm; perfusion scan delay: 7 s	M; 2D ROI	Perfusion, PEI, BV and TTP	BV increase is the most significant perfusional parameter in responding lesions, even at an early stage of therapy, with a high positive predictive value	CTp can predict the response to everolimus of liver metastases from PanNETs
Kaufmann et al[68]	2017	P	CTp to detect early therapeutic response in patients with HCC	Response to treatment	28 patients with HCC	Liver	/	/	BF, BV, MTT, k-trans, HAPI and HAP	Significant decrease is found in BF, BV, k-trans, HAP, and HAPI in patients with SD as well as a significant increase in MTT after two months compared to baseline. PD group show a significant increase in HAPI, BF and BV	Lower BF and HAPI after two months of sorafenib therapy predict disease stabilization after four months

(continued)

Table 1. (continued)

Author	Y	Study type	Aim	Clinical purpose	Patients	Zone	Acquisition details	ROI Info	CTp parameters	Results	Conclusion
Marquez et al[69]	2017	P	Monitor the perfusion changes in patients with HCC after DEB-TACE	Response to treatment	24 with HCC	Liver	/	M; 2D ROI	HAP, HPP and HAPI	HPP before DEB-TACE is significantly higher in pre-treated vs non-treated lesions. Mean changes of HAP, HPP and HAPI from before to after DEB-TACE are −55%, +24% and −27%. HAP and HAPI after DEB-TACE are relating with response-grades	The perfusion changes of HCC early after DEB-TACE show incomplete response with good diagnostic accuracy
Mohammed et al[70]	2017	P	Compare the accuracy of washout and CTp in diagnosis of adrenal tumors	Diagnosis	38 (15 patients with adrenal masses were metastasis)	Adrenal	Tube voltage: 120 kV; tube current-time product: 180 mAs; matrix; 512 x 512	M; 2D ROI	Perfusion, PEI, TTP and BV	BV differentiates adenomas and non-adenomas with an 80% sensitivity, 75% specificity and 77.1% accuracy	CTp can distinguish from adrenal adenomas and non-adenomas using BV; however, washout CT was more accurate than perfusion CTp
Popovic et al[71]	2017	R	CTp to predict the response to treatment and overall survival in patients affected by HCC and treated with DEB-TACE	Response to treatment/ survival prediction	18 patients with intermediate stage HCC	Liver	Tube voltage: 80 kV; tube current: 100 mA; slice thickness: 6 mm; matrix: 512 × 512 mm; perfusion scan delay: 6 s; total duration of acquisition: 55 s	M; 3D ROI	BV, BF, TTP, PS, HAP, HPP and HAPI	Survival is statistically significantly longer in patients with BF lower than 50.44 mL/100 mL/min, BV lower than 13.32 mL/100 mL and TTP longer than 19.035 s	CTp can predict survival in patients with intermediate stage HCC, treated with DEB-TACE based on the pre-treatment values of BF, BV and TTP perfusion parameters, but this technique can't be used to predict treatment response to DEB-TACE
Shalaby et al[16]	2017	R	CTp for diagnosis and monitoring of HCC	Diagnosis/ response to treatment	126 patients (141 lesions)	Liver	Tube voltage: 100 kv; tube current: 60 mA; perfusion scan delay: 4 s	M; 2D ROI	HAP, PEI and PF	141 lesions present 94% sensitivity and 40% specificity with elevated HAP and PEI and with PF	CTp can diagnose and monitor HCC
Tamandl et al[72]	2017	P	Analyze the role of CTp for early response assessment after TACE for HCC	Response to treatment	16 patients [41 HCC]	Liver	/	M, 3D ROI	BV, BF, TTS, HAP, HPP and HAPI	CTp parameters are significantly reduced after TACE in responders while no difference is shown in non-responders	CTp detects lesions with complete response one day after TACE
Aslan et al[73]	2018	P	Distinguish PDAC from pancreatitis through CTp	Diagnosis	61 cases with PDAC and 12 cases with MFCP	Pancreas	Tube voltage: 100 kVp; tube current-time product: 100 mAs; slice thickness: 5 mm; FOV: 300 mm	M; 2D ROI	BV, BF, MTT and PS	Compared with normal parenchyma, BV, BF, PS are lower and MTT is longer in PDAC and MFCP. Compared with MFCP, BV, BF, PS are lower and MTT is longer in PDAC. Compared with normal parenchyma, BV, BF, PS are lower and MTT is longer in isoattenuating lesions	CTp can help diagnose PDAC and characterize isoattenuating lesions
Deniffel et al[74]	2018	P	Evaluate perfusion parameters of the normal renal and of the renal tumors, extrapolated through different mathematical models	Diagnosis	35 [21: ccRCCs; 6: pRCC; 5: oncocytomas; 1: angiomyolipoma; 1: tubulocystic-RCC; 1: chromophobe RCC]	Kidney	Tube voltage: 100 kVp; tube current: 60 to 150 mA; matrix: 512 x 512; slice thickness: .5 mm; total duration of acquisition: 95 s	M; 2D ROI	BV, BF and MTT	There are significant differences and poor agreement between BF, BV and MTT for most models in both normal renal cortex and several renal cancers	BF and BV are a useful tool in the differential diagnosis of kidney tumors using the Patlak model
Detsky et al[75]	2018	P	Assess perfusion changes of liver metastases in patients treated with both bevacizumab and SBRT	Response to treatment	7 patients treated with both bevacizumab and SBRT	Liver	/	/	BV, BF and PS	After bevacizumab, a significant decrease is found in PS and BV, while with SBRT present a significant reduction in PS and B	After bevacizumab and SBRT perfusion changes can be studied
Ippolito et al[76]	2018	R	Evaluate the role of CTp in the early detection of BF changes correlated to sorafenib in patients with advanced HCC	Response to treatment	43 with liver cirrhosis and intermediate-to-advanced HCC	Liver	Tube voltage: 100 kV; tube current: 120 mA; matrix: 512 x 512; slice thickness: 3-mm; perfusion scan delay: 7 s; total duration of acquisition: 56 s	M; 2D ROI	Perfusion, HAP, HAPI and TTP	CTp values are significantly higher between baseline and follow-up in the CR and PR groups, while there aren't significant differences in SD patients and a significant trend toward increase in PD group	CTp helps to evaluate the therapeutic response to sorafenib in advanced HCC
Liang et al[77]	2018	R	Analyze the predictive value of CTp to evaluate efficacy of pre-operative CCRT in middle-aged and elderly patients with LAGC	Response to treatment/ survival prediction	126 [60 tumors in gastric Cardia; 27 lesions in the gastric corpus; 28 in the gastric antrum and 11 tumors in the entire stomach]	UGI tract	Slice thickness: 5 mm	/	BV, BF, MTT and PS	Patients with low BF, BV, and PS (compared to cut-off) have longer survival times than these with high BF, BV, and PS	CTp can predict the pre-operative CCRT efficacy in the LAGC therapy

(continued)

Table 1. (continued)

Author	Y	Study type	Aim	Clinical purpose	Patients	Zone	Acquisition details	ROI Info	CTp parameters	Results	Conclusion
Nakamura et al[78]	2018	P	The role of CTp such as biomarkers predictive of the prognosis of HCC treated with sorafenib	Response to treatment/ prognosis	36 affected by HCC	Liver	Tube voltage: 80 kV; tube current: .5; slice thickness: .5-mm; FOV: 32.0-42.8 cm; perfusion scan delay: 4 s	M; 2D ROI	HAP and HPP	Pre-HAP tumor is significantly related to the overall survival rate. The overall survival rate is higher in patients with pre-HAPtumor > 71.7 mL/min/100 mL, and with HAPtumor ratio ≦ 1.1	CTp can predict overall survival in HCC patients treated with sorafenib, such as biomarker
Ng et al[79]	2018	R	Assess the effects of bevacizumab and Everolimus on CTp in liver metastases from mNET and healthy liver	Response to treatment	27 with mNETs	Liver	/	M; 2D ROI	BV, BF, HAFr, MTT and PS	In tumor with mono-therapy with bevacizumab, BV is significantly reduced. During dual-therapy, BV and BF are significantly lower than baseline in both arms. No significant effects on CTp parameters in healthy liver	Bevacizumab and everolimus have significant effects on CTp parameters in mNETs and healthy tissue
Shen et al[80]	2018	R	CTp to monitor the Sorafenib changes in patients affected by HCC	Response to treatment	23 with HCC	Liver	Tube voltage: 100 kVp; tube current: 100 mA; perfusion scan delay: 7 s; total duration of acquisition: 74 s	M, 2D ROI	HAF, PVF, PEI	The group of responders to sorafenib shows a significantly decreased HAF value after 2 months compared to that of baseline, while non-responder group shows a significant increase in HAF. Finally, patients with PD show significantly higher HAF compared to that of SD patients	CTp can analyze the Sorafenib effects in HCC lesions
Andersen et al[81]	2019	P	Evaluate the CTp parameters during regorafenib in patients with treatment-refractory metastatic CRC	Response to treatment	33 [27 with liver lesions; 3 with abdominal lesions and 3 with pulmonary lesions]	Colon	Tube voltage: 100 kVp; tube current-time product: 100 mAs; perfusion scan delay: 15 s	M; 3D ROI	PEI, PS, BV, HPI, HPBV and HPMTT	During the treatment, there is a significant decrease of perfusion parameters over time. Changes are shown in the early phase of therapy and subsided or withdrew completely over time	There is a significant decrease in most dynamic parameters that highlight an overall treatment effect of regorafenib in tumor vasculature
Hamdy et al[82]	2019	P	Study CTp to predict the response of PDAC to CRT	Response to treatment	21 patients with PDAC	Pancreas	Tube voltage: 80 kVp; slice thickness: 3 mm; perfusion scan delay: 2 s	M; 2D ROI	BV, BF and PS	Baseline BF is higher in responders than in non-responders, while BV and PS are similar between groups	CTp can help predict the histopathological response to therapy in PDAC
Lee et al[83]	2019	P	Evaluate whether data acquired from CTp parameters can predict treatment outcome after palliative chemotherapy in patients with unresectable AGC	Response to treatment	21 [19 have distant metastasis in 2 patients there is invasion of the pancreas by AGC]	UGI tract	Tube voltage: 80 kVp; tube current-time product: 100 mAs; perfusion scan delay: 6 s	M; 2D ROI	BV, BF, TTP, MTT and PS	PS shows a significantly different between the responder and non-responder groups, whereas other CTp parameters do not demonstrate a significant difference	CTp parameters demonstrate predictive value for treatment outcome after palliative chemotherapy
Tian et al[84]	2020	R	Search a correlation between sorafenib-targeted genes and CTp to predict the response to sorafenib in advanced HCC	Prognosis/ response to treatment	21 patients with suspected liver tumors	Liver	Tube voltage: 100 kVp; tube current: 100 mA; perfusion scan delay: 8 s; total duration of acquisition: 74 s	M; 2D ROI	HAF, PVF, and HAPI	Tumor tissues present higher HAF	RAF1 expression might predict effects of sorafenib in advanced HCC
Zaborienė et al[22]	2021	P	Define the role of CTp in PDAC	Diagnosis	112 [56 with PDAC and 56 with nontumorous pancreatic]	Pancreas	Tube voltage: 120 kVp; tube current-time product: 150 mAs; slice thickness: 5 mm; FOV: 300 mm; total duration of acquisition: 50 s	M; 2D ROI	BV, BF, MTT and PS	BF and BV exceed the cut-off therefore the probability of the presence of PDAC is 97.69%	BF and BV can be independent diagnostic criteria to predict the presence of PDAC

and 31.5% (18/57) retrospective. Thirty-three studies involved the application of CTp in liver cancer (57.8%), 8 investigated the role of CTp in cancers of upper gastrointestinal tract (14%), 8 were on CTp in pancreatic cancer (14%), 3 on CTp in renal cancers (5.2%), and the remaining 5 were on CTp in colon–rectal cancer (8.7%). To facilitate the reading of Table 1, as well as to provide an organized summary of the CTp parameters investigated in the included studies, a list of perfusion parameters was provided in Table 2 with the corresponding definition and physiological meaning. Refer to Figure 2 for a graphic visualization of the obtained results according to the organs and clinical purposes investigated in the selected studies. Moreover, refer to Table 3 for a schematic representation of CTp parameters investigated in the included studies, according to the specific abdominal area and the clinical purpose.

Computed Tomography in Liver Cancer

Among studies on liver tumors, fourteen aimed at evaluating the role of CTp for prediction and assessment of response to treatment. Ippolito et al[40] found that CTp was able to assess HCC vascularity after radiofrequency ablation treatment by means of perfusion, HAO, and HPI features. Similar results were found by Marque et al, even if their study also involved patients with liver metastases other than HCC. Promising results were found by Yang et al[45] for patients with HCC treated with chemoembolization. Wang et al[54] found that all CTp parameters investigated in their study were significantly decreasing in HCC after argon–helium knife therapy. Four studies found that CTp parameters were able to assess response to TACE treatment in HCC patients.[55,57,69,72] Results from 3 studies[68,76,80] revealed that CTp could help to evaluate the therapeutic response in HCC patients treated with

Table 2. Summary of Perfusion Computed Tomography Parameters Used in the Included Studies.

CTp parameter (acronym)	Extended name	Definition	Units
BF (or Perfusion)	Blood flow	Flow rate in tissue region	mL per 100 g/min
BV	Blood volume	Volume of flowing blood In tissue region	mL per 100 g
Equiv BV	Equivalent blood volume	—	ml/100 g
PS	Permeability surface area-product	Total flux from plasma to interstitial space	mL per 100 g/min
MTT	Mean transit time	Average time taken to travel from artery to vein	Seconds
TTP	Time to peak	Time from arrival of the contrast in major arterial vessels to the peak enhancement	Seconds
TTS	Time to start	Intervals between contrast injection and the beginning of contrast enhancement	Seconds
PEI	Peak enhancement intensity	Maximum increase in tissue density after contrast injection	HU
HAP	Hepatic arterial perfusion	Perfusion of hepatic artery	mL/min per mL
HPP	Hepatic portal perfusion	Portal vein perfusion of the liver	mL/min per mL
HAPI	Hepatic arterial perfusion index	HAP/TLP	%
HPI	Hepatic perfusion index	HAP/(HAP + HPP)*100	%
APF	Arterial perfusion fraction	Perfusion percentage of the total blood from the arterial blood supply	%
HAFr	Hepatic arterial fraction	Percentage of the total blood input from the arterial blood supply	%
HAF	Hepatic artery flow	Hepatic artery perfusion	mL/min per mL
TLP	Total liver perfusion	Total perfusion of liver	mL/min per mL
K-trans	Transit constant	Sum of the flow within the microvasculature and capillary permeability	—
PF	Portal flow	Flow of portal vein	mL per 100 g/min
HBF	Hepatic blood flow	Flow rate in hepatic tissue	mL per 100 g/min
HBV	Hepatic blood volume	Volume of flowing blood in liver	mL per 100 g
HPBV	Hepatic portal blood volume	Volume of flowing blood hepatic region	mL per 100 g
HPMTT	Hepatic portal mean transit time	Average time taken to travel from artery to vein	Seconds
PVF	Portal vein flow	Flow rate in hepatic tissue	mL per 100 g/min
IRFTO	Induced residue fraction time of onset	—	Seconds
Tmax	Transit time to impulse residue function peak	Time to maximum of the residue function	Seconds

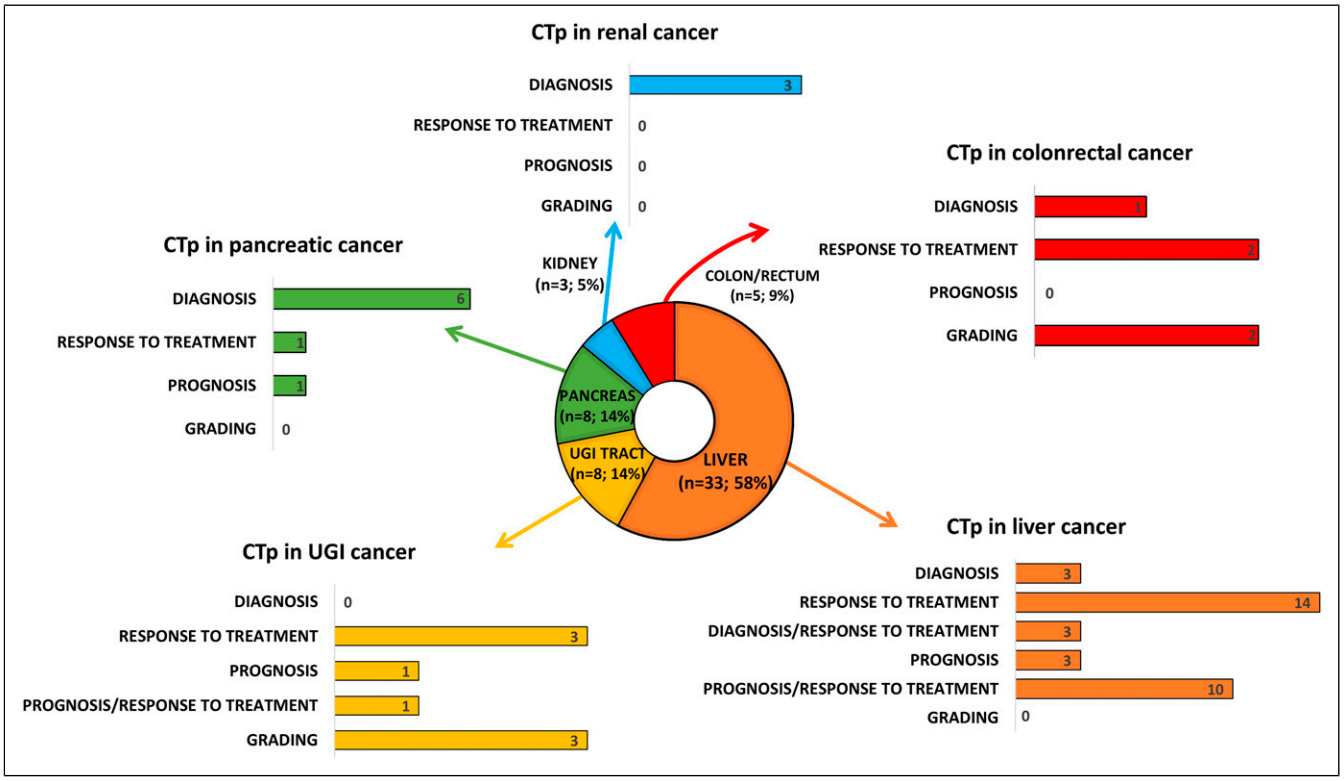

Figure 2. Graphic summary of the systematic review results according to the abdominal zone and clinical purposes investigated in the selected studies. The donut chart shows the number of included studies according to the abdominal zone investigated (liver in orange; upper gastrointestinal tract in yellow; pancreas in green; kidneys in blue; colon/rectum in red). Number and percentage of studies included in each of the five groups were reported investigates. For each group, the bar plots show the number of studies according to the clinical purpose investigated. Abbreviations: UGI = Upper Gastrointestinal.

sorafenib. D'Onofrio et al[67] and Ng et al[79] evaluated the role of CTp in patients with liver metastases arising from pancreatic neuroendocrine tumors and found that CTp was able to predict response to everolimus and bevacizumab therapy. Similar results were found by Detsky et al[75] for patients with liver metastases treated with both bevacizumab and stereotactic body radiotherapy. Three studies on liver tumors had diagnostic clinical purpose. Bai et al[47] found that CTp parameters (BF, HAFr, HAP, and HPP) were able to detect HCC lesion from healthy liver. Similar results were found by Bayraktutan et al.[48] However, their study did not involve control patients, but they used as reference only the surrounding liver parenchyma of HCC patients. Singh et al[53] found that CTp was a helpful tool in differentiating hemangiomas from HCC and liver metastases. Three studies investigated CTp for prognostic purposes. Kaufmann[56] found that CTp was able to quantify the degree of HCC arterialization. Wu et al[62] findings were in line with those from Kaufmann et al[56] since they found that values associated with PVF parameter were able to predict microvascular invasion in patients with HCC. Chen et al[46] found that arterial BF of HCC lesions was correlated with circulating angiogenetic factors. The remaining thirteen studies had multiple purposes. Specifically, ten investigated CTp for both prognosis and response to treatment assessment of liver cancer and 3 were on diagnosis and response to treatment. Among studies on prognosis and response to treatment, seven were on HCC. Petralia et al[36] found that BF and BV could predict response to thalidomide treatment and progressive disease. Jiang et al[41] found that, in HCC patients treated with bevacizumab, CTp parameters were able to monitor treatment effect as well as predict progression-free survival. By means of a histogram analysis of HAP, the work by Reiner et al[59] revealed that CTp was able to predict response to TARE in HCC. Similar results were also found by Su et al in HCC patients treated with TACE. Results by Popovic et al[71] revealed that CTp could predict survival in patients with intermediate stage HCC treated with DEB-TACE. However, this technique was not able to assess response to treatment. Nakamura et al[78] found that CTp was able to predict overall survival in HCC patients treated with sorafenib. Three studies assessed the role of CTp to predict response to treatment and prognosis in patients with liver metastases,[18,52,58] of which one involved patients with both liver metastases and HCC.[52] Finally, the remaining 3 studies found that several CTp parameters had both diagnostic

Table 3. Perfusion Computed Tomography (CTp) Parameters Investigated in the Included Studies, According to the Specific Abdominal Area and the Clinical Purpose. Refer to Table 2 for the Extended Name and Meaning of CTp Parameters. Abbreviations: UGI = Upper Gastrointestinal.

		Clinical purpose			
		Diagnosis	Response to treatment	Prognosis	Grading
Abdominal zone	Liver	HAP; HPP; HBF; HAFr; BV; BF; HAPI; MTT; TTP; IRFTO; PS	BV; HBV; BF; HBF; MTT; PS; Perfusion; HAP; HPI; HAPI; TTP; TTS; HPP; APF; HAFr; HAF	BV; BF; MTT; PS; HAP; TTP; HBV; HBF; HPP; HAFr; HAF; PVF; HAPI; k-trans; PEI	—
	Pancreas	BV; BF; PS; MTT; TTP; PEI	BF; BV; PS	BF; BV; PS	—
	UGI tract	—	BF; BV; PS; MTT; TTP; HAPI	BV; BF; MTT; PS; PEI; TTP	BF; BV; PS; MTT
	Kidney	BV; Equiv BV; BF; PEI; Perfusion; TTP; MTT; PS	—	—	—
	Colon	BV; BF; PS; MTT	PEI; PS; BV; HPI; HPBV; HPMTT; BF; MTT	—	BV; BF; MTT; PS; TTP; PEI

power and were able to predict response to treatment.[16,42,50] Any study on grading of liver cancer was found.

Computed Tomography in UGI Cancer

Considering the 8 articles highlighting the role of CTp in UGI tract, three investigated the power of CTp parameters for grade assessment of gastric cancer and both 3 found that BF, BV, and PS were able to differentiate poor-, moderately-, and well-differentiated gastric cancer.[60,61,66] Three studies aimed at assessing the role of CTp for response to treatment in patient with UGI cancer, of which two involved patients with gastric cancer[49,83] and the other one included patients with metastatic gastrointestinal stromal tumors (GIST).[37] Both found that CTp parameters were able to assess clinical response to different treatment regimens. Yao et al[38] aimed at evaluating prognosis in patients with gastric adenocarcinoma, focusing on the possible association between CTp and tumor angiogenesis. They found that BV could reflect the angiogenesis due to its significant correlation with microvessel density. The remaining study aimed at assessing both response to treatment and prognosis in patients with gastric cancer by means of CTp parameters.[77] They found that CTp was able to predict response to concurrent chemoradiotherapy and survival by means of BF, BV, and PF.

Computed Tomography in Pancreatic Cancer

Among studies on CTp role in pancreatic cancer, six had diagnostic purpose and the remaining two aimed at assessing prognosis[51] and response to treatment[82] of pancreatic cancer patients. Among diagnostic studies, two were performed by Delrue et al[33,34] who investigated the utility of 3 CTp parameters (BV, BF, and PS) for differential diagnosis of patients with pancreatic cancer. Specifically, they observed an overall decreasing of BF and BV perfusion values in tumoral tissues with respect to control populations. Similar results were found by Lu et al[35] who included also TTP and PEI among CTp parameters under investigation, finding promising results also for these features. The power of CTp for differential diagnosis of pancreatic cancer was also highlighted in a recent study performed by Zaboriene et al[22] who, in a study involving patients with pancreatic ductal adenocarcinoma (PDAC), found that BF and BV were independent predictors of PDAC. Aslan et al[73] showed that CTp was able to diagnose PDAC and isoattenuating pancreatic lesions thanks to the differences in BV, BF, PS, and MTT values. BV and BF were also found to be useful for the characterization of adenocarcinoma and mass-forming chronic pancreatitis in study by Yadav et al[21] Concerning works aiming at assessing response to treatment and prognosis, BF was the most significant parameter, with high BF values corresponding to a lower survival and response to treatment.[51,82]

Computed Tomography in Renal Cancer

Similar to what has been found for studies on pancreatic cancer, all 3 studies on CTp for renal cancer applications had diagnostic purposes. Chen et al[27] found that CTp parameters were useful for differential diagnosis of kidney tumors. Similar results were found by Deniffel et al.[74] The third included study involved patients with adrenal tumors and revealed that BV parameter was able to characterize adenomas from non-adenomas.[70]

Computed Tomography in Colon–rectal Cancer

Finally, concerning the five included works focused on CTp for the study of colon–rectal cancer, Khan et al[43] investigated the role of CTp parameters for quantifying different anatomical segments of colon–rectum. Significant differences were found in BF, BV, MTT, and PS. The same parameters

were investigated to evaluate their association with CRC grade in study by Kim et al.[44] They found that BF and MTT were able to predict moderately differentiated CRCs. These findings were also confirmed by Xu et al.[63] Of note, BF and MTT were also found to be useful for the assessment of response to chemoradiation therapy in locally advanced CRC patients.[39] Finally, Andersen et al. showed the ability of CTp for the assessment of response to regorafenib treatment in patients with treatment-refractory metastatic CRC.[81]

Quality Assessment

Based on the QUADAS-2 and QUIPS results, the overall quality of the included studies was considered good for our purposes. The results of the qualitative assessment are shown in Figures 3 and 4 and reported in the Supplementary Materials Tables S1 and S2. Regarding the QUADAS-2 assessment, the risk of bias was classified as low or unclear in all diagnostic studies, for all four QUADAS-2 domains. Concerns about applicability were classified as low across all diagnostic studies. Similarly, for the QUIPS assessment, the risk of bias was classified as low or moderate in all prognostic studies, for all 6 QUIPS domains.

Discussion

In this systematic review we aimed at investigating the role and clinical applications of CTp for clinical application in abdominal cancer, including diagnosis, grading, response to treatment, and prognosis. In recent years, the increasing availability and simplicity of CTp, together with its ability in quantification of the abnormal vasculature within tumors led to a growing interest in CTp imaging method for abdominal cancer applications. However, the still present drawbacks, mainly related with the lacking consensus on which CT protocol to use and the fact that published literature is based on small studies with different perfusion algorithms, have resulted in the missing integration of CTp into routine clinical practice protocols for abdominal imaging.[14,85] In this scenario, we performed a systematic review on the role of CTp in abdominal cancer with a view to provide important new insights and help to reach a common view on the use of CTp for

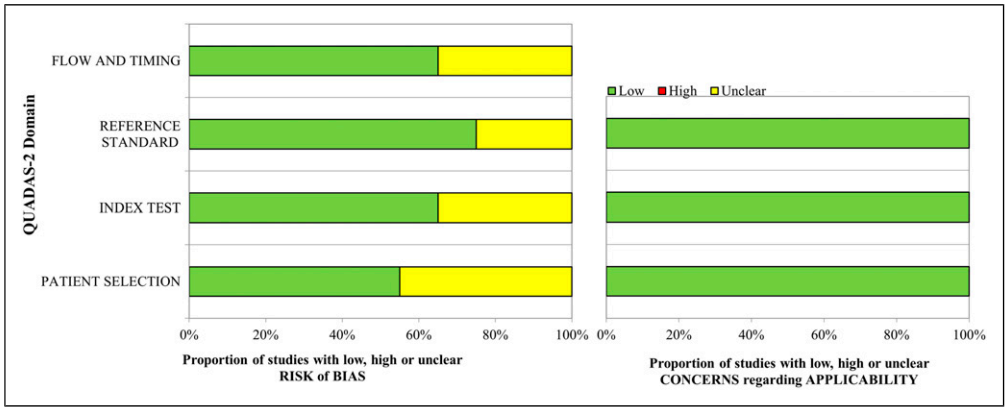

Figure 3. Quality assessment using QUADAS-2 tool for diagnostic studies.

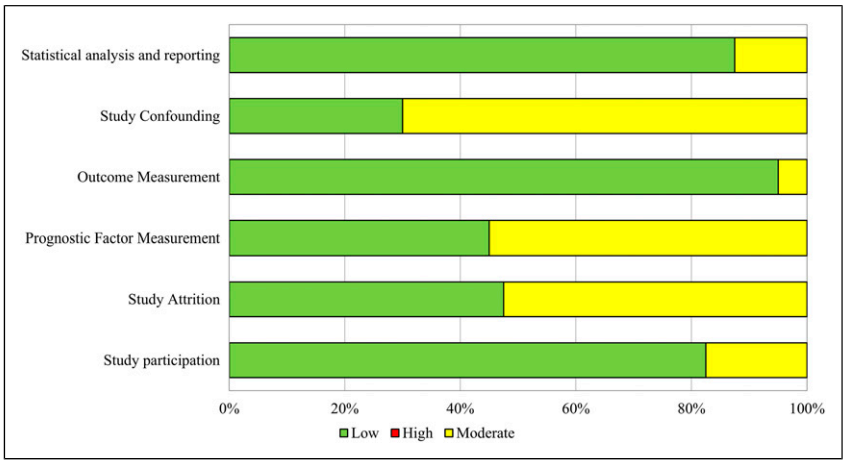

Figure 4. Quality assessment using QUIPS tool for prognostic studies.

several clinical purposes in the management of abdominal cancer. After appropriate inclusion and exclusion criteria, we examined 57 studies from 2011 onwards, evaluating the role of CTp in oncologic diseases of abdominal district. Studies were classified according to the abdominal organ investigated and the clinical purpose explored in the study. Most of the included articles (33/57) deal with CTp at the level of the liver, while a low number of studies investigated CTp for oncologic diseases involving UGI tract (8/57), pancreas (8/57), kidneys (3/57), and colon–rectum (5/57). Interestingly, about 60% of included studies and even about 80% of studies on liver cancer aimed at evaluating the response to treatment of the oncologic patients by means of CTp. This could be related with the urgent need of developing individualized approach, in which the treatment strategies are targeted according to the tumor biology. It is well known neoangiogenesis is one of the key elements of tumor physiology that influences the aggressiveness of cancer and its response to treatment and that the presence of high vascularity usually suggests aggressive behavior and is associated with a poor outcome. Perfusion CT displays and permits quantification of the abnormal vasculature within tumors, specifically hypervascularized tumors such as HCC.[2,4] This was also highlighted in the study by Goh et al[86] focused on the therapeutic assessment by means of CTp. Promising results were also found in the field of differential diagnosis of liver tumors, even if the number of studies investigating this issue were poor.[47,48,53] Even if only 35% of the included studies were performed on other tumors involving abdominal district, our systematic review revealed that CTp parameters could also help in diagnosis, prognosis, grading, and response to treatment in these areas. Notably, included studies involving patients with pancreatic and colon–rectal cancer had diagnostic purpose. Therefore, a larger number of studies are required to deepen grading, prognosis, and response to treatment in the field of these diseases.

Characteristics of the included studies, such as patient treatment, study aim and setting, CTp parameters investigated, segmentation, and analysis, were highly variable across studies, preventing us from performing a meta-analysis.

Moreover, about 30% of the included studies were retrospective, and they are supposed to have more bias and should be validated through prospective studies.[87,88] Other important limitations are that the number of patient samples included in the investigated studies was limited and that studies were predominantly single center, thus affecting the generalizability of the results.

To our knowledge, this is the first systematic review aiming at summarizing the role of CTp in abdominal cancer, exploring oncologic diseases of the whole abdominal area. Previous review studies aimed at review clinical applications and technical aspects of CTp.[2,89] Kambadakone et al[2] reviewed CTp technical aspects and its oncologic and non-oncologic applications. However, this study was not recent and was not focused on abdominal cancer. Bellomi et al[89] discussed on CTp in solid body-tumors. However, this study was not systematic and was not specific for abdominal cancer. Notably, Ogul et al[4] reviewed the basic principles of CTp discussing both oncologic and non-oncologic applications in abdominal district. Moreover, Hansen et al[10] presented an overview of CTp applications in abdominal cancer. However, any of these studies performed a systematic analysis of CTp applications in abdominal district.

Conclusions

In conclusion, our study revealed that CTp could be a valuable functional imaging tool in the field of abdominal oncology. CTp has the potential to play a crucial role in the management of patients with abdominal cancer, particularly as a biomarker for monitoring the response to anti-tumoral treatment. However, data relating CTp features to clinical outcomes remain limited, mainly due to the limited samples and monocentric setting of the studies, as well as the missing consensus about scan protocols for standardized examination. More collaborative research and robust validation are thus required before this innovative technique can be included in routine clinical practice.

Author's Note

The opinions expressed in the presented article are our own and not an official position of the institution or funder.

Declaration of Conflicting Interests

The author(s) declared no potential conflicts of interest with respect to the research, authorship, and/or publication of this article.

Funding

The author(s) received no financial support for the research, authorship, and/or publication of this article.

ORCID iDs

Nunzia Garbino https://orcid.org/0000-0001-6863-7313
Valentina Brancato https://orcid.org/0000-0002-6232-7645

Supplementary Material

Supplementary material for this article is available online.

References

1. Konstas AA, Goldmakher GV, Lee TY, et al. Theoretic basis and technical implementations of CT perfusion in acute ischemic stroke, part 1: theoretic basis. *AJNR Am J Neuroradiol*. 2009;30:662-668.
2. Kambadakone AR, Sahani DV. Body perfusion CT: technique, clinical applications, and advances. *Radiol Clin North Am*. 2009;47:161-178.
3. Petralia G, Bonello L, Viotti S, et al. CT perfusion in oncology: how to do it. *Cancer Imag*. 2010;10:8-19. doi:10.1102/1470-7330.2010.0001

4. Ogul H, Bayraktutan U, Kizrak Y, et al. Abdominal perfusion computed tomography. *Eurasian J Med*. 2013;45:50-57.
5. Miles KA, Lee TY, Goh V, et al. Current status and guidelines for the assessment of tumour vascular support with dynamic contrast-enhanced computed tomography. *Eur Radiol*. 2012;22:1430-1441.
6. Miles KA, Griffiths MR. Perfusion CT: a worthwhile enhancement? *Br J Radiol*. 2003;76:220-231.
7. Krishnan P, Murphy A, Aviv RI. CT-based techniques for brain perfusion. *Top Magn Reson Imag*. 2017;26:113-119.
8. Vilela P, Rowley HA. Brain ischemia: CT and MRI techniques in acute ischemic stroke. *Eur J Radiol*. 2017;96:162-172.
9. Donahue J, Wintermark M. Perfusion CT and acute stroke imaging: foundations, applications, and literature review. *J Neuroradiol*. 2015;42:21-29.
10. Hansen M, Norling R, Lauridsen C, et al. Computed tomography (CT) perfusion in abdominal cancer: technical aspects. *Diagnostics*. 2013;3:261-270.
11. Stiller W, Skornitzke S, Fritz F, et al. Correlation of quantitative dual-energy computed tomography iodine maps and abdominal computed tomography perfusion measurements: are single-acquisition dual-energy computed tomography iodine maps more than a reduced-dose surrogate of conventional computed tomography perfusion? *Invest Radiol*. 2015;50:703-708.
12. Kim SH, Kamaya A, Willmann JK. CT perfusion of the liver: principles and applications in oncology. *Radiology*. 2014;272: 322-344.
13. Miles KA, Hayball MP, Dixon AK. Functional images of hepatic perfusion obtained with dynamic CT. *Radiology*. 1993;188: 405-411.
14. García-Figueiras R, Goh VJ, Padhani AR, et al. CT perfusion in oncologic imaging: a useful tool? *Am J Roentgenol*. 2013;200: 8-19.
15. d'Assignies G, Couvelard A, Bahrami S, et al. Pancreatic endocrine tumors: tumor blood flow assessed with perfusion CT reflects angiogenesis and correlates with prognostic factors. *Radiology*. 2009;250:407-416.
16. Hatem Shalaby M, Ali Shehata KA. CT perfusion in hepatocellular carcinoma: Is it reliable? *Egypt J Radiol Nucl Med*. 2017;48:791-798.
17. Sheafor DH, Killius JS, Paulson EK, et al. Hepatic parenchymal enhancement during triple-phase helical CT: can it be used to predict which patients with breast cancer will develop hepatic metastases? *Radiology*. 2000;214:875-880.
18. Morsbach F, Pfammatter T, Reiner CS, et al. Computed tomographic perfusion imaging for the prediction of response and survival to transarterial radioembolization of liver metastases. *Invest Radiol*. 2013;48:787-794.
19. Zhu AX, Holalkere NS, Muzikansky A, et al. Early anti-angiogenic activity of Bevacizumab evaluated by computed tomography perfusion scan in patients with advanced Hepatocellular Carcinoma. *Oncol*. 2008;13:120-125.
20. Kandel S, Kloeters C, Meyer H, et al. Whole-organ perfusion of the pancreas using dynamic volume CT in patients with primary pancreas carcinoma: acquisition technique, post-processing and initial results. *Eur Radiol*. 2009;19:2641-2646.
21. Yadav AK, Sharma R, Kandasamy D, et al. Perfusion CT–can it resolve the pancreatic carcinoma versus mass forming chronic pancreatitis conundrum? *Pancreatology*. 2016;16:979-987.
22. Zaborienė I, Barauskas G, Gulbinas A, et al. Dynamic perfusion CT–A promising tool to diagnose pancreatic ductal adenocarcinoma. *Open Med*. 2021;16:284-292.
23. Dighe S, Castellano E, Blake H, et al. Perfusion CT to assess angiogenesis in colon cancer: technical limitations and practical challenges. *Br J Radiol*. 2012;85:e814-e825.
24. Sun H, Xu Y, Yang Q, et al. Assessment of tumor grade and angiogenesis in colorectal cancer: whole-volume perfusion CT. *Acad Radiol*. 2014;21:750-757.
25. Goh V, Halligan S, Daley F, et al. Colorectal tumor vascularity: quantitative assessment with multidetector CT–do tumor perfusion measurements reflect angiogenesis? *Radiology*. 2008; 249:510-517.
26. Goh V, Halligan S, Taylor SA, et al. Differentiation between diverticulitis and colorectal cancer: quantitative CT perfusion measurements versus morphologic criteria—initial experience. *Radiology*. 2007;242:456-462.
27. Chen C, Liu Q, Hao Q, et al. Study of 320-Slice dynamic volume CT perfusion in different pathologic types of kidney tumor: preliminary results. *PLoS One*. 2014;9:e85522.
28. Mazzei MA, Preda L, Cianfoni A, et al. CT perfusion: technical developments and current and future applications. *BioMed Res Int*. 2015;2015:1-2.
29. Moher D, Liberati A, Tetzlaff J, et al. Preferred reporting items for systematic reviews and meta-analyses: the PRISMA statement. *PLoS Med*. 2009;6:e1000097.
30. Whiting PF. QUADAS-2: a revised tool for the quality assessment of diagnostic accuracy studies. *Ann Intern Med*. 2011; 155:529.
31. Hayden JA, van der Windt DA, Cartwright JL, et al. Assessing bias in studies of prognostic factors. *Ann Intern Med*. 2013;158: 280-286.
32. Hayden JA, Côté P, Bombardier C. Evaluation of the quality of prognosis studies in systematic reviews. *Ann Intern Med*. 2006; 144:427.
33. Delrue L, Blanckaert P, Mertens D, et al. Tissue perfusion in pathologies of the pancreas: assessment using 128-slice computed tomography. *Abdom Imag*. 2012;37:595-601.
34. Delrue L, Blanckaert P, Mertens D, et al. Assessment of tumor vascularization in pancreatic Adenocarcinoma using 128-slice perfusion computed tomography imaging. *J Comput Assist Tomogr*. 2011;35:434-438.
35. Lu N, Feng XY, Hao SJ, et al. 64-Slice CT perfusion imaging of pancreatic Adenocarcinoma and mass-forming chronic pancreatitis. *Acad Radiol*. 2011;18:81-88.
36. Petralia G, Fazio N, Bonello L, et al. Perfusion computed tomography in patients with Hepatocellular Carcinoma treated with Thalidomide: initial experience. *J Comput Assist Tomogr*. 2011;35:195-201.
37. Schlemmer M, Sourbron SP, Schinwald N, et al. Perfusion patterns of metastatic gastrointestinal stromal tumor lesions under specific molecular therapy. *Eur J Radiol*. 2011;77:312-318.

38. Yao J, Yang Z, Chen H, et al. Gastric adenocarcinoma: can perfusion CT help to noninvasively evaluate tumor angiogenesis? *Abdom Imag*. 2011;36:15-21.
39. Curvo-Semedo L, Portilha MA, Ruivo C, et al. Usefulness of perfusion CT to assess response to neoadjuvant combined chemoradiotherapy in patients with locally advanced rectal cancer. *Acad Radiol*. 2012;19:203-213.
40. Ippolito D, Bonaffini PA, Capraro C, et al. Viable residual tumor tissue after radiofrequency ablation treatment in hepatocellular carcinoma: evaluation with CT perfusion. *Abdom Imag*. 2013; 38:502-510.
41. Jiang T, Kambadakone A, Kulkarni NM, et al. Monitoring response to Antiangiogenic treatment and predicting outcomes in advanced hepatocellular carcinoma using image biomarkers, CT perfusion, tumor density, and tumor size (RECIST). *Invest Radiol*. 2012;47:11-17.
42. Kanda T, Yoshikawa T, Ohno Y, et al. Perfusion measurement of the whole upper abdomen of patients with and without liver diseases: initial experience with 320-detector row CT. *Eur J Radiol*. 2012;81:2470-2475.
43. Khan S, Goh V, Tam E, et al. Perfusion CT assessment of the colon and rectum: feasibility of quantification of bowel wall perfusion and vascularization. *Eur J Radiol*. 2012;81:821-824.
44. Kim JW, Jeong YY, Chang NK, et al. Perfusion CT in colorectal cancer: comparison of perfusion parameters with tumor grade and microvessel density. *Korean J Radiol*. 2012;13:S89.
45. Yang L, Zhang X, Tan B, et al. Computed tomographic perfusion imaging for the therapeutic response of chemoembolization for hepatocellular Carcinoma. *J Comput Assist Tomogr*. 2012;36:226-230.
46. Chen YW, Pan HB, Tseng HH, et al. Assessment of blood flow in hepatocellular Carcinoma: correlations of computed tomography perfusion imaging and circulating angiogenic factors. *Int J Math Stat*. 2013;14:17536-17552.
47. Bai RJ, Li JP, Ren SH, et al. A correlation of computed tomography perfusion and histopathology in tumor edges of hepatocellular carcinoma. *Hepatobiliary Pancreat Dis Int*. 2014; 13:612-617.
48. Bayraktutan Ü, Kantarci A, Oğul H, et al. Evaluation of hepatocellular carcinoma with computed tomography perfusion imaging. *Turk J Med Sci*. 2014;44:193-196.
49. Hansen ML, Fallentin E, Lauridsen C, et al. Computed Tomography (CT) perfusion as an early predictive marker for treatment response to neoadjuvant chemotherapy in gastroesophageal junction cancer and gastric cancer–a prospective study. *PLoS One*. 2014;9:e97605.
50. Ippolito D, Fior D, Franzesi CT, et al. Tumour-related neoangiogenesis: functional dynamic perfusion computed tomography for diagnosis and treatment efficacy assessment in hepatocellular carcinoma. *Dig Liver Dis*. 2014;46:916-922.
51. Nishikawa Y, Tsuji Y, Isoda H, et al. Perfusion in the tissue surrounding pancreatic cancer and the patient's prognosis. *BioMed Res Int*. 2014;2014:1-6.
52. Reiner CS, Morsbach F, Sah BR, et al. Early treatment response evaluation after Yttrium-90 radioembolization of liver malignancy with CT perfusion. *J Vasc Intervent Radiol*. 2014; 25:747-759.
53. Singh J, Sharma S, Aggarwal N, et al. Role of perfusion CT differentiating hemangiomas from malignant hepatic lesions. *J Clin Imag Sci*. 2014;4:10.
54. Wang H, Shu S, Li J, et al. Management of liver cancer Argon-helium knife therapy with functional computer tomography perfusion imaging. *Technol Cancer Res Treat*. 2016;15:29-35.
55. Du F, Jiang R, Gu M, et al. The clinical application of 320-detector row CT in transcatheter arterial chemoembolization (TACE) for hepatocellular carcinoma. *Radiol Med*. 2015;120: 690-694.
56. Kaufmann S, Horger T, Oelker A, et al. Characterization of hepatocellular carcinoma (HCC) lesions using a novel CT-based volume perfusion (VPCT) technique. *Eur J Radiol*. 2015;84: 1029-1035.
57. Kaufmann S, Horger T, Oelker A, et al. Volume perfusion computed tomography (VPCT)—based evaluation of response to TACE using two different sized drug eluting beads in patients with nonresectable hepatocellular carcinoma: impact on tumor and liver parenchymal vascularisation. *Eur J Radiol*. 2015;84: 2548-2554.
58. Lv WF, Han JK, Cheng DL, et al. CT perfusion imaging can predict patients' survival and early response to transarterial Chemo-Lipiodol infusion for liver metastases from colorectal cancers. *Korean J Radiol*. 2015;16:810.
59. Reiner CS, Gordic S, Puippe G, et al. Histogram analysis of CT perfusion of hepatocellular carcinoma for predicting response to transarterial radioembolization: value of tumor heterogeneity assessment. *Cardiovasc Intervent Radiol*. 2016;39:400-408.
60. Sun ZQ, Cheng XF, Ge YX, et al. Role of CT perfusion imaging in patients with variously differentiated gastric adenocarcinoma. *J Xray Sci Technol*. 2015;23:737-744.
61. Sun ZQ, Li XH, Wang Z, et al. Clinical applications of computed tomography (CT) perfusion imaging in gastric cancer. *J Med Imag Health Inform*. 2015;5:1931-1935.
62. Wu D, Tan M, Zhou M, et al. Liver computed tomographic perfusion in the assessment of microvascular invasion in patients with small hepatocellular carcinoma. *Invest Radiol*. 2015;50: 188-194.
63. Xu Y, Sun H, Song A, et al. Predictive significance of tumor grade using 256-Slice CT whole-tumor perfusion imaging in colorectal adenocarcinoma. *Acad Radiol*. 2015;22:1529-1535.
64. Marquez HP, Puippe G, Mathew RP, et al. CT perfusion for early response evaluation of radiofrequency ablation of focal liver lesions: first experience. *Cardiovasc Intervent Radiol*. 2017;40: 90-98.
65. Su TH, He W, Jin L, et al. Early response of hepatocellular carcinoma to chemoembolization: volume computed tomography liver perfusion imaging as a short-term response predictor. *J Comput Assist Tomogr*. 2017;41:315-320.
66. Zongqiong S, Xiaohong L, Wei C, et al. CT perfusion imaging of the stomach: a quantitative analysis according to different degrees of adenocarcinoma cell differentiation. *Clin Imag*. 2016; 40:558-562.

67. D'Onofrio M, Cingarlini S, Ortolani S, et al. Perfusion CT changes in liver metastases from pancreatic neuroendocrine tumors during everolimus treatment. *Anticancer Res*. 2017;37: 1305-1311.
68. Kaufmann S, Thaiss WM, Schulze M, et al. Prognostic value of perfusion CT in hepatocellular carcinoma treatment with sorafenib: comparison with mRECIST in longitudinal follow-up. *Acta Radiol*. 2018;59:765-772.
69. Marquez HP, Karalli A, Haubenreisser H, et al. Computed tomography perfusion imaging for monitoring transarterial chemoembolization of hepatocellular carcinoma. *Eur J Radiol*. 2017;91:160-167.
70. Mohammed AR, Ahmed AT, Khalil TH, et al. Dynamic perfusion CT parameters and delayed contrast washout CT in characterization of adrenal tumors: a comparative study. *Egypt J Radiol Nucl Med*. 2017;48:707-716.
71. Popovic P, Leban A, Kregar K, et al. Computed tomographic perfusion imaging for the prediction of response and survival to transarterial chemoembolization of hepatocellular carcinoma. *Radiol Oncol*. 2017;52:14-22.
72. Tamandl D, Waneck F, Sieghart W, et al. Early response evaluation using CT-perfusion one day after transarterial chemoembolization for HCC predicts treatment response and long-term disease control. *Eur J Radiol*. 2017;90:73-80.
73. Aslan S, Nural MS, Camlidag I, et al. Efficacy of perfusion CT in differentiating of pancreatic ductal adenocarcinoma from mass-forming chronic pancreatitis and characterization of iso-attenuating pancreatic lesions. *Abdom Radiol*. 2019;44:593-603.
74. Deniffel D, Boutelier T, Labani A, et al. Computed tomography perfusion measurements in renal lesions obtained by Bayesian estimation, advanced singular-value decomposition deconvolution, maximum slope, and patlak models: intermodel agreement and diagnostic accuracy of tumor classification. *Invest Radiol*. 2018;53:477-485.
75. Detsky JS, Milot L, Ko YJ, et al. Perfusion imaging of colorectal liver metastases treated with bevacizumab and stereotactic body radiotherapy. *Phys Imag Rad Oncol*. 2018;5:9-12.
76. Ippolito D, Querques G, Pecorelli A, et al. Diagnostic value of quantitative perfusion computed tomography technique in the assessment of tumor response to Sorafenib in patients with advanced hepatocellular Carcinoma. *J Comput Assist Tomogr*. 2019;43:206-213.
77. Liang JX, Bi XJ, Li XM, et al. Evaluation of multislice spiral computed tomography perfusion imaging for the efficacy of preoperative concurrent chemoradiotherapy in middle-aged and elderly patients with locally advanced gastric cancer. *Med Sci Mon Int Med J Exp Clin Res*. 2018;24:235-245.
78. Nakamura Y, Kawaoka T, Higaki T, et al. Hepatocellular carcinoma treated with sorafenib: arterial tumor perfusion in dynamic contrast-enhanced CT as early imaging biomarkers for survival. *Eur J Radiol*. 2018;98:41-49.
79. Ng CS, Wei W, Duran C, et al. CT perfusion in normal liver and liver metastases from neuroendocrine tumors treated with targeted antivascular agents. *Abdom Radiol*. 2018;43:1661-1669.
80. Shen X, Wu D, Tang M, et al. Liver computed tomographic perfusion for monitoring the early therapeutic response to sorafenib in advanced hepatocellular carcinoma patients. *J Cancer Res Therapeut*. 2018;14:1556.
81. Andersen IR, Olesen R, Boysen AK, et al. Dynamic contrast-enhanced computed tomography as a potential biomarker in patients with metastatic colorectal cancer treated with regorafenib. *Acta Radiol*. 2019;60:836-845.
82. Hamdy A, Ichikawa Y, Toyomasu Y, et al. Perfusion CT to assess response to neoadjuvant chemotherapy and radiation therapy in pancreatic ductal adenocarcinoma: initial experience. *Radiology*. 2019;292:628-635.
83. Lee DH, Kim SH, Lee SM, et al. Prediction of treatment outcome of chemotherapy using perfusion computed tomography in patients with unresectable advanced gastric cancer. *Korean J Radiol*. 2019;20:589.
84. Tian N, Wu D, Tang M, et al. RAF1 expression is correlated with HAF, a parameter of liver computed tomographic perfusion, and may predict the early therapeutic response to sorafenib in advanced hepatocellular carcinoma patients. *Open Med*. 2020;15: 167-174.
85. Sheiman RG, Sitek A. CT perfusion imaging: know its assumptions and limitations. *Radiology*. 2008;246:649-650.
86. Goh V, Ng QS, Miles K. Computed tomography perfusion imaging for therapeutic assessment: has it come of age as a biomarker in oncology? *Invest Radiol*. 2012;47:2-4.
87. Norvell D. Study types and bias—Don't judge a study by the abstract's conclusion alone. *Evid Base Spine Care J*. 2010;1:7-10.
88. Euser AM, Zoccali C, Jager KJ, et al. Cohort studies: prospective versus retrospective. *Nephron Clin Pract*. 2009;113: c214-217.
89. Bellomi M, Viotti S, Preda L, et al. Perfusion CT in solid body-tumours part II. Clinical applications and future development. *Radiol Med*. 2010;115:858-874.