



Research Paper

Subcutaneous tocilizumab treatment in patients with severe COVID-19 –related cytokine release syndrome: An observational cohort study

Antonio Mastroianni^{a,*}, Sonia Greco^a, Giovanni Apuzzo^a, Salvatore De Santis^a, Carmela Oriolo^b, Alfredo Zanolini^c, Luciana Chidichimo^a, Valeria Vangeli^a

^a Infectious Diseases Unit, Annunziata Hospital, Viale della Repubblica s.n.c., 87100 Cosenza, Italy

^b Hospital Pharmacy, Annunziata Hospital, Cosenza, Italy

^c Radiology Unit, Annunziata Hospital, Cosenza, Italy

ARTICLE INFO

Article History:

Received 9 April 2020

Revised 21 May 2020

Accepted 21 May 2020

Available online 1 July 2020

Keywords:

Cytokine release syndrome

Coronavirus disease 2019

Tocilizumab

ABSTRACT

Background: Patients with severe coronavirus disease 2019 (COVID-19) have elevated levels of acute phase reactants and inflammatory cytokines, including interleukin-6, indicative of cytokine release syndrome (CRS). The interleukin-6 receptor inhibitor tocilizumab is used for the treatment of chimeric antigen receptor T-cell therapy–induced CRS.

Methods: Patients aged 18 years or older with laboratory-confirmed COVID-19 admitted to the Annunziata Hospital in Cosenza, Italy, through March 7, 2020, who received at least one dose of tocilizumab 162 mg subcutaneously for the treatment of COVID-19–related CRS in addition to standard care were included in this retrospective observational study. The primary observation was the incidence of grade 4 CRS after tocilizumab treatment. Chest computed tomography (CT) scans were evaluated to investigate lung manifestations.

Findings: Twelve patients were included; all had fever, cough, and fatigue at presentation, and all had at least one comorbidity (hypertension, six patients; diabetes, five patients; chronic obstructive lung disease, four patients). Seven patients received high-flow nasal cannula oxygen therapy and five received non-invasive mechanical ventilation for lung complications of COVID-19. No incidence of grade 4 CRS was observed within 1 week of tocilizumab administration in all 12 patients (100%) and within 2 days of tocilizumab administration in 5 patients (42%). The predominant pattern on chest CT scans at presentation was ground-glass opacity, air bronchograms, smooth or irregular interlobular or septal thickening, and thickening of the adjacent pleura. Follow-up CT scans 7 to 10 days after tocilizumab treatment showed improvement of lung manifestations in all patients. No adverse events or new safety concerns attributable to tocilizumab were reported.

Interpretation: Tocilizumab administered subcutaneously to patients with COVID-19 and CRS is a promising treatment for reduction in disease activity and improvement in lung function. The effect of tocilizumab should be confirmed in a randomised controlled trial.

© 2020 The Author(s). Published by Elsevier Ltd. This is an open access article under the CC BY-NC-ND license. (<http://creativecommons.org/licenses/by-nc-nd/4.0/>)

1. Introduction

Severe acute respiratory syndrome coronavirus 2 (SARS-CoV-2) and the associated disease, coronavirus disease 2019 (COVID-19), first identified in Wuhan, China, in December 2019 [1–4], is characterised as a pandemic by the World Health Organization, and global morbidity and mortality are increasing [5]. Severe complications of COVID-19 include acute respiratory distress syndrome and pneumonia, resulting in hospitalisation, severe burden on intensive care units, and high mortality rates [2]. There is no effective treatment for COVID-19 [2]. A trial of antiretroviral therapy with lopinavir-ritonavir

in patients hospitalised with COVID-19 did not demonstrate a benefit beyond standard care [6].

Patients with severe symptoms of COVID-19 have elevated markers of an exacerbated inflammatory response, in contrast to those who have mild symptoms, and elevated levels of the acute phase reactant C-reactive protein and the inflammatory cytokine interleukin-6, indicative of cytokine release syndrome (CRS) [7,8]. Furthermore, it has been reported that homeostasis of the immune system is integral in the development of pneumonia in patients with severe COVID-19 [9]. CRS is a severe or life-threatening systemic inflammatory reaction that occurs in some diseases and in response to certain therapies [10,11]. Low-grade or mild cases of CRS can present as fever and flu-like symptoms and are treated symptomatically; however, severe CRS (grade 3 or 4) requires hospitalisation and immediate treatment [10], and progression to grade 4 CRS is life-

* Corresponding author.

E-mail address: antoniomastroianni@yahoo.it (A. Mastroianni).

Research in context

Evidence before this study

Severe acute respiratory syndrome coronavirus 2 infection resulting in coronavirus disease 2019 (COVID-19) was first reported in Wuhan, China, in December 2019 and has become a pandemic with increasing global morbidity and mortality resulting from complications such as acute respiratory distress syndrome and pneumonia. Patients with severe COVID-19 have elevated levels of inflammatory cytokines, including interleukin-6, and acute phase reactants indicative of an exacerbated inflammatory response typical of cytokine release syndrome (CRS). We searched PubMed from database inception to March 28, 2020, using the terms 'tocilizumab AND (coronavirus OR 'severe acute respiratory syndrome coronavirus')' and did not identify any studies.

Added value of this study

This retrospective observational study from a hospital in Cosenza, Italy, is the first report on subcutaneous tocilizumab for the treatment of CRS in patients with COVID-19. We observed that there was no incidence of grade 4 CRS 7 days after these patients with severe COVID-19 received subcutaneous tocilizumab treatment. All patients demonstrated improvement of lung manifestations on follow-up chest computed tomography within 7 to 10 days after tocilizumab treatment.

Implications of all the available evidence

Subcutaneous tocilizumab therapy is a promising option for the treatment of CRS in patients with COVID-19. These results support investigation of tocilizumab in the treatment of COVID-19 in randomised controlled trials.

threatening with patients requiring ventilation support and/or experiencing organ toxicity [12]. CRS is characterised by a rapid and substantial increase in cytokines, including interleukin-6, a potent inflammatory mediator [13]. CRS is a potentially fatal adverse effect of cancer immunotherapy, particularly chimeric antigen receptor (CAR) T-cell therapy [14], and it is also associated with severe viral infections [10,15]. Respiratory symptoms and acute lung injury are common in patients with CRS and can progress to acute respiratory distress syndrome, as has been shown in SARS-CoV and influenza virus infection [10,11].

Tocilizumab is an anti-interleukin-6 receptor monoclonal antibody that blocks interleukin-6-mediated signalling and reduces markers of inflammation [16]. Tocilizumab is indicated for the treatment of chronic inflammatory disorders, including rheumatoid arthritis as intravenous dosing based on body weight or as 162 mg subcutaneous dosing, and is approved by the United States Food and Drug Administration (FDA) for the treatment of CAR T-cell-induced CRS for intravenous use [17,18]. Interleukin-6 has been identified as a key cytokine in the exacerbated immune response in patients with severe COVID-19, and interleukin-6 levels correlate with the severity of pneumonia (Zhou et al., 2020, unpublished data) [19]. A retrospective observational study of 21 patients conducted in China investigated the effectiveness of tocilizumab in patients with severe and critical COVID-19 [20]. In that study, all patients had improved within a few days of intravenous tocilizumab treatment, oxygen intake was lowered in 15 of 20 (75%) evaluable patients, and one patient did not require any oxygen therapy; in addition, computed tomography (CT) scans revealed that lung lesion opacity had been absorbed in 19 patients (90%). This suggests that tocilizumab treatment effectively attenuated clinical symptoms and suppressed deterioration in

patients with severe COVID-19, providing a potential new therapeutic strategy. Case studies and retrospective cohort analyses have reported on the use of intravenous tocilizumab in the treatment of patients with COVID-19-associated pneumonia, with results showing rapid improvement in inflammation, clinical symptoms, and lung function after the addition of tocilizumab to the treatment regimen [21–25]. A randomised controlled clinical trial of intravenous tocilizumab for the treatment of COVID-19 pneumonia is underway in China (ChiCTR2000029765) [26], and the FDA has approved a randomised controlled trial of intravenous tocilizumab in patients with severe COVID-19 pneumonia in the United States (ClinicalTrials.gov, NCT04320615) [27].

We conducted a retrospective observational study of patients admitted to hospital with COVID-19 and treated with subcutaneous tocilizumab to investigate the incidence CRS.

2. Patients and methods

2.1. Patients

Patients aged 18 years or older with laboratory-confirmed COVID-19 admitted to the infectious diseases unit of the Annunziata Hospital in Cosenza, Italy, through March 7, 2020, who received subcutaneous tocilizumab 162 mg at the discretion of the treating physician were included in this retrospective observational study. Demographic, clinical, treatment history, and laboratory data were extracted from electronic medical records and reviewed by Giuliana Guadagnino, MD, of the Annunziata Hospital. Severe COVID-19 disease was confirmed by the presence of at least one of the following: respiratory rate ≥ 30 /min; blood oxygen saturation $\leq 93\%$; ratio of partial pressure of oxygen in arterial blood to the inspired oxygen fraction ($\text{PaO}_2/\text{FiO}_2$) < 300 ; lung infiltrates present on $> 50\%$ of the lung field. CRS was determined according to the presence of clinical signs and symptoms (Table 1), and its severity was assessed based on a previously described revised grading system [12]. All patients provided written informed consent.

2.2. Assessments

The primary assessment was observation of the incidence of grade 4 CRS after tocilizumab treatment in patients with COVID-19 pneumonia, and the primary response was no incidence of grade 4 CRS. CRS was assessed according to a four-tier revised grading system with a proactive algorithm to guide the treatment of CRS based on severity that was designed to administer early immunosuppression therapy for cancer patients after adoptive T-cell therapies [12].

Table 1
Clinical signs and symptoms used in the grading of CRS.

Organ system	Symptoms
Constitutional	Fever (\pm rigors), malaise, fatigue, anorexia, myalgias, arthralgias, nausea, vomiting, headache
Skin	Rash
Gastrointestinal	Nausea, vomiting, diarrhea
Respiratory	Tachypnea, hypoxemia
Cardiovascular	Tachycardia, widened pulse pressure, hypotension, increased cardiac output (early), potentially diminished cardiac output (late)
Coagulation	Elevated D-dimer, hypofibrinogenemia (\pm bleeding)
Renal	Azotemia
Hepatic	Transaminitis, hyperbilirubinemia
Neurologic	Headache, mental status changes, confusion, delirium, word finding difficulty or frank aphasia, hallucinations, tremor, dysmetria, altered gait, seizures

Republished with permission of American Society of Hematology from Lee DW et al. Current concepts in the diagnosis and management of cytokine release syndrome. *Blood* 2014; **124**: 188–95. Permission conveyed through Copyright Clearance Center, Inc. CRS, cytokine release syndrome.

Routine blood samples were obtained to examine blood count, coagulation profile, serum biochemical tests (including kidney and liver function tests, creatine kinase, lactate dehydrogenase, and electrolytes), myocardial enzymes, and levels of interleukin-6, ferritin, and procalcitonin. Chest CT was performed for all patients as frequently as warranted according to the treating physician. Follow-up CT images were obtained for all patients within 7–10 days of tocilizumab treatment. Chest radiographs were evaluated by one of the authors (AZ) for the presence of ground-glass opacities, consolidation, nodules, pleural effusion, thoracic lymphadenopathy (defined as lymph nodes of abnormal size or morphology), or underlying lung disease such as emphysema or fibrosis; number of lobes affected by ground-glass or consolidative opacities; degree of lobe involvement and overall lung ‘total severity score’; or evidence of any other thoracic abnormalities. Lung severity score was assessed using the Brescia-COVID respiratory severity scale (BCRSS) and algorithm [28]. The BCRSS is a stepwise approach to managing COVID-19 in patients based on clinical severity. It was developed in Brescia, Italy, in response to the COVID-19 crisis and has not yet been validated or tested in other populations. Lung involvement was assessed using a chest CT severity score (CT-SS) [29] based on the initial scans obtained at presentation. The CT-SS uses lung opacification as a surrogate for extension of the disease in the lungs. Electrocardiography was performed daily in patients whose initial QT intervals were 450 to 500 milliseconds at presentation.

2.3. Role of funding

The authors did not receive any funding for this study. Support for third-party medical writing assistance was provided by F. Hoffmann-La Roche Ltd.

3. Results

3.1. Patient characteristics and clinical presentation

Twelve patients—eight men and four women—were included in this retrospective observational study; the total follow-up time was 4 weeks (Table 2) and the median length of stay in hospital was 24 days. The median (range) age of patients was 58 (48 to 72) years. All patients had at least one comorbidity, predominantly hypertension (six patients), diabetes (five patients), and chronic obstructive lung disease (four patients). The most common symptoms of COVID-19 on hospital admission were fever, cough, and fatigue, which were present in all patients. All patients had impaired oxygen status and CRS grade 1 to 3 at presentation. Markers of inflammation were elevated above normal levels, including CRP (median, 150 mg/L), fibrinogen (median, 850 mg/dl), D-dimers (median, 18.4 mg/L), and interleukin-6 (150 pg/ml) (Table 2).

3.2. Treatment

All patients were treated with antibiotics (azithromycin 500 mg/day), antivirals (lopinavir/ritonavir, eight patients; darunavir/cobicistat, four patients), and hydroxychloroquine (400 mg at suspicion/diagnosis followed by 400 mg after 12 h and 200 mg twice daily thereafter until day 5). Seven patients received high-flow nasal cannula oxygen therapy and five patients received non-invasive mechanical ventilation.

All patients received subcutaneous tocilizumab treatment for CRS; two patients received a single daily dose (two 162-mg doses resulting in a total dose of 324 mg), and ten patients received multiple doses (two 162-mg doses at baseline [324 mg] followed by two 162-mg doses after 24–72 h [324 mg]).

Table 2
Patient demographics and clinical characteristics upon presentation.

Characteristics	All patients N = 12
Male, n (%)	8 (66.7)
Female, n (%)	4 (33.3)
Age, years, median (range)	58 (48–72)
Comorbidity, n (%)	12 (100)
Hypertension	6 (50)
Diabetes	5 (41.7)
Chronic obstructive lung disease	4 (33)
Symptoms, n (%)	
Fever	12 (100)
Cough	12 (100)
Fatigue	12 (100)
Lymphocytopenia, ^a n (%)	12 (100)
Vitamin D deficiency, n (%)	12 (100)
Oxygen status, n (%)	
Respiratory rate ≥30 breaths/min	12 (100)
Blood oxygen saturation ≤93%	12 (100)
PaO ₂ /FiO ₂ <300 mm Hg	12 (100)
CRS, n (%)	
Grade 1	2 (16.7)
Grade 2	5 (41.7)
Grade 3	5 (41.7)
Grade 4	0
Inflammatory markers, median	
CRP, mg/L	150
Normal: <10	
Fibrinogen, mg/dl	850
Normal: 150–450	
LDH, U/L	950
Normal: 50–248	
D-dimer, mg/L	18.4
Normal: 0.0–0.5	
Ferritin, ng/ml	1750
Normal: 11–307	
Procalcitonin, ng/ml	0.17
Normal: ≤0.15	
Interleukin-6, pg/ml	150
Normal: 0.5–5	
Haptoglobin, mg/dl	570
Normal: 30–200	

CRP, C-reactive protein; CRS, cytokine release syndrome; PaO₂/FiO₂, ratio of partial pressure of oxygen in arterial blood to the inspired oxygen fraction; LDH, lactate dehydrogenase; mm Hg, millimetres of mercury.

^a Common Terminology Criteria for Adverse Events grade 3 or grade 4 lymphocyte count decrease (<0.05 to <0.2 × 10⁹/L).

3.3. Cytokine release syndrome

At presentation, two patients had grade 1 CRS, five patients had grade 2 CRS, five patients had grade 3 CRS, and no patients had grade 4 CRS. Eight patients had CRS for 0–4 days and four had CRS for longer than 4 days. Among seven patients who received high-flow nasal cannula oxygen therapy, three had grade 1 CRS and four had grade 2 CRS. All five patients who received non-invasive mechanical ventilation had grade 3 CRS. All patients received subcutaneous tocilizumab for the treatment of CRS.

There was no incidence of grade 4 CRS by day 7 in any of the 12 patients (100%) after they received tocilizumab treatment. Additional analysis showed that five patients (42%) had no incidence of grade 4 CRS by day 2 after they received tocilizumab treatment. Median serum levels of inflammatory markers, including C-reactive protein and interleukin-6, were elevated at presentation, before tocilizumab treatment (150 mg/L and 150 pg/ml, respectively; Table 2), and were markedly improved after tocilizumab treatment (25 mg/L and 8.1 pg/ml, representing a decrease of 125 mg/L and 142 pg/ml, respectively; Table 3).

Table 3
Serum markers of inflammation after tocilizumab treatment.

Inflammatory marker	After tocilizumab ^a N = 12	Decrease from presentation N = 12
CRP, mg/L Normal: <10	25	125
Fibrinogen, mg/dl Normal: 150–450	299	551
LDH, U/L Normal: 50–248	299	651
D-dimer, mg/L Normal: 0.0–0.5	0.46	17.94
Ferritin, ng/ml Normal: 11–307	550	1200
Procalcitonin, ng/ml Normal: ≤0.15	0.05	0.12
Interleukin-6, pg/ml Normal: 0.5–5	8.1	141.9
Haptoglobin, mg/dl Normal: 30–200	180	390

All data are shown as median values.

CRP, C-reactive protein; LDH, lactate dehydrogenase.

^a Laboratory parameters could have been measured at different times after tocilizumab treatment.

3.4. Oxygen status

At presentation in all patients, the respiratory rate was ≥ 30 breaths per minute, resting state oxygen saturation was $\leq 93\%$, and $\text{PaO}_2/\text{FiO}_2$ was ≤ 300 . Within 2–7 days of receiving tocilizumab treatment, the oxygen status of each patient normalised; respiratory rate was < 30 breaths per minute, oxygen saturation was $> 93\%$, and $\text{PaO}_2/\text{FiO}_2$ was > 300 .

3.5. Chest CT imaging

CT imaging at presentation revealed bilateral lung involvement with diffusely distributed peripheral and subpleural lesions. The predominant pattern was ground-glass opacity with ill-defined margins, air bronchograms, smooth or irregular interlobular or septal thickening, and thickening of the adjacent pleura. Follow-up CT images obtained 7–10 days after treatment with subcutaneous tocilizumab 162 mg showed radiographic improvement in all patients. Representative radiographs from three patients are shown in Fig. 1.

3.6. Safety

There were no reports of adverse events attributable to subcutaneous tocilizumab treatment in this study. No changes in liver function test results were reported (no patients had elevated levels of alanine aminotransferase [ALT] or aspartate aminotransferase [AST]), and none of the patients experienced neutropenia. No patients experienced adverse events related to elevated serum levels of triglycerides or low-density lipoprotein. There was no evidence of latent tuberculosis infection. One patient who tested negative for hepatitis B surface antigen but positive for hepatitis B core antibody and for hepatitis B surface antigen antibody received preventive antiviral therapy with lamivudine. No patient died. There was no documented interaction of tocilizumab with antivirals, hydroxychloroquine, or corticosteroids.

4. Discussion

Patients with severe COVID-19 are at risk for CRS [8]. Based on the use of tocilizumab for the treatment of CAR T-cell–induced CRS, we hypothesised that patients with COVID-19 who experienced CRS would have improved clinical outcomes, such as reduced systemic inflammation, and improved measures of respiratory distress or

failure if treated with subcutaneous tocilizumab. In this retrospective observational study of 12 patients with severe COVID-19 pneumonia treated with subcutaneous tocilizumab in a hospital in Italy, we observed a stable reduction in disease activity after 1 week, as determined by CRS grade. Rapid and sustained reduction in inflammatory markers, C-reactive protein, fibrinogen, lactate dehydrogenase, D-dimer, serum ferritin, procalcitonin, and interleukin-6 levels was also observed, and all patients showed radiographic improvement on chest CT. Therefore, our study demonstrates the potential for pre-emptive tocilizumab treatment to decrease CRS and to improve pulmonary outcomes in patients with severe COVID-19.

None of the patients observed in our study experienced adverse events attributable to tocilizumab treatment; there were no reported events of elevated lipid levels, ALT, or AST, as has been documented in patients with rheumatoid arthritis treated with subcutaneous tocilizumab [30,31]. Decreased levels of circulating neutrophils have been reported following tocilizumab treatment [32,33], but we did not observe any evidence of neutropenia after tocilizumab treatment in our study.

Current management of COVID-19 is supportive, and respiratory failure from acute respiratory distress syndrome is the leading cause of death as identified in a retrospective multicentre study of 150 confirmed cases of COVID-19 in Wuhan, China [7]. Predictors of fatality in this study included elevated ferritin (mean, 1297.6 ng/ml in 68 non-survivors vs 614.0 ng/ml in 82 survivors; $p < 0.001$) and interleukin-6 (mean, 11.4 ng/ml in non-survivors and 6.8 ng/ml in survivors; $p < 0.001$) [7], suggesting that mortality might be influenced by the exacerbated inflammatory response to SARS-CoV-2 infection [8].

Our results showing improvement in CRS grade and CT imaging results in all patients with severe COVID-19 treated with subcutaneous tocilizumab support those from a study in China in which 19 of 21 patients with severe COVID-19 who received treatment with intravenous tocilizumab 400 mg had improved findings on chest CT radiography, recovered, and were discharged from the hospital [20]. The patients observed in our study received subcutaneous dosing of tocilizumab 162 mg either as single or multiple doses, rather than the approved intravenous dosing, because the intravenous formulation was not available. Comparability between the subcutaneous and intravenous formulations of tocilizumab has been confirmed in patients with rheumatoid arthritis in the real-world setting, and the subcutaneous formulation can provide a more convenient administration option [34]. Pharmacokinetic and pharmacodynamic analysis has demonstrated that the pharmacodynamic effect of tocilizumab occurs independently of route of administration [35,36], and clinical studies in patients with rheumatoid arthritis have shown comparability of efficacy and safety between the subcutaneous and intravenous formulations [31,37]. We did not observe any new safety concerns in this study of subcutaneous tocilizumab in patients with COVID-19 and CRS.

Our CT image evaluations before tocilizumab treatment were consistent with observations from a single-centre study in China of 63 patients with COVID-19 pneumonia that identified multilobe involvement and ground-glass opacity, distributed subpleurally in most patients, as the predominant presentation [38]. A larger observational study of 1099 patients from 552 hospitals in China also found that ground-glass opacity was the most common pattern in chest radiographs from patients with COVID-19 who underwent CT on hospital admittance [39].

Limitations of our study include lack of a control group in this retrospective cohort analysis and lack of information on certain disease characteristics, such as levels of proinflammatory cytokines other than interleukin-6 and viral shedding. Evaluation of CT scans was performed by one of the authors, and the results should be interpreted with the acknowledgement that no independent review was performed. All patients in our study had received treatment with antibiotics, antivirals, and hydroxychloroquine at the suspicion or

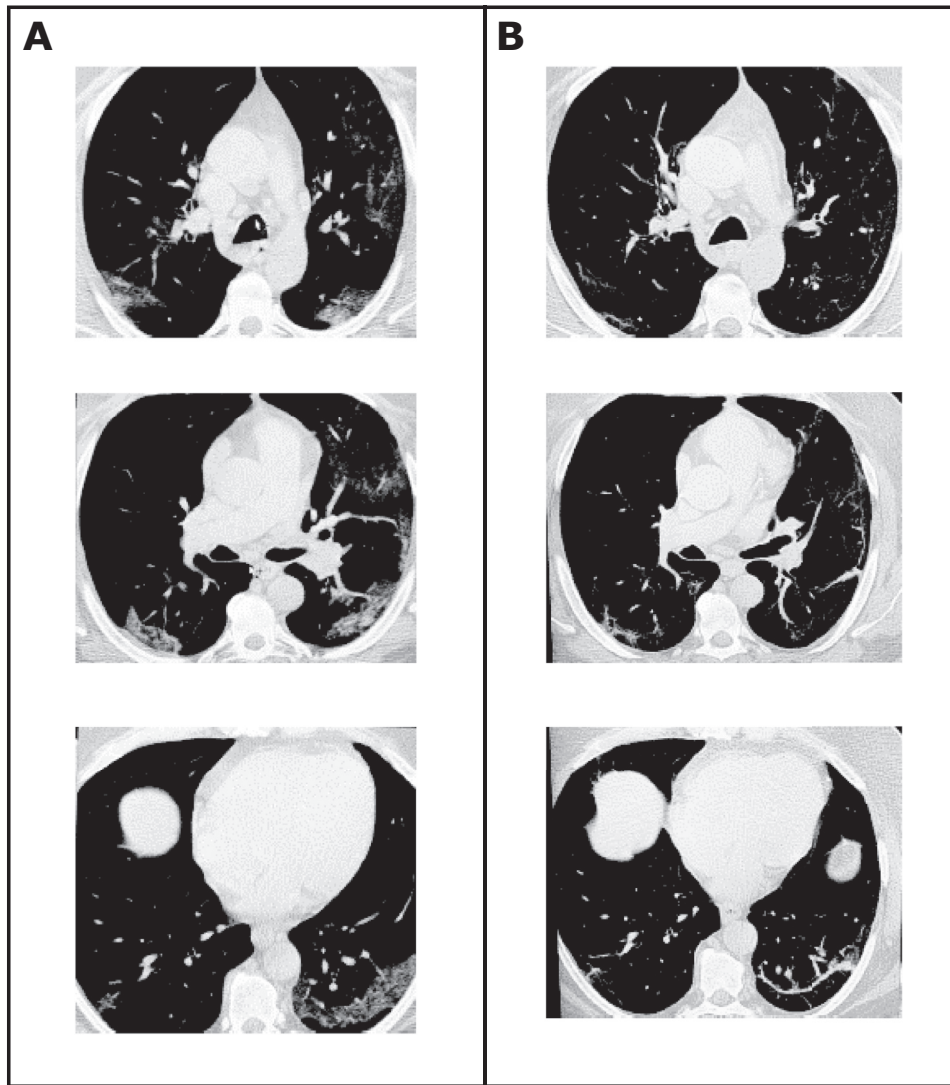


Fig. 1. Representative chest radiographs from high-resolution CT scans at presentation (A) and after tocilizumab treatment (B) in three patients. At hospital admission, all patients had suspected COVID-19 and underwent high-resolution multidetector or conventional CT of the chest. Initial CT performed at presentation (A) showed alveolar and interstitial ground-glass opacities and areas of consolidation compatible with interstitial pneumonia indicative of COVID-19 infection and no evidence of pleural effusion. CT performed after tocilizumab treatment showed reduction of ground-glass opacities in all patients and reduction in areas of consolidation in some patients. CT, computed tomography.

diagnosis of COVID-19 and before the administration of tocilizumab. Therefore, although rapid improvement was observed after the administration of tocilizumab, it is not possible to attribute the results to a direct effect of tocilizumab. Further studies are needed to determine whether the findings can be applied to the general population of patients with severe COVID-19. Other case/cohort studies that report rapid improvement after tocilizumab treatment used the intravenous formulation at various doses in the range of 4–8 mg/kg [20–25]; therefore, comparison of our findings with the findings of these studies is limited, and more data on the use of subcutaneous tocilizumab in patients with COVID-19 are needed. There is an unmet need for controlled clinical trial data to determine whether tocilizumab is effective for the treatment of COVID-19–induced pneumonia. A review of the literature did not identify any clinical trials of subcutaneous tocilizumab for the treatment of CRS in patients with COVID-19. However, clinical trials are underway in China (ChiCTR2000029765), Italy (ClinicalTrials.gov, NCT04317092 and NCT04315480), and the United States (ClinicalTrials.gov NCT04320615).

In conclusion, our findings suggest that with careful patient selection, the benefit/risk ratio for subcutaneous tocilizumab treatment in patients with severe COVID-19 is promising for rapid and sustained

reduction in disease activity, improved respiratory function, and reduced pulmonary structural damage. Given the results observed in our study, other early results reported in patients with severe COVID-19 treated with tocilizumab, and the current lack of effective treatments, the results of clinical trials are eagerly awaited to confirm the efficacy of tocilizumab for the treatment of patients with COVID-19 pneumonia.

Data sharing statement

A data sharing statement provided by the authors is available upon request.

Author contributions

All authors made substantial contributions to the conception or design of the work or the acquisition, analysis, or interpretation of data, were involved in drafting the manuscript or revising it critically for important intellectual content, approved the final version to be published, and agree to be accountable for all aspects of the work in ensuring that questions related to the accuracy or integrity of any part of the work are appropriately investigated and resolved.

Declaration of Competing Interest

The authors have no conflicts of interest to disclose.

Funding

The authors did not receive any funding for this study.

Acknowledgments

The authors thank Filippo Urso, MD, and Manola Peverini, MD, for their expertise and consultation, and they thank Francesca Greco, MD, and Maria Vittoria Mauro, MD, of the Annunziata Hospital Center for Microbiology & Virology for confirmation of COVID-19 in the patients included. The first draft of the manuscript was written by Antonio Mastroianni, MD, with writing assistance provided by Sara Duggan, PhD, of ApotheCom; this writing assistance was funded by F. Hoffmann-La Roche Ltd.

References

- Zhu N, Zhang D, Wang W, et al. A novel coronavirus from patients with pneumonia in China, 2019. *N Engl J Med* 2020;382:727–33.
- Yang X, Yu Y, Xu J, et al. Clinical course and outcomes of critically ill patients with SARS-CoV-2 pneumonia in Wuhan, China: a single-centered, retrospective, observational study. *Lancet Respir Med* 2020;8:475–81.
- Ren LL, Wang YM, Wu ZQ, et al. Identification of a novel coronavirus causing severe pneumonia in human: a descriptive study. *Chin Med J* 2020;133:1015–24.
- Zhou P, Yang XL, Wang XG, et al. A pneumonia outbreak associated with a new coronavirus of probable bat origin. *Nature* 2020;579:270–3.
- World Health Organization. Coronavirus disease (COVID-19) pandemic. <https://www.who.int/emergencies/diseases/novel-coronavirus-2019>. Accessed May 6, 2020.
- Cao B, Wang Y, Wen D, et al. A trial of lopinavir-ritonavir in adults hospitalized with severe Covid-19. *N Engl J Med* 2020;382:1787–99.
- Ruan Q, Yang K, Wang W, Jiang L, Song J. Clinical predictors of mortality due to COVID-19 based on an analysis of data of 150 patients from Wuhan, China. *Intensive Care Med* 2020;46:846–8.
- Mehta P, McAuley DF, Brown M, Sanchez E, Tattersall RS, Manson JJ. COVID-19: consider cytokine storm syndromes and immunosuppression [letter]. *Lancet* 2020;395:1033–4.
- Zheng HY, Zhang M, Yang CX, et al. Elevated exhaustion levels and reduced functional diversity of T cells in peripheral blood may predict severe progression in COVID-19 patients [letter]. *Cell Mol Immunol* 2020;17:541–3.
- Shimabukuro-Vornhagen A, Godel P, Subklewe M, et al. Cytokine release syndrome. *J Immunother Cancer* 2018;6:56.
- Tisoncik JR, Korth MJ, Simmons CP, Farrar J, Martin TR, Katze MG. Into the eye of the cytokine storm. *Microbiol Mol Biol Rev* 2012;76:16–32.
- Lee DW, Gardner R, Porter DL, et al. Current concepts in the diagnosis and management of cytokine release syndrome. *Blood* 2014;124:188–95.
- Teachey DT, Lacey SF, Shaw PA, et al. Identification of predictive biomarkers for cytokine release syndrome after chimeric antigen receptor T-cell therapy for acute lymphoblastic leukemia. *Cancer Discov* 2016;6:664–79.
- Hay KA. Cytokine release syndrome and neurotoxicity after CD19 chimeric antigen receptor-modified (CAR-) T cell therapy. *Br J Haematol* 2018;183:364–74.
- de Jong MD, Simmons CP, Thanh TT, et al. Fatal outcome of human influenza A (H5N1) is associated with high viral load and hypercytokinemia. *Nat Med* 2006;12:1203–7.
- Tanaka T, Narazaki M, Kishimoto T. IL-6 in inflammation, immunity, and disease. *Cold Spring Harb Perspect Biol* 2014;6:a016295.
- Le RQ, Li L, Yuan W, et al. FDA approval summary: tocilizumab for treatment of chimeric antigen receptor T cell-induced severe or life-threatening cytokine release syndrome. *Oncologist* 2018;23:943–7.
- Rubbert-Roth A, Furst DE, Nebesky JM, Jin A, Berber E. A review of recent advances using tocilizumab in the treatment of rheumatic diseases. *Rheumatol Ther* 2018;5:21–42.
- Zhou Y., Fu B., Zheng X., et al. Aberrant pathogenic GM-CSF+ T cells and inflammatory CD14+CD16+ monocytes in severe pulmonary syndrome patients of a new coronavirus [preprint]. <https://www.biorxiv.org/content/10.1101/2020.02.12.945576v1>. Accessed May 6, 2020
- Xu X, Han M, Li T, et al. Effective treatment of severe COVID-19 patients with tocilizumab. *Proc Natl Acad Sci* 2020;117:10970–5.
- De Luna G, Habibi A, Deux JF, et al. Rapid and severe Covid-19 pneumonia with severe acute chest syndrome in a sickle cell patient successfully treated with tocilizumab. *Am J Hematol* 2020;95:876–8.
- Cellina M, Orsi M, Bombaci F, Sala M, Marino P, Oliva G. Favorable changes of CT findings in a patient with COVID-19 pneumonia after treatment with tocilizumab [comment]. *Diagn Interv Imaging* 2020;101:323–4.
- Luo P, Liu Y, Qiu L, Liu X, Liu D, Li J. Tocilizumab treatment in COVID-19: a single center experience. *J Med Virol* 2020;92:814–8 [Epub ahead of print].
- Michot JM, Albiges L, Chaput N, et al. Tocilizumab, an anti-IL6 receptor antibody, to treat Covid-19-related respiratory failure: a case report. *Ann Oncol* 2020;31:961–4.
- Zhang X, Song K, Tong F, et al. First case of COVID-19 in a patient with multiple myeloma successfully treated with tocilizumab. *Blood Adv* 2020;4:1307–10.
- Chinese Clinical Trial Registry. A multicenter, randomized controlled trial for the efficacy and safety of tocilizumab in the treatment of new coronavirus pneumonia (COVID-19). <http://www.chictr.org.cn/showprojen.aspx?proj=49409>. Accessed May 6, 2020.
- Clinical Trials Arena. Roche to start phase III trial of Actemra in Covid-19 patients [press release]. March 19, 2020. <https://www.clinicaltrialsarena.com/news/roche-actemra-covid-19-trial/>. Accessed 6 May 2020.
- Duca A, Piva S, Foca E, et al. Calculated decisions: brescia-COVID respiratory severity scale (BCRSS)/algorithm. *Emerg Med Pract* 2020;22 CD1-2.
- Yang R, Li X, Liu H, et al. Chest CT severity score: an imaging tool for assessing severe COVID-19. *Radiol Cardiothoracic Imaging* 2020. doi: 10.1148/ryct.2020200047.
- Ohta S, Tsuru T, Terao K, et al. Mechanism-based approach using a biomarker response to evaluate tocilizumab subcutaneous injection in patients with rheumatoid arthritis with an inadequate response to synthetic DMARDs (MATSURI study). *J Clin Pharmacol* 2014;54:109–19.
- Burmester GR, Rubbert-Roth A, Cantagrel A, et al. Efficacy and safety of subcutaneous tocilizumab versus intravenous tocilizumab in combination with traditional DMARDs in patients with RA at week 97 (SUMMACTA). *Ann Rheum Dis* 2016;75:68–74.
- Moots RJ, Sebba A, Rigby W, et al. Effect of tocilizumab on neutrophils in adult patients with rheumatoid arthritis: pooled analysis of data from phase 3 and 4 clinical trials. *Rheumatology* 2016;56:541–9.
- Lok LSC, Farahi N, Juss JK, et al. Effects of tocilizumab on neutrophil function and kinetics. *Eur J Clin Invest* 2017;47:736–45.
- Lauper K, Nordstrom DC, Pavelka K, et al. Comparative effectiveness of tocilizumab versus TNF inhibitors as monotherapy or in combination with conventional synthetic disease-modifying antirheumatic drugs in patients with rheumatoid arthritis after the use of at least one biologic disease-modifying antirheumatic drug: analyses from the pan-European TOCERRA register collaboration. *Ann Rheum Dis* 2018;77:1276–82.
- Zhang X, Georgy A, Rowell L. Pharmacokinetics and pharmacodynamics of tocilizumab, a humanized anti-interleukin-6 receptor monoclonal antibody, following single-dose administration by subcutaneous and intravenous routes to healthy subjects. *Int J Clin Pharmacol Ther* 2013;51:443–55.
- Zhang X, Chen YC, Fettner S, et al. Pharmacokinetics and pharmacodynamics of tocilizumab after subcutaneous administration in patients with rheumatoid arthritis. *Int J Clin Pharmacol Ther* 2013;51:620–30.
- Burmester GR, Rubbert-Roth A, Cantagrel A, et al. A randomised, double-blind, parallel-group study of the safety and efficacy of subcutaneous tocilizumab versus intravenous tocilizumab in combination with traditional disease-modifying antirheumatic drugs in patients with moderate to severe rheumatoid arthritis (SUMMACTA study). *Ann Rheum Dis* 2014;73:69–74.
- Pan Y, Guan H, Zhou S, et al. Initial CT findings and temporal changes in patients with the novel coronavirus pneumonia (2019-nCoV): a study of 63 patients in Wuhan, China. *Eur Radiol* 2020;30:3306–9.
- Guan WJ, Ni ZY, Hu Y, et al. Clinical characteristics of coronavirus disease 2019 in China. *N Engl J Med* 2020;382:1708–20.