


# Comparison of two staining techniques on the manual and automated canine sperm morphology analysis

Paulina Surmacz<sup>1</sup> | Anna Niwinska<sup>1</sup>  | Ewa Kautz<sup>2</sup> | Slawomir Gizinski<sup>1</sup> | Ricardo Faundez<sup>3</sup>

<sup>1</sup>Department of Large Animal Diseases with Clinic, Faculty of Veterinary Medicine, Warsaw University of Life Sciences WULS – SGGW, Warsaw, Poland

<sup>2</sup>Institute of Genetics and Animal Biotechnology of the Polish Academy of Sciences, Warsaw, Poland

<sup>3</sup>InviMed Fertility Clinics, Warsaw, Poland

## Correspondence

A. Niwinska, Department of Large Animal Diseases with Clinic, Faculty of Veterinary Medicine; Warsaw University of Life Sciences WULS – SGGW, Warsaw, Poland.  
Email: [anna\\_niwinska@sggw.edu.pl](mailto:anna_niwinska@sggw.edu.pl)

## Abstract

Detailed and direct analysis of semen, including sperm morphology, enables a diagnosis of male fertility. This study aimed to describe an economical and verified protocol for canine spermograms and compare the effectiveness of Sperm Stain<sup>®</sup> and Sperm Blue<sup>®</sup> (Microptic, Spain) in veterinary practice. Sperm assessment was conducted manually, using a standard optical microscope, and via computerized semen analysis using the SCA<sup>®</sup> CASA (Sperm Class Analyzer<sup>®</sup> CASA System-MICROPTIC, Spain). This study showed that Sperm Blue<sup>®</sup> is a better solution for computerized sperm quality analysis of healthy dogs. At the same time, Sperm Stain<sup>®</sup> turned out to be more helpful in identifying specific morphological defects of sperm. Automated canine sperm morphology analysis worked better with Sperm Blue stain, but Sperm Stain simplified manual evaluation of various organelles' defects. Standard, manual examination is more error-prone for an inexperienced andrology technician, but it seems to be still a gold standard technique for canine sperm assessment.

## KEYWORDS

andrology, CASA, dog spermogram, Sperm Blue<sup>®</sup>, sperm morphology, Sperm Stain<sup>®</sup>

## 1 | INTRODUCTION

In recent years, breeders have been struggling with the reduced fertility of companion animals. Ejaculates from purebred dogs show a lower concentration of sperm, a smaller percentage of progressive motility and deterioration of other parameters, including sperm morphology. There are many apparent causes of abnormal spermogram results, such as underdevelopment of the testicles, the effect of age and prostate hypertrophy (Brito et al., 2020). Moreover, sperm quality is influenced by endocrine disorders, overheating of the testicles, injuries and underdevelopment of the testicles, intersexuality, testicular cancer, cysts and granulomas (Kolster, 2018). An increase in the number of cases of male fertility consultations raises the need

for a universal and verified test protocol for the dog's sperm quality evaluation.

A dog as a companion animal is exposed to many negative environmental factors such as a diet rich in endocrine disruptors or influence of diseases, for example, babesiosis (Domostawska & Zdunczyk, 2020) and chemical factors, or sexually transmitted and infectious diseases, for example, brucellosis and mycoplasma. (Tamiozzo, 2021). Breeding dogs' fertility problems are associated with a high cost of treatment, artificial insemination, and even the use of Assisted Reproductive Techniques (ART) (Kolster, 2018; Lopate, 2012).

Due to the growing interest in creating new races and modifying existing ones, semen analysis and infertility treatment have become

Anna Niwinska and Paulina Surmacz are first authors of the manuscript.

This is an open access article under the terms of the [Creative Commons Attribution-NonCommercial-NoDerivs](https://creativecommons.org/licenses/by-nc-nd/4.0/) License, which permits use and distribution in any medium, provided the original work is properly cited, the use is non-commercial and no modifications or adaptations are made.

© 2022 The Authors. *Reproduction in Domestic Animals* published by Wiley-VCH GmbH.

indispensable parts of veterinary medicine. Inbreeding or crossbreeding of closely related animals may cause abnormal fertility, that is, teratozoospermia or oligozoospermia, or other genetic defects of spermatozoa (Chenoweth, 2005; Marelli, Beccaglia, Bagnato, & Strillacci, 2020).

Canine semen is thick and dense in consistency, whitish in colour, and has a pH of 6.4–6.8. Canine ejaculation can be separated into three fractions. The first (0.2–3 ml) pre-sperm fraction cleans out the urethra and the second (0.5–4 ml) is ejaculated from the epididymis and contains the entire sperm pool in the semen plasma ( $200\text{--}500 \times 10^6/\text{ml}$ ). The third, prostate fraction (2–30 ml), is the largest in volume and contains only a few sperm (Peña Martínez, 2004).

The average sperm length of a dog's sperm is  $68 \mu\text{m}$ ; midpiece length is definite around  $11 \mu\text{m}$  (Bartlett, 1962), and tail around  $49 \mu\text{m}$ . The exact morphometric parameters of canine spermatozoa seem to vary between breeds, which makes it challenging to specify standard dimensions (Chłopik & Wysokińska, 2020; Dahlbom, Andersson, Vierula, & Alanko, 1997; Soler et al., 2017). Some studies draw attention to differences in the area of the sperm head ( $18.10\text{--}22.22 \mu\text{m}$ ), length ( $6.49\text{--}7.06 \mu\text{m}$ ), width ( $3.77\text{--}4.46 \mu\text{m}$ ) and the degree of roundness of the head ( $1.20\text{--}1.33 \mu\text{m}$ ) in different breeds of dogs (Soler et al., 2017).

Morphological defects of canine sperm are classified as primary: formed during spermatogenesis, and secondary: acquired during sperm maturation (Seager & Platz, 1977).

Due to the location of the defect, they can also be divided into acrosomal, head, midpiece and tail defects, of which examples are shown in Figure 1. It is well established that percentage of normal sperm has a predictive value for pregnancy and litter size (Hollinshead, Ontiveros, Burns, Magee, & Hanlon, 2020).

Unsuccessful fertilization is influenced by sperm defects, such as acrosomal defects, heads' defects and tails' defects (Chenoweth, 2005). It has been proved even a low content of cytoplasmic drops in the tails is associated with decreased fertility (Peña, Barrio, Becerra, Quintela, & Herradón, 2007).

In veterinary practice, the most commonly used tool for analysing sperm motility and morphology is manual evaluation (Kolster, 2018). This classic approach takes time and is limited by the practitioner's experience, which causes computer-assisted systems like SCA CASA by Microptic to become more and more popular (van der Horst, Maree, & du Plessis, 2018).

In both approaches, it is necessary to appropriately stain the morphological slides using universal dyes, like Diff-Quick or dyes dedicated to semen analysis, for example, Sperm Stain<sup>®</sup> or Sperm Blue<sup>®</sup>. Unifying the parameters and examination protocols and developing a standard for the species and, in the case of dogs, perhaps also for the breed, is essential for good laboratory practice for reproduction studies (Chłopik & Wysokińska, 2020; Dahlbom et al., 1997; Soler et al., 2017).

This study aimed to establish an economical, universal protocol for canine spermograms and compare the effectiveness and usefulness of two cytological stains commonly used in veterinary practice.

## 2 | MATERIALS AND METHODS

The study involved five fertile males of purebred English Cocker Spaniel ( $n = 3$ ) and German Shepherd ( $n = 2$ ) aged 1.5–7 years, all registered with the Fédération Cynologique Internationale (FCI). Each dog underwent a clinical health examination and a detailed examination of the male reproductive system. Samples were taken three times from each dog with a 3-week interval between collections. The owners agreed to the use of biological material for research purposes.

The samples were obtained via masturbation using an artificial vagina and a water-jacked flask, both preheated to  $37^\circ\text{C}$  and washed with sterile PBS. Sperm concentration and motility were tested using the CASA Sperm Class Analyzer 5.4.0.0. SCA Research Edition – Motility (Microptic, Spain). Samples were transferred to 1.5-ml sterile tubes and placed on a heated stand ( $37^\circ\text{C}$ ). For morphological analysis samples, smears of  $5 \mu\text{l}$  of ejaculate were made as shown in Figure 2 and allowed to dry on the heating pad. All samples were assayed in duplicate. For every sample analysis ( $n = 15$ ), at least 200 spermatozoa per staining method were evaluated. A total number of 6000 sperm were analysed in this study.

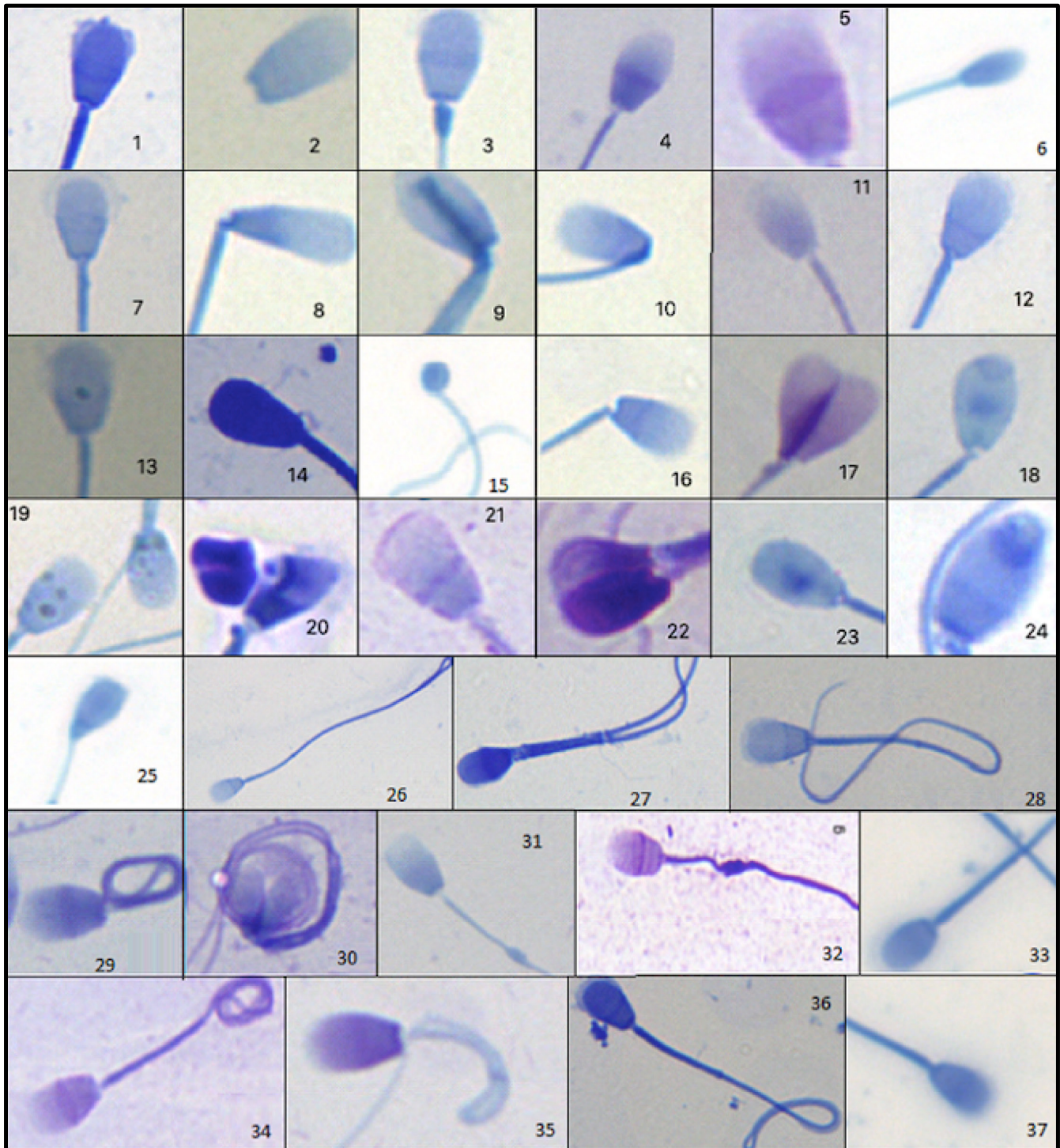
For sperm staining, slides were immersed consecutively in 3 reagents (fix and two staining reagents). The Sperm Stain<sup>®</sup> staining system is based on the Romanowski method. Slides were rinsed in deionized water (3 dips) and then left at a  $30^\circ$  angle to air dry. The sperm were stained dark purple, acrosome—light purple and sperm tail—dark purple.

For the Sperm Blue<sup>®</sup> staining, dried smears were placed in the staining tray containing the fixative for 10 min. Slides were pulled gently, pouring out an excess stain. Fixed slides were placed in the second staining tray containing the dye for 12 min. Then, the slides were rinsed in deionized water for 3 s and placed at a  $30^\circ$  angle to air dry. The reagent has been designed to stain all parts of the sperm in various shades of deep blue (head, acrosome, midpiece and tail; van der Horst & Maree, 2009).

Manual sperm morphology analysis under an optical microscope (Nikon Eclipse E200) at magnifications:  $\times 40$  dry and  $\times 100$  with immersion oil (Euromex, Germany) was performed by two experienced practitioners. The mean result was calculated. Simultaneously with the manual analysis, a computer-assisted sperm analysis system CASA 5.4.0.0 SCA Research Edition – Morphology (Microptic, Spain) was used. Analysis was performed at  $\times 100$  magnification with immersion oil (Euromex, Germany).

The results were recorded in test reports from the CASA5.4.0.0 SCA Research Edition system—Morphology (Microptic, Spain) and a subjective morphological assessment survey.

Data analysis was performed using Microsoft Excel 2016 (Microsoft Office 2016). Original data have been transformed into percentages for statistic evaluation and graph imaging. Sperm characteristics were normally distributed (Shapiro–Wilk test—IBM SPSS Statistics 26) and only compared between both staining groups. The normal and abnormal sperm percentage was analysed using the Student's *t*-test. Descriptive data are expressed as mean  $\pm$  SD. Differences were considered to be statistically significant when  $p < .05$ .



**FIGURE 1** Defects in the heads, acrosomes, insertions and tails of canine spermatozoa. Authors' rendition. Sperm Blue<sup>®</sup> (1,2,3,6,7,8,9,10,12,13,14,15,16,18,19,20,23,24,25,26,27,28,31,33,36,37) Sperm Stain<sup>®</sup> (4,5,11,17,21,22,29,30,32,34,35). 1 – ruptured acrosome; 2 – detached head; 3 – midpiece defect; 4 – acrosome and midpiece atrophy; 5 – acrosome stratification; 6 – micro-sperm head; 7 – small sperm head; 8 – amorphous head, abnormal midpiece angle; 9 – amorphous head; 10 – wrapping of midpiece; 11 – an absence of acrosome; 12 – pear-shaped head; 13 – granules in sperm head; 14 – pear-shaped head and absence of well-defined acrosome; 15 – micro-round head; 16 – head at the midpiece erosion; 17 – double-headed sperm; 18 – cyst at the apex of the sperm acrosome; 19 – granules in the sperm head; 20 – double-headed, amorphous sperm; 21 – tapered head; 22 – double-headed sperm; 23 – vacuoles in the sperm head; 24 – cyst at the apex of the head; 25 – paintbrush head; 26 and 35 – rolling of sperm tail; 27 – two tails; 28 and 36 – acrosome swelling and rolling of tail; 29 and 34 – Dag defect; 30–2 – double sperm; 31 and 32 – the presence of distal cytoplasmic droplet; sperm with short tail; 33 – short tail; 37 – normal sperm head



### 3 | RESULTS

#### 3.1 | Subjective assessment of sperm morphology using a standard optical microscope

The results have been summarized in graphs (Figures 3 and 4).

Both stains were successfully applied for canine spermatozoa manual morphology evaluation. Sperm Stain<sup>®</sup> dye enabled detailed

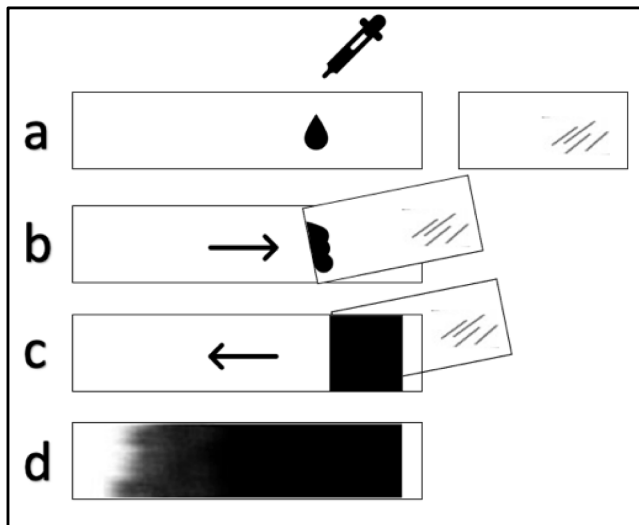


FIGURE 2 Diagram of a smear preparation. Authors' rendition

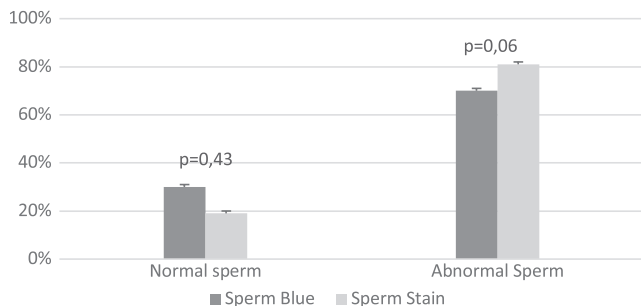
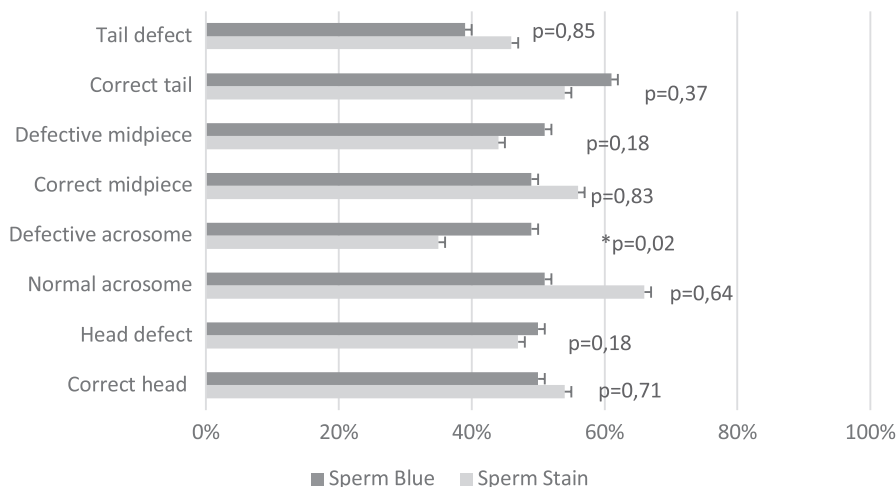


FIGURE 3 Comparison of subjective, manual evaluation of Sperm Stain<sup>®</sup> and Sperm Blue<sup>®</sup> stained samples. Normal/abnormal spermatozoa

FIGURE 4 Summary of subjective morphological evaluation of spermatozoa. Comparison of Sperm Stain<sup>®</sup> and Sperm Blue<sup>®</sup> for different teratozoospermic characteristics



morphology examination and differentiation of teratozoospermic characteristics. In Sperm Blue<sup>®</sup> staining, normal spermatozoa were clearly visible, while abnormal changes of sperm morphology, other than shape and size, were lost. However, a manual count of normal sperm percentage using both stains resulted in a similar score.

A statistically significant difference in acrosome defects between used stains was found ( $p = .02$ ): Sperm Blue<sup>®</sup> (49%) showed acrosome defects more often than Sperm Stain<sup>®</sup> (35%). Other differences were not statistically significant and are presented in the graph (Figure 4).

#### 3.2 | Analysis of sperm morphology in the CASA system (Microptic)

Both stains were successfully applied for canine spermatozoa computer-assisted morphology evaluation. The results have been summarized in graphs (Figures 5–7).

Sperm Stain<sup>®</sup> stained all parts of the head and showed morphological and morphometric defects related to the shape and dimensions of the head and anomalies of the midpiece. The CASA5.4.0.0 system did not mark the tail.

Automatic, computer-assisted morphology evaluation using Sperm Stain<sup>®</sup> showed 1.2% of normal sperm and 98.8% of abnormal sperm. The main abnormalities were head defects (98.8%). In 8.6% spermatozoa, multiple abnormalities occurred (head +midpiece). The tail was not marked in Sperm Blue<sup>®</sup> staining.

Computer-assisted Sperm Blue<sup>®</sup> staining evaluation showed 4.1% of normal sperm and 95.9% of abnormal sperm. The main pathologies were the head defects (95.4%), the midpiece defects were also present in 4.1% of the tested sperm, and the tail defects were not automatically marked.

In slides stained with Sperm Blue<sup>®</sup>, the CASA system marked sperm as normal more often than in Sperm Stain<sup>®</sup> slides (Figure 5).

The CASA system in both stains did not mark defects of the tail and did not notice cytoplasmic drops' presence. Defects of the midpiece and the head were automatically noted more frequently in the Sperm Stain<sup>®</sup> slides.

Detailed analysis of results obtained from the CASA system followed by statistical analysis (Student's *t*-test) showed a difference in identifying spermatic anomalies (Figure 7 and Table 1).

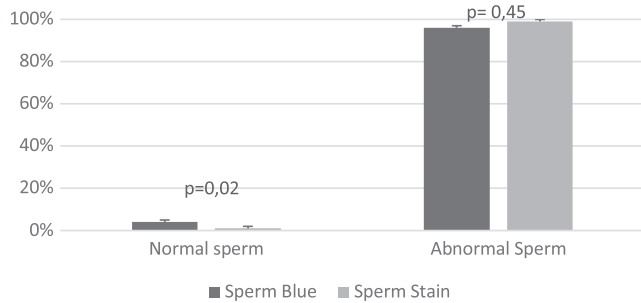


FIGURE 5 Comparison of automatic Sperm Stain<sup>®</sup> and Sperm Blue<sup>®</sup> staining analysis in CASA 5.4.0.0 system. Normal/abnormal spermatozoa

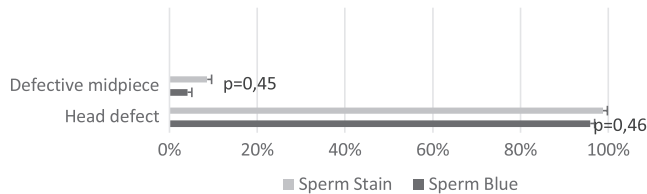


FIGURE 6 Comparison of automatically detected morphological defects results from the same samples stained with Sperm Stain<sup>®</sup> and Sperm Blue<sup>®</sup>. Analysis in CASA 5.4.0.0 system

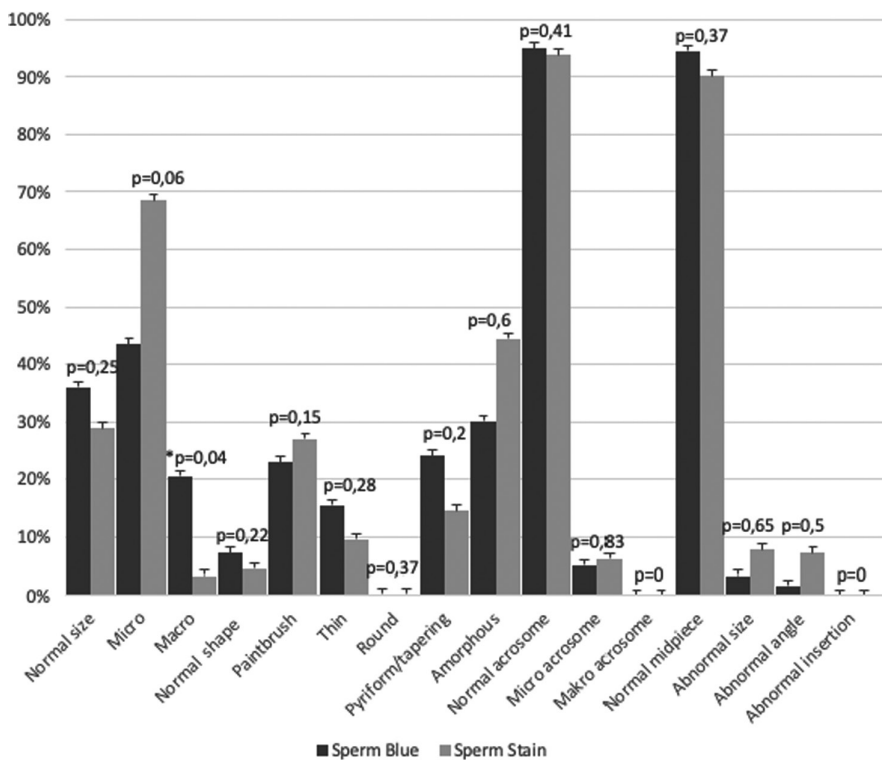


FIGURE 7 Summary of sperm morphological defects. Comparison of Sperm Stain<sup>®</sup> and Sperm Blue<sup>®</sup> staining. Analysis in CASA system

## 4 | DISCUSSION

Computer-assisted sperm analysis systems are commonly used for the evaluation of human sperm. It proved helpful in infertility clinic practice, saves time and ensures objective, precise evaluation independent of the practitioner's experience. CASA systems are recognized as a valuable tool by WHO laboratory manual 2021 (van der Horst et al., 2018). This system, however, has its disadvantages. For example, its accuracy is dependent on sample preparation, and even slight differences in staining intensity can compromise automatic evaluation. The system also focuses on analysing sperm heads, while other organelles are not analysed so thoroughly; therefore, defects such as the Dag defect, tail wraps, tail fracture or the presence of cytoplasmic droplets are not classified as abnormal sperm. The other disadvantage is the inability to analyse sperm in clusters. Any imperfection in the image, that is, the presence of protein debris, may disturb the correctness of sperm shape selection. Nevertheless, CASA systems have been optimized and successfully used for many farm animals like boars, bulls or horses (van der Horst et al., 2018).

Analysing canine sperm in the CASA system appears to be inaccurate. Results of this study point out that many spermatozoa, despite their physiological correctness confirmed by experienced practitioners in manual evaluation, were not falling within limits set by the CASA system and are marked as abnormal (van der Horst et al., 2018). However, the precise morphology of canine spermatozoa is a topic of wide discussion, and morphological parameters might vary depending on a dog's breed (Chłopak & Wysokińska, 2020; Maree, du Plessis, Menkveld, & van der Horst, 2010; Soler et al., 2017).

In standard veterinary practice, a simple analysis of sperm morphology is performed manually, using a stained sample and an optical microscope. This examination is more error-prone for an inexperienced andrology technician, but it seems to be still a gold standard technique for canine sperm assessment.

Regardless of the chosen method of sperm analysis, an important point is to select the appropriate staining technique for the species, which impacts the accuracy of the test, as shown by studies on

human sperm (Maree et al., 2010) and on livestock sperm (Freneau, Chenoweth, Ellis, & Rupp, 2010). The staining technique should not interfere with the physiological structure of spermatozoa while exhibiting most of the morphological details (Maree et al., 2010). The search for the most accurate method of staining sperm cells has led to many staining techniques. Accuracy of the morphological evaluation largely depends on the careful preparation of samples, the experience of the person performing the test and the method of staining used (Czubaszek, Andraszek, Banaszewska, & Walczak-Jędrzejowska, 2019).

This study compares two sperm staining systems by Microptic: Sperm Blue<sup>®</sup> and Sperm Stain<sup>®</sup>.

The Sperm Blue<sup>®</sup> staining resulted in intense staining of the head, which does not allow for the exact identification of the acrosome area and morphological defects, which may inhibit subjective morphological evaluation of sperm. Similar observations were presented by Czubaszek et al. (2019). Sperm Blue<sup>®</sup> staining seems better for sperm analysis of healthy dogs with no indication of reproductive system diseases. This stain was also easier to work with while using the CASA system of sperm morphology. Sperm Blue<sup>®</sup> stain is recommended for this system, and newer versions of this stain and software are developed every year.

There are few studies on Sperm Stain<sup>®</sup> staining. The system's composition is similar to the Diff-Quik<sup>®</sup> staining commonly used in human and veterinary medicine as a universal cytological stain.

During the study, Sperm Stain<sup>®</sup> dyed samples were considered easier to evaluate in the subjective, manual assessment of the canine sperm morphology, as all organelles were clearly visible and distinguishable. Sperm Stain<sup>®</sup> turned out to be a bit more demanding in the CASA, as the automatic system commonly failed to cover a mark of whole spermatozoa and often failed to correctly identify sperm organelles (vide Figure 8).

Well-conducted morphological and morphometric sperm analysis is a crucial part of andrological diagnostics (Czubaszek et al., 2019).

TABLE 1 Summary of sperm morphological defects

Sperm defect	Sperm Stain <sup>®</sup> (%)	Sperm Blue <sup>®</sup> (%)
Normal size	29.0	36.0
Micro head	68.5	43.5
Macro head	3.3	20.5
Normal shape	4.5	7.2
Paintbrush	27.0	22.9
Thin	9.5	15.4
Round	0.3	0.3
Pyriform/tapering	14.5	24.0
Amorphous	44.5	20.1
Normal acrosome	93.8	94.9
Micro acrosome	6.2	5.1
Macro acrosome	0.0	0.0
Normal midpiece	90.2	94.5
Abnormal size	7.7	3.4
Abnormal angle	7.1	1.7
Abnormal insertion	0.0	0.0
Normal tail	100.0	100.0
Abnormal tail	0.0	0.0

Note: Comparison of Sperm Stain<sup>®</sup> and Sperm Blue<sup>®</sup> staining. Analysis in CASA system.

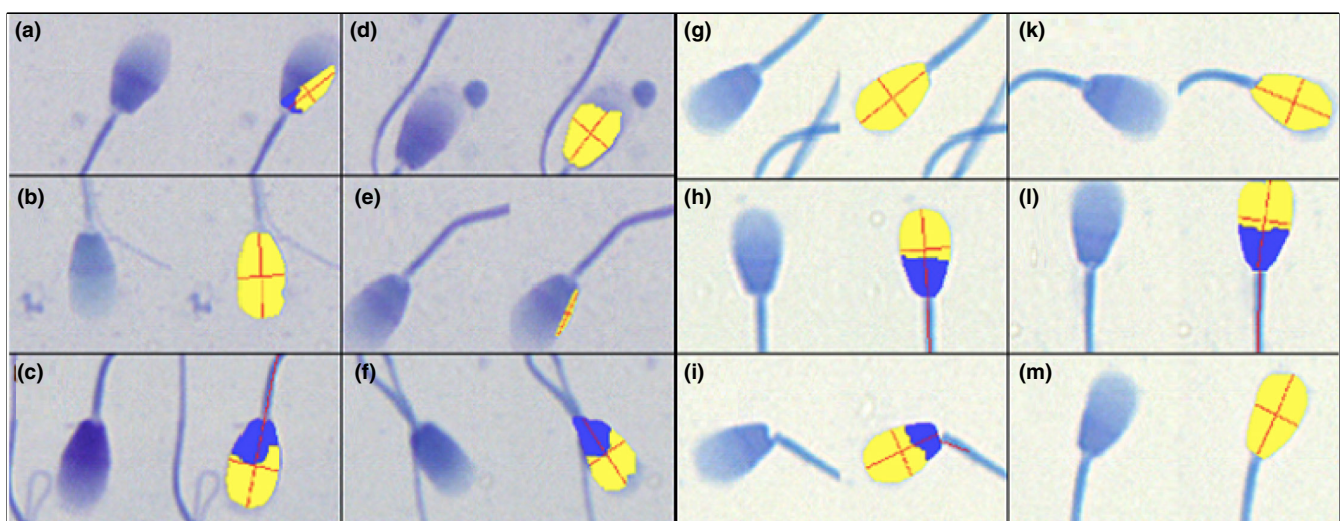


FIGURE 8 Analysis of CASA 5.4.0.0 SCA Research Edition – Morphology module (Microptic, Spain) A-F Sperm Stain sperm staining; G-M Sperm Blue staining. Authors' rendition

As a conclusion of this study, the Sperm Blue<sup>®</sup> stain seems to be more efficient during computer-assisted morphology assessment, especially while evaluating fertile dogs, that is, while studying detailed sperm morphometry. The Sperm Stain<sup>®</sup> reagent appears to be more beneficial for standard, manual evaluation as it allows identifying organelles and clear spermatozoa structure. Specific differentiation of teratozoospermic traits can lead to a better diagnosis in cases of fertility problems.

In conclusion, Sperm Blue<sup>®</sup> staining can be performed in conjunction with a computer-assisted sperm assessment system to routinely check the quality of the canine ejaculate. However, in case of repeated unsuccessful fertilizations or diagnosed diseases of the male reproductive system, a subjective, manual, detailed evaluation of sperm morphology should be performed, preferably using a Sperm Stain<sup>®</sup>.

## ACKNOWLEDGEMENT

This research received no specific grant from any funding agency in the public, commercial or not-for-profit sectors.

## CONFLICT OF INTEREST

The authors whose names are listed immediately below certify that they have NO affiliations with or involvement in any organization or entity with any financial interest (such as honoraria; educational grants; participation in speakers' bureaus; membership, employment, consultancies, stock ownership or other equity interest; and expert testimony or patent-licensing arrangements) or non-financial interest (such as personal or professional relationships, affiliations, knowledge or beliefs) in the subject matter or materials discussed in this manuscript.

## DATA AVAILABILITY

The data that support the findings of this study are available from the corresponding author upon reasonable request.

## ORCID

Anna Niwinska  <https://orcid.org/0000-0001-9024-9237>

## REFERENCES

- Bartlett, D. J. (1962). Studies on dog semen. *Reproduction*, 3(2), 173–189. <https://doi.org/10.1530/JRF.0.0030173>
- Brito, M. M., Angrimani, D. D. S. R., Rui, B. R., Kawai, G. K. V., Losano, J. D. A., & Vannucchi, C. I. (2020). Effect of senescence on morphological, functional and oxidative features of fresh and cryopreserved canine sperm. *Aging Male*, 23(4), 279–286. <https://doi.org/10.1080/13685538.2018.1487931>
- Chenoweth, P. J. (2005). Genetic sperm defects. *Theriogenology*, 64(3), 457–468. <https://doi.org/10.1016/J.THERIOGENOLOGY.2005.05.005>
- Chłópiak, A., & Wysokińska, A. (2020). Canine spermatozoa—What do we know about their morphology and physiology? An overview. *Reproduction in Domestic Animals*, 55(2), 113–126. <https://doi.org/10.1111/RDA.13596>
- Czubaszek, M., Andraszek, K., Banaszewska, D., & Walczak-Jędrzejowska, R. (2019). The effect of the staining technique on morphological and morphometric parameters of boar sperm. *PLoS One*, 14(3), e0214243. <https://doi.org/10.1371/JOURNAL.PONE.0214243>
- Dahlbom, M., Andersson, M., Vierula, M., & Alanko, M. (1997). Morphometry of normal and teratozoospermic canine sperm heads using an image analyzer: Work in progress. *Theriogenology*, 48(4), 687–698. [https://doi.org/10.1016/S0093-691X\(97\)00284-7](https://doi.org/10.1016/S0093-691X(97)00284-7)
- Domostawska, A., & Zdunczyk, S. (2020). Canine babesiosis – A disease rarely considered in the context of male infertility. *Irish Veterinary Journal*, 73(1). <https://doi.org/10.1186/S13620-020-00174-Y>
- Freneau, G., Chenoweth, P., Ellis, R., & Rupp, G. (2010). Sperm morphology of beef bulls evaluated by two different methods. *Animal Reproduction Science*, 118(2–4), 176–181. <https://doi.org/10.1016/J.ANIREPROSCI.2009.08.015>
- Hollinshead, F. K., Ontiveros, M., Burns, J. G., Magee, C., & Hanlon, D. W. (2020). Factors influencing parentage ratio in canine dual-sired litters. *Theriogenology*, 158, 24–30. <https://doi.org/10.1016/J.THERIOGENOLOGY.2020.08.030>
- Kolster, K. A. (2018). Evaluation of canine sperm and management of semen disorders. *Veterinary Clinics of North America—Small Animal Practice*, 48(4), 533–545. <https://doi.org/10.1016/j.cvsm.2018.02.003>
- Lopate, C. (2012). The problem stud dog. *Veterinary Clinics of North America—Small Animal Practice*, 42(3), 469–488. <https://doi.org/10.1016/J.CVSM.2012.01.014>
- Maree, L., du Plessis, S. S., Menkveld, R., & van der Horst, G. (2010). Morphometric dimensions of the human sperm head depend on the staining method used. *Human Reproduction*, 25(6), 1369–1382. <https://doi.org/10.1093/HUMREP/DEQ075>
- Marelli, S. P., Beccaglia, M., Bagnato, A., & Strillacci, M. G. (2020). Canine fertility: The consequences of selection for special traits. *Reproduction in Domestic Animals = Zuchthygiene*, 55(Suppl 2), 4–9. <https://doi.org/10.1111/RDA.13586>
- Peña, A. I., Barrio, M., Becerra, J. J., Quintela, L. A., & Herradón, P. G. (2007). Infertility in a dog due to proximal cytoplasmic droplets in the ejaculate: Investigation of the significance for sperm functionality in vitro. *Reproduction in Domestic Animals*, 42(5), 471–478. <https://doi.org/10.1111/j.1439-0531.2006.00809.x>
- Peña Martínez, A. I. (2004). Canine fresh and cryopreserved semen evaluation. *Animal Reproduction Science*, 82–83, 209–224. <https://doi.org/10.1016/J.ANIREPROSCI.2004.04.024>
- Seager, S. W., & Platz, C. C. (1977). Collection and evaluation of canine semen. *Veterinary Clinics of North America*, 7(4), 765–773. [https://doi.org/10.1016/S0091-0279\(77\)50089-5](https://doi.org/10.1016/S0091-0279(77)50089-5)
- Soler, C., Alambiaga, A., Martí, M. A., García-Molina, A., Valverde, A., Contell, J., & Campos, M. (2017). Dog sperm head morphometry: Its diversity and evolution. *Asian Journal of Andrology*, 19(2), 149. <https://doi.org/10.4103/1008-682X.189207>
- Tamiozzo, P. J. (2021). *Mycoplasma maculosum* and *Mycoplasma spumans* associated with fertility disorders in dogs from a Bernese mountain dog kennel. *Revista Argentina De Microbiología*, 46(2), 4. <https://doi.org/10.1016/J.RAM.2021.04.001>
- van der Horst, G., & Maree, L. (2009). SpermBlue: A new universal stain for human and animal sperm which is also amenable to automated sperm morphology analysis. *Biotechnic & Histochemistry*, 84(6), 299–308. <https://doi.org/10.3109/10520290902984274>
- van der Horst, G., Maree, L., & du Plessis, S. S. (2018). Current perspectives of CASA applications in diverse mammalian spermatozoa. *Reproduction, Fertility, and Development*, 30(6), 875–888. <https://doi.org/10.1071/RD17468>

**How to cite this article:** Surmacz, P., Niwinska, A., Kautz, E., Gizinski, S., & Faundez, R. (2022). Comparison of two staining techniques on the manual and automated canine sperm morphology analysis. *Reproduction in Domestic Animals*, 57, 678–684. <https://doi.org/10.1111/rda.14100>