

# Development of postoperative central anticholinergic syndrome due to low-dose intravenous fentanyl

### ABSTRACT

A 37-year-old female patient, 57 kg and 160 cm, underwent laparoscopic appendectomy. In the recovery room, fentanyl 100 mcg was intravenously administered for pain control. Three minutes after the administration, the patient developed intense and uncontrolled myoclonus, lower limb rigidity, agitation, aphasia, and periorcular and neck swelling. The myoclonus and rigidity were suspected to be due to the opioid administration, and thus, naloxone was administered, but the symptoms were not improved. The patient's symptoms continued until the patient received administration of physostigmine. The patient was discharged 3 days later, following resolution of the symptoms. We report a case of central anticholinergic syndrome that developed after general anesthesia owing to the interaction of opioid at an analgesic dose for postoperative pain control with another anesthetic.

**Key words:** Central anticholinergic syndrome; fentanyl; myoclonus; postoperative pain control

### Introduction

Central anticholinergic syndrome (CAS) is a disease that can be caused by sedatives, antidepressants, and antihistamines. However, it can occur in many drugs used in the anesthetic field. CAS can cause fatal outcomes such as respiratory failure or brain damage. Hence, early diagnosis and treatment are important. CAS involves a wide range of mental states from agitation to depression, as well as various symptoms such as myoclonus, rigidity, shivering, respiratory depression, and aphasia. Since CAS shows nonspecific neurologic symptoms, the syndrome is diagnosed if the symptoms are improved by the administration of physostigmine, following appropriate consideration of the differential diagnosis.<sup>[1]</sup>

When an opioid is used for postoperative pain control, myoclonus and rigidity may rarely occur at an analgesic dose, and these symptoms are generally improved with administration of naloxone owing to the antagonistic effect of naloxone on opioids.<sup>[2]</sup> However, in this case, myoclonus and rigidity occurred 3 min after the administration of an intravenous (iv) fentanyl bolus at an analgesic dose, and administration of naloxone to reverse the opioid side effects failed to improve the symptoms. Therefore, considering the pattern of agitation, aphasia, myoclonus, and rigidity, CAS due to the interaction of the opioid with another drug was suspected, and physostigmine was thus administered; this improved the patient's symptoms.

We report a case of CAS that developed after general anesthesia owing to the interaction of opioid at an analgesic dose for postoperative pain control with another anesthetic.

This is an open access article distributed under the terms of the Creative Commons Attribution-NonCommercial-ShareAlike 3.0 License, which allows others to remix, tweak, and build upon the work non-commercially, as long as the author is credited and the new creations are licensed under the identical terms.

**For reprints contact:** reprints@medknow.com

**How to cite this article:** Cho H, Kim J. Development of postoperative central anticholinergic syndrome due to low-dose intravenous fentanyl. Saudi J Anaesth 2018;12:328-31.

Video Available on: [www.saudija.org](http://www.saudija.org)

Access this article online

Website:

[www.saudija.org](http://www.saudija.org)

DOI:

10.4103/sja.SJA\_478\_17

Quick Response Code



### HOJAE CHO, JIYEON KIM

Department of Anesthesiology and Pain Medicine, Inje University Ilsan Paik Hospital, Juhwa-ro 170, Ilsan Seo-gu, Gyeonggi-do, Republic of Korea

**Address for correspondence:** Dr. Jiyeon Kim, Inje University Ilsan Paik Hospital, Juhwa-ro 170, Ilsan Seo-gu, Gyeonggi-do, Republic of Korea. E-mail: jy67925@naver.com

## Case Report

A 37-year-old female patient, 58 kg and 160 cm, with no specific medical history, underwent general anesthesia for laparoscopic appendectomy. The patient had no history of convulsions, neurologic abnormalities, or administration of antipsychotic medication. Anesthesia was induced with 2% lidocaine 80 mg, 1% propofol 100 mg, and rocuronium 40 mg and maintained with remifentanyl and desflurane. For postoperative pain control, drip infusion of nefopam 20 mg mixed with normal saline 100 cc was initiated 20 min before the end of the operation. After completion of the operation, glycopyrrolate 0.2 mg and pyridostigmine 10 mg were administered to reverse the muscular relaxation. The intraoperative vital signs were stable, and the total duration of the operation was 80 min. Following the operation, self-tidal volume 350 mL, forceful hand grip, eye opening, and alert mentality were verified to perform extubation and then transfer the patient to the recovery room.

Upon arrival in the recovery room, the patient complained of pain at a level of 8 on the numeric rating scale, and fentanyl 100 mcg was administered intravenously. Three minutes after the fentanyl administration, the patient developed intense and uncontrolled myoclonus in both arms at a rate of three to four times per second as well as rigidity in both lower limbs [Figure 1] [Video Available on]. The patient's mental status was agitated. The patient also displayed periorbital swelling, facial flushing, and neck swelling as well as aphasia. The pupil diameter was 3–4 mm, and the light reflex was normal. Vital signs were as follows: blood pressure 100/42 mmHg, heart rate 90/min, respiratory rate 30/min, body temperature 36.7°C, and SaO<sub>2</sub> 98% with face mask with reservoir bag 10 L. As opioid-induced myoclonus and rigidity were suspected, IV administration of naloxone

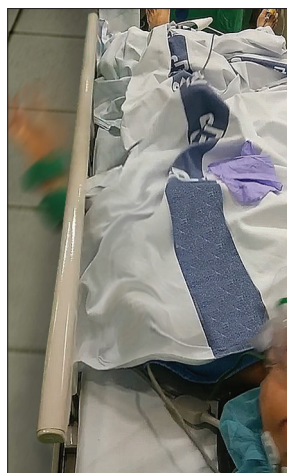

Figure 1: Upper-limb myoclonus, lower limb rigidity

40 mcg was performed. One minute after the naloxone administration, the myoclonus in the upper limbs as well as the rigidity in the lower limbs, aphasia, and agitation continued in the same pattern. IV Dexamethasone 5mg was administered for the periorbital swelling, facial flushing, and neck swelling. The bispectral index showed a value between 80 and 85. Doll's eyes examination performed to rule out brain stem abnormality revealed normal findings [Figure 2]. Arterial blood gas analysis performed and electrolyte imbalance was not observed. Midazolam 2 mg was administered intravenously; this resulted in slight improvement in the agitation. Facial flushing and neck swelling gradually improved. A neurologist performed a neurologic examination, but neither specific findings representing organic brain abnormality or hypoxic brain damage nor seizure activity was observed. CAS was suspected, and IV administration of physostigmine 1 mg was slowly performed over 2 min. Subsequently, the symptoms of myoclonus and rigidity were improved. The patient was transported to the sub-Intensive Care Unit (ICU) for further evaluation and observation 2 h after the symptoms occurred.

Laboratory tests and brain magnetic resonance imaging performed to rule out organic causes of the patient's symptoms revealed normal findings. Even after transfer to the sub-ICU, the patient continued to show myoclonus in the upper limbs that occurred three to four times per hour as well as rigidity in the lower limbs. On postoperative day (POD) 1, the myoclonus in the upper limbs occurred one to two times per hour, and the patient was able to walk with the help of a caregiver. The aphasia was improved to the degree of enabling communication. The patient described her previous state as "being conscious and able to hear voices, but unable to move her body as she wanted." On POD 2, the myoclonus in the upper limbs and the rigidity in the lower limbs had almost completely resolved, and the patient was able to walk on her own. On POD 3, the patient was discharged with no particular

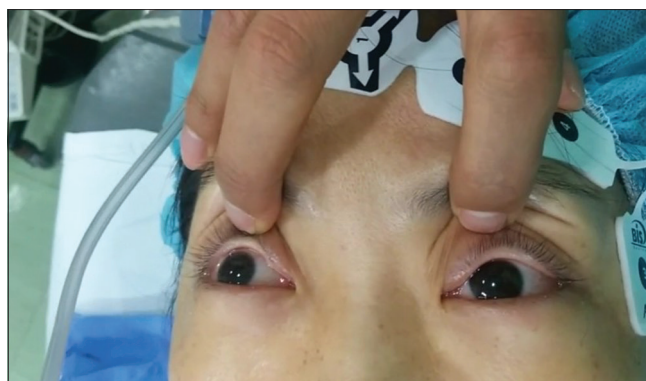

Figure 2: Doll's eye examination (vestibulo-ocular reflex), light reflex: No specific abnormality

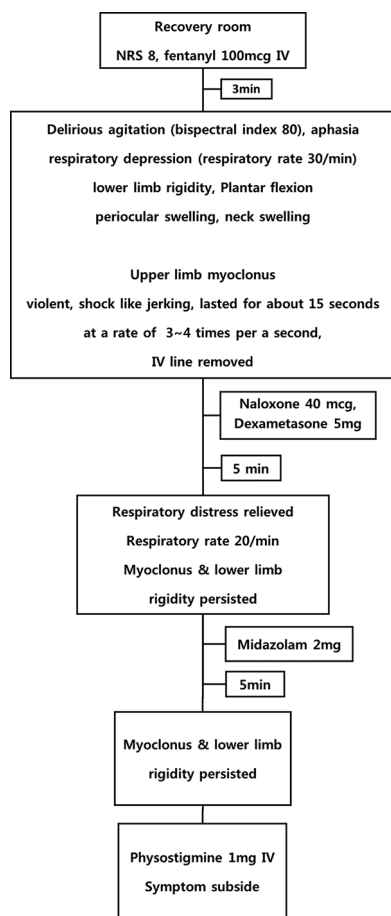


Figure 3: Patient symptom flow diagram

complications [Figure 3].

### Discussion

CAS occurs when antimuscarinic medications prevent acetylcholine from acting on muscarinic receptors to cause relative activation of nicotinic receptors in the central nervous system.<sup>[3]</sup>

CAS involves many nonspecific symptoms. The central symptoms are extensive, ranging from agitation to depression, and the peripheral signs include warm and dry skin, dry mouth, tachycardia, and urinary retention. Therefore, it is critical to perform differential diagnosis by ruling out the effects of other drugs as well as metabolic abnormalities and neurologic diseases. When CAS is suspected, physostigmine is administered, and CAS is then diagnosed if the symptoms are improved by the administration of this agent.<sup>[4]</sup>

In this case, myoclonus and rigidity occurred immediately after IV administration of fentanyl 100 mcg for postoperative pain control. These symptoms may be frequently observed when narcotic analgesics are used, mostly in patients who

are administered antipsychotics, such as antidopaminergic agents.<sup>[4-6]</sup> However, it is rare that CAS occurs after only one IV administration at an analgesic dose, as in this case. Most adverse effects of a narcotic analgesic may be reversed by naloxone, and myoclonus has been improved in many reported cases.<sup>[2,6]</sup> In this case, however, only the respiratory system symptoms were improved following the administration of naloxone while other symptoms, such as aphasia, agitation, myoclonus, and rigidity, continued.

As the patient in this case showed altered mental status as well as myoclonus, rigidity, and aphasia, we suspected CAS in relation an anticholinergic effect resulting from the interaction between the previously administered drugs.

Not only antimuscarinic agents such as atropine and scopolamine but also various other drugs with anticholinergic effects may cause CAS. Fentanyl, meperidine, nitrous oxide, glycopyrrolate, and nefopam may have such an effect.<sup>[7]</sup> A study measuring the anticholinergic burden of various drugs such as meperidine, nefopam, codeine, and cimetidine may, although rarely, show a moderate anticholinergic effect, and thus, the possibility of CAS due to drug interactions should be considered in their use.<sup>[8]</sup>

Fentanyl, nefopam, and glycopyrrolate were administered to the patient in this case. Glycopyrrolate, a quaternary amine, is not lipophilic and is thus unable to penetrate the blood brain barrier to cause CAS. Nefopam, although its mechanism has not been clarified, is known as a drug showing a nonopioid analgesic effect through inhibition of the reuptake of serotonin, dopamine, and norepinephrine. Nefopam is also known to have various anticholinergic effects, as demonstrated by case reports of dry mouth and urinary retention, as well as altered mental status including confusion and delirium.<sup>[9]</sup> While nefopam showed a moderate anticholinergic scale score, fentanyl showed a low anticholinergic scale score.<sup>[8]</sup> Therefore, in this case, it was difficult to conclude that fentanyl, showing a low anticholinergic scale score, caused the CAS independently. As there have been no published reports of CAS caused by fentanyl alone, the interaction of fentanyl with other drugs had to be suspected in this case. Therefore, it was presumed that the CAS was caused by the anticholinergic effect of nefopam and fentanyl.

Physostigmine, which is used for the diagnosis and treatment of CAS, is a lipophilic tertiary amine that is able to penetrate the blood brain barrier to show a central effect.<sup>[1,7]</sup> In this case, the patient received IV administration of physostigmine 1 mg for 2 min, after which the symptoms of myoclonus, rigidity,

and aphasia were improved. Therefore, the patient was diagnosed with CAS. When physostigmine was administered to the patient, the IV administration was performed for 2 min while observing the adverse effect of bradycardia. Observation is important because it can sometimes show severe bradycardia.<sup>[10]</sup> Even if the symptoms improved with physostigmine, there was a difference for each person. Drug effect duration was relatively short, about 2 h, so we had to monitor the recurrent symptom continuously.

Another possible explanation in this case is prolonged myoclonus due to propofol. Cases of prolonged myoclonus due to propofol have been reported in the literature, including one case in which myoclonus occurred during recovery in a recovery room and continued for about 3 weeks.<sup>[11]</sup> However, in this case, the symptoms occurred immediately after the IV administration of fentanyl, and the pattern of myoclonus was different from that of previous reports, indicating that the possibility of prolonged myoclonus due to propofol is low.

As CAS often occurred in the past when atropine or scopolamine was administered as premedication, CAS is currently not readily taken into consideration if one of these drugs is not administered. Therefore, in this case, we did not suspect CAS and administer physostigmine until 2 h had elapsed after the patient first showed symptoms. In our case, it is regrettable that we did not perform rapid diagnosis and treatment.

## Conclusion

When a patient shows altered mental status and atypical neurological symptoms postoperatively, CAS due to the interaction between various anesthesia-related drugs should

keep in mind. Since diagnostic suspicion is critical in CAS, rapid diagnosis and treatment should be performed for the safety of patients.

## Financial support and sponsorship

Nil.

## Conflicts of interest

There are no conflicts of interest.

## References

1. Brown DV, Heller F, Barkin R. Anticholinergic syndrome after anesthesia: A case report and review. *Am J Ther* 2004;11:144-53.
2. Bowdle TA, Rooke GA. Postoperative myoclonus and rigidity after anesthesia with opioids. *Anesth Analg* 1994;78:783-6.
3. Weinbroum AA. Pathophysiological and clinical aspects of combat anticholinesterase poisoning. *Br Med Bull* 2004;72:119-33.
4. Watkins JW, Schwarz ES, Arroyo-Plasencia AM, Mullins ME, Toxicology Investigators Consortium investigators. The use of physostigmine by toxicologists in anticholinergic toxicity. *J Med Toxicol* 2015;11:179-84.
5. Yaksh TL, Harty GJ, Onofrio BM. High dose of spinal morphine produce a nonopiate receptor-mediated hyperesthesia: Clinical and theoretic implications. *Anesthesiology* 1986;64:590-7.
6. Weinger MB, Sanford TJ, Smith NT. Do dopaminergic drugs really prevent opiate-induced rigidity? *Anesth Analg* 1988;67:900-2.
7. Schneck HJ, Ruprecht J. Central anticholinergic syndrome (CAS) in anesthesia and intensive care. *Acta Anaesthesiol Belg* 1989;40:219-28.
8. Salahudeen MS, Duffull SB, Nishtala PS. Anticholinergic burden quantified by anticholinergic risk scales and adverse outcomes in older people: A systematic review. *BMC Geriatr* 2015;15:31.
9. Park YS, Kim YB, Kim JM. Status epilepticus caused by Nefopam. *J Korean Neurosurg Soc* 2014;56:448-50.
10. Burns MJ, Linden CH, Gaudins A, Brown RM, Fletcher KE. A comparison of physostigmine and benzodiazepines for the treatment of anticholinergic poisoning. *Ann Emerg Med* 2000;35:374-81.
11. Tam MK, Irwin MG, Tse ML, Lui YW, Law KI, Ng PW, *et al.* Prolonged myoclonus after a single bolus dose of propofol. *Anaesthesia* 2009;64:1254-7.