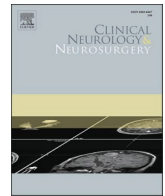




Since January 2020 Elsevier has created a COVID-19 resource centre with free information in English and Mandarin on the novel coronavirus COVID-19. The COVID-19 resource centre is hosted on Elsevier Connect, the company's public news and information website.

Elsevier hereby grants permission to make all its COVID-19-related research that is available on the COVID-19 resource centre - including this research content - immediately available in PubMed Central and other publicly funded repositories, such as the WHO COVID database with rights for unrestricted research re-use and analyses in any form or by any means with acknowledgement of the original source. These permissions are granted for free by Elsevier for as long as the COVID-19 resource centre remains active.



## COVID-19 infection produces subarachnoid hemorrhage; acting now to understand its cause: A short communication

Osman Ersegun Batcik<sup>a</sup>, Ayhan Kanat<sup>a,\*</sup>, Tuba Uyar Cankay<sup>b</sup>, Gulsah Ozturk<sup>c</sup>, Leyla Kazancioğlu<sup>d</sup>, Hizir Kazdal<sup>d</sup>, Hasan Gundogdu<sup>e</sup>, Bulent Ozdemir<sup>a</sup>, Ilkay Bahceci<sup>f</sup>, Ugur Kostakoglu<sup>g</sup>, Sule Batcik<sup>d</sup>, Omer Gundogdu<sup>b</sup>, Gokcen Sevilgen<sup>h</sup>

<sup>a</sup> Recep Tayyip Erdogan University, Medical Faculty, Department of Neurosurgery, Rize, Turkey

<sup>b</sup> Recep Tayyip Erdogan University, Medical Faculty, Department of Neurology, Rize, Turkey

<sup>c</sup> Memorial Health Group Sisli Hospital Neurosurgery, Department, Istanbul, Turkey

<sup>d</sup> Recep Tayyip Erdogan University Medical Faculty, Department of Anesthesiology and Reanimation Rize, Turkey

<sup>e</sup> Recep Tayyip Erdogan University Medical Faculty, Department of Radiology, Rize, Turkey

<sup>f</sup> Recep Tayyip Erdogan University Medical Faculty, Department of Medical Microbiology, Rize, Turkey

<sup>g</sup> Recep Tayyip Erdogan University, Medical Faculty, Department of Infectious Diseases and Clinical Microbiology, Rize, Turkey

<sup>h</sup> Recep Tayyip Erdogan University, Medical Faculty Department of Thoracic Surgery Rize, Turkey

### ARTICLE INFO

#### Keywords:

Spontaneous subarachnoid hemorrhage  
COVID-19 infection

### ABSTRACT

In the medical literature, some case reports on the association of the COVID-19 infection and occurrence of spontaneous subarachnoid hemorrhage (SAH) have been reported. Aim of the present paper is to search the causes of this association. The diagnosis of COVID-19 was based on the real-time reverse-transcription polymerase chain reaction (PCR) test and computed tomography (CT) of the chest. There were four patients, whose median ages were 46,758, ranged 36–54 years). In conclusion, Spontaneous SAH can occur in the early and late course of COVID-19 infection. Its early recognition of the patient with spontaneous SAH is imperative.

### Introduction

The novel coronavirus disease 2019 (COVID-19) is a global pandemic with international concern [1]. SAH is a devastating disease [2], which accounts for approximately 5–10 % of strokes [2]. Several case reports about the SAH and COVID-19 infection have been reported [3–6], but three reviews about the interaction between COVID-19 and the central nervous system have been recently published, but the occurrence of SAH in patients with Covid-19 infection has not been mentioned in these reviews [7–9]. There is limited knowledge on the SAH following COVID-19 at present. A direct or indirect association between the occurrence of spontaneous SAH and COVID-19 has not been demonstrated yet. Identifying factors for diagnosis and management of patients with COVID-19 infection and SAH is necessary.

### Methods

COVID-19 infections associated with spontaneous SAH were

retrospectively analyzed in patients who were admitted between March 10 and 2 September 2020 to a university hospital. The patients with positive lung CT findings underwent formal testing using a real-time reverse-transcription polymerase chain reaction (PCR) analysis (Bio-Speedy Covid-19 RTQPCR Bioeksan, Turkey) or rapid Test COVID-19 for detecting IgM and IgG antibodies (Covid-19 IgM/IgG Ab-CG hotgen Beijing hotgen biotech Co. Germany). Patients were excluded if they had a hemorrhage due to head trauma or other causes. DSA was performed to diagnose the aneurysm of patients.

### Results

Four consecutive patients COVID 19 with spontaneous SAH admitted between 10 March 2020 and 2 September 2020. The median age was 46,758 between 36–54 years).

*Abbreviations:* CT, computed tomography; SAH, subarachnoid hemorrhage.

\* Corresponding author.

*E-mail address:* [ayhankanat@yahoo.com](mailto:ayhankanat@yahoo.com) (A. Kanat).

<https://doi.org/10.1016/j.clineuro.2021.106495>

Received 14 September 2020; Received in revised form 10 January 2021; Accepted 11 January 2021

Available online 19 January 2021

0303-8467/© 2021 Elsevier B.V. All rights reserved.

## Cases

**Case 1.** GH, 52 years old female admitted with the sudden loss of consciousness. Her fever ( $38.9^{\circ}\text{C}$ ), her GCS was 3. On admission, a CT scan showed a diffuse spontaneous SAH and intraventricular hemorrhage (World Federation of Neurosurgical Societies grade 5, grade 4 on modified Fisher scale). Her chest CT and PCR test were positive for Covid-19. CT demonstrated SAH, including a ventricular and anterior interhemispheric, and left Sylvian fissure hemorrhage with generalized sulcal effacement and cerebral edema. DSA showed an anterior communicating artery aneurysm with a diameter of  $6,5 \times 5$  mm size. She died after 13 days of hospitalization.

**Case 2.** EC, 54 years male admitted with low consciousness and low GCS (3) score He has had fixed and dilated pupils and fever ( $39.2^{\circ}\text{C}$ ). His non-contrast computed tomography (CT) brain showed massive spontaneous SAH. World Federation of Neurologic Surgeons (WFNS) grading scale for SAH was 5. The chest CT was consistent with COVID-19. Reverse transcription-polymerase chain reaction (RT-PCR) from nasopharyngeal swab specimens confirmed positive COVID-19. The patient died after two days of hospitalization.

**Case 3.** TE, a 45 years old male, was admitted to the hospital with a high fever ( $39.1^{\circ}\text{C}$ ), severe dyspnea. His neurological examination was intact. His chest CT showed an involvement consistent with COVID-19. Reverse transcription-polymerase chain reaction (RT-PCR) from nasopharyngeal swab specimens was negative for COVID-19, but his serum COVID-19 rapid Test detected IgM and IgG antibodies to COVID-19. The patient was hospitalized for ten days, and medical treatment was given. Four months after discharge, sudden deterioration occurred. His GCS 3, pupils were dilated, nonresponsive to light. Noncontrast cranial CT revealed SAH. Ten days after hospitalization, the patient died.

**Case 4.** 36 years woman was referred to our hospital after sudden deterioration. Before admission, she had no symptoms and signs related COVID-19. Her GCS was 3 at the admission, the patient was immediately intubated. Her chest CT showed a COVID-19 related diffuse involvement. Fisher Grade 4 SAH was seen on the Cranial CT. Polymerase chain reaction (PCR) and chest CT for Covid-19 were positive. Her clinical status improved after admission, but no aneurysm was detected in DSA examination.

## Discussion

### Main findings

This article provides evidence of the spontaneous SAH producing effect of COVID-19 infection in four cases. A ruptured aneurysm was detected in only one of these four patients. Our study demonstrates that there a risk of spontaneous SAH with COVID-19 infection, there can be a direct or indirect relationship between the occurrence of spontaneous SAH and COVID-19 depending on endothelial dysfunction of patients with Covid-19 infection. Three of four cases were admitted to the hospital with a high fever. Reddy et al. reported their experience of 12 cases with COVID-19 infection and concurrent cerebrovascular disease [10]. In their series of 12 patients, 10 patients had an ischemic stroke, of which 1 suffered hemorrhagic transformation and only two had intracerebral hemorrhage [10]. Recently, a European multicenter study, eighteen COVID 19 patients with intracranial hemorrhage were reported [11]. Of these patients, 11(61.1 %) has had SAH [11], but secondary SAH was seen in only one patient. In this European multicenter study case series, no aneurysm was found in DSA. The major pathologic state of necrotizing vasculitis is typically associated with parenchymal hemorrhage [11]. In our case series, cranial and chest CTs were obtained. No evidence of a vascular pathology (except aneurysm in case 1) was observed. SAH may be depended on anticoagulation therapy, two patients of the present study had not used anticoagulation therapy, their

platelet count, and the prothrombin time was normal. Another problem is that ECMO and ventilation may lead to an increased incidence of intracranial hemorrhage [11], likely SAH. However, in four of our case series, SAH had been occurred, before ECMO and ventilation therapy has been given.

## Conclusion

Understanding the relationship between spontaneous SAH and COVID-19 is of paramount importance to implement management changes, such as obtaining cranial and thorax CT of patients. In our cases, spontaneous SAH were incidentally identified, all patients died. The Covid-19 primarily affects the lungs. On chest imaging, multi-focal areas of consolidation in a peripheral distribution pattern were observed in all four cases. Every suspected SAH patient should be screened for possible COVID-19 symptoms. If there are positive lung symptoms, non-contrast chest, and brain CT at the same time should be obtained. SAH may occur in the early (in three patients, case, 1,2,4) and late course (case 3) of COVID-19 infection. Understanding the occurrence of SAH in COVID-19 is still at the beginning phase. Detection of spontaneous SAH in patients with COVID-19 is likely not easy given limited and difficult examination in many critical care patients. We speculate that COVID-19 infection triggers SAHs, but the mechanism can not be fully understood by limited sources or publications. If we consider the nervous system as a great orchestra that can express a complete range of rhythms and melodies and the most complex harmonic combinations [12], we will find it easier to understand the relationship between Covid-19 related endothelial dysfunction and SAH. To understand the biomechanical, molecular, and cellular effects [13] of Covid-19 infection-related SAH, more histopathological studies are needed. Its early recognition is imperative. The paper will provide further studies. It is required to act now to understand its cause.

## Funding

No funding was received for this paper.

## Ethical approval

All procedures performed in studies involving human participants were under the ethical standards of the institutional and/or national research committee (name of institute/committee) and with the 1964 Helsinki declaration and its later amendments or comparable ethical standards. "For this type of study, formal consent is not required."

## CRediT authorship contribution statement

**Osman Ersegun Batcik:** Conceptualization, Methodology, Software. **Ayhan Kanat:** Conceptualization, Methodology, Software, Writing - review & editing. **Tuba Uyar Cankay:** Conceptualization, Methodology, Software. **Gulsah Ozturk:** Data curation, Writing - original draft. **Leyla Kazancioglu:** Data curation, Writing - original draft. **Hizir Kazdal:** Data curation, Writing - original draft. **Hasan Gundogdu:** Data curation, Writing - original draft. **Bulent Ozdemir:** Data curation, Writing - original draft. **Ilkay Bahceci:** Data curation, Writing - original draft. **Ugur Kostakoglu:** Investigation, Visualization. **Sule Batcik:** Investigation, Visualization. **Omer Gundogdu:** Supervision. **Gokcen Sevilgen:** Software, Validation.

## Declaration of Competing Interest

All authors certify that they have no affiliations with or involvement in any organization or entity with any financial interest.

## References

- [1] D. Chachkhiani, M.Y. Soliman, D. Barua, M. Isakadze, N.R. Villemarette-Pittman, D.J. Devier, J.F. Lovera, Neurological complications in a predominantly African American sample of COVID-19 predict worse outcomes during hospitalization, *Clin. Neurol. Neurosurg.* 197 (2020), 106173, <https://doi.org/10.1016/j.clineuro.2020.106173>.
- [2] M.D. Aydin, A. Kanat, C. Yolas, C. Soyalp, M.R. Onen, I. Yilmaz, N.C. Karaavci, M. Calik, O. Baykal, L. Ramazanoglu, Spinal Subarachnoid Hemorrhage Induced Intractable Miotic Pupil. A Reminder of Ciliospinal Sympathetic Center Ischemia Based Miosis: An Experimental Study, *Turk. Neurosurg.* 29 (2019) 434–439, <https://doi.org/10.5137/1019-5149.JTN.24446-18.1>.
- [3] S. Basirjafari, M. Rafiee, B. Shahhosseini, M. Mohammadi, S.A.S. Neshin, M. Zarei, Association of pediatric COVID-19 and subarachnoid Hemorrhage, *J. Med. Virol.* (2020), <https://doi.org/10.1002/jmv.26434>.
- [4] A. Craen, G. Logan, L. Ganti, Novel Coronavirus Disease 2019 and Subarachnoid Hemorrhage: A Case Report, *Cureus.* 12 (2020), e7846, <https://doi.org/10.7759/cureus.7846>.
- [5] S. Harrogate, A. Mortimer, L. Burrows, B. Fiddes, I. Thomas, C.M. Rice, Non-aneurysmal subarachnoid haemorrhage in COVID-19, *Neuroradiology* (2020) 1–4, <https://doi.org/10.1007/s00234-020-02535-4>.
- [6] D.J. Altschul, S.R. Unda, R. de La Garza Ramos, R. Zampolin, J. Benton, R. Holland, A. Fortunel, N. Haranhalli, Hemorrhagic presentations of COVID-19: risk factors for mortality, *Clin. Neurol. Neurosurg.* 198 (2020), 106112, <https://doi.org/10.1016/j.clineuro.2020.106112>.
- [7] M.P. Wilson, A.S. Jack, Coronavirus disease 2019 (COVID-19) in neurology and neurosurgery: A scoping review of the early literature, *Clin. Neurol. Neurosurg.* 193 (2020), 105866, <https://doi.org/10.1016/j.clineuro.2020.105866>.
- [8] S.O. Alomari, Z. Abou-Mrad, A. Bydon, COVID-19 and the central nervous system, *Clin. Neurol. Neurosurg.* 198 (2020), 106116, <https://doi.org/10.1016/j.clineuro.2020.106116>.
- [9] V. Montalvan, J. Lee, T. Bueso, J. De Toledo, K. Rivas, Neurological manifestations of COVID-19 and other coronavirus infections: a systematic review, *Clin. Neurol. Neurosurg.* 194 (2020), 105921, <https://doi.org/10.1016/j.clineuro.2020.105921>.
- [10] S.T. Reddy, T. Garg, C. Shah, F.A. Nascimento, R. Imran, P. Kan, R. Bowry, N. Gonzales, A. Barreto, A. Kumar, J. Volpi, V. Misra, D. Chiu, R. Gadhia, S. I. Savitz, Cerebrovascular disease in patients with COVID-19: a review of the literature and case series, *Case Rep. Neurol.* 12 (2020) 199–209, <https://doi.org/10.1159/000508958>.
- [11] J. Nawabi, A. Morotti, M. Wildgruber, G. Boulouis, H. Kraehling, F. Schlunk, E. Can, H. Kniep, G. Thomalla, M. Psychogios, B. Hamm, J. Fiehler, U. Hanning, P. Sporns, Clinical and Imaging Characteristics in Patients with SARS-CoV-2 Infection and Acute Intracranial Hemorrhage, *J. Clin. Med.* 9 (2020), <https://doi.org/10.3390/jcm9082543>.
- [12] E.R. Gasenzer, A. Kanat, E. Neugebauer, Neurosurgery and music; effect of Wolfgang amadeus mozart, *World Neurosurg.* 102 (2017) 313–319, <https://doi.org/10.1016/j.wneu.2017.02.081>.
- [13] B. Ozdemir, A. Kanat, H. Kazdal, Deneysel Beyin Yaralanma Modelleri Experimental Cerebral Injury Models, *Turk Norosirurji Derg.* 30 (2020) 308–311.