



About this issue

Glaucoma affects millions of people worldwide, but it is difficult to diagnose and manage. In this issue, we have included practical articles to help clinicians facing the challenge of providing care to glaucoma patients. Topics include glaucoma detection and diagnosis, gonioscopy (a vital examination technique), the latest guidelines for open-angle glaucoma management, and tips for managing neovascular glaucoma and the painful, blind eye. We also look at the importance of counselling and how low vision support can benefit patients with vision loss due to glaucoma.

Contents

- 31 Update on glaucoma**
Elmien Wolvaardt and Victor H Hu
- 32 Defining and diagnosing glaucoma: a focus on blindness prevention**
Jibran Mohamed-Noriega and G Chandra Sekhar
- 36 The optic nerve head in glaucoma**
Rupert RA Bource and Tasneem Khatib
- 40 Gonioscopy skills and techniques**
Winnie Nolan and Adeola Onakoya
- 43 Management of chronic open-angle glaucoma**
Heiko Philippin
- 47 Counselling in a glaucoma care service**
Fatima Kyari, Heiko Philippin, Peter Shah, Hannah Faal, Sani Babayo and Mohammed Abdull
- 51 Low vision care for patients with glaucoma: there is more you can do!**
Karin Van Dijk, Aimbora Kristonsia Kimaro and Heiko Philippin
- 53 Neovascular glaucoma: prevention and treatment**
Jibran Mohamed-Noriega and Jason A Penniecook
- 55 Managing the painful blind eye**
Jason A Penniecook, Doris Sarai Garza Cruz and Maria Soledad Pighin Caminos
- 57 Minimum requirements for a glaucoma programme**
Fatima Kyari and Rohit C Khanna
- 59 Minimally invasive glaucoma surgery (MIGS) devices: risks, benefits and suitability**
Francisco Otárola and Francisco Pooley
- 61 The global challenge of glaucoma**
Victor H Hu
- 62 Exploring strategies for trachoma elimination in Ethiopia**
Adugna Amin, Alemayehu Sisay and Tim Jesudason
- 63 Test your knowledge: glaucoma**
- 64 Picture quiz and useful resources**



Jibran Mohamed-Noriega

Associate Professor:
Department of Ophthalmology,
University Hospital and
Faculty of Medicine,
Autonomous University of
Nuevo Leon, Mexico.



G Chandra Sekhar

Vice Chair:
VST Center for Glaucoma,
L V Prasad Eye Institute,
Hyderabad, India.

Defining and diagnosing glaucoma: a focus on blindness prevention

A diagnostic approach that focuses on patients with definite (or clinical) glaucoma optimises the likelihood of preventing visual disability due to this potentially blinding condition.

The term glaucoma refers to a group of diseases that affect the optic nerve and could potentially lead to irreversible visual loss. Glaucomatous optic neuropathy is the hallmark of all types of glaucoma. It is characterised by deformation of the optic nerve (see Figure 1, page 4), which manifests as diffuse or focal narrowing of the neuroretinal rim and peripapillary retinal nerve fibre layer loss. The type of glaucoma, the severity of the disease, and the risk of blindness can be assessed by carrying out gonioscopy, slit lamp examination, visual field tests, and intraocular pressure (IOP) measurement.

Definitions of glaucoma

The definition of glaucoma in adults has changed over the years due to changes in our understanding of how glaucoma affects the eye, the technology available, and the

Community Eye Health Journal

VOLUME 33 • NUMBER 112 • 2021



INTERNATIONAL CENTRE FOR EYE HEALTH



LONDON SCHOOL OF HYGIENE & TROPICAL MEDICINE



Editor

Elmien Wolvaardt
editor@cehjournal.org

Medical editor

Victor Hu

Consulting editor for Issue 112

Victor Hu

Editorial administrator

Anita Shah admin@cehjournal.org

Editorial committee

Simon Arunga (Uganda)
João M Furtado (Brazil)
Clare Gilbert (UK)
Esmael Habtamu (Ethiopia)
Fatima Kyari (Nigeria)
Ciku Mathenge (Rwanda)
Nyawira Mwangi (Kenya)
GVS Murthy (India)
Heiko Philippin (Germany)
Thulsiraj Ravilla (India)
Serge Resnikoff (Geneva)
Jude Stern (Australia)

Sumrana Yasmin (Pakistan)
David Yorston (UK)

Editorial advisors

Nick Astbury (Partnerships)
John Buchan (Ophthalmology)
Jenny Evans (Systematic reviews)
Michelle Hennelly (Ophthalmic nursing)
Islay Mactaggart (Disability)
Priya Marjoria (Optometry)
Daksha Patel (Education)

Regional consultants

Hannah Faal (AFR)
Kovin Naidoo (AFR)
Van Lansingh (AMR)
Andrea Zin (AMR)
Ian Murdoch (EUR)
Janos Nemeth (EUR)
GVS Murthy (SEAR)
R Thulsiraj (SEAR)
Babar Qureshi (EMR)
Mansur Rabi (EMR)
Leshan Tan (WPR)
Hugh Taylor (WPR)

Design

Lance Bellers

Printing

Newman Thomson

Download our app

Download the free *Community Eye Health Journal* app today: bit.ly/CEHJ-app

Visit us online www.cehjournal.org

Subscribe

Visit: www.cehjournal.org/subscribe
Email: web@cehjournal.org

Readers in low- and middle-income countries receive print copies free of charge. To subscribe, send your name, occupation, and postal address to:

Anita Shah, International Centre for Eye Health, London School of Hygiene and Tropical Medicine, Keppel Street, London WC1E 7HT, UK.

Email: admin@cehjournal.org

reasons why a particular definition was constructed. A current **clinical definition** of glaucoma is: "A characteristic pattern of glaucomatous optic neuropathy (e.g., narrowing of the neuroretinal rim) with corresponding visual field defects."

Other changes related to glaucoma might be present in some patients before a clinical diagnosis is made. These may include:

- Thinning of the retinal nerve fibre layer or ganglion cell layer, which can be visualised using optical coherence tomography (OCT)
- Other functional changes such as reduced contrast sensitivity and electrophysiological abnormalities.

However, if clinically significant glaucomatous damage has occurred, then optic disc changes are normally visible, and it is very unusual that glaucoma would be diagnosed from visual field or OCT changes without disc features.

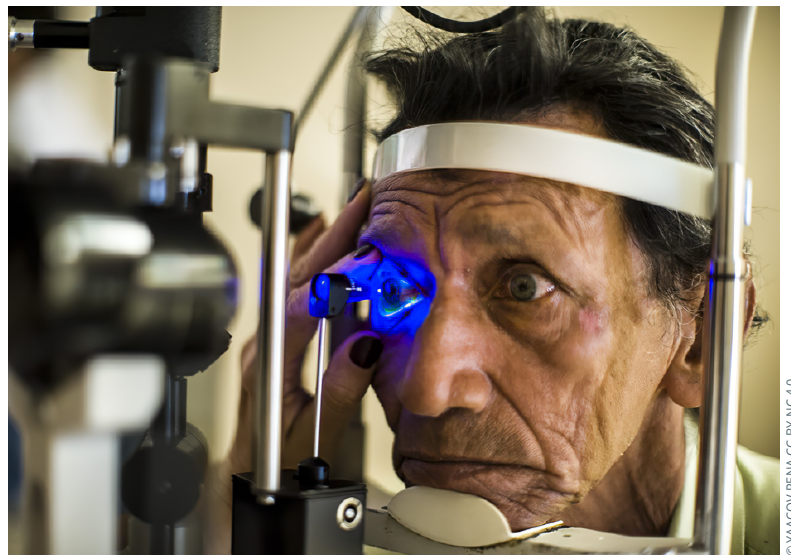In this article, we want to propose an approach to diagnosing adults with glaucoma that is focused on preventing visual disability. With this approach, we distinguish between two groups of patients:

- Patients with **definite** (or **unequivocal**) glaucoma: those who have definite signs of glaucomatous optic neuropathy. They are at imminent risk of visual loss, usually need treatment, and must be monitored.
- Patients with **suspected** (or **equivocal**) glaucoma: those with possible signs of glaucomatous optic neuropathy. They are not at immediate risk of visual loss, at least in the short term, and usually do not need treatment, but can/must be followed up and monitored (depending on the patient).

We propose that attention is focused on patients with **definite glaucoma** as they are at greater risk of blindness and are likely to require monitoring and treatment by more experienced eye care providers.

Essential investigations

The following investigations are needed in order to determine whether a patient has definite glaucoma requiring treatment, has suspected glaucoma and also for ongoing monitoring.



© YACOVY PENA CC BY-NC 4.0

Visual acuity with best correction. Although visual acuity only deteriorates at the last stages of glaucoma, measuring it on all visits is important to assess the overall visual function and rule-out other diseases.

Anterior segment examination using a slit lamp. This will help in the detection of secondary types of glaucoma such as pseudoexfoliation, uveitic or pigmentary glaucoma.

Anterior chamber angle assessment (including gonioscopy). This will determine whether the patient has open-angle or angle-closure glaucoma.

Examination of the optic nerve head. This is done using a slit lamp (binocularly) and a 90D or similar lens. Perform a dilated examination to rule out other retinal diseases and to make it easier to examine the optic nerve. Do this on the initial visit and yearly or if any clinical parameter (decreased visual acuity, new onset metamorphopsia etc.) changes significantly.

Visual field testing. Carry out static, automated perimetry, commonly performed using a Humphrey visual field machine.

Tonometry. Use Goldman's applanation tonometer.

Measuring intraocular pressure using a Goldmann tonometer.
COLOMBIA

Continues overleaf ➤

Support our work

We rely on subscriptions and donations from charities and generous individuals to carry out our work.

To support us, visit:

www.cehjournal.org/donate

or contact Anita Shah:

admin@cehjournal.org

Published by the International Centre for Eye Health, London School of Hygiene & Tropical Medicine.

Unless otherwise stated, authors share copyright for articles with the *Community Eye Health Journal*. Illustrators and photographers retain copyright for images published in the journal.

Please note that some articles are published online first and may have been shortened to fit the available space in this printed edition.

Unless otherwise stated, journal content is licensed under a Creative Commons Attribution-NonCommercial (CC BY-NC) license which permits unrestricted use,

distribution, and reproduction in any medium for non-commercial purposes, provided that the copyright holders are acknowledged.

ISSN 0953-6833.

Disclaimer

Signed articles are the responsibility of the named authors alone and do not necessarily reflect the views of the London School of Hygiene & Tropical Medicine (the School). Although every effort is made to ensure accuracy, the School does not warrant that the information contained in this publication is complete and correct and shall not be liable for any damages incurred as a result of its use.

The mention of specific companies or of certain manufacturers' products does not imply that they are endorsed or recommended by the School in preference to others of a similar nature that are not mentioned. The School does not endorse or recommend products or services for which you may view advertisements in this Journal.

The *Community Eye Health Journal* is supported by:



Sightsavers



The Fred Hollows Foundation
www.hollows.org



TIJSSSEN FOUNDATION

Optional investigations

These additional investigations or tests can be performed if needed and if the equipment is available.

Measuring central corneal thickness. This can improve the accuracy of measurements using Goldmann's applanation tonometer because this method overestimates IOP in patients with thick corneas and underestimates it in those with thin corneas. However, nomograms to 'correct' the IOP tend to be inaccurate at an individual level and are not recommended. A thin central cornea might influence the decision if the target IOP is reached in a patient with progressive disease, as the actual IOP is likely to be higher than measured.

Optical coherence tomography (OCT). This can help in the examination of the optic nerve and retina. The most frequently used metrics are the average thickness of the circumpapillary retinal nerve fibre and ganglion cell layer. However, each innovation cycle produces a different generation of devices with incompatible measurements, so the results cannot be compared for long-term follow-up assessments.

Corneal hysteresis. This non-contact tonometry technique also assesses the corneal biomechanical response and may prove to be helpful for glaucoma assessment.

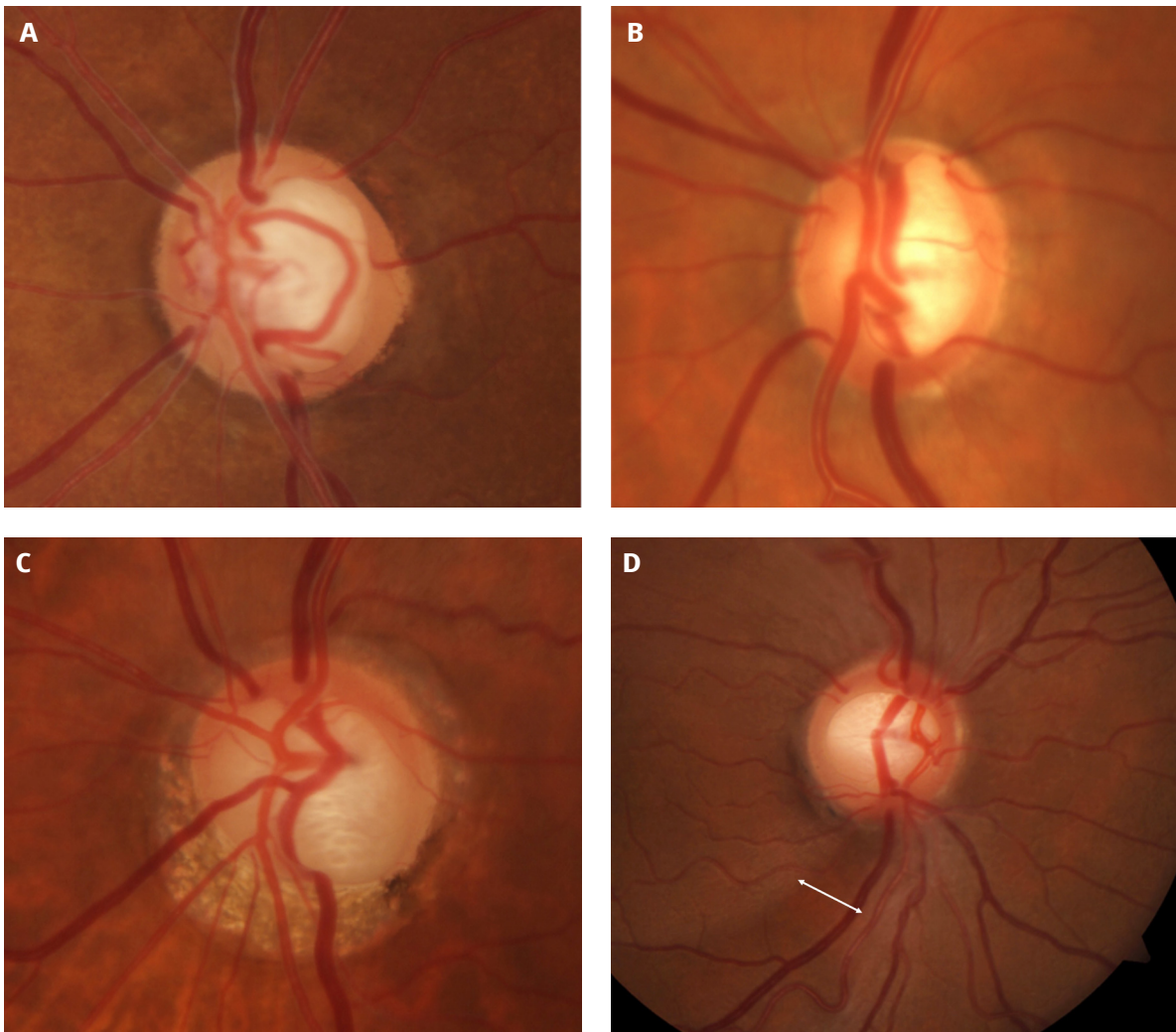
Characteristics of definite glaucoma

After an initial or single examination

The characteristics of a **definite** or unequivocal diagnosis of glaucoma and/or where intervention might be needed, **after an initial or single examination** include:

- 1 Focal complete loss of the neuroretinal rim. The disc damage likelihood scale (DDLS) is a good way of grading the optic disc.¹
- 2 DDLS stage ≥ 6 .
- 3 Cup-to-disc ratio > 0.8 .
- 4 Focal narrowing of the neuroretinal rim, with a corresponding visual field defect. It is important to identify if the sector of the optic nerve that is affected corresponds to the location of the VF defect. Representations of the structure-function relationship, such as the Garway-Heath map, help clinicians identify if the damaged sector of the neuroretinal rim is affecting the corresponding visual field locations (Figure 2).
- 5 IOP > 35 mm Hg is not diagnostic of glaucoma, but almost all patients with this IOP level need IOP-lowering interventions. A high IOP in the absence of disc damage may be seen in patients with a secondary glaucoma or primary angle closure disease. Over-estimation of the IOP should be considered, e.g., a non-contact tonometer used or a very thick cornea. It is recommended to repeat the measurement before initiating treatment.

Figure 1 Different forms of glaucomatous optic neuropathy. **A** Enlarged CDR. **B** Focal superior disc rim narrowing. **C** Diffuse loss of the inferior disc rim. **D** Inferotemporal thinning of the disc rim and retinal nerve fibre layer defect.



© AUTONOMOUS UNIVERSITY OF NUEVO LEÓN (UANL), MEXICO CC BY-NC 4.0

After consecutive examinations

On follow-up examination, the following signs of progression would confirm an unequivocal or definite diagnosis of glaucoma:

- 1 Progression of a **visual field defect** that corresponds to a location of narrow neuroretinal rim or retinal nerve fibre layer loss.
- 2 Progression of **glaucomatous optic neuropathy**:
 - Enlargement of the vertical cup-disc ratio > 0.2
 - Increase in DDLS > 2 stages
 - Increased narrowing of the neuroretinal rim (change in a sector of the neuroretinal rim (NNR) from narrow to complete loss or from a homogeneous neuroretinal rim to a narrow sector)
 - Significant expansion of a retinal nerve fibre layer defect on OCT
 - Change in the course of vessels due to changes of the optic nerve head
 - The detection of a single new disc haemorrhage usually should not be considered sufficient to diagnose glaucoma or progression, however, they do increase the risk of developing glaucoma and visual field deterioration, particularly if they appear repeatedly.

There are other factors which need to be considered when deciding on and planning the treatment of a person with glaucoma.

Patients with confirmed glaucoma, i.e., those who are most in need of treatment, can be diagnosed using a slit lamp, tonometer and visual fields alone. Clinicians who do not have access to other instruments, such as OCT, can be reassured that their patients are receiving good care so long as they receive a good clinical examination and visual field analysis.

When to suspect glaucoma

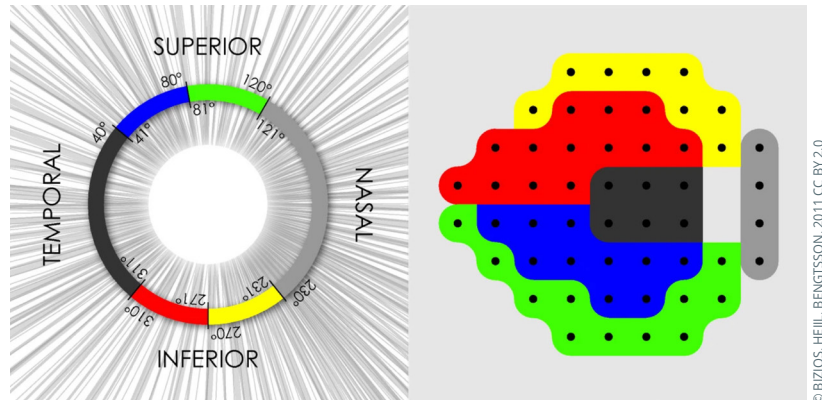
The identification of only one of the following characteristics is not enough to confirm the diagnosis of glaucoma, but they do raise the suspicion of possible glaucoma. See Figure 1 for examples.

- Cup-to-disc ratio > 0.7 (this value applies to all disc sizes, but in small discs, a smaller cup-to-disc ratio represents greater damage than in larger discs)
- Diffuse narrowing of the neuroretinal rim
- DDLS stage ≥ 4
- Disc haemorrhages
- Retinal nerve fibre layer defects
- IOP > 24 mm Hg increases the risk for glaucoma, especially in thin corneas
- Abnormal visual field defects (remember that all the diseases that affect the visual pathway from dry eye affecting the cornea, cataracts affecting the lens, retinal changes, to cerebral strokes affecting the posterior visual pathway, can affect the visual field results)
- A reduction in the thickness of OCT parameters.

It is important to remember that an OCT scan that flags in red the thickness of the retinal nerve fibre layer, ganglion cell layer, or optic nerve head rim of a

It is important to rule out secondary glaucomas which might well carry a high risk of glaucoma blindness."

Figure 2 Map representing the relationship between Standard Automated Perimetry visual field sectors and sections of the peripapillary OCT scan circle. This map is based on the work of Garway-Heath et al and shows the correspondence between areas of the visual field and peripapillary retinal nerve fibre layer due to the anatomical configuration of the retinal nerve fibre bundles.²



patient is not enough to diagnose glaucoma. These parameters are compared to a normative dataset that underrepresent many ethnic and age groups. Similarly, an OCT scan with all parameters in green is not enough to rule out glaucomatous optic neuropathy and should not be considered equivalent to a 'normal' optic nerve. OCT changes which, in reality, represent early glaucomatous changes, typically involve only the superior or infero-temporal neuroretinal rim or macular ganglion cell layer. These changes should usually correspond with optic disc changes seen clinically and/or with visual field changes (Figure 2).

It is always important to exclude non-glaucomatous causes of an enlarged cup-to-disc ratio and loss of neuroretinal rim or retinal nerve fibre layers.

Glaucoma classification

After clinical or definite glaucoma is diagnosed, the two main questions for the clinician are:

1. Is this glaucoma primary or secondary?

It is important to rule out secondary glaucomas which might well carry a high risk of glaucoma blindness. These include those which could have causative treatment if identified appropriately (e.g., neovascular glaucoma) and those associated with medical

conditions (e.g., uveitic or increased episcleral pressure glaucoma) and which may even potentially be life threatening (e.g., rheumatological diseases and cavernous-carotid fistulas).

2. Is the anterior chamber angle open or closed?

Gonioscopy is critical.

The management plan of a patient with glaucoma differs significantly depending on whether the iridotrabecular angle (where aqueous drains out of the eye) is open, narrow or closed and it is vitally important to determine this with gonioscopy.

When a patient is diagnosed with definite glaucoma, it is the responsibility of all eye care providers to advise patients and family about the increased risk of glaucoma in first-degree relatives.

References

- 1 Bayer A, Harasymowicz P, Henderer JD, Steinmann WG, Spaeth GL. Validity of a new disk grading scale for estimating glaucomatous damage: correlation with visual field damage. *Am J Ophthalmol* 2002;133(6):758–63.
- 2 Bizios D, Heijl A and Bengtsson B. Integration and fusion of standard automated perimetry and optical coherence tomography data for improved automated glaucoma diagnostics. *BMC Ophthalmol* 2011;11(20).

Further reading

- European Glaucoma Society guidelines. www.eugs.org/eng/guidelines.asp
- Foster PJ, Buhrmann R, Quigley HA, Johnson GJ. The definition and classification of glaucoma in prevalence surveys. *Br J Ophthalmol* 2002;86(2):238–42.
- American Academy of Ophthalmology. Preferred Practice Pattern: Primary Open Angle Glaucoma. www.aao.org/preferred-practice-pattern/primary-open-angle-glaucoma-ppp
- American Academy of Ophthalmology. Preferred Practice Pattern: Primary Angle Closure Disease. www.aao.org/preferred-practice-pattern/primary-angle-closure-disease-ppp