

# A Case of Heterotopic Ovarian Pregnancy after *in vitro* Fertilization: Early Diagnosis and Single-port Access Conservative Laparoscopic Treatment

Yeon Hee Hong<sup>1,2</sup>, Hyojin Kim<sup>3</sup>, Seul Ki Kim<sup>1,2</sup>, Byung Chul Jee<sup>1,2\*</sup>

Departments of <sup>1</sup>Obstetrics and Gynecology and <sup>3</sup>Pathology, Seoul National University Bundang Hospital, Seongnam, <sup>2</sup>Department of Obstetrics and Gynecology, Seoul National University College of Medicine, Seoul, Korea

## Abstract

Here, we reported the case of a 32-year-old pregnant woman who presented with sudden abdominal pain at 5 weeks of gestation and diagnosed as ruptured heterotopic ovarian pregnancy. She was conceived after *in vitro* fertilization. Right ovarian pregnancy was noticed, and we performed right ovarian wedge resection via single-port access laparoscopic surgery. Intrauterine pregnancy had remained intact, and she delivered a term baby. Rapid diagnosis in early gestation and minimally invasive laparoscopy resulted in a satisfactory pregnancy outcome without other complications. Single-port laparoscopic surgery can be feasible and appears to be a good first treatment option in a ruptured heterotopic ovarian pregnancy.

**Keywords:** Diagnosis, heterotopic, ovarian pregnancy, single-port laparoscopy

## INTRODUCTION

Heterotopic pregnancy refers to the case where both intrauterine and ectopic pregnancies exist simultaneously. Ectopic pregnancy can occur at salpinx, uterine cornus, uterine cervix, broad ligament, ovary, and abdomen, thus various forms of heterotopic pregnancy can also occur.<sup>[1]</sup>

The incidence of heterotopic pregnancy in the general population is rare as 1/8000–1/30,000.<sup>[2]</sup> Currently, the frequency of heterotopic pregnancy might increase, and one of the major contributors to the increment of heterotopic pregnancy is the wide use of assisted reproductive technology (ART). In fact, the frequency of heterotopic pregnancy has been reported as 1/100 in *in vitro* fertilization (IVF) cases and as 1/900 in women taking clomiphene citrate.<sup>[3,4]</sup>

Heterotopic ovarian pregnancy is very rare but its incidence in the general population or ART users is largely unknown. In one review article, the incidence of heterotopic ovarian pregnancy was 2.3% of all heterotopic pregnancies.<sup>[5]</sup> To date, there have been fewer than forty reported cases in PubMed/Medline.<sup>[6]</sup> In previous case reports, heterotopic ovarian pregnancy was diagnosed after 6 weeks of gestation, and all were surgically treated. Most of them received laparoscopic surgery but none received single-port access laparoscopic surgery. Here, we report a case of heterotopic ovarian pregnancy diagnosed in early gestational age and successfully treated by single-port access laparoscopic surgery. Finally, the term baby was successfully delivered.

**Address for correspondence:** Prof. Byung Chul Jee, Department of Obstetrics and Gynecology, Seoul National University Bundang Hospital, 82 Gumi-Ro 173-Beon-Gil, Bundang-Gu, Seongnam 13620, Korea.  
E-mail: blasto@snuh.org

### Article History:

**Submitted:** 19 March 2020

**Revised:** 16 April 2020

**Accepted:** 14 July 2020

**Published:** 30 January 2021

### Access this article online

#### Quick Response Code:



**Website:**  
www.e-gmit.com

**DOI:**  
10.4103/GMIT.GMIT\_117\_19

This is an open access journal, and articles are distributed under the terms of the Creative Commons Attribution-NonCommercial-ShareAlike 4.0 License, which allows others to remix, tweak, and build upon the work non-commercially, as long as appropriate credit is given and the new creations are licensed under the identical terms.

**For reprints contact:** WKHLRPMedknow\_reprints@wolterskluwer.com

**How to cite this article:** Hong YH, Kim H, Kim SK, Jee BC. A case of heterotopic ovarian pregnancy after *in vitro* fertilization: Early diagnosis and single-port access conservative laparoscopic treatment. *Gynecol Minim Invasive Ther* 2021;10:57-60.

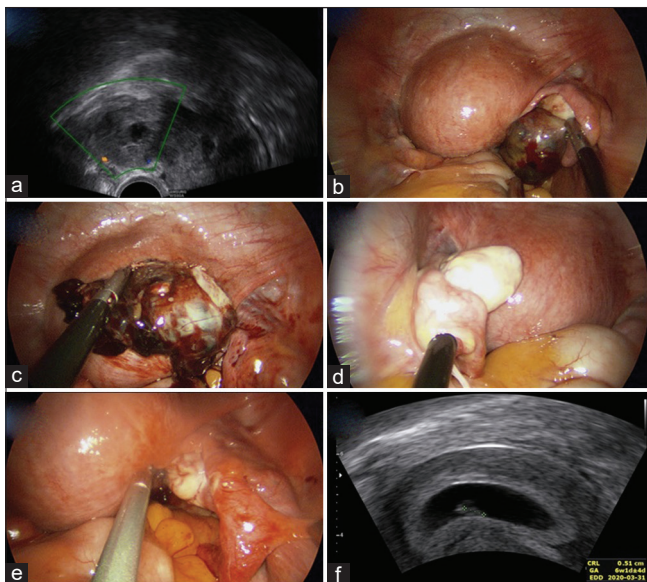
## CASE REPORT

A 32-year-old, nulliparous woman visited the Emergency Department at the Seoul National University Bundang Hospital on July 31, 2019. She was complaining right lower abdominal pain. She received day-3 double-embryo transfer at an infertility clinic and conceived thereafter. The gestational age was 5 + 4 weeks. There was no specific medical and surgical history. Her initial vital sign was stable. Her hemoglobin level was 12.7 g/dL, hematocrit was 38.5%, and serum  $\beta$ -human chorionic gonadotropin ( $\beta$ -hCG) level was 38,337 mIU/mL.

Physical examination revealed mild tenderness around the right pelvic cavity.

At the infertility clinic, hematoma around the right adnexa (3.2 cm in diameter) and free fluid collection in the pelvic cavity were identified by transvaginal ultrasound examination. We also identified hematoma around the right adnexa (3.4 cm in diameter) by transvaginal ultrasound examination [Figure 1a]. At the central portion of the hematoma, anechoic feature was seen, thus ectopic gestational sac or ovarian cyst was suspected. We also identified a single intrauterine gestational sac without yolk sac or fetal pole.

At that time, heterotopic tubal or ovarian pregnancy was strongly suspected. Thus, we performed an emergent single-port access laparoscopic surgery. First, approximately 200 mL of free blood was seen in the posterior cul-de-sac.



**Figure 1:** (a) Right adnexal mass (3.4 cm in diameter) during a transvaginal ultrasound examination. (b) Hematoma complex (4 cm in diameter) at the right ovary during single-port access laparoscopic surgery. (c) Identification of ruptured site at the right ovary, (d) normally looking left adnexa. (e) Normally looking right salpinx. (f) Viable intrauterine pregnancy with fetal heartbeats at postoperative 1 week (6 + 4 weeks of gestation)

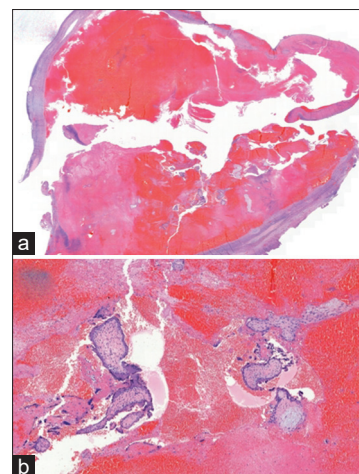
After blood suction, hematoma complex (4 cm in diameter) was observed at the postero-right lateral side of the right ovarian surface [Figure 1b]. The hematoma complex was in a partially ruptured state with bleeding and looked like an ectopic gestational sac mixed with hematoma and corpus luteum [Figure 1c].

The right salpinx and the left adnexa were normal [Figure 1d]. The hematoma complex on the right ovary was completely enucleated with salvaging the right ovary near completely [Figure 1e]. Hemostatic sealant (Surgicel; Johnson and Johnson, Switzerland) was applied on the remaining part of the right ovary. Skin suture was adapted by steri-strips after edge alignment. The total operation time was 40 min.

The hemoglobin level on postoperative day 1 was 11.6 g/dL, and serum  $\beta$ -hCG level was 47,729 mIU/mL. Transvaginal ultrasound confirmed that the intrauterine pregnancy is well maintained. There were no special events during the hospital stay. The degree of pain was relatively tolerable (an average of 3 points on a visual analog scale). She was discharged without any problems at postoperative day 2. Five days later (6 + 4 weeks of gestation), transvaginal ultrasound also confirmed that the intrauterine pregnancy is well maintained with good fetal heartbeats [Figure 1f]. The umbilical wound was clean and well adapted, and she did not complain wound pain or vaginal bleeding.

Pathologic examination confirmed right ovarian ectopic pregnancy. On microscopic examination, chorionic villi mixed with blood clots were observed in the ovarian parenchyma [Figure 2a and b].

There were no obstetrical complications during pregnancy. The patient delivered a baby at term by cesarean section on March 2020.



**Figure 2:** (a) Chorionic villi mixed with blood clots observed in the ovarian parenchyma ( $\times 6$ ). (b) The magnified view of chorionic villi ( $\times 50$ )

## DISCUSSION

We reported a case of heterotopic ovarian pregnancy, which occurred after IVF at a relatively earlier 5 weeks of gestation and treated successfully through single-port access laparoscopic surgery. Our case of ovarian pregnancy fulfilled four conditions as suggested by Spiegelberg; pregnancy in normally positioning ovary, the ovary attached to the uterus through the utero-ovarian ligament, intact fallopian tube, and existence of ovarian tissue in the wall of the gestational sac.<sup>[7]</sup>

Even one viable intrauterine pregnancy is already present, heterotopic pregnancy should be considered strongly when abdominal pain, adnexal mass, or free fluid collection around the adnexa exist.<sup>[8]</sup>

The presence of risk factors suggestive of the existence of heterotopic ovarian pregnancy may be helpful for diagnosis of heterotopic pregnancy; history of multiple embryo transfer or abnormally high  $\beta$ -hCG level or history of previous tubal surgery, history of ectopic pregnancy.<sup>[5,8]</sup> However, heterotopic pregnancy may commonly occur even in the absence of risk factors.<sup>[8]</sup>

In our case, a fairly high level of serum  $\beta$ -hCG, more than expected at 5 weeks of gestation, could be a clue for the suspicion of heterotopic pregnancy. However, heterotopic pregnancy could occur even when serum  $\beta$ -hCG level is as low as 125 mIU/mL.<sup>[9]</sup> The patient in our case received day-3 double-embryo transfer at another infertility clinic and conceived thereafter, and this information could be another clue for the suspicion of heterotopic pregnancy. The stage of embryo does not appear to be a significant factor because heterotopic pregnancy could occur after day-3 cleavage embryo or day-5 blastocyst transfer.<sup>[5]</sup>

Nonetheless, the diagnosis of heterotopic pregnancy is usually difficult. Some patients do not complain any symptoms, or complain nonspecific symptoms such as vaginal bleeding or abdominal pain, which may be confused with threatened abortion.<sup>[8]</sup> Because intrauterine pregnancy is present, it is not easy to presume that there will be presence of another ectopic pregnancy.

Adnexal mass is often confused with corpus luteal cyst of ovarian mass or an ovarian tumor.

Especially, ovarian pregnancy had been confused with corpus luteal cysts in many previous reports.<sup>[6,10]</sup> In fact, when evaluating with ultrasound examination, it was mistaken for an ovarian cyst.

Transvaginal ultrasound is the most useful tool for diagnostic purposes, but low sensitivity is a problem.<sup>[1]</sup> To overcome this pitfall, use of Doppler flow was suggested.<sup>[10]</sup> Peri-trophoblastic flow sometimes can be seen as typical “ring

of fire,” which is a characteristic feature of ectopic pregnancy. In case with ruptured ectopic pregnancy, free fluid collection at postcul-de-sac is commonly seen, and this finding has been suggested as a strong evidence of ectopic pregnancy.<sup>[8]</sup>

Heterotopic pregnancy is usually treated as a surgical approach. Systemic administration of methotrexate is contraindicated because of viable intrauterine pregnancy. The safety of laparoscopy has been reported in heterotopic pregnancies even in the presence of intrauterine pregnancy.<sup>[10]</sup> Heterotopic ovarian pregnancy has been traditionally managed with laparoscopic wedge resection or ipsilateral oophorectomy.<sup>[11]</sup>

Last year 2019, Ramalho *et al.* reported a live birth after laparoscopic treatment of a spontaneous heterotopic ovarian pregnancy.<sup>[10]</sup> We reported the first case of a child born after treatment of a heterotopic ovarian pregnancy with IVF through single-port access laparoscopic surgery.

In the present case, we found that single-port access laparoscopic surgery is feasible and safe in a case of heterotopic ovarian pregnancy. Our case report is also meaningful because the diagnosis of heterotopic pregnancy was made at 5 weeks of gestation and the surgery was promptly decided. Thus, single-port access laparoscopic surgery can be suggested as the first-line treatment option in heterotopic ovarian pregnancy.

## Ethical statement

This study was approved by the Ethics Committee of Seoul National University Bundang Hospital (approval no. B-1910/571-702). IRB approval was obtained on September 30, 2019.

## Declaration of patient consent

The authors certify that they have obtained all appropriate patient consent forms. In the form, the patient has given her consent for her images and other clinical information to be reported in the journal. The patient understands that her name and initial will not be published, and due efforts will be made to conceal identity, but anonymity cannot be guaranteed.

## Financial support and sponsorship

Nil.

## Conflicts of interest

There are no conflicts of interest.

## REFERENCES

1. Xu Y, Lu Y, Chen H, Li D, Zhang J, Zheng L. Heterotopic pregnancy after *in vitro* fertilization and embryo transfer after bilateral total salpingectomy/tubal ligation: Case report and literature review. *J Minim Invasive Gynecol* 2016;23:338-45.
2. Chen JS, Ke TY, Hsieh PC. Heterotopic ovarian pregnancy. *Taiwan J Obstet Gynecol* 2009;48:193-5.
3. Brunette DD, Roline C. Heterotopic pregnancy resulting from *in vitro*

- fertilization. *Am J Emerg Med* 2011;29:960.e1-2.
4. Honarbakhsh A, Khoori E, Mousavi S. Heterotopic pregnancy following ovulation induction by Clomiphene and a healthy live birth: A case report. *J Med Case Rep* 2008;2:390.
  5. Kamath MS, Aleyamma TK, Muthukumar K, Kumar RM, George K. A rare case report: Ovarian heterotopic pregnancy after *in vitro* fertilization. *Fertil Steril* 2010;94:1910.e9-11.
  6. Gundabattula SR, Resapu P, Surampudi K, Surapaneni T, De Padua M. Ovarian apoplexy resulting from ruptured heterotopic pregnancy following intrauterine insemination. *J Obstet Gynaecol Res* 2017;43:1222-6.
  7. Spiegelberg O. Casuistry in ovarian pregnancy. *Arch Gynecol Surv* 1978;13: 73-9.
  8. Stanley R, Fiallo F, Nair A. Spontaneous ovarian heterotopic pregnancy. *BMJ Case Rep* 2018. doi:10.1136/bcr-2018-225619.
  9. Trompoukis P, Chaidogiannos C, Zourla A, Grapsas S, Salampasis C, Papoulias I, *et al.* Spontaneous heterotopic pregnancy leading to intrauterine abortion and subsequent ruptured ectopic pregnancy with a bhCG of 125 mIU/ml: A case report-A case of a woman at five weeks of gestation. *Clinical and Experimental Obstetrics and Gynaecology* 2008;35:81-2.
  10. Ramalho I, Ferreira I, Marques JP, Carvalho MJ, Lobo A, Rebelo T, *et al.* Live birth after treatment of a spontaneous ovarian heterotopic pregnancy: A case report. *Case Rep Womens Health* 2019;24:e00144.
  11. Yu Y, Xu W, Xie Z, Huang Q, Li S. Management and outcome of 25 heterotopic pregnancies in Zhejiang, China. *Eur J Obstet Gynecol Reprod Biol* 2014;180:157-61.