

# Perioperative Anesthetic Management of an 18-month-old Pediatric Patient with a Congenital Coronary Fistula between the Left Circumflex Coronary Artery and Coronary Sinus: Report of a Rare Case

## Abstract

We present a case of an 18-month-old, 8.69 kg, female, who presented with a coronary fistula between the left circumflex coronary artery and coronary sinus (CS) for remote computed tomography (CT) imaging and transcatheter closure. This is the fifth published case report to describe this congenital anomaly and the first to discuss general anesthesia (GA) and the hemodynamic management considerations for the anesthesiologist.

**Keywords:** Congenital cardiac fistula, pediatric hemodynamic care, remote anesthesia, transcatheter cardiac fistula closure

## Introduction

Pediatric coronary artery fistulas (CAFs) are a rare congenital coronary anomaly with a known incidence of 0.1–0.2% of all children.<sup>[1,2]</sup> Approximately 40–55% of CAFs originate from the right coronary artery and drain into the right atrium (RA) or ventricle; origination from the left circumflex artery is extremely rare.<sup>[2,3]</sup> Most fistulas empty into the RA or pulmonary artery.<sup>[4]</sup> To the authors' knowledge, this is the first case report to discuss the anesthetic challenges for a toddler who presented with a left circumflex coronary artery to coronary sinus (CS) fistula for remote computed tomography (CT) imaging and transcatheter closure and the fifth to discuss this congenital anatomy entirely [Table 1].

## Case History

An 18-month-old, 8.69 kg female, presented for cardiac CT imaging for further characterization of a known left circumflex to CS fistula under general anesthesia (GA). The patient was born at 40 2/7 weeks of gestation via cesarean section for breech presentation weighing 2.68 kg with a notable II/VI systolic murmur auscultated at delivery. There were no other physical examination findings concerning for overt heart failure

including the absence of peripheral cyanosis or clubbing of the extremities, abnormal lung sounds, or hepatomegaly. An echocardiogram was performed on the second day of life and was notable for a large fistula connection between the left circumflex artery and CS (peak pressure gradient 72 mmHg/mean 52 mmHg) and associated with right ventricular dilation, moderate right ventricular hypertrophy (right ventricular systolic pressure [RVSP] 42.9 mmHg), and significant proximal left main coronary dilation (5.0 mm, Z score of 10.85). On her third day of life, her weight had decreased by 6.7% and she developed tachypnea with progressive difficulty breastfeeding and subsequent minimal urine output. A proBNP was drawn and elevated at 35,000 pg/mL. Due to echocardiographic, laboratory and physical exam findings, the patient was transferred to a tertiary care facility on her third day of life. She was able to gain weight appropriately after transitioning to bottle-feeding with no increased work of breathing, despite a mildly elevated respiratory rate of 32 breaths per minute. Therefore, immediate intervention was deferred given clinical improvement. She was discharged home on day eight of life. Furosemide therapy (1 mg/kg) was initiated at 6-weeks-old due to tachypnea with new fatigue during

**Beth A VanderWielen, Yuanxu J Dong<sup>1</sup>, Shelly B Borden<sup>2</sup>**

*Department of Anesthesiology, Gundersen Health System, La Crosse, <sup>1</sup>Department of Anesthesiology, American Family Children's Hospital, <sup>2</sup>Department of Anesthesiology, University of Wisconsin Hospital and Clinics, Madison, WI*

**Submitted:** 05-Sep-2019

**Accepted:** 14-Nov-2019

**Published:** 17-Jul-2020

### Address for correspondence:

*Dr. Beth A. VanderWielen, Gundersen Health System, 1900 South Avenue, Mail Stop H02-002, La Crosse, WI - 54601, US.*

*E-mail: bavander@gundersenhealth.org*

### Access this article online

**Website:** www.annals.in

**DOI:** 10.4103/aca.ACA\_127\_19

### Quick Response Code:



**How to cite this article:** VanderWielen BA, Dong YJ, Borden SB. Perioperative anesthetic management of an 18-month-old pediatric patient with a congenital coronary fistula between the left circumflex coronary artery and coronary sinus: Report of a rare case. *Ann Card Anaesth* 2020;23:347-50.

This is an open access journal, and articles are distributed under the terms of the Creative Commons Attribution-NonCommercial-ShareAlike 4.0 License, which allows others to remix, tweak, and build upon the work non-commercially, as long as appropriate credit is given and the new creations are licensed under the identical terms.

**For reprints contact:** reprints@medknow.com

**Table 1: Known left circumflex to coronary sinus fistula patients**

Publication	Age of patient	Patient presentation	Intervention
Li <i>et al.</i> , <sup>[3]</sup> 2011	6-hour-old	Tachypnea, murmur, X-ray with severe cardiomegaly and pulmonary congestion	Open surgical; median sternotomy, direct ligation of fistula off pump followed by cardiopulmonary bypass run for ASD patch repair
Perry <i>et al.</i> , <sup>[5]</sup> 1992	3-year-old	Murmur, otherwise asymptomatic	Transcatheter via gianturco coils (5 total)
	7-year-old	Murmur, otherwise asymptomatic	Transcatheter via gianturco coils (5 total)
	9-month-old	Murmur, otherwise asymptomatic	Transcatheter via double-umbrella closure device

feeding and findings of left atrial and ventricular dilation on follow-up echocardiography.

The patient was carefully monitored with serial electrocardiograms and echocardiograms. Serial chest X-rays were deferred because of radiation dose in light of the patient's age and the comparative high sensitivity and specificity of echocardiography in the assessment of her cardiac function. At 18-months of age, 8.69 kg, severe and progressive dilation of the left main coronary artery (9–10 mm) was found on follow-up echocardiography along with new trace aortic regurgitation, mild to moderate aortic root dilation (1.9 cm), and slightly decreased left ventricular function. There was no evidence of regional wall motion abnormalities. In consultation with pediatric interventional cardiology, the patient then presented for a cardiac CT under GA to further characterize the fistula anatomy in planning for surgical closure given the progressive echocardiographic findings. Her preoperative electrocardiogram revealed normal sinus rhythm with evidence of left ventricular hypertrophy and the absence of signs of ischemia. Standard ASA monitors were applied to the patient and a sevoflurane inhalation induction was performed followed by an uneventful placement of a size 1 laryngeal mask airway (LMA). An 8 cc/kg bolus of lactated ringers was given after successful intravenous (IV) placement to maintain the preload. One breath-hold lasting less than 10 sec was required for adequate imaging, which was achieved with a 20 mg propofol bolus in conjunction with a 15 mcg bolus of phenylephrine to maintain systemic vascular resistance. The patient promptly regained spontaneous respirations to avoid an increase in her pulmonary vascular resistance. She recovered uneventfully post anesthesia.

The cardiac CT revealed a large 4–5 mm fistula originating adjacent to the origin of the proximal dilated left circumflex artery (11 mm) and terminating at the dilated coronary sinus (11 mm) [Figure 1]. The patient was then referred to a tertiary pediatric hospital for transcatheter intervention. GA was induced via gentle inhalational induction after which an endotracheal tube was placed and controlled ventilation initiated. A 6 French sheath was then placed in the right femoral artery and vein by the interventional cardiology team through which femoral arterial blood pressure monitoring was initiated. Additional peripheral large-bore IV access was obtained. A 10 cc/kg lactated ringer bolus

was given to optimize her fluid status. Subsequently, the patient was heparinized to maintain an activated clotting time of greater than 200 sec in preparation for the deployment of an Amplatzer duct occluder. A 4 French pigtail catheter was placed in the ascending aorta for contrast deployment followed by the placement of a 100 cm guidewire into the left main coronary artery, traversing the fistula CS, RA and superior vena cava (SVC). A segment of the fistula was found narrowed to about 4.5 to 5 mm [Figure 2]. An additional venous catheter was then placed through the right femoral vein to snare the original wire in the SVC, creating an arterial venous rail. A 6 French wedge Amplatzer occlusion device was then placed into the right femoral vein and into the SVC, fed retrograde through the RA into the CS and deployed within the narrowed segment of the fistula [Figure 3]. Diminished flow through the fistula was achieved after device deployment. The patient tolerated the procedure well without evidence of cardiac ischemia, arrhythmias, or coronary artery entrapment. Transthoracic echocardiogram was performed the following day, which confirmed significantly sustained reduced flow through the fistula. She was placed on Plavix for 6-weeks postprocedure to decrease the risk of thrombotic sequela.

## Discussion

CAFs are a rare neonatal congenital malformation. They may be asymptomatic and close spontaneously or may present with serious pathology [Table 1]. Fistulas that terminate in low-pressure structures, such as the CS, can result in significant left-to-right-sided shunts because of differences in pressure gradients and increased compliance of the pulmonary circulation.<sup>[3]</sup>

Lesions can be corrected via a transcatheter or open surgical approach, depending on the size, location, and tortuosity of the lesion.<sup>[4,6]</sup> If left unrepaired, CAFs can enlarge over time and place the patient at risk for rupture or lead to severe hemodynamic, thrombotic, or ischemic consequences.<sup>[6]</sup> Unrepaired lesions may also pose an increased risk of endocarditis.<sup>[6]</sup> Postprocedure anticoagulation is often considered because of the risk of thrombus formation, although definitive guidelines are lacking. Transcatheter procedural complications can include migration and/or embolization of the closure device, myocardial ischemia, residual shunt, infection, recanalization, provocation of arrhythmias, and risks related to deep sedation or GA. An open surgical approach carries

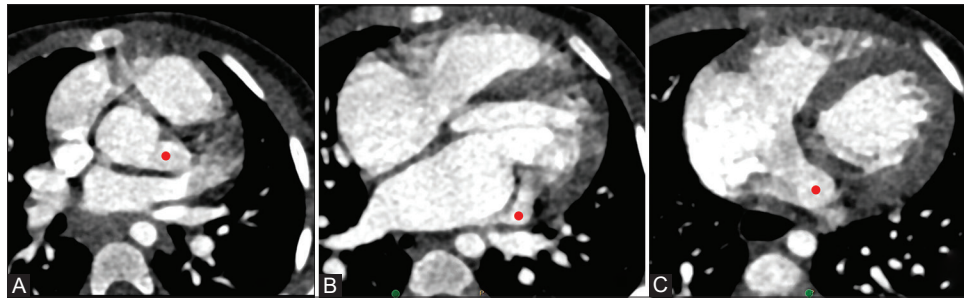


Figure 1: (Original Image) The red dot represents the proximal dilated left circumflex artery in panel A, the coronary fistula in panel B, and the dilated coronary sinus draining into the right atrium in panel C

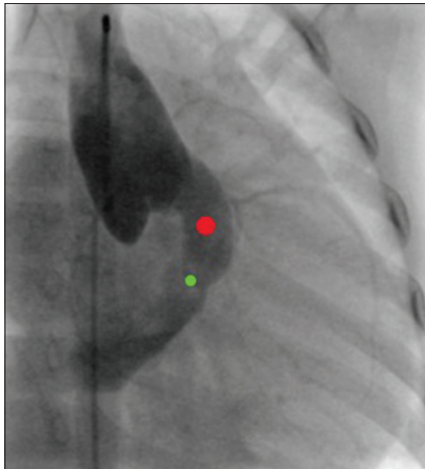


Figure 2: (Original Image) The green dot represents the narrowed segment of the fistula; red dot represents the dilated left coronary artery

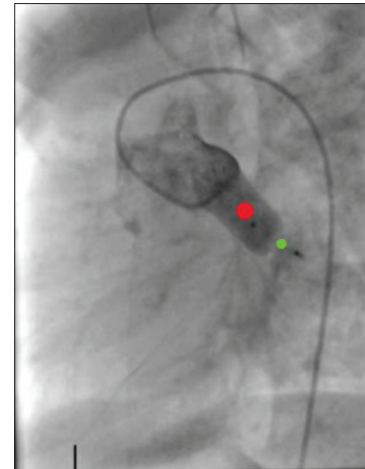


Figure 3: (Original Image) The green dot represents the occlusion device within the fistula; red dot represents the dilated left coronary artery

many of the same inherent cardiac ischemia and arrhythmia risks in addition to higher expected morbidity and mortality from cardiopulmonary bypass along with significantly longer expected surgical recovery times, higher bleeding and infection risks, and the risks of a prolonged general anesthetic.<sup>[7]</sup>

This young child demonstrated signs and symptoms of pulmonary overcirculation which were corroborated on echocardiography, CT imaging, and hemodynamic measurements via cardiac catheterization. In the cases of similar pathology that have been published, none of these patients received CT imaging guidance prior to surgical correction.<sup>[3]</sup> While coronary angiography is the gold standard for coronary artery imaging, it can be limited in its ability to measure abnormal tortuous blood vessels in one section or view.<sup>[8]</sup> Coronary angiography is also invasive and may not be readily available without a pediatric interventional cardiology service. Newer advances in ultrafast CT imaging are helpful in these circumstances as in the case of this patient.

Approximately 60% of CAFs are associated with additional congenital cardiac defects, which are pertinent to recognize in the preoperative evaluation, as it may alter hemodynamic goals for an individual patient<sup>[6,9]</sup> For example, in patients with a patent ductus

arteriosus (PDA), additional left-to-right shunting through a fistula that terminates in the right side of the heart can cause lower diastolic pressures, which may increase the risk of cardiac ischemia.<sup>[3]</sup> The fear for patients with CAFs immediately after birth is rapidly progressive heart failure secondary to volume overload due to the sudden decrease in pulmonary vascular resistance, subsequent pulmonary overcirculation and precipitation of myocardial ischemia.<sup>[6,10]</sup> This can be life-threatening and therefore, requires a high level of suspicion from neonatologists and anesthesiologists who may be called to provide care for urgent imaging and/or subsequent interventional procedures.

Anesthetic considerations for preoperative imaging studies and transcatheter closure procedures include adequate preload to maintain overall cardiac output ventilatory support via either spontaneous or mechanical ventilation to optimize pulmonary vascular resistance optimal heart rate control to maintain cardiac output and minimizing the risk of cardiac ischemia and vasoactive medications for optimal inotropy, afterload, and contractility.

## Conclusion

In conclusion, pediatric CAFs are extremely rare, especially originating from the left circumflex artery and terminating

in the CS. Ultrafast cardiac CT can be an alternative diagnostic imaging modality for an accurate diagnosis. Anesthetic considerations for preoperative anesthetic imaging and transcatheter closure were reviewed.

#### **Acknowledgment**

We would like to acknowledge the collaborate effort between Gundersen Health System and the University of Wisconsin Hospital and Clinics in partnership with American Family Children's Hospital in providing exceptional care for this patient.

#### **Declaration of patient consent**

The authors certify that they have obtained all appropriate patient consent forms for imaging and other clinical information to be reported in the journal from the parents. Given the age of the patient, the parents also understand that the child's name and initials will not be published and due efforts are made to conceal their identity, but anonymity cannot be guaranteed.

#### **Financial support and sponsorship**

None.

#### **Conflicts of interest**

There are no conflicts of interest.

#### **References**

1. Krasemann T, van Beynum I, Frohn-Mulder I, Dalinghaus M. Endocarditis of a congenital coronary fistula in a child. *Cardiol Young* 2018;28:334-7.
2. Taverne A, de Jong P, Witsenburg M, Bogers A. Surgical correction of a coronary fistula between the left main coronary artery and the coronary sinus in a neonate. *Interact Cardiovasc Thorac Surg* 2016;23:498-500.
3. Li J, Sakazaki H, Tsukuda K, Fujiwara K. A neonate of coronary artery fistula from left circumflex to coronary sinus. *Pediatr Cardiol* 2011;32:1212-5.
4. Ali M, Kassem K, Osei K, Effat M. Coronary artery fistulae. *J Thromb Thrombolysis* 2019;48:345-51.
5. Perry S, Rome J, Keane J, Baim D, Lock J. Transcatheter closure of coronary artery fistulas. *J Am Coll Cardiology* 1992;20:205-9.
6. Christmann M, Hoop R, Dave H, Quandt D, Knirsch W, Kretschmar O. Closure of coronary artery fistula in childhood: Treatment techniques and long-term follow-up. *Clin Res Cardiol* 2017;106:211-8.
7. Harikrishnan S, Bimal F, Ajithkumar V, Bhat A, Krishnamoorthy K, Sivasubramonian S, *et al.* Percutaneous treatment of congenital coronary arteriovenous fistulas. *J Interv Cardiol* 2011;24:208-15.
8. Gowda R, Vasavada B, Khan I. Coronary artery fistulas: Clinical and therapeutic considerations. *Int J Cardiol* 2006;107:7-10.
9. Welisch E, Norozi K, Burrill L, Rauch R. Small coronary artery fistulae in childhood: A 6-year experience of 31 cases in a tertiary paediatric cardiac centre. *Cardiol Young* 2016;26:738-42.
10. Shimada S, Taketazu M, Sato M, Nii M, Shirai M. Heart failure and coronary ischemia in a neonate with right coronary artery fistula. *Pediatr Int* 2019;61:417-8.