

Dacryoendoscopy for dacryocystitis management in a dog: A case report

Yeon-Hyung Choi¹  | Je-Hwan Jang²  | Joon-Young Kim² 

¹Veterinary Medical Teaching Hospital, Konkuk University, Seoul, Korea

²Department of Veterinary Ophthalmology, College of Veterinary Medicine, Konkuk University, Seoul, Korea

Correspondence

Joon-Young Kim, Department of Veterinary Ophthalmology, College of Veterinary Medicine, Konkuk University, 120 Neungdong-ro, Gwangjin-gu, Seoul, 05029, Korea.

Abstract

A castrated, mixed-breed, 10-year-old male dog developed a skin fistula from a ruptured periorbital swelling on the right eye; the patient was successfully treated with dacryoendoscope-guided cannulation using a nasolacrimal tube. On presentation, computed tomography with concurrent dacryocystography (CT-DCG) revealed obstruction of the right nasolacrimal duct and abnormal flow of contrast agents towards the root of tooth 109 at the right maxillary bone; however, the origin of the fistula remained unclear on CT-DCG. Dacryoendoscopy was used to confirm the physical association between the fistula and the nasolacrimal duct; the fistula end was found to be near the right upper gum mucosa around tooth 107. CT-DCG and dacryoendoscopy revealed that the periorbital swelling occurred owing to an infection or inflammation of the accessory nasolacrimal duct. The fistula end was connected to the oral cavity through a nasolacrimal tube installed in the oral mucosa. The tube was removed a week later, and the clinical symptoms completely resolved.

KEYWORDS

Dacryocystitis, dacryocystography, dacryoendoscopy, dog, fistula

1 | INTRODUCTION

Dacryocystitis is an inflammation of the nasolacrimal drainage system (Grahn & Sandmeyer, 2013). It may occur as a result of acute or chronic obstruction of the nasolacrimal drainage system. Clinical signs that may be associated with dacryocystitis are epiphora, mild conjunctivitis, mucopurulent exudate at the medial canthus, pain at the medial canthus, recurrent unilateral conjunctivitis with temporary response to medical therapy and occasional abscessation of the lacrimal sac (Lussier & Carrier, 2004). If left untreated, the lacrimal sac may rupture, usually anteriorly through the overlying skin (Mills & Meyer, 2006). Present treatment options are in short supply, and despite medical management controlling secondary infection, it is nearly consistently unsuccessful in enduringly clearing

the obstruction or associated signs (Strom et al., 2018). Therefore, identifying and treating the underlying cause of obstruction via cannulation, surgical foreign body removal, or surgical rerouting of the nasolacrimal apparatus are typically required (Grahn & Sandmeyer, 2013).

Because direct examination of the orbit is limited due to its anatomic characteristics, a variety of imaging techniques has been used to diagnose orbital disease, including radiography, ultrasonography, computed tomography (CT) and magnetic resonance imaging (MRI) (Boland et al., 2013). Imaging studies used to evaluate the nasolacrimal system include ultrasonography, dacryoscintigraphy, dacryocystorhinography (DCRG), CT and MRI (Giuliano et al., 2006). Small drainage structures, such as the lacrimal canaliculi, are well delineated on computed tomography with concurrent dacryocystography

This is an open access article under the terms of the Creative Commons Attribution-NonCommercial-NoDerivs License, which permits use and distribution in any medium, provided the original work is properly cited, the use is non-commercial and no modifications or adaptations are made.

© 2020 The Authors *Veterinary Medicine and Science* Published by John Wiley & Sons Ltd

(CT-DCG), and the relationship between the nasolacrimal duct system and surrounding soft tissue can be seen clearly (Rached et al., 2011). However, to investigate the internal change in the nasolacrimal duct, more accurate information may be obtained if the endoscope can be inserted into the duct. (Heichel et al., 2017).

Dacryocystoscopy enables clear and direct observation of the lacrimal passage in a way similar to probing. The procedure does not require invasive manipulation such as incision of the skin or nasal mucosa. Furthermore, a nasolacrimal duct obstruction can also be treated simultaneously with the tip of a dacryocystoscope (Yamada et al., 2009).

The purpose of this case report was to present an account of diagnosis and treatment tool of dacryocystitis in the eyes of dogs using dacryocystoscopy.

2 | CASE REPORT

A castrated, mixed-breed, 10-year-old male dog was brought to the veterinary ophthalmologist with an 8-month history of moderate epiphora and a periorbital swelling on the right eye. The periorbital swelling had ruptured 2 months previously, and pus was continuously coming out of the skin near the medial canthus of the right eye.

The patient was otherwise healthy and had no history of ocular disease. After repetitive antibiotic treatments in the local animal hospital had failed to resolve the clinical signs, the patient was referred to a veterinary ophthalmologist. A complete ophthalmic examination revealed normal findings in both eyes except for periorbital mild swelling and pus drainage of the right eye (Figure 1). The menace response was present in both eyes, and all reflexes were normal. Intraocular pressure (IOP), measured using a Tono-Pen (Reichert, Depew, NY, USA), was 15 mmHg in both eyes. Moderate medial canthal melanosis was found in the conjunctiva of both eyes. No significant abnormalities were detected on oral examination. Complete blood count and serum biochemical analysis results

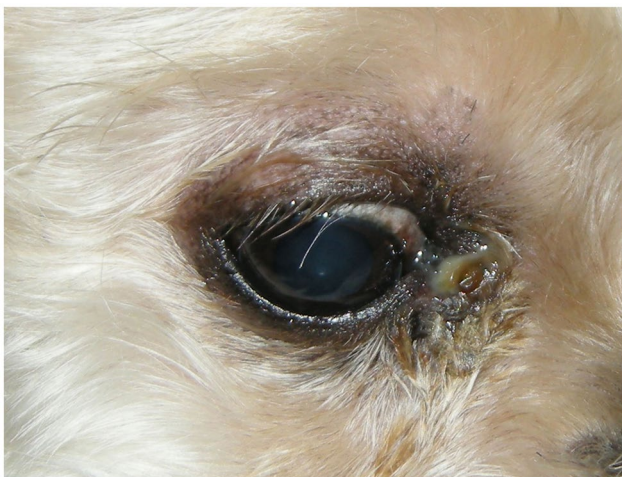

FIGURE 1 Periorbital swelling and pus drainage from the skin near the medial canthus of the right eye

were normal. A scab that had formed over the purulent discharge was softly rinsed with 0.9% normal saline (sodium chloride injection 0.9%; Dai Han Pharm. Co., Ltd., Seoul, Korea). When the scab was removed, a skin fistula was revealed. A 24-gauge IV catheter tip (BD Angiocath Plus; Becton Dickinson Korea Co., Ltd., Seoul, Korea) attached to a 3-ml syringe (Sofjec 3 ml; Hwajin Medical Co., Ltd., Cheonan, Korea) containing normal saline was inserted into the fistula to confirm an opening to the nasolacrimal duct system or oral cavity. The fistula was flushed when the end of the tip met resistance. The saline flowed backward, and no leakage was found in the oral cavity. Considering the location of the fistula, a connection between the fistula and nasolacrimal drainage system needed to be confirmed. As repeated antibiotic treatments failed to resolve the patient's symptoms, CT-DCG along with diagnostic dacryocystoscopy was recommended for a definitive diagnosis. CT-DCG of both nasolacrimal ducts was performed under general anesthesia. Anesthesia induction was performed with 6 mg/kg of intravenous propofol (Provive 1%®; MyungMoon Pharm. Co., Ltd., Seoul, Korea). Maintenance of anaesthesia was achieved using isoflurane (Isoflurane®; Choongwae Co., Ltd., Seoul, Korea). Intraoperative fluid therapy was administered using 0.9% normal saline. Multiple 3-mm contiguous axial CT images captured with bone and soft tissue algorithms were evaluated before and after the administration of contrast (Omnipaque iohexol; GE Healthcare Ireland, Cork, Ireland) into each nasolacrimal duct and the fistula. The administration of contrast agent was conducted by inserting a 24-gauge catheter tip attached to a 3-mL syringe containing 1 ml of contrast agent. Pre-contrast images revealed gas attenuation around the fistula at the level of tooth 108 (Figure 2a). This gas attenuation could lead to the suspicion of the presence of a fistula in the oral cavity and bacterial infection as a result of this fistula. The nasolacrimal ducts underwent contrast imaging first. Post-contrast images of the left nasolacrimal duct showed complete patency through the nasal mucosa, while the contrast agent was not found in the mucous membrane of the right nasal cavity (Figure 2b). However, a connection with the fistula could not be found.

After that, the fistula was evaluated in the same manner. It was confirmed that the contrast agent injected into the fistula remained in the orbit, and some of the contrast agent flowed toward the root of tooth 109 (Figure 2c). However, we could not find any signs of nasolacrimal duct involvement.

Both lacrimal puncta and the fistula were irrigated after CT-DCG using a mixed solution of 10 ml of normal saline. After CT imaging, a weeks' worth of neomycin, polymyxin B, and dexamethasone 0.1% eye drops (Maxitrol; Novartis, Puurs, Belgium) was prescribed.

As CT-DCG showed evidence of right nasolacrimal duct obstruction, we hypothesized that the nasolacrimal duct inflammation may have led to a duct rupture and formation of a skin fistula. Because of insufficient evidence on CT-DCG, we decided to perform surgical cannulation with nasolacrimal tube insertion into the obstructed area using dacryocystoscopy. The purpose of surgery was to recover patency of the obstructed area and resolve the inflammation by direct irrigation of the nasolacrimal duct.

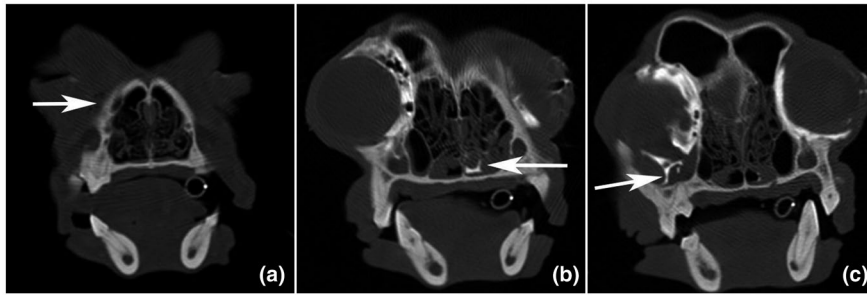


FIGURE 2 Computed tomography with concurrent dacryocystography (CT-DCG). Pre-contrast images revealed gas attenuation (arrow) around the fistula at the level of tooth 108 (a). Post-contrast images of the left nasolacrimal duct showed complete patency through the nasal mucosa (arrow), while the contrast agent was not found in the mucous membrane of the right nasal cavity (b). Post-contrast images showed that the contrast agent was not discharged through the nasolacrimal duct; however, the contrast agent remained in the orbit, and some of the contrast agent flowed toward the root of tooth 109 (arrow) (c)

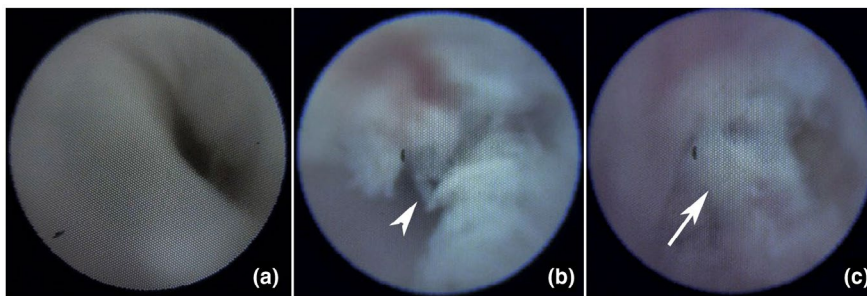


FIGURE 3 Dacryoendoscopy images. There was no debris and the wall of duct was smooth in the normal nasolacrimal duct (a). Patency was confirmed, although much debris (arrowhead) was detected until the upper part of the right nasolacrimal duct (b). The dacryoendoscope met resistance (arrow) in the middle part when advanced through the right lower lacrimal punctum (c)

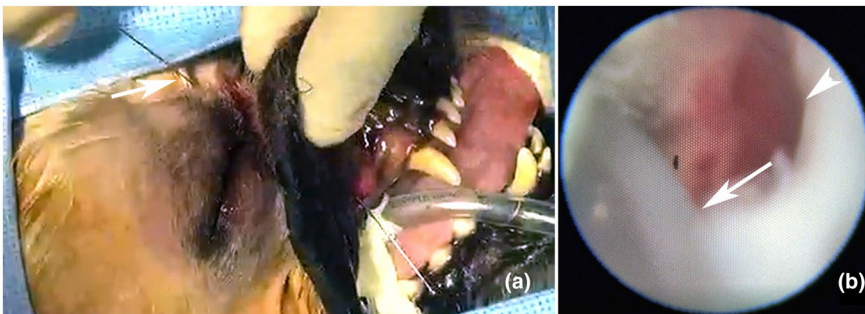


FIGURE 4 Nasolacrimal tube installation. A nasolacrimal tube (arrow) was installed by drilling a hole in the oral mucosa (a). Nasolacrimal tube installation was confirmed by dacryoendoscopy (arrow); the lower nasolacrimal duct was completely obstructed (arrowhead) (b)

The operation was performed a week later under general anaesthesia. A total of 30 mg/kg of intravenous cefazolin (Safdin®; Daehan New Pharm Co., Ltd., Seoul, Korea) was administered as a prophylactic antibiotic before propofol was used to induce anaesthesia. Maintenance of anaesthesia and intraoperative fluid therapy were achieved as routine procedures. A diagnostic dacryoendoscopy system (light source, KESS-100EN, GSMT Co., Ltd., Gwangju, Korea; lacrimal endoscope, KESS-FC070100030-D90, GSMT Co., Ltd., Gwangju, Korea) was used. During the dacryoendoscopy, the lacrimal puncta and fistula were dilated continuously with 0.9% normal saline for navigation. After dilatation of the right upper lacrimal punctum with a nettleship lacrimal dilator, the endoscope was inserted perpendicularly over the margin of the eyelid into the vertical portion of the canaliculus. There was no debris and the wall of

duct was smooth in the normal dacryoendoscopic image (Figure 3a). The horizontal portion of the canaliculus was visualized through further insertion of the endoscope; patency was confirmed, although much debris was detected until the upper part of the right nasolacrimal duct (Figure 3b). However, the endoscope met resistance in the middle part and could not be advanced any further, as debris blocked the duct completely (Figure 3c). So, we could diagnose the dacryocystitis.

The fistula was then checked to demonstrate the connectivity to the nasolacrimal duct. The fistula was associated with the right upper gum mucosa near tooth 107 in the oral cavity. A nasolacrimal tube was installed by drilling a hole in the oral mucosa (Figure 4a). The nasolacrimal tube installation was confirmed by dacryoendoscopy (Figure 4b) which entered from the lacrimal punctum. The skin

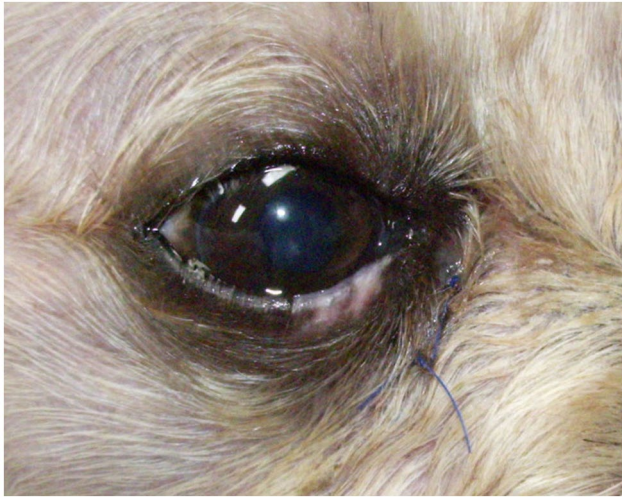

FIGURE 5 Photograph taken 10 days after the operation and right before suture removal. Note the improvement of clinical signs

fistula was sutured with 6-0 Dafilon® (polyamide; B. Braun Surgical SA, Barcelona, Spain).

After the operation, neomycin, polymyxin B and dexamethasone 0.1% eye drops (Maxitrol; Novartis, Puurs, Belgium) were applied

in the right eye every 6 hr for a week. Oxytetracycline and polymyxin B ophthalmic ointment (Terramycin ophthalmic ointment; Pfizer, Jakarta, Indonesia) was applied to the sutured fistula region every 12 hr for a week. Systemic antibiotics (5.5 mg/kg of clindamycin [Fullgram cap 150 mg; Samjin Pharmaceutical Co., Ltd., Seoul, Korea] and 12.5 mg/kg of ciprofloxacin [Ciproby tab 250 mg; Bayer Korea Ltd., Seoul, Korea]) were administered every 12 hr for a week. Systemic prednisolone at 0.8 mg/kg (Solondo tab 5 mg; Yuhan Co., Ltd., Seoul, Korea) was administered every 12 hr for a week with an additional 5 days at a reduced dose. The nasolacrimal tube was removed a week after surgery and the patient's owner reported resolution of the epiphora and purulent discharge. The fistula was fully healed 10 days after the surgery (Figure 5), and no recurrence of the clinical signs was reported within a 1-year follow-up period.

All treatments were conducted as summarized in Figure 6.

3 | DISCUSSION

Indications for imaging of the nasolacrimal system in animals include chronic epiphora; orbital trauma; chronic, nonresponsive conjunctivitis; and proptosis of the third eyelid (Johnston & Feeney, 1980). In

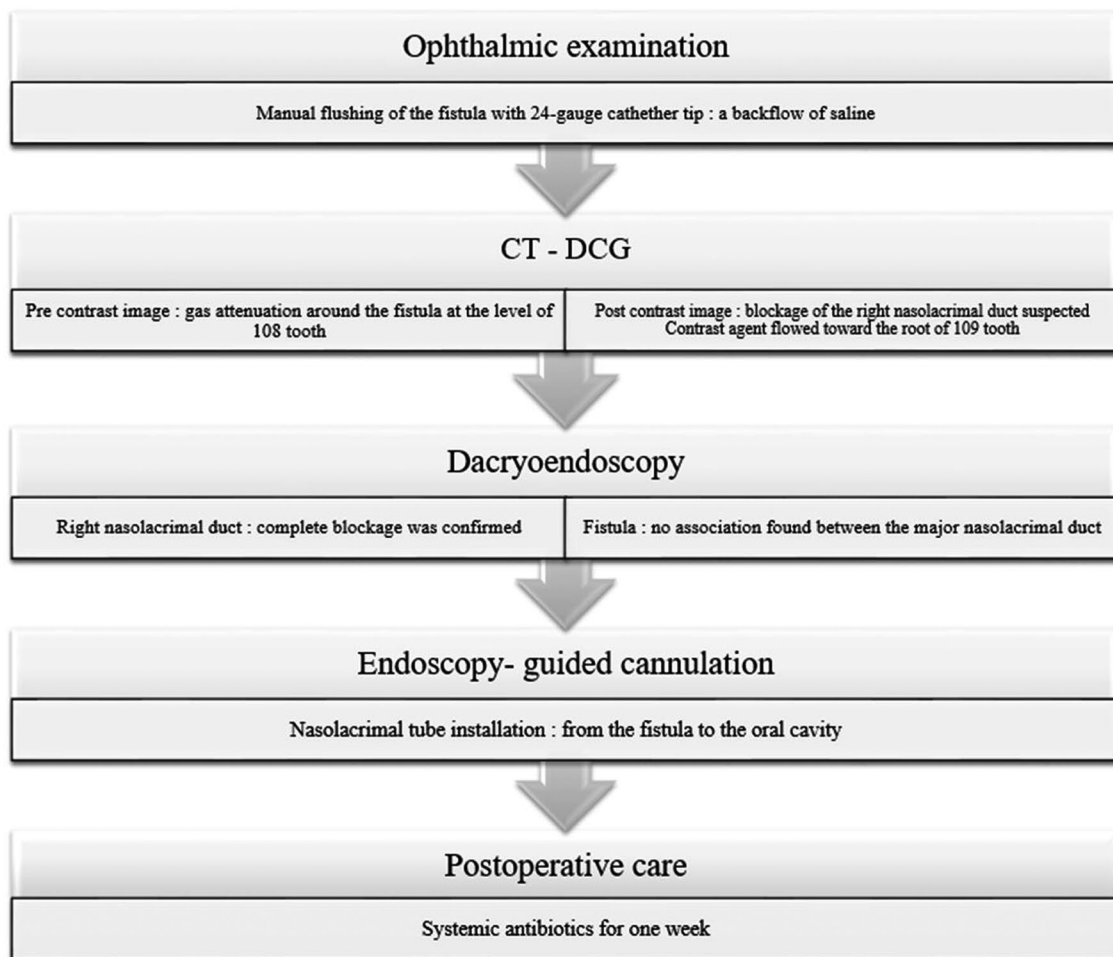


FIGURE 6 Summary of all the diagnostic and treatment procedures used in this study

this study, the main presenting sign was a swelling and ruptured skin ventromedial to the right eye. Generally, such swellings are relatively painless and cause no irritation or only minor irritation caused by occasional rubbing. The presence or absence of epiphora is variable, and mucopurulent ocular discharge is found predominantly in cases of dacryocystitis (Featherstone & Llabres, 2003). In dogs and cats, the nasolacrimal drainage system is composed of paired nasolacrimal puncta, which are located at the medial aspect of the superior and inferior eyelids and open into the nasolacrimal duct (Murphy & Gutierrez, 2018). The duct passes rostrally through the lacrimal and maxillary bones to empty via an ostium on the ventrolateral floor of the nasal vestibule (Murphy & Gutierrez, 2018). Approximately 40% of dogs have an additional connection of the duct with the ventral nasal meatus at the level of the canine tooth root (Binder & Herring, 2010). It is likely that the periorbital swelling in the dog discussed here occurred due to an infection or inflammation of the accessory nasolacrimal duct.

In general, the accessory nasolacrimal duct opens toward the canine tooth root, as mentioned, but in this case, the tube was installed near tooth 107 through the endoscope. This might be due to the incomplete structure of the accessory nasolacrimal opening, which is not often fully patent.

When the skin fistula was flushed with saline to check the connection with the oral cavity, no leakage or swelling was found. It is possible that leaking and swelling did not appear due to an insufficient amount of saline being used or weak syringe pressure when the fistula was flushed. This possibility could explain the post-contrast CT images, which showed leakage of the contrast medium near the root of tooth 109, which was not found at the level of tooth 107. Further studies are needed to determine how many cases of dacryocystitis are associated with issues of accessory nasolacrimal duct opening, which are often found in brachycephalic dogs and cats.

This study suggests that dacryoendoscopy can be used to effectively and accurately detect the origin of a periorbital fistula when CT-DCG cannot provide a definitive diagnosis for appropriate treatment. Recently, the veterinary community has attempted to use dacryoendoscopy to visualize nasolacrimal diseases and make more accurate diagnoses. In this case, dacryoendoscopy was useful for identifying the patency of the nasolacrimal duct and skin fistula, and these findings were not consistent with CT-DCG findings. Although CT-DCG has many advantages for the investigation of apparent nasolacrimal disease, a definitive diagnosis can only be achieved with the aid of dacryoendoscopy in cases in which CT-DCG findings are insufficient. The confirmation of an anatomic connection with the nasolacrimal duct, prior to and during surgery, would lead to prompt and accurate diagnosis and treatment.

ETHICS STATEMENT

The authors confirm that the ethical policies of the journal, as noted on the journal's author guidelines page, have been adhered to and that no ethical approval was required for this particular case report.

CONFLICTS OF INTEREST

The authors have no competing interests to declare.

AUTHOR CONTRIBUTION

Yeon-Hyung Choi: Project administration; Writing-original draft. Je-Hwan Jang: Project administration. Joon Young Kim: Project administration; Supervision; Writing-review & editing.

FUNDING INFORMATION

The currently described clinical case is not funded by any project grant.

PEER REVIEW

The peer review history for this article is available at <https://publons.com/publon/10.1002/vms3.410>.

ORCID

Yeon-Hyung Choi  <https://orcid.org/0000-0003-4984-7037>

Je-Hwan Jang  <https://orcid.org/0000-0002-0206-2921>

Joon-Young Kim  <https://orcid.org/0000-0002-0608-6269>

REFERENCES

- Binder, D. R., & Herring, I. P. (2010). Evaluation of nasolacrimal fluorescein transit time in ophthalmically normal dogs and nonbrachycephalic cats. *American Journal of Veterinary Research*, 71(5), 570–574. <https://doi.org/10.2460/ajvr.71.5.570>
- Boland, L., Gomes, E., Payen, G., Bouvy, B., & Poncet, C. (2013). Zygomatic salivary gland diseases in the dog: Three cases diagnosed by MRI. *Journal of the American Animal Hospital Association*, 49(5), 333–337. <https://doi.org/10.5326/JAAHA-MS-5882>
- Featherstone, H., & Llabres, D. F. (2003). Maxillary bone epithelial cyst in a dog. *The Journal of Small Animal Practice*, 44(12), 541–545. <https://doi.org/10.1111/j.1748-5827.2003.tb00118.x>
- Giuliano, E. A., Pope, E. R., Champagne, E. S., & Moore, C. P. (2006). Dacryocystomaxillostomy for chronic dacryocystitis in a dog. *Veterinary Ophthalmology*, 9(2), 89–94. <https://doi.org/10.1111/j.1463-5224.2006.00443.x>
- Grahn, B. H., & Sandmeyer, L. S. (2013). Diseases and surgery of the canine nasolacrimal system. In K. N. Gelatt, B. Gilger, & T. Kern (Eds.), *Veterinary Ophthalmology* (5th ed., pp. 894–944). Wiley.
- Heichel, J., Struck, H. G., Fiorentzis, M., Hammer, T., & Bredehorn-Mayr, T. (2017). A Case Series of Dacryoendoscopy in Childhood: A Diagnostic and Therapeutic Alternative for Complex Congenital Nasolacrimal Duct Obstruction Even in the First Year of Life. *Advances in Therapy*, 34(5), 1221–1232. <https://doi.org/10.1007/s12325-017-0517-8>
- Johnston, G. R., & Feeney, D. A. (1980). Radiology in ophthalmic diagnosis. *Veterinary Clinics of North America: Small Animal Practice*, 10(2), 317–337. [https://doi.org/10.1016/s0195-5616\(80\)50032-x](https://doi.org/10.1016/s0195-5616(80)50032-x)
- Lussier, B., & Carrier, M. (2004). Surgical treatment of recurrent dacryocystitis secondary to cystic dilatation of the nasolacrimal duct in a dog. *Journal of the American Animal Hospital Association*, 40(3), 216–219. <https://doi.org/10.5326/0400216>
- Mills, D. M., & Meyer, D. R. (2006). Acquired nasolacrimal duct obstruction. *Otolaryngologic Clinics of North America*, 39(5), 979–999. <https://doi.org/10.1016/j.otc.2006.07.002>
- Murphy, C. J., & Gutierrez, J. C. (2018). The eye. In J. W. Hermanson, H. E. Evans, & A. Lahunta (Eds.), *Miller's anatomy of the dog* (5th ed., pp. 858–911). Elsevier.

- Rached, P. A., Canola, J. C., Schlüter, C., Laus, J. L., Oechtering, G., de Almeida, D. E., & Ludewig, E. (2011). Computed tomographic-dacryocystography (CT-DCG) of the normal canine nasolacrimal drainage system with three-dimensional reconstruction. *Veterinary Ophthalmology*, 14(3), 174–179. <https://doi.org/10.1111/j.1463-5224.2010.00861.x>
- Strom, A. R., Culp, W. T. N., Leonard, B. C., Dear, J. D., Wisner, E. R., Johnson, L. R., & Maggs, D. J. (2018). A multidisciplinary, minimally invasive approach combining lacrimoscopy and fluoroscopically guided stenting for management of nasolacrimal apparatus obstruction in dogs. *Journal of the American Veterinary Medical Association*, 252(12), 1527–1537. <https://doi.org/10.2460/javma.252.12.1527>
- Yamada, T., Katori, N., Takahashi, Y., & Kashima, T. (2009). Dacryoendoscopic detection for origin of congenital lacrimal sac fistula. *Eye (London, England)*, 23(9), 1871. <https://doi.org/10.1038/eye.2008.368>

How to cite this article: Choi Y-H, Jang J-H, Kim J-Y. Dacryoendoscopy for dacryocystitis management in a dog: A case report. *Vet Med Sci*. 2021;7:674–679. <https://doi.org/10.1002/vms3.410>