

Half-tied Stay Suture Technique for Cerebrovascular End-to-side Anastomosis: A Technique to Expand the View of the Hidden Ostium

Satoru SHIMIZU,¹ Shigeyuki OSAWA,¹ Hiroki KURODA,¹ Hiroyuki KOIZUMI,² Takahiro MOCHIZUKI,¹ and Toshihiro KUMABE²

¹*Department of Neurosurgery, Yokohama Brain and Spine Center, Yokohama, Kanagawa, Japan;*

²*Department of Neurosurgery, Kitasato University School of Medicine, Sagamihara, Kanagawa, Japan*

Abstract

In cerebrovascular end-to-side anastomosis, thick, hard donor arteries overlying thin recipient arteries impair the view of the ostium, and may result in occlusion of the anastomosis. To improve the intraoperative view, we modified the stay sutures. After performing standard recipient arteriotomy and placing the first stay suture, we half-tied the second stay suture to leave a loop: half-tied stay suture (HSS). The thread of the HSS was secured with a clip to avoid slippage. For suturing side A, the clip pulling on the HSS was gently moved to the opposite side of side A, i.e. to side B, and the donor artery was revolved by several degrees to side B; the first stay suture was used as the fulcrum. Under the expanded view of the ostium, untied interrupted sutures were placed on side A. Then the donor vessel was revolved to the opposite side and side B was sutured in the same manner. At last, the HSS and all other sutures were tied fully. Our HSS method was used in three adults who underwent superficial temporal- to middle cerebral artery anastomosis despite anticipated poor visibility of the ostium. Compared with the conventional method, the view of the ostium was expanded with less manipulation of the vessel walls. There were no complications, and the anastomosis remained patent in all three patients. This simple modification of the stay sutures reduces the risk of anastomotic occlusion due to iatrogenic vascular damage by excessive manipulation under a restricted view.

Key words: cerebrovascular anastomosis, ostium, stay suture, visualization

Introduction

In microvascular anastomosis, iatrogenic vessel wall damage due to excessive and imprecise manipulation, e.g. touching the intima, pinching the full thickness of the vessel wall, multiple suturing attempts, and prolonged clamping, may result in occlusion of the ostium.¹⁾ Such problems can arise during the performance of cerebrovascular end-to-side anastomosis when the donor arteries overlying thin recipient arteries are thick and hard, because of the poor visibility of the ostium. This issue is not resolved by current techniques to improve the intraoperative view, e.g. staining the vessels with methylrosaniline

chloride,²⁾ elliptical cutting out of the recipient wall,³⁾ temporary intraluminal placement of silicone rubber stents,⁴⁾ and continuous suction of the cerebrospinal fluid and epidural blood.^{5,6)} Therefore, we developed and applied our modified stay suture method.

Surgical Technique

After staining the vessels with methylrosaniline chloride,²⁾ and placing a linear recipient arteriotomy,⁷⁾ the first stay suture is placed at the most distal site using a 10-0 nylon thread. The second stay suture perforating the wall of the donor- and recipient artery is tied halfway to leave a loop; this produces a half-tied stay suture (HSS). As the diameter of the loop and of the donor artery is approximately the same, the loop allows minimal but sufficient mobilization of the donor artery for the performance of the next maneuver, and avoids excessive mobilization of the

Received November 6, 2018; Accepted March 25, 2019

Copyright© 2019 by The Japan Neurosurgical Society
This work is licensed under a Creative Commons Attribution-NonCommercial-NoDerivatives International License.

donor artery that may damage the recipient artery at the first stay suture. The longish thread of the HSS is secured with an aneurysm clip (Fig. 1A). For suturing side A, the clip pulling on the HSS is gently moved to the opposite side of side A, i.e. side B, and the donor artery is revolved by several degrees to side B (Fig. 1B). In this process, the first stay suture acts as a fulcrum and the view of the ostia of both arteries is expanded. Three or four interrupted sutures are placed on side A with minimal manipulation of the vessels. By referring to the two stay sutures, additional sutures are placed at even intervals. This can be somewhat difficult because the length of the wall of the donor artery supported by the HSS may differ from that of the recipient vessel. The sutures are then cut without tying a knot. Next, the sutures on side A are arranged to not protrude into the ostium, and the donor vessel is revolved to the opposite side for suturing side B (Fig. 1C). After its suturing and cutting the sutures, the anatomically correct placement of each suture

is confirmed. After removing the clip from the HSS by cutting the ends of the threads, the knot is tied as usual and the sutures on both sides are tied consecutively (Fig. 1D).

Since its introduction at our institution in 2013, we used our HSS method in 3 of 19 patients (16%) who underwent superficial temporal- to middle cerebral artery anastomosis. They ranged in age from 56 to 83 years (mean 67.7 years). Their diagnosis was cerebral ischemia due to atherosclerotic stenosis of the middle cerebral artery, atherosclerotic occlusion of the internal carotid artery, and Moyamoya disease. Intraoperative findings led us to suspect poor visibility of the ostium because the diameter of the recipient arteries (<1 mm) and of the thick donor arteries was mismatched. All procedures were performed by the same surgeon. In all patients, the application of our HSS- rather than the conventional method yielded an expanded view of the ostia of both the donor- and recipient arteries (Fig. 2). Pulling of the vessel walls to view the

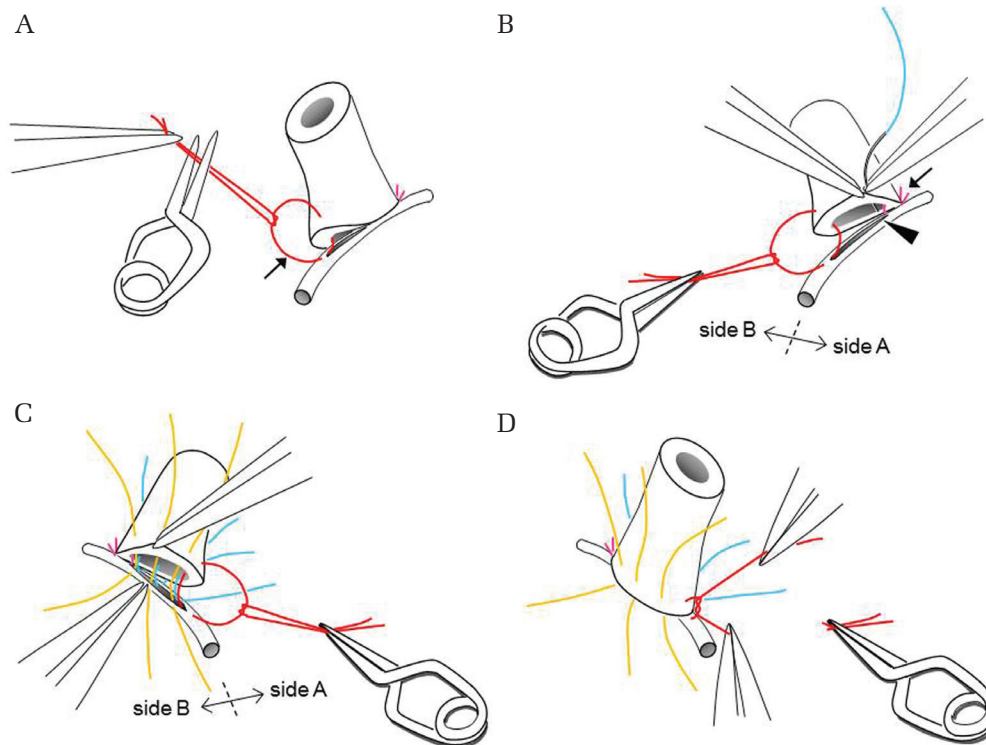


Fig. 1 Steps for placing modified stay sutures to expand the view of the hidden ostium. **A:** After conventional arteriotomy and placement of the first stay suture, the second stay suture is half-tied to leave a loop (*arrow*). The ends of the half-tied stay suture (HSS) are secured with a clip. **B:** To suture side A, the clip pulling on the HSS is gently moved to the opposite side of side A, i.e. side B, and the donor artery is revolved. The first stay suture (*arrowhead*) acts as a fulcrum. All vessel wall edges are visualized and the ostium beside the first stay suture (*arrowhead*), the most frequent site of incorrect suturing of the contralateral wall, is clearly visible with minimal pulling. Interrupted sutures are placed on side A, and then cut without tying a knot. **C:** The donor artery is revolved to the opposite side and interrupted sutures are placed on side B. **D:** After removing the clip from the HSS, the knot is tied as usual and the sutures on both sides are tied consecutively.

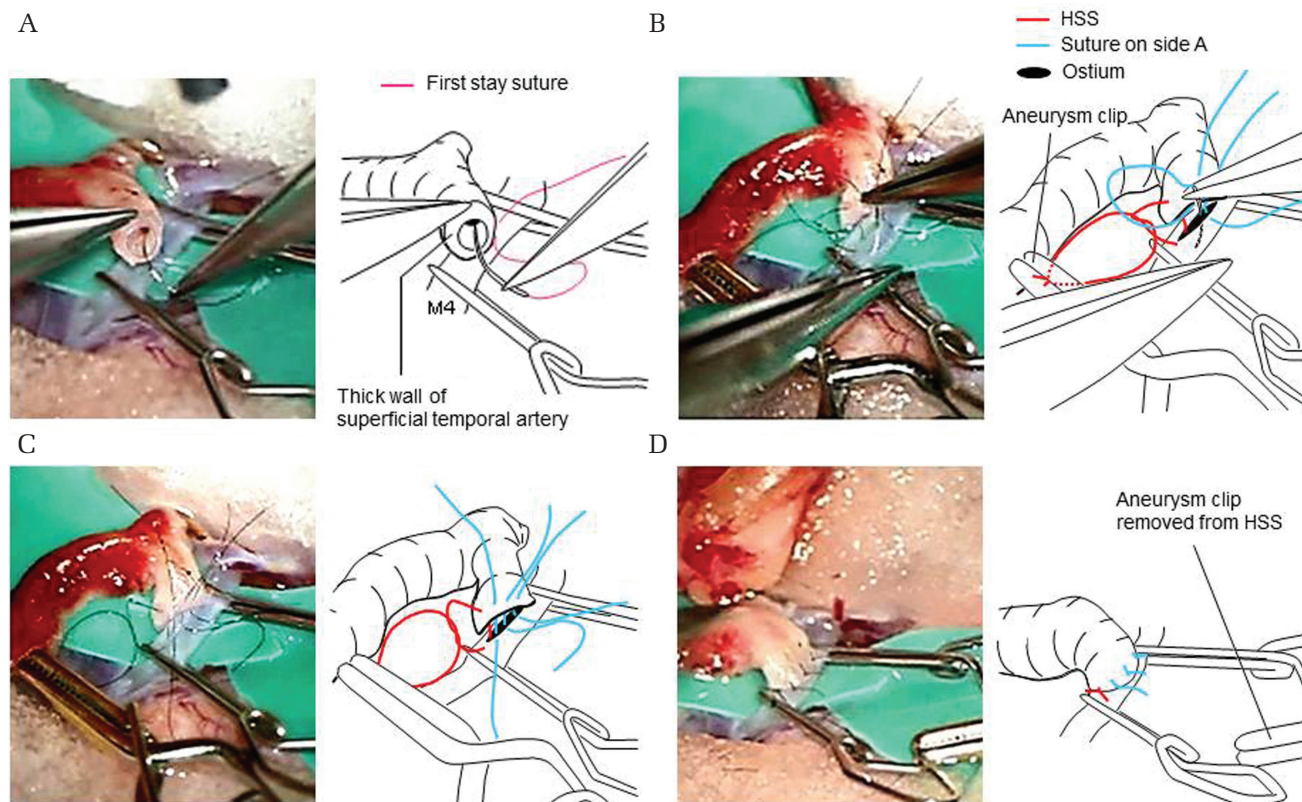


Fig. 2 Application of half-tied stay suture (HSS) method in an elderly patient who underwent superficial temporal to middle cerebral artery anastomosis. **A:** The first stay suture is being placed. Thick wall of hard donor artery is observed. **B:** The second stay suture is left as an HSS, and the thread of the HSS is secured with an aneurysm clip. Revolution of the donor artery facilitates viewing of the ostium of the recipient artery. **C:** Completion of interrupted sutures on side A. Next, the donor artery is revolved to the opposite side and side B is sutured in the same manner. **D:** Finally the HSS and all other sutures are tied fully. The clip removed from the HSS is seen.

ostia was minimized; this was especially apparent in the region just beside the stay suture, the most frequent site of incorrect suturing of the contralateral wall. The duration of temporary occlusion of the recipient artery was 25–34 min (mean 28.7 min). In patients with similar unfavorable conditions, application of the conventional method by the same surgeon required up to 50 min. Upon completion of the anastomosis, there was no leakage requiring additional sutures. In all patients, Doppler flowmeter results or indocyanine green video angiograms confirmed patency of the anastomosis and none of the patients required removal of incorrect sutures or heparinization for recanalization. None manifested recurrence of ischemic symptoms, and patency of the anastomosis was confirmed in the follow-up period ranging from 3–46 months (mean 24.7 months) on magnetic resonance angiograms. A technique-related problem was encountered in the first patient who underwent anastomosis using our HSS technique. It was due to inadvertent hooking of a suture loop on side A upon needling on side B. The mistake

was corrected without repercussions and there were no further complications in this patient.

Discussion

Our HSS technique is a partial application of the untied stay suture method used in vascular end-to-end anastomosis for the replantation of an amputated fingertip.⁸⁾ Untied stay sutures facilitate viewing the ostia of very thin vessels whose diameter is 0.5 mm or less by leaving a space between the stumps.

For cerebrovascular end-to-side anastomosis, modifications of the stay suture method, i.e. widening the view of the ostium by mobilization of the donor arteries, have been reported. Shimizu et al.⁹⁾ proposed placing a single stay suture. However, in the absence of a second stay suture to help identifying the center of the two sides, it is difficult to needle the floated donor artery at correct intervals. Others^{7,10)} placed a stay suture, leaving a needle as a marking pin in the perforated vascular walls of the donor- and recipient arteries. Their methods risk pulling out the needle

during mobilization of the donor artery. Compared with those modified stay sutures, our HSS method is easier and more effective because it identifies the center of both sides and facilitates correct suturing of the floated donor artery, and because it allows mobilizing the donor artery without the risk of pulling out the suture thread.

It may be possible to use our HSS method to treat children with Moyamoya disease whose vessels are thin and fragile. However, technical difficulties may arise in patients whose anastomosis site is deep and narrow, and whose anastomosis requires many sutures. Application of the HSS method needs space for the clip securing the HSS. Also, the sutures remaining on side A must be carefully placed upon needling on side B to avoid hooking the suture loops.

In conclusion, the HSS method presented here may be safe and effective in patients requiring cerebrovascular end-to-side anastomosis and in those where visualization of the ostium is poor when the conventional fully-tied stay suture method is used. The application of our method can be expected to reduce the risk for occlusion of the anastomosis.

Conflicts of Interest Disclosure

The authors have no personal financial or institutional interest in any of the drugs, materials, or devices in the article. All authors who are members of The Japan Neurosurgical Society (JNS) have registered online Self-reported COI Disclosure Statement Forms through the website for JNS members.

References

- 1) Guity A, Young PH, Fischer VW: In search of the "perfect" anastomosis. *Microsurgery* 11: 5–11, 1990
- 2) Kamiyama H, Takahashi A, Houkin K, Mabuchi S, Abe H: Visualization of the ostium of an arteriotomy in bypass surgery. *Neurosurgery* 33: 1109–1110, 1993
- 3) Miyamoto S, Nagata I, Morimoto M, et al.: [Fundamental techniques of vascular anastomosis]. *Jpn J Neurosurg (Tokyo)* 9: 451–456, 2000 (Japanese)
- 4) Okada Y, Shima T, Yamane K, Yamanaka C, Kagawa R: Cylindrical or T-shaped silicone rubber stents for microanastomosis—technical note. *Neurol Med Chir (Tokyo)* 39: 55–58, 1999
- 5) Koyama J, Tanaka Y, Iwashita T, Kitazawa K, Hongo K: Continuous suction method in superficial temporal artery-middle cerebral artery anastomosis surgery. Technical note. *Neurol Med Chir (Tokyo)* 46: 262–264, 2006
- 6) Spetzler RF, Iversen AA: Malleable microsurgical suction device. Technical note. *J Neurosurg* 54: 704–705, 1981
- 7) Houkin K: [The basics of vascular anastomosis]. In Kamiyama H (ed): *Cerebrovascular Reconstruction*, (author's translation). Tokyo, Chugai Igakusha, 2000, pp. 1–30 (Japanese)
- 8) Hasegawa K, Metani M, Saiga M, Kimata Y: [Replantation of infantile zone I after fingertip amputation using the untied stay suture method]. *Journal of the Chugoku-Shikoku Orthopaedic Association* 21: 183–188, 2009 (Japanese)
- 9) Shimizu K, Okamoto S, Sakamoto Y, Yokoyama K, Araki Y, Wakabayashi T: [*In situ* bypass using a superficial temporal artery as an interposition graft in a case of unruptured middle cerebral artery aneurysm] (author's translation). Abstract in The 74th Annual Meeting of the Japan Neurosurgical Society, 2015 (Japanese)
- 10) Haga D, Uekusa H: [Modification of superficial temporal to middle cerebral artery bypass in our institute for easy and secure anastomosis] (author's translation). Abstract in The 77th Annual Meeting of the Japan Neurosurgical Society, 2018 (Japanese)

Address reprint requests to: Satoru Shimizu, MD, Department of Neurosurgery, Yokohama Brain and Spine Center, 1-2-1 Takigashira, Isogo-ku, Yokohama, Kanagawa 235-0012, Japan.
e-mail: Satoru4756@aol.com