


Myxedema heart disease and non-comatose presentation of myxedema: A case report

SAGE Open Medical Case Reports
Volume 10: 1–4
© The Author(s) 2022
Article reuse guidelines:
sagepub.com/journals-permissions
DOI: 10.1177/2050313X221130227
journals.sagepub.com/home/sco



Laura Valenzuela-Vallejo^{1,2}, Lucila Emilse Folleco-Ortiz^{2,3},
David Corredor-Orlandelli^{1,2} , Juan Felipe Aguirre-Ruiz^{4,2},
Nicolas Isaza⁵ and Alex Valenzuela-Rincon^{6,7}

Abstract

Myxedema coma is an emergency that develops from non-diagnosed or severe hypothyroidism and requires early recognition and management. Cardiac manifestations are uncommon and pose a challenge in the recognition of myxedema coma. We present the case of a 76-year-old male with a history of thyroidectomy secondary to a follicular carcinoma, who presented with dyspnea, generalized edema, drowsiness, disorientation, memory loss, and episodic generalized tonic-clonic seizures. Antiepileptic and diuretic treatment for seizures and heart failure exacerbation did not improve the symptoms. Further blood analysis revealed a thyroid-stimulating hormone and free thyroxine of 163 mUL/L and 0.64 ng/dL, respectively. Treatment with intravenous hydrocortisone and levothyroxine led to progressive clinical improvement. Uncommon clinical manifestations such as cardiac and non-specific neurologic symptoms should be considered as manifestations of myxedema coma. A comatose mental status is not a universal manifestation, and milder symptoms should be considered. An adequate assessment, including diagnostic scores and prompt hormonal supplementation prevents fatal consequences.

Keywords

Hypothyroidism, myxedema, heart failure, thyroxine, abnormal movement disorder, myxedema coma

Date received: 2 July 2022; accepted: 15 September 2022

Introduction

Myxedematous coma (MC) is an emergency that results from severe or untreated hypothyroidism. The prevalence of this condition is approximately 0.1% of hospitalized patients with hypothyroidism, mainly affecting women over 60 years of age.¹ MC is associated with triggers such as infections, acute coronary syndrome, cerebrovascular disease, heart failure (HF) exacerbation, administration of sedatives, trauma, or electrolyte disturbances. The mortality attributed to MC (30%–60%) is mainly secondary to delayed diagnosis and treatment due to MC's insidious and non-specific symptoms.² MC can manifest at various levels of altered consciousness, along with drowsiness or disorientation not necessarily reaching comatose levels. Other symptoms of MC include hypothermia, hypopnea, ileus/constipation, acute kidney injury, or hypoglycemia.³ Cardiovascular manifestations are less frequent and include hypotension, bradycardia, or HF, which in conjunction can lead to myxedema heart disease (MHD).^{4,5} MHD is a potentially fatal condition first described in 1918 by Zondek et al. as a syndrome that

encompasses an enlarged cardiac silhouette, pericardial effusions, and electrocardiographic changes, that is, bradycardia, low-voltage, conduction blocks, ST changes, T-wave inversions, and arrhythmias.^{6,7} In addition, uncommon neurological manifestations such as seizures have been

¹School of Medicine and Health Sciences, Universidad del Rosario, Bogotá, Colombia

²Fundación Cardioinfantil – LaCardio, Bogotá, Colombia

³Neurology Department, Neuroscience Research Group (NEUROS), School of Medicine and Health Sciences, Universidad del Rosario, Bogotá, Colombia

⁴Internal Medicine Department, School of Medicine and Health Sciences, Universidad del Rosario, Bogotá, Colombia

⁵Department of Internal Medicine, Beth Israel Deaconess Medical Center, Harvard Medical School, Boston, MA, USA

⁶Endocrinology Department and Internal Medicine Department, Fundación Cardioinfantil – LaCardio, Bogotá, Colombia

⁷School of Medicine and Health Sciences, Universidad del Rosario, Bogotá, Colombia

Corresponding Author:

David Corredor-Orlandelli, School of Medicine and Health Sciences, Universidad del Rosario, Bogotá 110111, Colombia.
Email: David.corredor01@urosario.edu.co



Table 1. Evolution of laboratory results over time.

Test	Reference value	Days of hospitalization									
		1	5	10	13	17	20	30	36	44	62
TSH (mUI/L)	0.35–4.94			166.3		56.2	21.2		29.05	28.4	10.2
Free T4 (ng/dL)	0.7–1.48			0.64		0.68	0.83		0.99	0.96	0.91
Total T4 (µg/dL)	4.87–11.7							4.7			4.5
Total T3 (ng/mL)	0.58–1.59			< 0.4							
Free T3 (pg/mL)	2.2–4.4			0.94							
Creatinine (mg/dL)	0.7–1.3	1	1.4	1.9	1.4	1.1	1	0.8	1	1	0.8
BUN (mg/dL)	8.4–25.7	17	22	43	38	29	30	14	13	16	18
Na (mEq/L)	136–142	137	138	139	148	140	143	137	135	134	142
Calcium (mg/dL)	8.8–10	9.1	8.7	9.6	8.8	7.9	7.5	8	8	8.6	8.9
CK (U/L)	39–308						301				
Cortisol (µg/dL)	3.7–19.4						15.3				

TSH: thyroid-stimulating hormone; BUN: blood urea nitrogen; CK: creatin kinase.
Evolution of most important laboratory workup through admission.

described.⁸ This condition is potentially reversible with thyroid hormone (TH) administration, but the lack of suspicion can result in fatal outcomes due to delays in treatment.

We report a case of MC with an unusual presentation characterized by refractory congestive HF, progressive confusion, non-specific neurological symptoms, and memory loss that resolved after TH supplementation. The consideration of uncommon features of MC can lead to its early recognition and treatment and, therefore, prevention of fatal outcomes.

Case report

A 76-year-old male presented to the emergency department with a 2-month course of progressive somnolence, bradypsychia, confusion, memory loss, dyspnea, lower extremity edema, and episodes of generalized tonic-clonic seizures. The patient had a history of controlled hypertension and hypothyroidism with ongoing TH replacement therapy (50 µg/day – a recently reduced dose changed after admission to a different institution) due to a remote history of thyroidectomy secondary to poorly differentiated follicular carcinoma.

On admission, the patient was somnolent, hemodynamically stable, and without respiratory distress. On physical exam, the patient had evidence of volume overload given jugular vein distension, bibasilar rales on auscultation, and generalized edema affecting the face and bilateral lower extremities. Notably, he had several witnessed episodes of generalized tonic-clonic seizures. A complete blood count, blood glucose, electrolytes, and renal function were unremarkable, and a natriuretic peptide was unavailable. An electrocardiogram (ECG) showed atrial fibrillation, diffuse low voltages, and a right-bundle branch block. The chest X-ray was notable for cardiomegaly, and a transthoracic echocardiogram showed grade-I diastolic dysfunction with a preserved left ventricular ejection fraction (60%). Based on the above, the primary working diagnosis was an acute HF exacerbation with a preserved ejection fraction (HF-pEF),

complicated by volume overload. A 6-h video-encephalogram showed moderate encephalopathy, and a head computed tomography (CT) revealed no abnormal findings.

Volume overload was initially managed with boluses of intravenous furosemide, followed by an infusion, and the patient was started on levetiracetam and lacosamide for antiepileptic treatment. Despite the aggressive escalating diuretic management, the patient showed no improvement and had several episodes of bradycardia and hypotension, with mild hypothermia suggestive of refractory HF that prompted transfer to the intensive care unit (ICU) with an initial SOFA score of 4. Further laboratory workup upon ICU admission was notable for a severely increased thyroid-stimulating hormone (TSH) (163 mUI/L), low free thyroxine (FT4) (0.64 ng/dL), and low free triiodothyronine (FT3) (0.94 pg/mL) (Table 1). The Popoveniuc and Wartofsky myxedema score (75 points), which in conjunction with the elevated TSH and the presence of the cardinal symptoms supported the diagnosis of MC.⁹ Treatment with intravenous hydrocortisone (50 mg every 8 h for 9 days) and oral levothyroxine (200 µg daily) were started. Mechanical ventilation was not needed, as ventilatory mechanics and oxygenation parameters improved with a non-rebreather mask. On the following days, the levothyroxine dose was adjusted to 225 µg daily. TSH levels eventually decreased (29.05 mUI/L), and FT4 normalized (0.99 ng/dL), while progressive improvement of congestive symptoms was noted.

Notably, only after thyroid function tests normalized, the patient responded to the same diuretic regimen that was attempted before diagnosing the thyroid abnormalities. Thus, congestive symptoms progressively improved while the fluid balance was monitored with the strict quantification of urinary output, point-of-care ultrasound, and serial chest X-rays. Table 1 and Figure 1 illustrate the evolution of laboratory results throughout the admission. At the time of discharge, the patient was euvolemic without ongoing diuretic requirements or indication for HF medication as an outpatient. The response to

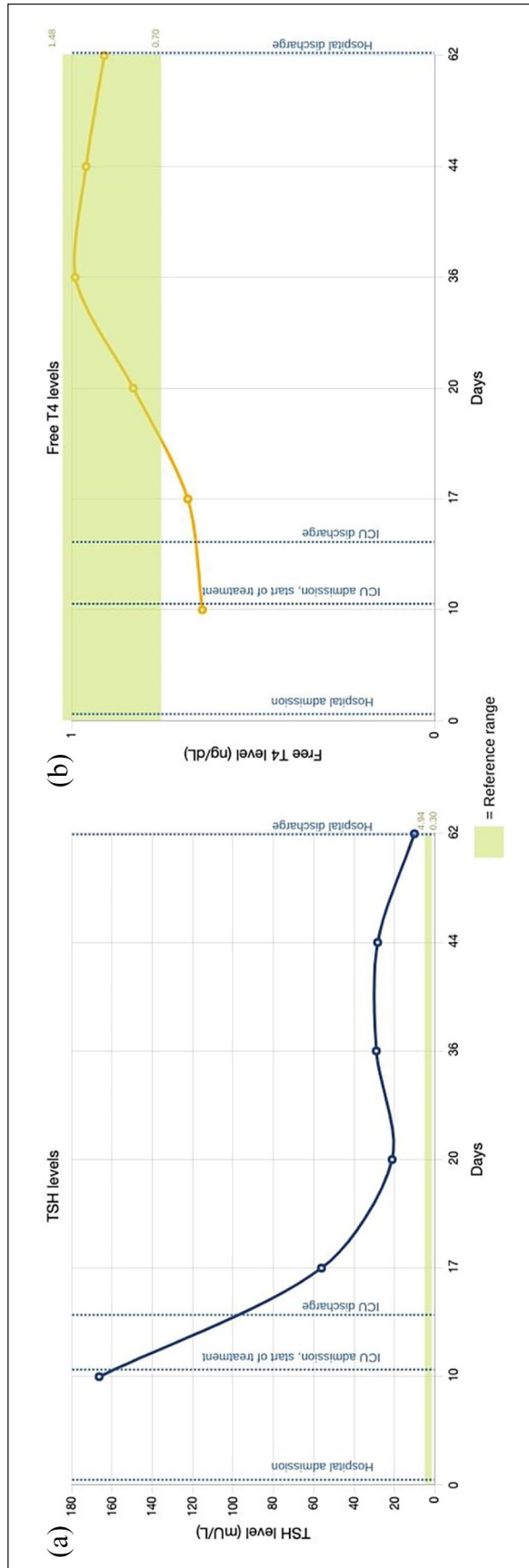


Figure 1. TSH (a) and FT4 (b) level variation during hospital stay. Note. The laboratory reference ranges are represented by the green areas in each graphic.

treatment once euthyroid, as well as the lack of ongoing symptoms of HF, and the fact that the patient required no maintenance diuretic was highly suggestive of the fact that the episode was MHD rather than decompensated HF with concomitant hypothyroidism. Upon discharge, the patient was stable from a cardiovascular perspective, but cognitive symptoms remained compromised, as reflected by a Montreal Cognitive Assessment (MOCA) test score 10/30.¹⁰

Discussion

MC is a multifactorial disease that can present with variable clinical features. MHD and unusual neurological symptoms, including cognitive impairment and seizures, represent a challenge because they can delay the diagnosis and treatment of MC, negatively impacting prognosis and outcomes.⁸ The clinical diagnosis of MC can be supported by a score >60 in the Popoveniuc and Wartofsky MC score (100% sensitivity and 85% specificity), guiding clinicians to promptly start an aggressive treatment.⁹

In the cardiovascular system, THs modulate stroke volume, heart rate, and cardiac output.⁴ Cardiac cells are susceptible to TH changes; thus, acute hypothyroidism can contribute to the development of HF.¹¹ Moreover, fluid imbalance in hypothyroidism can lead to pericardial effusion and cardiac tamponade. MHD is a rare syndrome, first described in 1914, in which severe and refractory cardiac alterations occur in patients with profound hypothyroidism.^{7,12} Early manifestations of the disease include bradycardia and decreased myocardial contractility. However, blood pressure can be maintained initially with compensatory vasoconstriction, which can lead to diastolic hypertension. Nonetheless, due to the altered homeostasis, hypotension and shock can develop later in the disease, as observed in our case. Vascular permeability is compromised as well, causing pericardial and pleural effusions. In more than 95% of the described cases of MHD-related effusions, TSH levels were above 30 mU/L.^{12,13} Thereby, in cases of unexplained effusions, severe hypothyroidism should be ruled out.

ECG changes that resolve with TH supplementation are a characteristic finding of MHD, even though may not always be present. Another differentiating factor of MHD is the inadequate response to conventional HF treatment until TH supplementation is administered.

On the contrary, hypothyroidism alters neurologic functions. MC could alter memory, attention, language, psychomotor, perceptual, and executive functions. These symptoms usually improve with therapy but can persist over time in MC, as in the case reported.¹⁴ Even though MC classically presents with altered mental status, other neurological features such as abnormal movement disorders have also been scarcely reported in the literature.¹⁵ Some animal experiments have shown the incidence of seizures in severe hypothyroidism following thyroidectomy, in addition to reduced photoparoxysmal epileptic response in baboons.⁸ Nevertheless,

seizures caused by MC are not precisely understood. Some hypotheses point to cerebral edema secondary to extracellular volume expansion, blood–brain barrier alterations, and increased cerebrospinal fluid as potential causes of MC-related seizures.⁸ In addition, hyponatremia, hypoventilation, post-anoxic encephalopathy, hepatic glycogenolysis failure, and reduced adrenocortical function have been related to this phenomenon as well.¹⁶

When MC is suspected, ICU-supportive treatment and steroid supplementation must be promptly started. TH replacement should be prioritized, initially, at a dose of 200–500 µg intravenous (IV) levothyroxine, followed by 50–100 µg IV daily. The preferred route of administration in these scenarios is IV because of its greater bioavailability compared to the oral route, especially as patients with MC can develop intestinal dysmotility. However, the availability of IV levothyroxine differs by country, and oral supplementation can be used when there is no IV option. Once the patient tolerates oral supplementation, levothyroxine should be dosed at 1.6 µg/kg/day or 75% of the previous IV dose. Following TH supplementation, MC symptoms should progressively improve. The mental status of our patient considerably improved as TH levels normalized, but the cognitive alteration persisted at the time of discharge with only slight amelioration. As seen in our case, an incomplete resolution in cognitive impairment after MC treatment has been reported.¹⁷

Conclusion

We report an unusual case of MC in which an overlapping presentation of MHD and unusual neurological symptoms led to a delayed diagnosis. It is crucial to recognize atypical clinical manifestations of MC and have in mind thyroid function on the clinical approach of unexplained and refractory cardiovascular and neurological alterations as possible findings of MC. Immediate treatment is fundamental to decreasing fatal complications.

Author contributions

All the authors have accepted responsibility for the entire content of this submitted manuscript and approved submission.

Declaration of conflicting interests

The author(s) declared no potential conflicts of interest with respect to the research, authorship, and/or publication of this article.

Funding

The author(s) received no financial support for the research, authorship, and/or publication of this article.

Ethics approval

Ethical approval for this study was obtained from: Fundación Cardioinfantil – LaCardio Ethics Committee and Institutional Review Board. #Acta No. 33-2021.

Informed consent

Written informed consent was obtained from the legally authorized representative of the patient.

ORCID iD

David Corredor-Orlandelli  <https://orcid.org/0000-0002-0676-1770>

References

1. Papi G, Corsello SM and Pontecorvi A. Clinical concepts on thyroid emergencies. *Front Endocrinol* 2014; 5: 102–111.
2. Beynon J, Akhtar S and Kearney T. Predictors of outcome in myxoedema coma. *Crit Care* 2008; 12(1): 111.
3. Ono Y, Ono S, Yasunaga H, et al. Clinical characteristics and outcomes of myxedema coma: analysis of a national inpatient database in Japan. *J Epidemiol* 2017; 27(3): 117–122.
4. Danzi S and Klein I. Thyroid hormone and the cardiovascular system. *Med Clin North Am* 2012; 96(2): 257–268.
5. Dhara C, Gangadharan V and Forrest T. Heart failure presenting as myxedema coma: case report and review article. *Tennessee Med* 2014; 107(2): 39–41.
6. Zonder H. Das myxödemherz. *Münch Med Wochenschr* 1918; 2: 1180–1182.
7. Chaudhry MA, Grazette L and Fong MW. Myxedema heart disease: a rare disease entity—case report and brief review of the literature. *Curr Hypertens Rev* 2019; 15(1): 13–16.
8. Bryce GM and Poyner F. Myxoedema presenting with seizures. *Postgrad Med J* 1992; 68(795): 35–36.
9. Popoveniuc G, Chandra T, Sud A, et al. A diagnostic scoring system for myxedema coma. *Endocr Pract* 2014; 20(8): 808–817.
10. Freitas S, Simões MR, Alves L, et al. Montreal cognitive assessment: validation study for mild cognitive impairment and Alzheimer disease. *Alzheimer Dis Assoc Disord* 2013; 27(1): 37–43.
11. Shuvy M, Shifman OET, Nusair S, et al. Hypothyroidism-induced myocardial damage and heart failure: an overlooked entity. *Cardiovasc Pathol* 2009; 18(3): 183–186.
12. Baldwin C, Newman JD, Vallejo F, et al. Myxedema heart and pseudotamponade. *J Endocr Soc* 2021; 5(1): 1–9.
13. Wang JL, Hsieh MJ, Lee CH, et al. Hypothyroid cardiac tamponade: clinical features, electrocardiography, pericardial fluid and management. *Am J Med Sci* 2010; 340(4): 276–281.
14. Constant EL, Adam S, Seron X, et al. Anxiety and depression, attention, and executive functions in hypothyroidism. *J Int Neuropsychol Soc* 2005; 11(5): 535–544.
15. Patel P, Bekkerman M, Varallo-Rodriguez C, et al. An atypical case of myxedema coma with concomitant nonconvulsive seizure. *Case Rep Crit Care* 2016; 2016: 3438080–3438084.
16. Gunatilake SSC and Bulugahapitiya U. Myxedema crisis presenting with seizures: a rare life-threatening presentation – a case report and review of the literature. *Case Rep Endocrinol* 2017; 2017: 4285457.
17. Cho JN, Avera S and Iyamu K. A case of myxedema coma confounded by dementia and hypokalemia. *J Endocrinol Metab* 2019; 9(3): 71–76.