

[ CASE REPORT ]

## The Successful Application of Plasmapheresis in the Treatment of a Patient with Opsoclonus and Autoantibodies to Glutamate Receptor $\delta 2$

Kiyotaka Nakamagoe<sup>1</sup>, Seitaro Nohara<sup>1</sup>, Yukitoshi Takahashi<sup>2</sup>, Mao Takiguchi<sup>1</sup>,  
Rio Kawakami<sup>1</sup>, Tadachika Koganezawa<sup>3</sup> and Akira Tamaoka<sup>1</sup>

### Abstract:

Glutamate receptor  $\delta 2$  (GluR $\delta 2$ ) is expressed in the neuronal postsynaptic densities at the junctions between the Purkinje cells and the parallel fibers. Recent reports have described patients with opsoclonus who possess anti-GluR $\delta 2$  antibodies. We report the case of a 53-year-old man with opsoclonus whose cerebrospinal fluid was positive for anti-GluR $\delta 2$  antibodies. Electronystagmography revealed abnormal sinusoidal eye movements, which were definitively identified as opsoclonus. The frequency and amplitude of saccadic oscillations diminished after plasmapheresis (PE). The patient's opsoclonus was altered after PE, suggesting that anti-GluR $\delta 2$  antibodies may act on the saccade generator in the brainstem via the cerebellum and that they may be involved in the onset of opsoclonus.

**Key words:** oscillopsia, cerebrospinal fluid, antiglutamate receptor antibody, saccadic oscillation, opsoclonus, plasmapheresis

(Intern Med 56: 2773-2778, 2017)

(DOI: 10.2169/internalmedicine.6771-15)

### Introduction

Opsoclonus is a sinusoidal oscillation of the eye that is believed to be associated with a disturbance of the omnipause neurons (OPNs) in the paramedian pontine reticular formation (1). When the cerebellar Purkinje cells are impaired, disinhibition of the cerebellar fastigial nucleus occurs. It has been hypothesized that this may cause opsoclonus (2-4). Based on this hypothesis, it has also been theorized that input from the parallel fibers to the Purkinje cells in the cerebellum may be blocked by autoantibodies, causing the appearance of opsoclonus (5, 6). Another study reported that the impairment of ion channels in burst neurons may contribute to the development of opsoclonus (7).

Anti-GluR $\delta 2$  antibodies have been implicated in opsoclonus-myoclonus syndrome in three recent case reports (6, 8, 9). The cerebrospinal fluid of all three patients

tested positive for anti-GluR $\delta 2$  antibodies, and all of the patients responded well to steroid pulse therapy or immunotherapy with intravenous immunoglobulin (6, 8, 9). These results suggest an association between anti-GluR $\delta 2$  antibodies and opsoclonus, myoclonus, and the loss of coordination; however, it remains unclear whether anti-GluR $\delta 2$  antibodies are directly involved in the mechanism that underlies the onset of saccadic oscillations, including opsoclonus.

We carried out eye movement tests on a patient with opsoclonus whose cerebrospinal fluid was positive for anti-GluR $\delta 2$  antibodies. We analyzed the changes in saccadic oscillations brought about by plasmapheresis (PE) and attempted to formulate an electrophysiological explanation for the mechanism underlying the onset of saccadic oscillations related to anti-GluR $\delta 2$  antibodies.

<sup>1</sup>Department of Neurology, Division of Clinical Medicine, Faculty of Medicine, University of Tsukuba, Japan, <sup>2</sup>National Epilepsy Center, Shizuoka Institute of Epilepsy and Neurological Disorders, Japan and <sup>3</sup>Department of Physiology, Division of Biomedical Science, Faculty of Medicine, University of Tsukuba, Japan

Received: October 30, 2015; Accepted: March 8, 2017; Advance Publication by J-STAGE: September 15, 2017

Correspondence to Dr. Kiyotaka Nakamagoe, nakamagoek@md.tsukuba.ac.jp

## Case Report

The patient was a 53-year-old man whose chief complaints were oscillopsia and staggering when walking. These symptoms appeared suddenly in 2014. Abnormal eye movements were identified at a local clinic, but no abnormality was apparent on cranial magnetic resonance imaging (MRI). The symptoms spontaneously improved after approximately one month. Four months after this improvement, the symptoms flared up again, but not to the extent that they significantly interfered with his daily life. One month later, the oscillopsia was exacerbated when the patient suffered from fever, nausea, diarrhea, and other symptoms of acute gastroenteritis, and he developed vertigo and became unable to walk. He regained the ability to walk after approximately one month; however, the oscillopsia and unsteady gait persisted for at least another three months.

### Neurological findings

The patient was lucid, and his higher brain function was preserved. Irregular rapid abnormal eye movements were evident, the movements were primarily horizontal, but movements in all directions were observed. These movements were suppressed when his gaze was fixed. The finger-to-nose test of coordinated movement revealed bilateral cerebellar ataxia, primarily on the left. There were no involuntary movements such as myoclonus. The patient was unable to walk heel-to-toe; however, the muscle strength in all four limbs was preserved. The deep tendon reflexes, including the masseter reflex, were normal. There were no sensory or autonomic nervous disturbances.

### Test results

The peripheral blood count and blood biochemistry test results were all normal. An analysis of the cerebrospinal fluid revealed that the cell count was normal at 1/ $\mu$ L (mononuclear cells, 1/ $\mu$ L; polymorphonuclear cells, 0/ $\mu$ L), and that the protein level (33 mg/dL) was also normal. The cerebrospinal fluid was negative for oligoclonal bands, and there was no elevation of the IgG index or of antibodies to any viruses. General bacterial and mycobacterial cultures were negative, and the cytology was class II. Furthermore, cranial contrast MRI revealed no abnormalities.

We performed thoracoabdominal CT, abdominal echo, upper gastrointestinal endoscopy, and investigated the patient's tumor marker levels in order to distinguish paraneoplastic opsoclonus; however, no neoplastic disease was detected.

### Clinical course

Brainstem-cerebellar syndrome due to autoantibody-mediated encephalopathy was suspected on the basis of the opsoclonus and cerebellar ataxia; thus, the anti-GluR $\delta$ 2 antibody levels in the patient's plasma and cerebrospinal fluid were measured. At eight months after the onset of symptoms, simple PE was performed a total of three times. Step-

ping tests, heel-to-toe walking tests, and electronystagmography were performed before and after PE.

### The detection of antibodies against three domains of GluR $\delta$ 2 in the serum and CSF

We detected antibodies against three domains of Glu $\delta$ 2 molecules using conventional enzyme-linked immunosorbent assays. The natriuretic (NT)-peptide (FDESAKKDDEVFRT, 33-46 of the Glu $\delta$ 2 molecule) was synthesized as an antigen to detect antibodies against the N-terminal of Glu $\delta$ 2 (antibodies against Glu $\delta$  2-NT). The CT-peptide (PEHRTGPFHRAPNG, 958-972 of the Glu $\delta$ 2 molecule) was synthesized as an antigen to detect antibodies against the C-terminal domain of Glu $\delta$ 2 (antibodies against Glu $\delta$ 2-CT). The binding of these antibodies was detected by measuring the optical density of the samples. Results were considered positive if the values exceeded the mean + two standard deviations of the control serum and the control cerebrospinal fluid. The optical density level was increased in our patient [level (mean (SD) control value),  $\delta$ 2-NT: 0.676 (0.358 (0.165))], indicating anti-GluR $\delta$ 2 antibody positivity. Serum tests for anti-GluR $\delta$ 2 antibodies were negative. The patient's cerebrospinal fluid was tested for Anti-N-methyl-D-aspartate receptor antibodies with a cell-based assay using NR1 and NR2 co-transfected human embryonic kidney (HEK) cells; however, the result was negative.

Stepping tests and heel-to-toe walking tests: The stepping test with eyes closed was performed as a test of the balance function of the vestibulospinal reflex system. The patient stood in the center of a circle with a radius of one meter with his eyes closed. He then stepped in place 50 times with both arms stretched out in front of him while keeping his eyes closed. Bias was evaluated based on the step angle and the distance traveled. The heel-to-toe walking test was also carried out before and after PE to evaluate gait disturbance. The bias angle improved after PE, and ultimately disappeared (Table). PE had no effect on the distance traveled. The patient was incapable of heel-to-toe walking before PE; however, his gait function improved after PE and heel-to-toe walking became possible. His oscillopsia was reduced.

The measurement and analysis of eye movements: Electrodes were attached to the patient's eyelids in horizontal and vertical orientations; direct current (DC) recordings of the original waveforms of the eye movements in each direction were made using electronystagmography (ENG) (First, Tokyo, Japan) and a PowerLab data collection and recording device (sampling frequency of 1 kHz; AD Instruments, Castle Hill, Australia). Tests were carried out in the dark, with the patient's eyes open. The patient was in a supine position and wore goggles fitted with an infrared camera that monitored his eye movements. The patient was seated and instructed to fix his gaze on a red laser light directly in front of him (frontal gaze); during this time, his eye movements were recorded. He then closed his eyes and fixed his gaze again. One series involved the maintenance of each condition for 20 seconds; this was performed a total of three

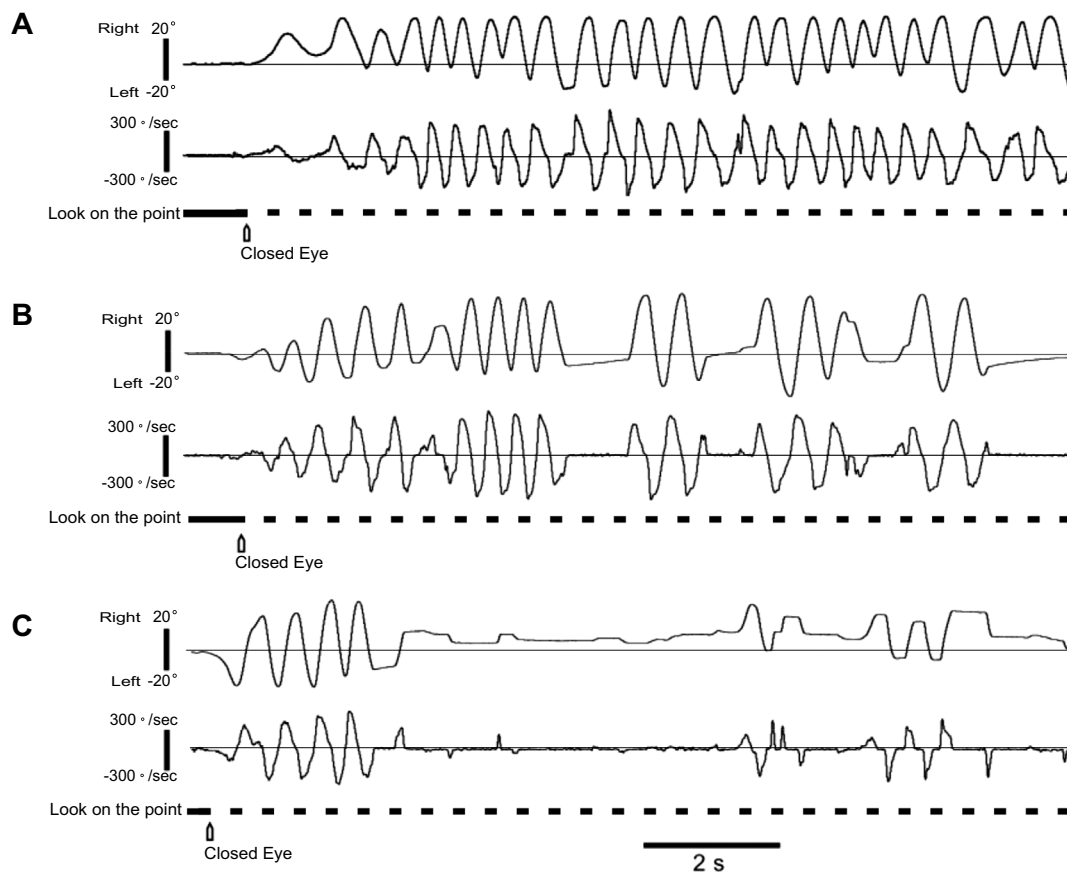
**Table.** Analysis of Eye Movement Recordings and Clinical Examination in Pre-PE and Post-PE.

|                | Opsoclonus        |                        | Stepping test |               | Tandem gait |
|----------------|-------------------|------------------------|---------------|---------------|-------------|
|                | Frequency (/min.) | Amplitude (°)          | Angle (°)     | Distance (cm) |             |
| Pre-PE         | 106.6±20.5        | 59.5±9.2               | 60            | 55            | Impossible  |
| Post-PE 2nd    | 78.7±9.2          | 70.0±9.6 <sup>a</sup>  | 30            | 60            | Possible    |
| Post-PE 3rd -1 | 42.7±15.1         | 58.0±15.3 <sup>a</sup> | 0             | 50            | Possible    |
| Post-PE 3rd -2 | 46.7±8.3          | 44.4±12.9 <sup>a</sup> | 0             | 50            | Possible    |

The results from two days before the first PE (Pre-PE), five days after the second PE (Post-PE 2nd), five days after the third PE (Post-PE 3rd-1), and 12 days after the third PE (Post-PE 3rd-2) are shown.

<sup>a</sup>Compared using the Mann-Whitney U test ( $p < 0.05$ )

PE: plasmapheresis



**Figure 1.** Electronystagmography with eyes closed (DC recording). The top traces show the horizontal eye movements, and the bottom traces show their speed. A: Waveforms recorded two days before the first PE. B: Waveforms recorded five days after the second PE. C: Waveforms recorded five days after the third PE. In A, the position of the eyes when the gaze was fixed on a laser light was constant in the primary position; however, opsoclonus (sinusoidal abnormal eye movements) appeared after the eyes were closed. Similar results were recorded in B and C; however, opsoclonus appeared less frequently in comparison to A.

times. The waveforms of the recorded eye movements were analyzed, 15-second waveforms were extracted at three points, and the mean frequency of their appearance was measured. The mean amplitude was calculated. The SPSS software program (IBM, New York, USA) was used to compare data from before and after PE.  $p$  values of  $< 0.05$  were considered to indicate statistical significance. Electronystagmography revealed high-amplitude sinusoidal eye move-

ments at around 2 Hz in the horizontal direction when the patient's gaze was not fixated, with closed eyes, and when his eyes were open in the dark. These findings were consistent with opsoclonus (Fig. 1A). All of these eye movements were suppressed and disappeared when the patient's gaze was fixated.

Fig. 1 shows an electronystagmogram that was taken when the patient's eyes were closed. The frequency with

which opsoclonus appeared decreased each time that PE was performed. There was a significant increase in the amplitude after the second PE; however, it diminished after the third PE (Fig. 1B and C, Table).

## Discussion

### Anti-GluR $\delta$ 2 antibodies

GluR $\delta$ 2 has a specific distribution in the cerebellar Purkinje cells of mice: it is present in the parallel fiber synapses but not in the climbing fiber synapses (10-13). GluR $\delta$ 2 is believed to be an important factor in the formation, maturation, and plasticity of parallel fiber synapses (14). In recent years, there have been several cases in which anti-GluR $\delta$ 2 antibodies have been found in the cerebrospinal fluid of patients with opsoclonus-myoclonus syndrome (6, 8, 9).

In the present case, no prior infection was evident. However, the patient's symptoms worsened when he was suffering from acute gastroenteritis. From this episode, we suggested that a prior infection might have induced the activation of the peripheral blood lymphocytes, their passage through the blood-brain barrier, and their production of anti-GluR antibodies in the central nervous system (CNS).

### The mechanism underlying the appearance of opsoclonus due to anti-GluR $\delta$ 2 antibodies

Opsoclonus is defined as follows: "Combined multidirectional, horizontal, vertical, and torsional saccadic oscillations without an intersaccadic interval" (15). In the present case, the patient's saccadic oscillations were defined as opsoclonus based on the ENG pattern.

The reported frequency of opsoclonus ranges from 4-15 Hz (2, 5). Although our patient had the clinical features of characteristic oscillations such as multidirectional and sinusoidal ocular movement, their low frequency (2 Hz) complicated the diagnosis of opsoclonus. We assume that the cause of this low frequency may have been the extremely large amplitude ( $> 60^\circ$ ).

There have been reports on opsoclonus in which saccadic oscillations both increased (2, 4) and decreased (2) during eye fixation. The mechanisms underlying these responses are still unknown. In our case, opsoclonus decreased during eye fixation. At the time of onset, our patient's symptoms (*e.g.*, diplopia) worsened when he gazed. Eight months later, our clinical examinations revealed that the patient had obtained relief from this symptom while gazing. Thus, this episode suggests that the effects during eye fixation varied according to the phase of the disease.

Fig. 2A shows a diagram-which was produced based on previous studies-of the neural pathways involved in saccade generation in the cerebellum and brainstem when the eyes are fixated in the central position (16-23). The oculomotor vermis (OMV) exerts inhibitory control over the fastigial oculomotor region (FOR). The FOR, in turn, exerts inhibitory control over the OPNs, thus controlling saccades. When

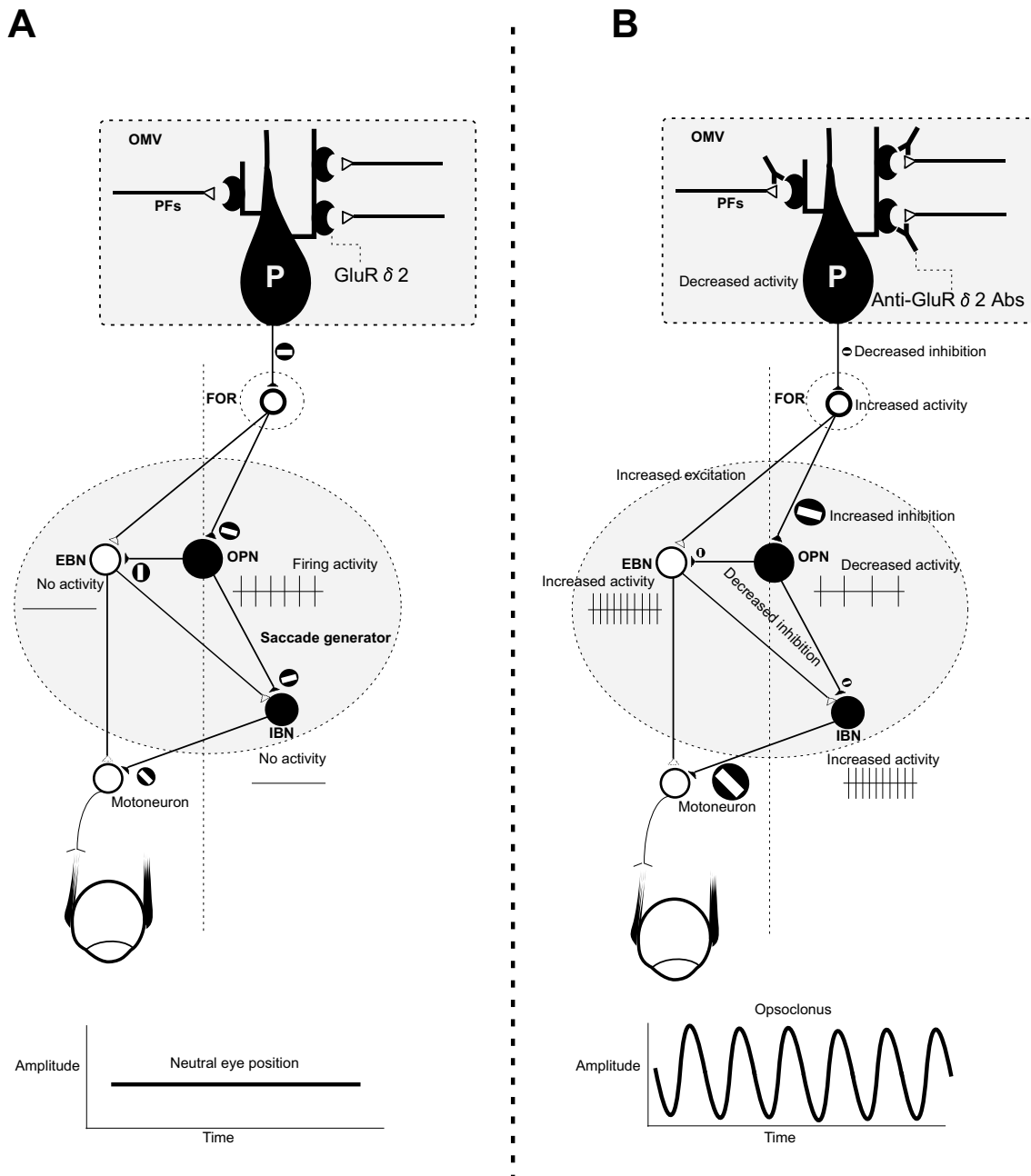
the eyes are fixated, there is no saccade command from the superior colliculus; thus, there is no excitatory burst neuron (EBN) or inhibitory burst neuron (IBN) activity. Consequently, firing remains quiescent. However, the OPNs, which (in addition to the EBNs and IBNs) is an important structural element of the saccade generator, does exhibit sustained firing. GluR $\delta$ 2 is expressed at the junctions of the cerebellar Purkinje cells and parallel fibers and is one of the molecules expressed in neuronal postsynaptic densities (PSDs) (10-13). According to Bataller et al., PSDs may offer an easy target for autoantibodies as new autoantigens (24).

Based on previous saccade generation mechanisms, we hypothesize that the following mechanism underlies the appearance of opsoclonus due to anti-GluR $\delta$ 2 antibodies (Fig. 2B) (16-23). When input to Purkinje cells from junctions with parallel fibers is blocked by anti-GluR $\delta$ 2 antibodies, the Purkinje cell activity declines, and the inhibition of the FOR diminishes, causing the FOR to become disinhibited. The increased activity of the FOR results in the greater inhibition of the OPNs, reducing the sustained firing by the OPNs. As a result, the inhibition of EBNs and IBNs by the OPN weakens, generating burst firing. In addition, the excitation of EBNs is increased by the elevated FOR activity, which promotes firing activity. The abnormal firing activity induced by the EBNs and IBNs acts on the extraocular motoneurons, causing the appearance of abnormal sinusoidal eye movements (opsoclonus). The fact that opsoclonus appears when the input from fibers parallel to the Purkinje cells is disrupted (5) and that abnormal eye oscillations resembling opsoclonus were seen in GluR $\delta$ 2-knockout mice when there was no input from fibers parallel to the cerebellar Purkinje cells (25) are both consistent with this hypothesis. Reports that functional MRIs of patients with opsoclonus reveal increased activity in the bilateral fastigial nuclei also support our hypothesis (3).

In this case, the bias during the stepping test with eyes closed was significantly resolved after PE, and the patient also became capable of heel-to-toe walking, indicating that the changes in abnormal eye movements, which occurred as a result of PE, directly affected physical balance and improved the patient's gait disturbance.

In conclusion, we showed-clinically and physiologically-that anti-GluR $\delta$ 2 antibodies are implicated in the generation of opsoclonus. The elimination of the anti-GluR $\delta$ 2 antibodies by PE changed the opsoclonus and improved the patient's impaired physical balance. The generation of opsoclonus can be explained by the hypothesized mechanism of saccade generation. We were not able to investigate the chronological changes in the anti-GluR antibody levels. Thus, a further investigation is necessary to prove whether anti-GluR antibodies are related to clinical manifestations such as opsoclonus. We intend to carry out further studies to back up these hypotheses in the future.

**The authors state that they have no Conflict of Interest (COI).**



**Figure 2.** The proposed mechanism for the involvement of anti-GluR $\delta$ 2 antibodies in the generation of saccadic oscillations. **A:** A diagram of the neural pathways associated with the generation of saccades when the eyes are fixated in the central position (16-23). GluR $\delta$ 2 is expressed in the neuronal postsynaptic densities at the junctions between the cerebellar Purkinje cells and the parallel fibers. The OMV exerts inhibitory control over the FOR. The FOR exerts inhibitory control over the OPNs. There is no saccade command from the superior colliculus; thus, there is no EBN or IBN activity. Consequently, firing remains quiescent. The OPNs, however, exhibit sustained firing. **B:** The proposed mechanism for the appearance of opsoclonus caused by anti-GluR $\delta$ 2 antibodies. When input to Purkinje cells from the junctions with parallel fibers is blocked by anti-GluR $\delta$ 2 antibodies, there is a decline in Purkinje cell activity, and the disinhibition of the FOR occurs. An increase in the activity of the FOR results in the greater inhibition of the OPNs, reducing their sustained firing. As a result, the inhibition of EBNs and IBNs by the OPNs weakens, resulting in burst firing. In addition, the firing activity of EBNs is increased by the elevated activity of the FOR. Abnormal firing by the EBNs and IBNs acts on the extraocular motoneurons, causing the appearance of sinusoidal abnormal eye movements (opsoclonus). GluR $\delta$ 2: glutamate receptor  $\delta$ 2, P: Purkinje cells, PFs: parallel fibers, OMV: oculomotor vermis, FOR: fastigial oculomotor region, OPN: omnipause neuron, EBN: excitatory burst neuron, IBN: inhibitory burst neuron, Anti-GluR $\delta$ 2 Abs: anti-glutamate receptor  $\delta$ 2 antibodies



**Acknowledgement**

The authors thank Keiko Tanaka, MD, PhD (Department of Neurology, Kanazawa Medical University), for performing the tests for Anti-N-methyl-D-aspartate receptor antibodies.

**Financial Support**

This work was supported by JSPS KAKENHI Grant number JP 26460901.

**References**

- Zee DS, Robinson DA. A hypothetical explanation of saccadic oscillations. *Ann Neurol* **5**: 405-414, 1979.
- Wong AM, Musallam S, Tomlinson RD, Shannon P, Sharpe JA. Opsoclonus in three dimensions: oculo-graphic, neuropathologic and medelling correlates. *J Neurol Sci* **189**: 71-81, 2001.
- Helmchen C, Rambold H, Sprenger A, Erdmann C, Binkofski F. Cerebellar activation in opsoclonus: an fMRI study. *Neurology* **61**: 412-415, 2003.
- Helmchen C, Rambold H, Erdmann C, Mohr C, Sprenger A, Binkofski F. The role of the fastigial nucleus in saccadic eye oscillations. *Ann N Y Acad Sci* **1004**: 229-240, 2003.
- Jen JC, Lopez I, Baloh RW. Opsoclonus: clinical and immunological features. *J Neurol Sci* **320**: 61-65, 2012.
- Hosaka T, Nakamagoe K, Takahashi Y, Mamada N, Tamaoka A. Opsoclonus associated with autoantibodies to glutamate receptors  $\delta 2$ . *Neurol Sci* **36**: 1741-1742, 2015.
- Shaikh AG, Ramat S, Optican LM, Miura K, Leigh RJ, Zee DS. Saccadic burst cell membrane dysfunction is responsible for saccadic oscillations. *J Neuroophthalmol* **28**: 329-336, 2008.
- Shiikawa T, Takahashi Y. Correspondence: a further case of opsoclonus-myoclonus syndrome associated with Mycoplasma pneumoniae infection. *Eur J Pediatr* **169**: 639, 2010.
- Kambe T, Takahashi Y, Furukawa Y. A mild form of adult-onset opsoclonus-myoclonus syndrome associated with antiglutamate receptor antibody. *JAMA Neurol* **70**: 654-655, 2013.
- Araki K, Meguro H, Kushiya E, Takayama C, Inoue Y, Mishina M. Selective expression of the glutamate receptor channel delta 2 subunit in cerebellar Purkinje cells. *Biochem Biophys Res Commun* **197**: 1267-1276, 1993.
- Lomeli H, Sprengel R, Laurie DJ, et al. The rat delta-1 and delta-2 subunits extend the excitatory amino acid receptor family. *FEBS Lett* **315**: 318-322, 1993.
- Takayama C, Nakagawa S, Watanabe M, Mishina M, Inoue Y. Light-and electron-microscopic localization of the glutamate receptor channel delta 2 subunit in the mouse Purkinje cell. *Neurosci Lett* **188**: 89-92, 1995.
- Landsend AS, Amiry-Moghaddam M, Matsubara A, et al. Differential localization of delta glutamate receptors in the rat cerebellum: coexpression with AMPA receptors in parallel fiber-spine synapses and absence from climbing fiber-spine synapses. *J Neurosci* **17**: 834-842, 1997.
- Kashiwabuchi N, Ikeda K, Araki K, et al. Impairment of motor coordination, Purkinje cell synapse formation, and cerebellar long-term depression in GluR delta 2 mutant mice. *Cell* **81**: 245-252, 1995.
- Leigh RJ, Zee DS. Diagnosis of nystagmus and saccadic intrusion. Chapter 11; Saccadic intrusions and oscillations. *The Neurology of Eye Movements*. 5th ed. Oxford University Press, Oxford, UK, 2015: 716-726.
- Highstein SM, Baker R. Excitatory termination of abducens internuclear neurons on medial rectus motoneurons: relationship to syndrome of internuclear ophthalmoplegia. *J Neurophysiol* **41**: 1647-1661, 1978.
- Hikosaka O, Igusa Y, Nakao S, Shimazu H. Direct inhibitory synaptic linkage of pontomedullary reticular burst neurons with abducens motoneurons in the cat. *Exp Brain Res* **33**: 337-352, 1978.
- Igusa Y, Sasaki S, Shimazu H. Excitatory premotor burst neurons in the cat pontine reticular formation related to the quick phase of vestibular nystagmus. *Brain Res* **182**: 451-456, 1980.
- Sasaki S, Shimazu H. Reticulovestibular organization participating in generation of horizontal fast eye movement. *Ann N Y Acad Sci* **374**: 130-143, 1981.
- Scudder CA, Kaneko CS, Fuchs AF. The brainstem burst generator for saccadic eye movements: a modern synthesis. *Exp Brain Res* **142**: 439-462, 2002.
- Yoshida K, McCrea R, Berthoz A, Vidal PP. Morphological and physiological characteristics of inhibitory burst neurons controlling horizontal rapid eye movements in the alert cat. *J Neurophysiol* **48**: 761-784, 1982.
- Yoshida K, Iwamoto Y, Chimoto S, Shimazu H. Saccade-related inhibitory input to pontine omnipause neurons: an intracellular study in alert cats. *J Neurophysiol* **82**: 1198-1208, 1999.
- Yoshida K, Iwamoto Y, Chimoto S, Shimazu H. Disynaptic inhibition of omnipause neurons following electrical stimulation of the superior colliculus in alert cats. *J Neurophysiol* **85**: 2639-2642, 2001.
- Bataller L, Rosenfeld MR, Graus F, Vilchez JJ, Cheung NK, Dalmau J. Autoantigen diversity in the opsoclonus-myoclonus syndrome. *Ann Neurol* **53**: 347-353, 2003.
- Yoshida T, Katoh A, Ohtsuki G, Mishina M, Hirano T. Oscillating Purkinje neuron activity causing involuntary eye movement in a mutant mouse deficient in the glutamate receptor  $\delta 2$  subunit. *J Neurosci* **24**: 2440-2448, 2004.

The Internal Medicine is an Open Access article distributed under the Creative Commons Attribution-NonCommercial-NoDerivatives 4.0 International License. To view the details of this license, please visit (<https://creativecommons.org/licenses/by-nc-nd/4.0/>).