

# CASE REPORT

Nagoya J. Med. Sci. 79. 267 ~ 272, 2017  
doi:10.18999/nagjms.79.2.267

## A case of anterior communicating artery aneurysm successfully treated after a stent migration during stent assisted endovascular coil embolization

Tomotaka Ohshima<sup>1</sup>, Andrey Belayev<sup>2,3</sup>, Shunsaku Goto<sup>1</sup>, Taiki Yamamoto<sup>1</sup>,  
Kojiro Ishikawa<sup>1</sup> and Yoko Kato<sup>3</sup>

<sup>1</sup>Department of Neurosurgery, Kariya Toyota General Hospital, Aichi, Japan

<sup>2</sup>Department of Neurosurgery, Raleigh Neurosurgical Clinic, NC, USA

<sup>3</sup>Department of Neurosurgery, Fujita Health University, Banbuntane Houtokukai Hospital, Aichi, Japan

### ABSTRACT

Stent migration is a complication associated with endovascular coil embolization of intracranial aneurysms. We report a case of anterior communicating artery (ACoA) aneurysm that was successfully treated after stent migration during endovascular coil embolization without retrieval of the stent. A 47-year-old man presented with sudden onset severe headache. Patient was noted to have subarachnoid hemorrhage from a ruptured ACoA aneurysm. Emergency endovascular coil embolization was performed. The second coil embolization was scheduled for the neck-remnant portion with a stent after 16 days from the initial operation. At first, a stent was deployed from the right perpendicular division of anterior cerebral artery (A2) to the left horizontal division of anterior cerebral artery (A1) entirely across the aneurysmal neck. Although the stent position looked fine, the stent migrated inferiorly to the proximal A1 portion when its delivery wire was withdrawn. Fortunately, the stent could be pushed into the distal A1 portion, when we trying to re-access the aneurysm thorough the stent with a pig-tail shaped microguidewire. Additional coil embolization was achieved using the assistance of distal tip of the stent as a scaffold of the coil. The patient was discharged without any complication on the postoperative day 6. Although there are various choices of rescue treatment after stent migration, this is the first reported case of stent repositioning with a microguidewire. Our technique may represent an effective option in case of stent migration.

Key Words: bailout, coil embolization, intracranial aneurysms, stent migration

This is an Open Access article distributed under the Creative Commons Attribution-NonCommercial-NoDerivatives 4.0 International License. To view the details of this license, please visit (<http://creativecommons.org/licenses/by-nc-nd/4.0/>).

### INTRODUCTION

Despite recent developments in endovascular techniques and technology for coil embolization of intracranial aneurysms, one of the fundamental problems is the treatment of broad-necked aneurysms. The use of self-expandable stents with endovascular coil embolization for the broad-necked aneurysms has increased over time. Stent migration can occur as a complication of the stent deployment procedure. All of the stents which are available in Japan are not retrievable

Received: December 28, 2016; accepted: March 6, 2017

Corresponding author: Tomotaka Ohshima, MD, PhD

Department of Neurosurgery, Kariya Toyota General Hospital 5-15 Sumiyoshi-cho, Kariya, Aichi, 448 8505, Japan

Tel: +81-566-21-2450, fax: +81-566-22-2493, E-mail: tmtkoh@gmail.com

after deployment. Although some authors have reported successful retrieval of a fully deployed stent, it increases the risk of the procedure significantly.<sup>1-5)</sup> In this article we describe and discuss a unique case of anterior communicating artery aneurysm successfully treated even after stent migration during stent assisted endovascular coil embolization.

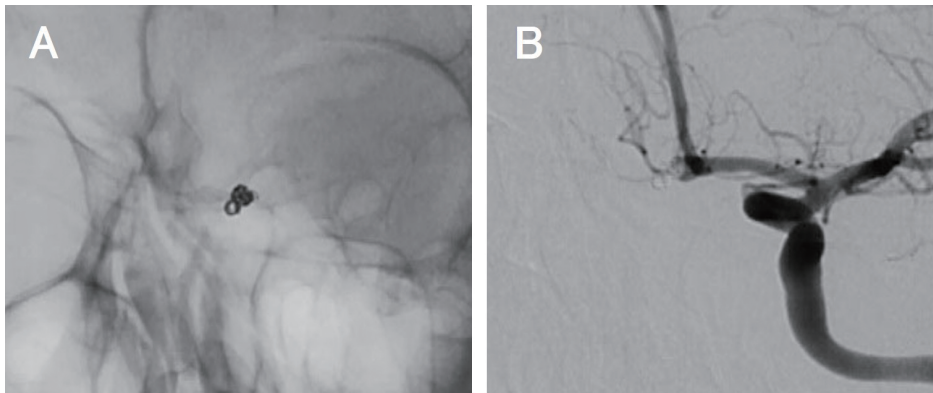
## CASE REPORT

A 47-year-old man presented with sudden onset of worst headache of his life and transferred to our emergency room. On admission, the patient had no focal deficits during neurological examination. Initial computed tomography (CT) scan showed thin subarachnoid hemorrhage into the base of the interhemispheric cistern. Three-dimensional (3D) CT angiography revealed ACoA aneurysm with a bleb. Emergency endovascular coil embolization was performed. The diagnostic 3D digital subtracted angiography (DSA) showed ACoA aneurysm of which maximum diameter was 6.0 mm with broad-neck. The initial coil embolization, which was designed to occlude the ruptured point of the aneurysm, was performed by the simple technique utilizing 4 bare platinum coils. There was no peri-procedural complications or postoperative vasospasm. Follow-up DSA was performed on postoperative day 14, revealing loose coil mass density in the bleb portion of the aneurysm (Fig. 1). We predicted that the bleb may recanalize in the future, therefore additional coiling with a stent was scheduled on postoperative day 16.

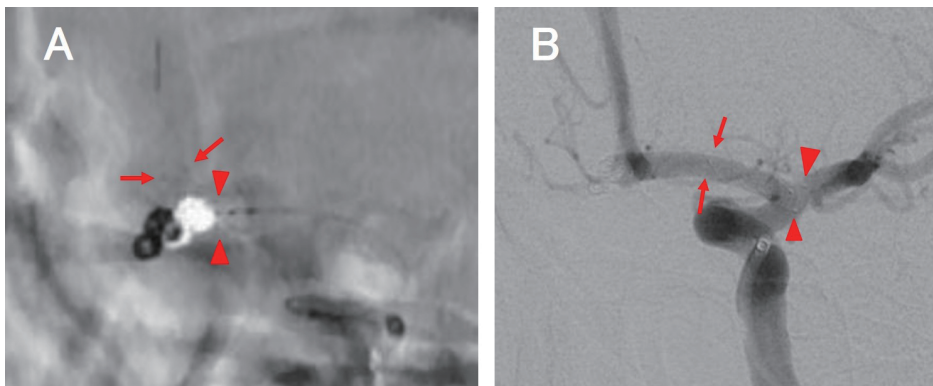
Two weeks prior to the procedure the patient was started on cilostazol at 200 mg daily, and 1 week prior to the procedure clopidogrel at 100 mg daily. Under local anesthesia, an 8F short sheath was inserted into the right femoral artery. Heparin was administered intravenously, and the activated clotting time (ACT) was maintained at 250 seconds or longer. Eight French Cello (Medtronic, Minneapolis, MN, USA) was guided to the left internal carotid artery (ICA). Four French Fubuki (Asahi Intecc, Aichi, Japan) was navigated to the supraclinoidal portion of the left internal carotid artery as a supportive intermediate catheter. Headway 17 microcatheter straight (TERUMO, Tokyo, Japan) was guided to the right A2 segment about 20 mm distal to the aneurysmal neck over a Chikai 14 microguidewire (Asahi Intecc, Aichi, Japan). Distal and proximal diameter of the parent artery were measured at 2.3 mm, we selected a LVIS Jr. stent 2.5×13 mm (TERUMO, Tokyo, Japan). The stent was deployed at the proper position with push and pull technique, however, when the delivery wire was withdrawn, the stent migrated proximally (Fig. 2). Angiogram revealed the stent was positioned between the proximal A1 segment and the ICA.

We decided to access the distal A1 segment through the true lumen of the stent with a microcatheter and microguidewire instead of capturing and retrieving the stent. The microguidewire was shaped into a pig-tail configuration. As the wire engaged the stent, the stent began to migrate accidentally from the proximal A1 to the distal A1 (Fig. 3A). The shape and size of the wire was entirely matched to fit inside the stent. We continued to push the wire and the stent until the distal flare of the stent reached into the aneurysmal neck (Fig. 3B, 3C, 4). Additional 2 bare platinum coils (HyperSoft helical 2.0×20 mm, and 1.5×20 mm (TERUMO, Tokyo)) were positioned in the aneurysm dome with the assistance of the edge of the stent that functioned as a scaffold in neck remodeling (Fig. 5).

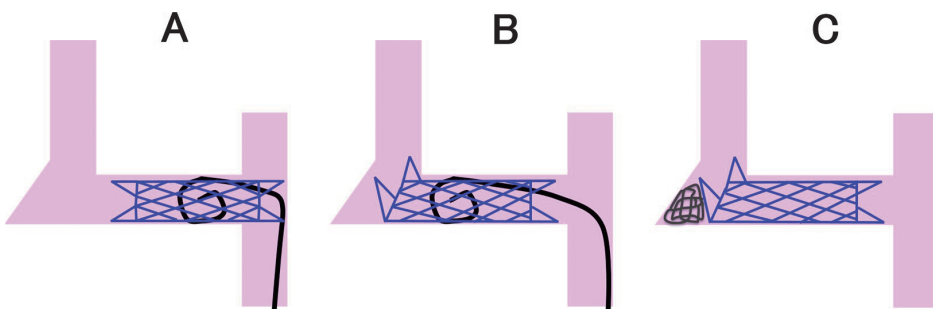
The patient demonstrated no neurological deficits and was subsequently discharged 6 days after the intervention. Magnetic resonance (MR) image at patient's 3-month follow-up revealed no aneurysm filling and patent left anterior cerebral artery.



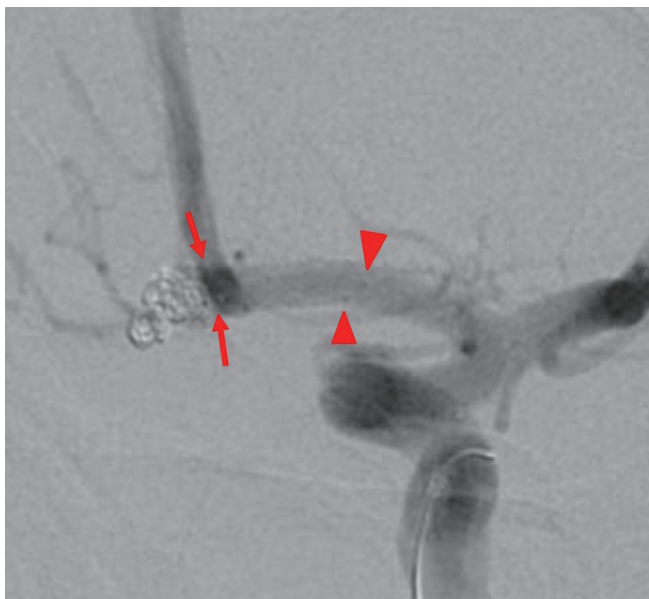
**Fig. 1:** Preoperative images showing. A: X-ray image, B: Angiography of the working angle



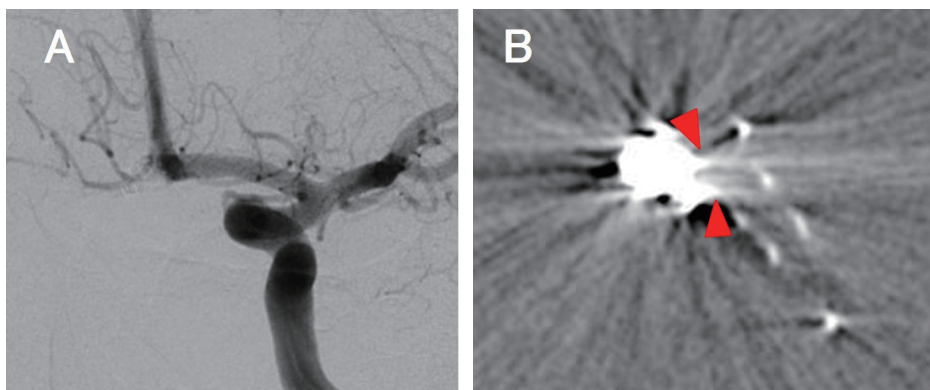
**Fig. 2:** (A) Roadmap image just after the stent deployment (arrows: stent distal marker, arrowheads: stent proximal marker) (B) Digital subtraction angiography after the delivery wire withdrawn (arrows: stent distal marker, arrowheads: stent proximal marker)



**Fig. 3:** Imaginary schematic drawings of the stent repositioning. (A) The shape and size of the wire was entirely matched to fit inside the stent. (B) We continued to push the wire and the stent until the distal flare of the stent reached into the aneurysmal neck. (C) Coils were positioned in the aneurysm dome with the assistance of the edge of the stent.



**Fig. 4:** Digital subtraction angiography after pushing the stent (arrows: stent distal marker, arrowheads: stent proximal marker)



**Fig. 5:** Postoperative images. (A) Digital subtraction angiography. (B) Cone-beam CT showing coil mass is supported by a part of stent horizontally between two arrowheads.

## DISCUSSION

Stent-assisted coil embolization is a common treatment strategy for intracranial aneurysms. Various types of stent misplacement, such as stent distal migration due to foreshortening or jumping, proximal migration, distortion, incomplete opening, and herniation into the aneurysm, can occur as a complication of the stent deployment procedure. The causes of the stent migration have not been discussed in the literature. In our case, the stent size that was selected was too small for the parent vessel, additionally the radial force of LVIS Jr. stent is lower than other stents such as Neuroform and Enterprise. The angle of the parent artery between the A2 and A1

is relatively sharp, the delivery wire can catch on the stent during withdrawal.

When stent migration occurs, leaving it at the new position is the best option if possible. When the stent distortion or incomplete opening occurs, intraluminal balloon stent-plasty can be utilized. Rarely, telescopic or overlapping stent deployment may be required to gain the patency of the parent artery. Rescue retrieval of the stent should be selected as the last resort. Rescue retrieval of deployed intracranial stent have been reported previously in the literature, however, there are few case reports.<sup>1-5)</sup> Fatal vessel injuries may occur if the stent is broken during the retrieval. In our case, we attempted to re-access the A2 segment through the stent that was positioned in the A1 segment with a plan of putting another bridging stent. The microguidewire was shaped in a pig-tail configuration to assist in gaining access to the true lumen of the stent and chance of vascular injury. Because the pig-tail shape of wire the stent could be advanced with the distal flare reaching into the aneurysmal neck. This phenomenon occurred accidentally. When we noticed that the stent was moved under our control, we seemed to be able to choose two options. First, we could put the proximal flare of the stent back in the A1 trunk, because it might disturb the blood flow into the middle cerebral artery. Second, we could use the stent with assistance of coil insertion again, if possible. In this case, it was relative safe to push back the stent as the previous coil mass worked protective against an aneurysmal perforation.

Additional coils were deployed into the aneurysm dome with the assistance of the stent edge as a scaffold in neck remodeling. We initially thought that this procedure was the waffle-cone technique which has been reported in the past as not reliable to support coils over the long term.<sup>6-8)</sup> In this technique the end of the stent holds coils in place perpendicularly. Coil mass is supported with the whole edge of the stent like an ice cream. However, postoperative cone-beam CT revealed that additional coils were supported by the part of the stent horizontally (Fig. 5). Assistance of the coil deployment with the part of the stent or the stent flare has been reported by our center as a half-bridge stenting method and an alpha horizontal stent delivery technique.<sup>9-10)</sup> The durability of coiling over long time period has been demonstrated in these studies. Although we confirmed that a few struts of a stent were enough durable to support coil mass, the flare of LVIS Jr. might be more fragile than other stents. We should select softer coils compared with the usual stent-assist coil embolization.

If we could not re-access the distal side of the stent, we would have to retrieve the stent. As the proximal flare of the stent was protruding into the ICA, its retrieval would be performed utilizing a 4-mm Amplatzer Gooseneck microsnare loop device. We would then select a large sized stent to complete the aneurysm embolization.

## CONCLUSIONS

There are various choices of rescue treatments after stent migration. To the best of our knowledge, this is the first reported case of ACoA aneurysm successfully treated post stent proximal migration with a specially shaped microguidewire during stent assisted endovascular coil embolization. Our technique might be an effective option in case of stent migration.

## ACKNOWLEDGEMENTS

The authors have no personal financial or institutional interest in any of the drugs, materials, or devices in the article.

## REFERENCES

- 1) Eggebrecht H, Haude M, von Birgelen C, Oldenburg O, Baungart D, Herrmann J, *et al.* Nonsurgical retrieval of embolized coronary stents. *Catheter Cardiovasc Interv*, 2000; 51: 432–440.
- 2) Oh Y, Hwang DH, Ko YH, Nang IW, Kim IS, Hur CW. Foreign body removal by snare loop: during intracranial stent procedure. *Neurointervention*, 2012; 7: 50–53.
- 3) Mitchell B, Lou LD, Mawad M, Retrieval of distorted pipeline embolic device using snare-loop. *J Vasc Interv Neurol*, 2014; 7: 1–4.
- 4) Chen M, Smith LG. Endovascular rescue of a misshapen intracranial stent: report of two cases. *J Neurointerv Surg*, 2011; 3: 25–26.
- 5) Barbuoblu M, Aydin K. Rescue retrieval of a fully deployed low-profile intracranial stent after acute occlusion. *World Neurosurg*, 2016; 85: 349–352.
- 6) Hauck EF, Natarajan SK, Hopkins LN, Levy EI, Siddiqui AH. Salvage Neuroform stent-assisted coiling for recurrent giant aneurysm after waffle-cone treatment. *J Neurointerv Surg*, 2011; 3: 27–29.
- 7) Sychra V, Klisch J, Werner M, Dettenborn C, Petrovitch A, Strasilla C, *et al.* Waffle-cone technique with Solitaire™ AB remodeling device: endovascular treatment of highly selected complex cerebral aneurysms. *Neuroradiology*, 2011; 53: 961–972.
- 8) Xu F, Qin X, Tian Y, Gu Y, Leng B, Song D. Endovascular treatment of complex intracranial aneurysms using intra/extra-aneurysmal stent. *Acta Neurochir (Wien)*, 2011; 153: 923–930.
- 9) Ohshima T, Nagakura M, Tajima H, Nishizawa T, Kato K. Aneurysmal neck plasty in broad-necked aneurysms with a unilateral partial stent reconstruction: half-bridge stenting method. *JNET*, 2014; 8: 172–178.
- 10) Ohshima T, Nagakura M, Nishizawa T, Kato K. Alpha horizontal stent delivery for coil embolization of a broad-necked large basilar apex aneurysm: a case report. *Nagoya J Med Sci*, 2015; 77: 659–665.