



Contents lists available at ScienceDirect

## International Journal of Surgery Case Reports

journal homepage: [www.casereports.com](http://www.casereports.com)

# Simultaneous bilateral dual mobility total hip arthroplasty dislocation in a patient with hepatic encephalopathy: A case report

Oriol Pujol<sup>a,\*</sup>, Iñaki Mimendia<sup>a,b</sup>, Lidia Martin-Dominguez<sup>d</sup>, Carles Amat<sup>a,c</sup>, Víctor Barro<sup>a,b</sup>

<sup>a</sup> Orthopedic Surgery Department, Vall d'Hebron University Hospital, Barcelona, Spain

<sup>b</sup> Hip Surgery Unit, Orthopedic Surgery Department, Vall d'Hebron University Hospital, Barcelona, Spain

<sup>c</sup> Septic and Reconstructive Surgery Unit, Orthopedic Surgery Department, Vall d'Hebron University Hospital, Barcelona, Spain

<sup>d</sup> Orthopedic Surgery Department, Dexeus University Hospital, Barcelona, Spain

## ARTICLE INFO

## Article history:

Received 3 February 2021

Received in revised form 23 February 2021

Accepted 23 February 2021

Available online 25 February 2021

## Keywords:

Case report

Bilateral

Dual mobility

Dislocation

Myoclonus

Hepatic encephalopathy

## ABSTRACT

**INTRODUCTION AND IMPORTANCE:** Dislocation is a severe complication after total hip arthroplasty (THA). It is one of the most common reasons for failure and revision surgery. This is the first case of a documented simultaneous bilateral dual mobility (DM) THA dislocation.

**CASE PRESENTATION:** A forty-nine-year-old man presented with bilateral hip pain, immobility and deformity. X-ray images demonstrated simultaneous bilateral posterior THA dislocation. Previously, the patient had presented atraumatic dislocations recurrently. When he was thoroughly re-interrogated, he complained of uncontrolled and generalized muscle contractions, which were compatible with myoclonus due to hepatic encephalopathy (HE). Multidisciplinary treatment was performed satisfactorily to control myoclonus symptomatology and to prevent dislocation.

**CLINICAL DISCUSSION:** Patient's most important risk factor was a neuromuscular disorder, which we initially gave little notice and undervalued. HE is a serious but reversible syndrome, observed in patients with liver dysfunction. It leads to a wide spectrum of neuropsychiatric abnormalities. Management is based on prevention of episodes, avoiding the underlying triggers.

Due to the high risk for dislocation of our patient, we decided to use DM cups bilaterally. This system has demonstrated lower rates of dislocation.

**CONCLUSION:** This case report reminds us that a careful evaluation through meticulous history and physical examination are mandatory when faced with recurrent instability. Furthermore, prevention of dislocation is vastly preferable to treating this challenging complication. High-risk patients should be identified, and appropriate surgical approach, technique and implants have to be collectively used to reach a strategy that mitigates and ideally prevents dislocation.

© 2021 The Author(s). Published by Elsevier Ltd on behalf of IJS Publishing Group Ltd. This is an open access article under the CC BY-NC-ND license (<http://creativecommons.org/licenses/by-nc-nd/4.0/>).

## 1. Introduction and importance

Although total hip arthroplasty (THA) is considered one of the most successful orthopedic surgeries, severe complications such as dislocation can occur. The incidence of hip dislocation after primary THA ranges from 1% to 10%, and is as high as 28% with revision THA [1,2]. It is one of the most common reasons for failure and revision surgery in the first postoperative years, affecting joint function and patient satisfaction [3].

Multiple risk factors have been reported, neurological impairment among them [1,2,4,5]. Hepatic encephalopathy (HE) is a

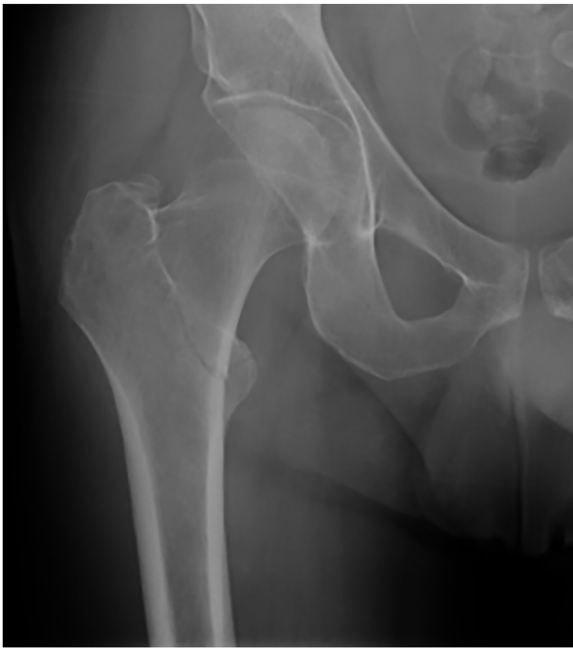serious but reversible syndrome, frequently observed in patients with advanced liver dysfunction, and leading to a wide spectrum of neuropsychiatric abnormalities (confusion, asterixis, myoclonus, etc.) [6].

Non-operative treatment of dislocation (closed reduction) should be considered first. It is indicated in first-time episodes with no signs of underlying instability [2]. On the other hand, revision surgery is recommended when instability is clearly present [1,7]. Different operative strategies can be used in revision surgeries or in high-risk primary THAs [8,9]. One of these options is use of a dual mobility (DM) cup.

We present the first report of a documented simultaneous bilateral DM-THA dislocation. It is a complex case, involving fracture, infection and mechanical complications, and ending in this unusual and severe scenario. Patient's recurrent and bilateral dislocations were attributed to his uncontrolled muscular contractions

\* Corresponding author at: Orthopedic Surgery Department, Vall d'Hebron University Hospital, Universitat Autònoma de Barcelona, Pg. Vall d'Hebron 119-129, 08035 Barcelona, Spain.

E-mail address: [opujol@vhebron.net](mailto:opujol@vhebron.net) (O. Pujol).



**Fig. 1.** Nondisplaced intertrochanteric right fracture, subsequent to a low-energy trauma.

(myoclonus) due to HE. We discuss the clinical relevance of this novel case.

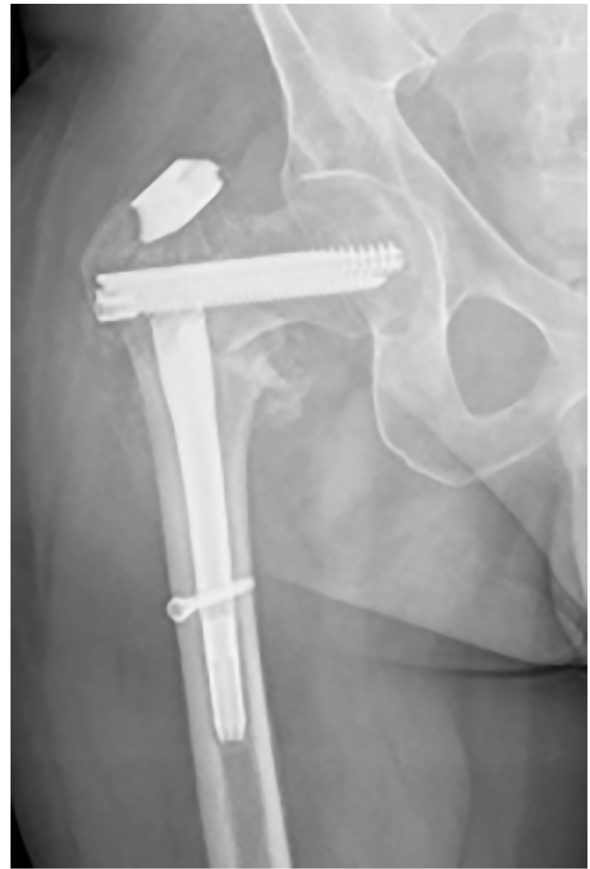This case has been reported in line with the SCARE criteria [10].

## 2. Case presentation

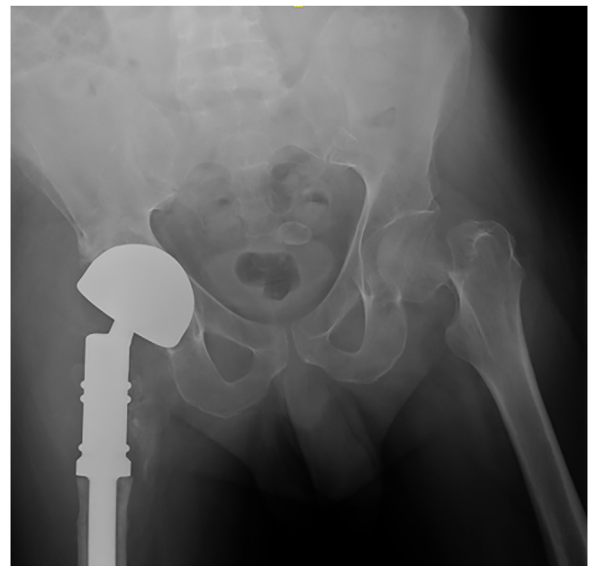In 2014, a forty-five-year-old man presented to our emergency room with an intertrochanteric right fracture, subsequent to a low-energy trauma (Fig. 1). He suffered from multiple medical comorbidities; highlighted among them were liver transplantation due to cirrhosis, poorly controlled diabetes with peripheral neuropathy, ex-alcoholism and smoking. He had not had any previous orthopedic pathology. As soon as the patient could be medically optimized and surgery planned, a short intramedullary hip screw was placed.

Two years later, he presented to a routine control visit with hip pain, after hearing a “crack” some days before. X-ray images showed a fatigue fracture (Fig. 2). Following our hospital’s protocol, a biopsy and culture was done to rule out septic pseudoarthrosis. A coagulase-negative staphylococcus (*S. epidermidis*) was found. Consequently, it was necessary to perform a two-stage surgery. In the first stage, after a thorough debridement, an antibiotic-loaded cement spacer was implanted. After one month, the patient suffered a posterior spacer dislocation without an associated traumatic event. The dislocation was satisfactorily treated with closed reduction. Unfortunately, the patient presented with four more similar spacer dislocations. Finally, the second stage was performed. Due to the aggressiveness of the infection and the multiple debridement, the proximal femur presented a severe loss of bone stock. In consequence, a silver-coated proximal femur megaprosthesis was implanted (MUTARS®; Implantcast GmbH, Germany), using a cementless stem with a DM cup. Abductor mechanism reconstruction was done, suturing the stumps directly to the megaprosthesis. Intraoperative cultures were negative.

One year later, the patient appeared with a posterior hip arthroplasty dislocation, which was treated with a closed reduction. During hospitalization, he suffered a fall from his own height and presented a contralateral subcapital femoral neck fracture (Fig. 3). A THA (H-Max®; Lima, Italy) was implanted through a posterior



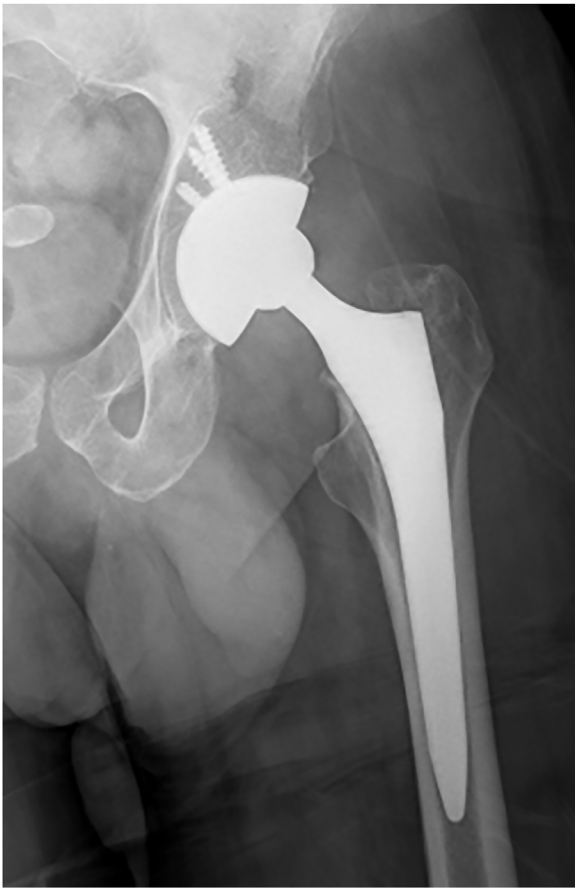**Fig. 2.** X-ray images demonstrating a fatigue fracture. It was presumably caused by chronic infection and fracture non-union.



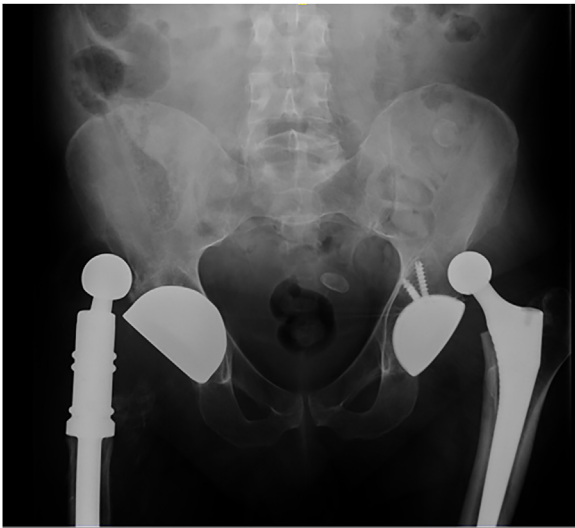
**Fig. 3.** Left subcapital femoral neck fracture after a low-energy trauma. In the contralateral hip, the silver-coated proximal femur megaprosthesis using a cementless stem with a dual mobility cup (MUTARS®; Implantcast GmbH, Germany) is correctly positioned.

approach, using a cementless stem and DM cup (Fig. 4). Two months after surgery, the patient suffered his first posterior dislocation in the left primary arthroplasty. It was resolved non-operatively.

Two months later, the patient was once again admitted to our center. On this occasion, he presented bilateral hip pain, immobil-



**Fig. 4.** The subcapital femoral neck fracture has been operated through a THA (H-Max®; Lima, Italy), using a cementless stem and dual mobility cup.



**Fig. 5.** Simultaneous bilateral dual mobility THA dislocation.

ity and deformity. His symptomatology had begun during sleep, without trauma. A simultaneous bilateral posterior DM-THA dislocation had occurred (Fig. 5). Closed reduction under anesthesia was achieved in the left primary prosthesis. However, it was unsuccessful in the right proximal femur megaprosthesis, so it required open reduction. During the reduction surgery, the femoral head and liner were exchanged.

Since the patient was presenting bilateral atraumatic dislocations recurrently, risk factors were more thoroughly studied. After performing a CT-scan, the arthroplasties were found to be correctly implanted within the safe zone, and offsets were also correct. Intra-prosthetic dislocation was also ruled out. The hip abductor mechanism was functional at clinical examination, presenting a negative Trendelenburg test. However, when the patient was re-interrogated, he described uncontrolled and generalized muscle contractions. These contractions were thought to be compatible with myoclonus due to HE. Thus, his recurrent and bilateral dislocations were attributed to this neuromuscular disorder.

In consequence, multidisciplinary treatment was begun to control myoclonus symptomatology and to prevent dislocation. The neurology department performed an MRI of the brain and an electroencephalogram, ruling out other possible severe etiologies such as epilepsy. The internists optimized his medical comorbidities, focusing on hepatic dysfunction and poorly controlled diabetes. Management of HE is based on the prevention of episodes, so avoiding the underlying triggers became the principal objective.

After twenty-six months of follow-up, no more complications have occurred and no signs of infection relapse have appeared. The patient refers an improvement in the control of his myoclonus symptomatology. He presents no pain, and is able to walk with the support of two crutches, though he needs a wheelchair for long distances.

### 3. Clinical discussion

Hip instability is a severe complication, which presents a multifactorial etiology [11]. Our patient's most important risk factor was a neuromuscular disorder, which we initially gave little notice and undervalued. When the patient was thoroughly re-interrogated, he complained of uncontrolled and generalized muscle contractions. Hepatic dysfunction after liver transplant could cause an HE, expressed in myoclonus.

HE is a serious but reversible syndrome, frequently observed in patients with advanced liver dysfunction. This metabolic disorder is caused by the accumulation of neurotoxic substances in the brain, leading to a wide spectrum of neuropsychiatric abnormalities, such as confusion, bradyphrenia, somnolence, asterixis, rigidity or myoclonus. Triggers of this encephalopathy include renal failure, gastrointestinal bleeding, constipation, infection, dehydration, excessive dietary protein intake and consumption of alcohol or opioids. Management is based on prevention of episodes, avoiding the underlying triggers. Thus, lifestyle changes and education are mandatory. When an episode occurs, general measures like empiric antibiotics, hydration, osmotic laxatives, and reduction of drugs doses should be considered [6].

With the aim of reducing risk of dislocation, several operative strategies exist. Such options include implant positioning, constrained implant, increased head size, reconstruction of abductor mechanism or use of DM cup. Anterior approaches are also associated with a favorable dislocation rate, as demonstrated by Sheth et al. [12] after studying 22,237 primary THAs (0.4%, 0.8% and 1.4% dislocation rate using the anterolateral, direct anterior and posterior approaches respectively). We performed patient's surgeries through a posterior approach because, at that moment, it was the usual approach for THA in our center. Currently, as we have more experience using the direct anterior approach, we recommend to use it due to its low dislocation rate.

Due to the high risk for dislocation of our patient, we decided to use DM cups bilaterally. It provides increased range of movement and head-neck ratio, a larger effective head size and a greater jump distance, leading to high stability. The DM system has demonstrated lower rates of dislocation and need for revision due to

dislocation in both primary and revision THAs [13–15]. In a systematic review, significantly fewer primary THA dislocations were found in the DM group (0.2% vs 7.1%;  $p = 0.009$ ) [13]. Dislocation rate in revision THA can be as high as 28% [1], and revision THA performed after recurrent instability can reach a re-dislocation rate of 35% [16]. However, Unter Ecker et al. [17] performed 327 complex revision THAs using a DM cup, demonstrating a lower dislocation rate (11%). Besides, Li et al. [15] studied 267 revision THAs and showed that patients who received a DM liner had lower rates of dislocation (OR 0.12,  $p = 0.019$ ). In another meta-analysis studying 2408 THAs, Romagnoli et al. [18] arrived at similar conclusions regarding both primary and revision THAs (RR 0.15 and 0.19 respectively).

Nevertheless, concerns do exist regarding the additional modularity and the risk of intraprostatic dislocation. Beyond the classic hard-on-soft articulation there is a second soft-on-hard coupling, with the polyethylene liner articulating with the metallic acetabular component. Although this could lead to an accelerated wear, osteolysis and aseptic loosening, no implications of higher failure rates have been demonstrated (specifically in highly cross-linked polyethylene liners) [13,15,18,19]. On the other hand, intraprostatic dislocation is a new mode of failure relatively rare, and limited mainly to earlier designs. Its incidence ranges between 0.7%–1.1% in primary THA, and 0.3%–1.3% in revision THA [19,20]. However, this complication requires open reduction and additional surgery [15].

#### 4. Conclusions

This is the first case of a documented simultaneous bilateral DM-THA dislocation. Patient's unnoticed neuromuscular disorder eventually proved to be the key to the problem. This case report reminds us that a careful evaluation through meticulous history and physical examination are mandatory when faced with recurrent instability. Furthermore, prevention of dislocation is vastly preferable to treating this challenging complication. High-risk patients should be identified, and appropriate surgical approach, technique and implants have to be collectively used to reach a strategy that mitigates and ideally prevents dislocation.

#### Declaration of Competing Interest

The authors report no declarations of interest.

#### Funding

This research did not receive any specific grant from funding agencies in the public, commercial, or not-for-profit sectors.

#### Ethical approval

We consulted our Center's Ethics Committee (CEIC). Due to the nature of our study, it was exempt from specific ethical approval in our institution.

#### Consent

Written informed consent was obtained from the patient for publication of this case report and accompanying images. A copy of the written consent is available for review by the Editor-in-Chief of this journal on request.

#### Authors contribution

All authors contributed equally to this work: design of the study, data recollection, statistical analysis and writing of the manuscript. All authors read and approved the final manuscript.

#### Registration of research studies

Not Applicable.

#### Guarantor

Oriol Pujol.

#### Provenance and peer review

Not commissioned, externally peer-reviewed.

#### Acknowledgements

We wish to thank Russell Williams of RoundlyWorded.com for his editorial recommendations.

#### References

- [1] Y. Lu, H. Xiao, F. Xue, Causes of and treatment options for dislocation following total hip arthroplasty (Review), *Exp. Ther. Med.* 18 (July (3)) (2019) 1715–1722.
- [2] A.M. Saiz, Z.C. Lum, G.C. Pereira, Etiology, evaluation, and management of dislocation after primary total hip arthroplasty, *JBJS Rev.* 7 (July (3)) (2019) e7.
- [3] J. Dargel, J. Oppermann, G.-P. Brüggenmann, P. Eysel, Dislocation following total hip replacement, *Dtsch Arzteblatt Online [Internet]* 111 (December (51–52)) (2014) 884–890, Available from: <https://www.aerzteblatt.de/10.3238/arztebl.2014.0884>.
- [4] A.J. Rondon, T.L. Tan, P.K. Schlitt, M.R. Greenky, J.L. Phillips, J.J. Purtill, Total joint arthroplasty in patients with Parkinson's disease: survivorship, outcomes, and reasons for failure, *J. Arthroplasty* 33 (April (4)) (2018) 1028–1032.
- [5] K.T. Aziz, M.J. Best, Z. Naseer, R.L. Skolasky, K.E. Ponnusamy, R.S. Sterling, et al., The association of delirium with perioperative complications in primary elective total hip arthroplasty, *Clin. Orthop. Surg.* 10 (3) (2018) 286.
- [6] C.F. Rose, P. Amodio, J.S. Bajaj, R.K. Dhiman, S. Montagnese, S.D. Taylor-Robinson, et al., Hepatic encephalopathy: novel insights into classification, pathophysiology and therapy, *J. Hepatol.* 73 (December (6)) (2020) 1526–1547.
- [7] S. Masiewicz, A. Mabrouk, D.E. Johnson, Posterior hip dislocation, in: *StatPearls [Internet]*, StatPearls Publishing, Treasure Island (FL), 2020 [cited 2020 Nov 14]. Available from: <http://www.ncbi.nlm.nih.gov/books/NBK459319/>.
- [8] S.A. Jones, The prevention and treatment of dislocation following total hip arthroplasty: efforts to date and future strategies, *Hip Int.* 25 (July (4)) (2015) 388–392.
- [9] J.-L. Charissoux, Y. Asloum, P.-S. Marcheix, Surgical management of recurrent dislocation after total hip arthroplasty, *Orthop. Traumatol. Surg. Res.* 100 (February (1)) (2014) S25–S34.
- [10] R.A. Agha, T. Franchi, C. Sohrabi, G. Mathew, for the SCARE Group, The SCARE 2020 guideline: updating consensus surgical CAse REport (SCARE) guidelines, *Int. J. Surg.* 84 (2020) 226–230.
- [11] F.E. Rowan, B. Benjamin, J.R. Pietrak, F.S. Haddad, Prevention of dislocation after total hip arthroplasty, *J. Arthroplasty* 33 (May (5)) (2018) 1316–1324.
- [12] D. Sheth, G. Cafri, M.C.S. Inacio, E.W. Paxton, R.S. Namba, Anterior and anterolateral approaches for THA are associated with lower dislocation risk without higher revision risk, *Clin. Orthop.* 473 (November (11)) (2015) 3401–3408.
- [13] R.C. Jonker, L.W.A.H. van Beers, B.C.H. van der Wal, H.C. Vogely, S. Parratte, R.M. Castelein, et al., Can dual mobility cups prevent dislocation without increasing revision rates in primary total hip arthroplasty? A systematic review, *Orthop. Traumatol. Surg. Res.* 106 (May (3)) (2020) 509–517.
- [14] Y.T. Kim, J.-H. Yoo, M.K. Kim, S. Kim, J. Hwang, Dual mobility hip arthroplasty provides better outcomes compared to hemiarthroplasty for displaced femoral neck fractures: a retrospective comparative clinical study, *Int. Orthop.* 42 (June (6)) (2018) 1241–1246.
- [15] W.T. Li, Z. Kozick, M. Sherman, C. Restrepo, E.B. Smith, P.M. Courtney, Dual mobility bearing articulations result in lower rates of dislocation after revision total hip arthroplasty, *J. Am. Acad. Orthop. Surg.* 28 (October (20)) (2020) 831–837.

- [16] S. Jo, J.H. Jimenez Almonte, R.J. Sierra, The cumulative risk of re-dislocation after revision THA performed for instability increases close to 35% at 15years, *J. Arthroplasty* 30 (July (7)) (2015) 1177–1182.
- [17] N. Unter Ecker, H. Kocaoğlu, A. Zahar, C. Haasper, T. Gehrke, M. Citak, What is the dislocation and revision rate of dual-mobility cups used in complex revision THAs? *Clin. Orthop.* (September (2)) (2020).
- [18] M. Romagnoli, A. Grassi, G.G. Costa, L.E. Lazaro, M. Lo Presti, S. Zaffagnini, The efficacy of dual-mobility cup in preventing dislocation after total hip arthroplasty: a systematic review and meta-analysis of comparative studies, *Int. Orthop.* 43 (May (5)) (2019) 1071–1082.
- [19] I. De Martino, R. D'Apolito, V.G. Soranoglou, L.A. Poultsides, P.K. Sculco, T.P. Sculco, Dislocation following total hip arthroplasty using dual mobility acetabular components: a systematic review, *Bone Jt J.* 99-B (January (1\_Supple\_A)) (2017) 18–24.
- [20] B. Darrith, P.M. Courtney, C.J. Della Valle, Outcomes of dual mobility components in total hip arthroplasty: a systematic review of the literature, *Bone Jt J.* 100-B (January (1)) (2018) 11–19.

#### Open Access

This article is published Open Access at [sciencedirect.com](https://www.sciencedirect.com). It is distributed under the [IJSCR Supplemental terms and conditions](#), which permits unrestricted non commercial use, distribution, and reproduction in any medium, provided the original authors and source are credited.