

# Reconstructive Surgery in a Patient with High Radial Nerve Palsy Using the WALANT Technique

Homid Fahandezh-Saddi Díaz,  
MD, PhD\*†  
Fátima Bebea Zamorano, MD\*  
Jorge Enrique Ruiz Zafra, MD\*  
Antonio Ríos Luna, MD, PhD‡  
María Elena Cantero Yübero, MD§  
Donald H. Lalonde, MD, MSc,  
FRCS¶

**Summary:** Tendon transfers can be tied too tight or too loose. Both impede good function after surgery. Performing tendon transfers without sedation and pain during the surgery and then watching the patient move the transfer have helped us adjust the tension more accurately. This method can be applied to complex transfers such as radial nerve palsy triple tendon transfers. We describe the technique and results of a triple tendon transfer using wide-awake local anesthesia no tourniquet in a patient with a high radial nerve palsy. This was a complex case of reconstruction after five operations at the level of the humerus. This left him with a pseudoarthrosis of the humerus and a complete radial nerve palsy. We performed tendon transfers of pronator teres to extensor carpi radialis brevis, flexor carpi ulnaris to extensor digitorum communis, and palmaris longus to extensor pollicis longus tendons. Eighteen months after the triple tendon transfer surgery for the radial nerve palsy, the patient has good extension of the fingers, wrist, and thumb. He can open and close the hand properly. He has excellent function and mobility allowing him to perform most activities in a manner that is practically normal. Wide-awake local anesthesia no tourniquet can be used safely and successfully in complex cases requiring triple radial nerve tendon transfers of pronator teres to extensor carpi radialis brevis, flexor carpi ulnaris to extensor digitorum communis, and palmaris longus to extensor pollicis longus tendons. (*Plast Reconstr Surg Glob Open* 2022;10:e4500; doi: [10.1097/GOX.0000000000004500](https://doi.org/10.1097/GOX.0000000000004500); Published online 14 September 2022.)

The wide-awake local anesthesia no tourniquet (WALANT) technique has been a topic of growing interest in the literature. The possibility of performing invasive surgery with preservation of intraoperative active motion of reconstructed structures has expanded the field of action in the world of hand surgery.

In recent reviews of the WALANT technique, Lalonde<sup>1</sup> and Kurtzman et al<sup>2</sup> confirm the overall impact of this technique.

From the \*Hand and Upper Extremity Surgery Unit, Hospital Universitario Fundación Alcorcon, Madrid, Spain; †Clínica AVANFI, Madrid, Spain; ‡Clínica Doctor Antonio Ríos Luna, Almería, Spain; §Family Doctor Área Oeste, CL Arroyomolinos, Madrid, Spain; and ¶Dalhousie University, Saint John, New Brunswick, Canada.

Received for publication April 13, 2022; accepted July 11, 2022.

Copyright © 2022 The Authors. Published by Wolters Kluwer Health, Inc. on behalf of The American Society of Plastic Surgeons. This is an open-access article distributed under the terms of the Creative Commons Attribution-Non Commercial-No Derivatives License 4.0 (CCBY-NC-ND), where it is permissible to download and share the work provided it is properly cited. The work cannot be changed in any way or used commercially without permission from the journal.

DOI: [10.1097/GOX.0000000000004500](https://doi.org/10.1097/GOX.0000000000004500)

The aim of this article is to describe the WALANT treatment of a high radial nerve palsy with complex triple tendon transfers.

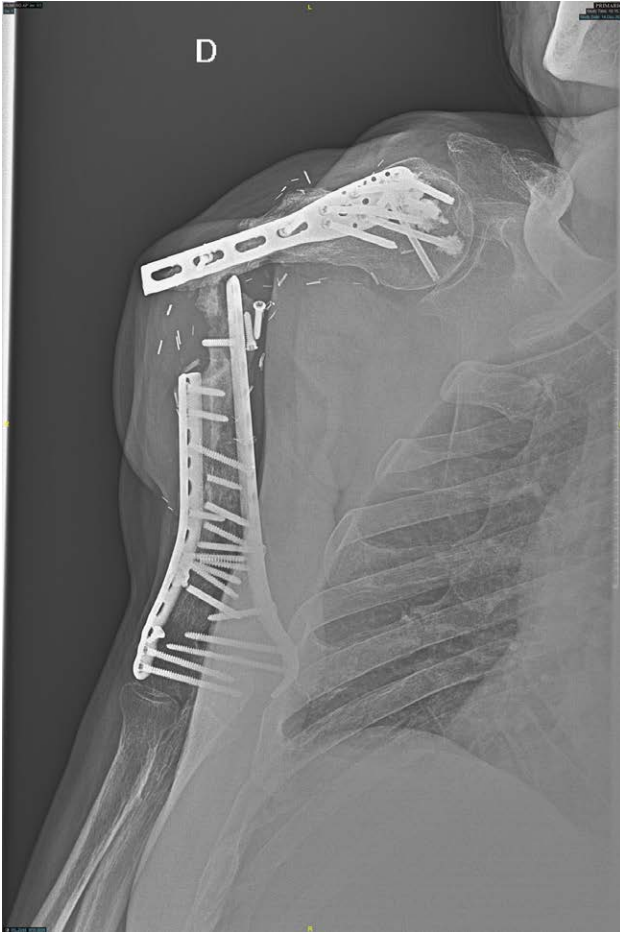## CASE DESCRIPTION

A 66-year-old man was diagnosed with a myxoid liposarcoma affecting the right medial deltoid muscle belly. Four years after the initial resection, the patient developed intraosseous recurrence and underwent radical resection surgery with allograft in the proximal humerus. The patient developed pseudoarthrosis, which led to a further three surgical interventions. He did not achieve consolidation of the humerus (Fig. 1), and he sustained a radial nerve injury at the level of the radial sulcus with a high radial nerve palsy.

He had pain-free mobility with elbow flexion and extension preserved. He had a complete absence of function of the brachioradialis, extensor carpi radialis longus (ECRL), extensor carpi radialis brevis (ECRB), extensor digitorum communis (EDC), extensor pollicis longus (EPL), abductor pollicis longus, and extensor index propius.

**Disclosure:** The authors have no financial interest to declare in relation to the content of this article.

Related Digital Media are available in the full-text version of the article on [www.PRSGlobalOpen.com](http://www.PRSGlobalOpen.com).



**Fig. 1.** Recalcitrant pseudoarthrosis of the middle third of the shaft of the humerus (1b).

### DESCRIPTION OF WALANT TECHNIQUE

Physiological saline solution of 150 cc was mixed with 50 ml of 1% lidocaine with 1:100,000 epinephrine and 5 ml of 8.4% bicarbonate to obtain 205 ml of solution available for injection.

We infiltrated from proximal to distal, until the subcutaneous cellular tissue was visibly tumesced 2 cm beyond any area of dissection.

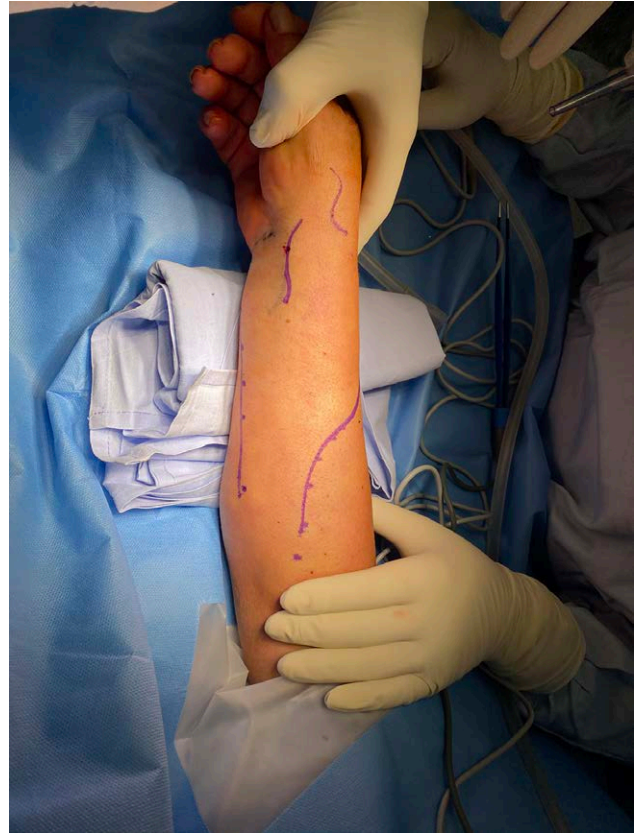Five surgical areas were sequentially infiltrated (Fig. 2).

The pronator teres (PT) muscle was infiltrated along the path of its superficial head, by injecting 40 cc of solution subcutaneously up to and including its bony insertion on the radius.

Subcutaneous tumescence was achieved with 40 ml over the EDC, EPL, and ECRB from proximal to the extensor retinaculum to the wrist. The soft tissue over the ECRB was injected proximally enough to cover the zone of suturing PT to ECRB.

A further 40 ml of local anesthesia was injected over the entire dissection path of the flexor carpi ulnaris (FCU) for its transfer over the ulna.

Finally, 30 ml was infiltrated in the volar and radial border of the wrist where the palmaris longus (PL) to EPL transfer was performed.



**Fig. 2.** Different surgical areas approached, a total of five, are sequentially infiltrated to perform the surgical transfer technique.

### SURGICAL TECHNIQUE

The surgical procedure commenced 30 minutes after injection of the anesthetic solution. The intervention was performed on a surgical hand table, without a tourniquet.

We began with a curvilinear incision over the PT. The PT tendon was identified where it inserts on the radius and was detached with a periosteal strip (1 cm wide and 2–3 cm long). Then, the tendon was prepared for transfer to the ECRB.

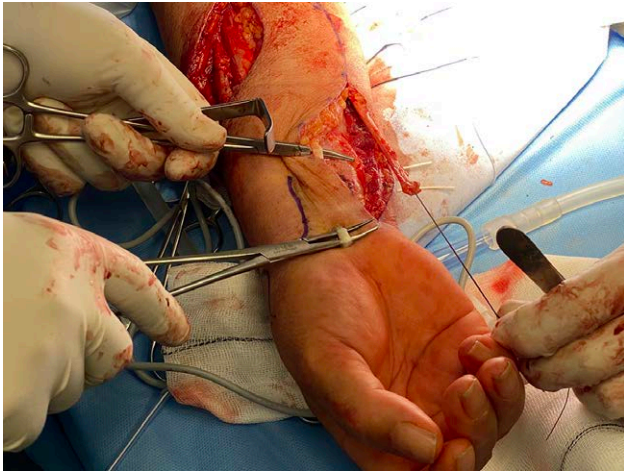
Next, the EDC and extensor digiti minimi tendons were identified and freed of adhesions.

The palmar approach centered over FCU and PL was performed. The FCU tendon was detached proximal to the pisiform, and its muscular part was elevated and routed along the ulnar border until it reached the dorsal region for transfer to the EDC. Before the transfer, the FCU tendon was split into two tendinous hemitendons. Using the same volar approach, the PL tendon was identified and sectioned distally, releasing the tendon and muscle belly sufficiently to perform the transfer (Fig. 3).

The EPL was sectioned proximal to the extensor retinaculum, recovered in the anatomical snuffbox, and passed through a subcutaneous tunnel volarly and radially for the tendon transfer with the PL.

The tendon transfer order was as follows:

- Transfer of PT to ECRB by weaving the periosteal sheet of the PT through the ECRB using the



**Fig. 3.** Palmaris longus and FCU tendon are identified and sectioned distally.

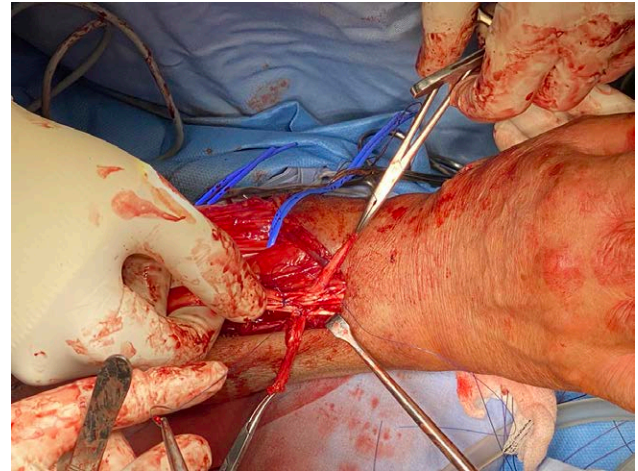
Pulvertaft method (2–3 times), with the wrist maintained in 45-degree extension.

- Transfer of the FCU hemitendon through the EDC. Before performing the transfer, the volar and ulnar wound was closed. After sewing all four EDC tendons together, one of the FCU hemitendons was passed through an opening for each of the EDC tendons (Fig. 4). Finally, to reinforce the repair, the transfer was covered with the second hemitendon using a 3/0 nylon monofilament suture. The dorsal wrist wound was closed.
- Transfer of PL to EPL: On the volar and radial aspect of the wrist (Z-shaped incision), and in a position of maximum tension of the PL and EPL tendons, a Pulvertaft suture was performed. After the first loop, the tension of the transfer was tested, and we continued with four more loops of Pulvertaft weave.

In all the transfers performed, objective evidence of satisfactory transfer tension was obtained by asking the patient to extend his wrist, fingers, and thumb, and he was delighted to see it. The surgeon was able to see that the tendon transfers were solid and of the right tension before the skin was closed. The duration of the surgery was 210 minutes, without at any time resulting in a sensation of pain. (See Video [online], which displays the final results of the reconstructive surgery with triple tendon transfer. When all the transfers were performed, objective evidence of satisfactory transfer tension was obtained by asking the patient to extend his wrist, fingers, and thumb.)

The transfers were protected by an above-elbow thermoplastic splint (4 weeks) with wrist in 20 degrees of extension, metacarpophalangeal joints in full extension, and proximal interphalangeal joints free and thumb immobilization in full extension. At 4 weeks, we changed the splint of the wrist in 0 degrees, and we started active mobility. Splints were discontinued at 8 weeks.

The patient is now 6 years free of myxoid liposarcoma. Eighteen months after triple tendon transfer surgery, the patient has good extension of the fingers, wrist, and thumb with excellent function and mobility.



**Fig. 4.** One of the FCU hemitendons is passed through an opening for each of the EDC tendons.

## DISCUSSION

We described a complex case of triple radial nerve palsy WALANT tendon transfers of PT to ECRB, FCU to EDC, and PL to EPL. There is one previous report of WALANT triple tendon transfer for radial nerve palsy but using the flexor carpi radialis (FCR) to EDC.<sup>3</sup>

Our case was complicated with a humerus pseudoarthrosis on top of the radial nerve palsy, and we showed that we could avoid the use of a tourniquet over this pseudoarthrosis and perform a triple tendon transfer in a safe way and with good results.

Regarding the transfer sequence, we first performed the transfer of PT to ECRB, followed by FCU to EDC, and finally, PL to EPL. In the above-mentioned article, the tendon transfer sequence was PL to EPL, FCR to EDC, and finally PT to ECRB. Both techniques achieved a good result.

The WALANT technique has gained popularity thanks to the work of Lalonde,<sup>1</sup> Ahmad et al,<sup>4</sup> Kurtzman et al,<sup>2</sup> and Huang et al,<sup>5</sup> and it is increasingly being used in procedures on the upper limb.<sup>6</sup> Among its benefits is the advantage of not using a tourniquet<sup>7</sup> and the possibility of carrying out an assessment of the surgical outcome intraoperatively.

Lalonde<sup>1</sup> suggests that a dose of up to 200 ml of 0.25% lidocaine with 1:400,000 epinephrine is reliable for 3 hours of safe, pain-free surgery. In this case, we used 180 ml of this solution, without observing any adverse effect or complication, and with absence of pain throughout the intervention.

A key point in tendon transfer surgery is the tension of the repair. As the patient remains awake with the WALANT technique, the tension of each sequential repair can be assessed painlessly and without motor block. The fact that the patient collaborates directly means that a real adjustment of tension can be made.

We, like other authors,<sup>1,4</sup> have observed how the brain is immediately able to adjust the functions of the new tendon transferred using the WALANT technique.

We feel that intraoperative assessment by the patient plays an important role in the process of rehabilitation and functional recovery, and testing the resistance of the

transfer gives the surgeon greater confidence to initiate an earlier rehabilitation.

### CONCLUSION

This patient's good progress would suggest that WALANT is undeniably a very useful tool and can be safely used in triple tendon transfers for radial nerve palsy.

**Homid Fahandezh-Saddi Díaz, MD, PhD**  
 Hand and Upper Extremity Unit  
 Hospital Universitario Fundación Alcorcón  
 Clínica AVANFI  
 Madrid, Spain 28922  
 E-mail: madridtrauma@hotmail.com

### REFERENCES

1. Lalonde DH. Latest advances in wide awake hand surgery. *Hand Clin.* 2019;35:1–6.
2. Kurtzman JS, Etcheson JI, Koehler SM. Wide-awake local anesthesia with no tourniquet: an updated review. *Plast Reconstr Surg Glob Open.* 2021;9:e3507.
3. Abdullah S, Ahmad AA, Lalonde D. Wide awake local anesthesia no tourniquet forearm triple tendon transfer in radial nerve palsy. *Plast Reconstr Surg Glob Open.* 2020;8:e3023.
4. Ahmad AA, Ubaidah Mustapa Kamal MA, Ruslan SR, et al. Plating of clavicle fracture using the wide-awake technique. *J Shoulder Elbow Surg.* 2020;29:2319–2325.
5. Huang YC, Hsu CJ, Renn JH, et al. WALANT for distal radius fracture: open reduction with plating fixation via wide-awake local anesthesia with no tourniquet. *J Orthop Surg Res.* 2018;13:195.
6. Aultman H, Roth CA, Curran J, et al. Prospective evaluation of surgical and anesthetic technique of carpal tunnel release in an orthopedic practice. *J Hand Surg Am.* 2021;46:69.e1–69.e7.
7. Evangelista TMP, Pua JHC, Evangelista-Huber MTP. Wide-awake local anesthesia no tourniquet (WALANT) versus local or intravenous regional anesthesia with tourniquet in atraumatic hand cases in orthopedics: a systematic review and meta-analysis. *J Hand Surg Asian Pac Vol.* 2019;24:469–476.