

Received: 2016.02.16  
Accepted: 2016.03.23  
Published: 2016.11.26

# Electroconvulsive Therapy-Induced Brain Structural and Functional Changes in Major Depressive Disorders: A Longitudinal Study

Authors' Contribution:  
Study Design A  
Data Collection B  
Statistical Analysis C  
Data Interpretation D  
Manuscript Preparation E  
Literature Search F  
Funds Collection G

ABCDEF **Haitang Qiu\***  
ABCDEF **Xirong Li\***  
BDEF **Wenjing Zhao**  
ABCDEF **Lian Du**  
BDEF **Peiyu Huang**  
BDEF **Yixiao Fu**  
BDEF **Tian Qiu**  
BDE **Peng Xie**  
BDF **Huaqing Meng**  
ABCDEFG **Qinghua Luo**

Mental Health Center, The First Affiliated Hospital of Chongqing Medical University, Chongqing, P.R. China

\* Co-first authors

**Corresponding Author:** Qinghua Luo, e-mail: [qihualuosci@126.com](mailto:qihualuosci@126.com)

**Source of support:** This work was supported by grants from the National Basic Research Program of China (2009CB918300) and the Science Foundation of Chongqing municipal education commission (KJ110318) and ChongQing Science & Technology Commission (cstc2014yykfA110030)

**Background:** This study aimed to study the brain structural and functional changes after 8 courses of electroconvulsive therapy (ECT) on patients with major depressive disorder (MDD).





**Material/Methods:** MRI scans were performed on 12 depressive patients before and after 8 courses of ECT and compared with those of 15 normal controls. Data were analyzed by voxel-based morphometry (VBM) using SPM8 software. Functional MRI (fMRI) and regional homogeneity (ReHo) analyses were used to assess the functional changes after ECT.

**Results:** Grey matter volumes were smaller in the right cingulate gyrus of depressive patients before ECT compared with normal controls. After false discovery rate (FDR) correction, post-ECT grey matter volumes were increased in bilateral amygdala and hippocampus compared with pre-ECT. Resting-state ReHo maps showed significant differences in brain activity pre- and post-ECT. Compared with healthy controls, MDD patients treated with 8 courses of ECT showed higher ReHo values in the bilateral frontal lobe, bilateral parietal lobe, and right caudate nucleus. Decreased ReHo values were observed in the right medial temporal gyrus, right superior temporal gyrus, right cingulate gyrus, and left anterior cerebellar lobe.

**Conclusions:** Results suggested that there were both structural and functional differences between the brains of MDD patients and healthy controls. After ECT, both structural and functional changes occurred, but without complete recovery to normal. ECT may display effects through regulating other brain regions to compensate for the original defects.

**MeSH Keywords:** **Depressive Disorder • Electroconvulsive Therapy • Magnetic Resonance Imaging**

**Full-text PDF:** <http://www.medscimonit.com/abstract/index/idArt/898081>

 3508  3  4  65



## Background

Depression is a mental disorder with potentially lethal consequences but its pathogenic and therapeutic mechanisms are unknown. Indeed, approximately 3.4% of patients with major depressive disorder (MDD) commit suicide in the United States [1]. Early intervention should reduce the suicide rate and decrease treatment time in MDD.

One of the quickest and most effective ways to treat MDD is electroconvulsive therapy (ECT) [2]. There is evidence suggesting that patients typically respond to ECT with progressive symptomatic improvement in the first week, and are in complete remission after 3 to 4 weeks [3–5]. However, for the several decades during which ECT has been in use, few improvements have been found to enhance its effect and reduce clinical complications. ECT has been shown to be a valid therapeutic tool for treatment of depression but its therapeutic mechanisms are unknown [3–6].

Induction of grand mal seizures is the therapeutic basis of ECT and the seizure resulting from ECT is believed to stimulate nerve cells growth and branching especially in the hippocampus [7–9]. Results from an animal study found that ECT can produce more robust neuroplastic effects than antidepressant drugs [10]. Few studies thus far have focused on the detailed brain structure before and after ECT. Currently, imaging techniques like magnetic resonance imaging (MRI) are used to study MDD [11,12].

A number of studies have reported changes in grey matter (GM) volume in various brain regions in MDD [13,14]. In addition to MRI, medications can induce brain volume changes in the hippocampus, amygdala, and temporal lobe [15,16], and similar results have been observed with ECT [17]. The amygdala has been associated with stress and depression. A recent study reported that high doses of electric shock could reduce the number and proportion of amygdala excitatory synaptic to inhibit stress-induced amygdala excitatory change, effectively treating depression [18]. An imaging study using region of interest (ROI) analysis reported increased hippocampal volume after ECT in patients with depression [19]. Similarly, a recent longitudinal study in 2013 showed that the hippocampal volume increase was reversible after ECT [20]. Results in that study indicated that the hippocampal volume returned to baseline, which proved the antidepressant effect of ECT in clinical practice [20]. Nevertheless, these results did not screen the whole brain and we still cannot define the importance of the hippocampus and amygdala in ECT.

The imaging techniques of voxel-based morphometry (VBM) provide an opportunity to elucidate the mechanism of ECT. This technique can assess the GM density changes across the

entire brain. The superiority of VBM for screening is that it assesses the brain regions equally and comprehensively [21]. This imaging technique was used to study schizophrenia, depression, autism, and dyslexia.

Functional MRI (fMRI) has become an important technique for studying advanced activities of the human brain [22,23]. Performing fMRI in the task-state is complicated, and patient compliance is usually poor, so the results obtained from task-states are difficult to reproduce. As it is free of task, resting-state fMRI reflects the brain's spontaneous baseline functional activity [24]. Resting-state fMRI has been used in research on schizophrenia, attention deficit hyperactivity disorder, epilepsy, and depression [25,26]. Currently, fMRI reports on patients with depression have greatly advanced our understanding of the neuropathology of depression. Functional abnormalities have been found in the anterior cingulate cortex (ACC), dorsolateral prefrontal cortex, hippocampus, striatum, and amygdala [27–29] in patients with depression. Yao et al. reported that patients with MDD have extensively distributed abnormal brain activity during resting state [30]. Previous studies have also shown that a variety of anti-depressant treatments not only improved the symptoms of depressive patients, but also altered brain function. Exploring the relationship between the efficacy of ECT and the changes in the ECT process may lead to a better understanding of the pathogenesis of MDD and the mechanism of ECT antidepressant activity.

The assessment of regional homogeneity (ReHo), a data-driven method, assumes that a given voxel is temporally similar to its neighbors. It measures the ReHo of the time series of the regional blood oxygen level-dependent (BOLD) signal. Kendall's coefficient of concordance (KCC) is used to measure the similarity of the time series of the voxel with those of its nearest neighbors in a voxel-wise way. Different ReHo of brain activity between depressed patients and controls were explored using second-level statistical analysis on individual KCC maps. The major advantage of ReHo is the ability to detect spontaneous hemodynamic responses of resting-state fMRI [31]. Therefore, ReHo reflects the temporal homogeneity of the regional BOLD signal rather than its density. As the BOLD signal of fMRI may reflect neural activity [32], the comparison of ReHo value between patients and controls may be used to identify the alterations in local spontaneous brain activity. This method has been applied to various clinical populations to investigate the functional modulations in the resting state [33–36]. In addition, ReHo was identified as a neuroimaging marker to investigate neural activity [36]. Some authors suggest that the increased ReHo value in some parts of the brain might be responsible for seizure genesis and propagation [37,38]. Changes of ReHo in the cortex may reflect dysfunction of the corresponding cortical network associated with a specific disorder [39].

In the present study, the influence of ECT on the brain structure changes during MDD treatment was longitudinally assessed using VBM analysis after MRI. Resting-state fMRI and ReHo analyses were performed in the same subjects before and after ECT to further assess the functional brain changes after ECT.

## Material and Methods

### Subjects

Twelve MDD inpatients (8 females and 4 males, aged  $34.4 \pm 10.1$ , range 21–55 years) were recruited at the Mental Health Center, the First Affiliated Hospital of Chongqing Medical University, as well as 15 normal controls (10 females and 5 males, aged  $36.1 \pm 9.4$ , range 21–55 years). All patients had a unipolar depressive episode and met Diagnostic and Statistical Manual (DSM)-IV criteria for MDD [40]. Diagnoses and structured clinical interviews for DSM-IV were based on the consensus of 2 psychiatrists (T.F. and M.J.). The Hamilton Depression (HAM-D) Rating Scale was used to assess severe negative emotions and suicidal ideation or behavior [41]. All patients underwent a physical examination, including a routine blood test, electroencephalogram, electrocardiogram, and X-ray before ECT. The subjects had not received antipsychotics, antidepressants, mood stabilizers, or ECT for at least 1 month. Patients were all Han Chinese and right-handed. Other general patient information, including sex, age and educational level, was collected.

Exclusion criteria were: 1) contraindication to MRI scanning; 2) neurological disorders; 3) severe somatic disease; 4) substance abuse; 5) pregnancy; 6) lactation; or 7) depression caused by or combined with somatic disease and other psychiatric disorders.

This research was approved by the local Ethics Committee of the Chongqing Medical University, China. All patients and normal controls had given written informed consent before the study.

### Electroconvulsive therapy (ECT)

All 12 patients received 8 sessions of ECT during a 3-week period, 3 times per week (Monday, Wednesday, and Friday) for 2 weeks, and the remaining 2 times (Monday and Friday) for the 3rd week. The patients accepted MRI scanning, fMRI scanning, and HAM-D rating on the day before the 1st ECT and the day after the 8th ECT. During the process of ECT, patients did not use any antidepressants and antipsychotics.

ECT was conducted using a Thymatron DGx (Somatics LLC, Lake Bluff, IL) at the Mental Health Center, the First Affiliated Hospital of Chongqing Medical University. The initial dosage selected was normalized based on sex, age, weight, and height, and

the stimulus intensity was individually adjusted by the seizure response, effect, and adverse effects during ECT. Anesthesia was induced with sodium thiopental (3.0–5.0 mg/kg) and succinylcholine (0.5–1.0 mg/kg). The d'Elia placement was used for the standard bitemporal placement for bilateral (BL) ECT.

### MRI scanning

All MRI scans were conducted using a 3T magnet (Sigma, GE Medical Systems, Waukesha, WI) using a circular polarized birdcage head coil. 3-D T1-weighted anatomical images were acquired using the spoiled gradient recall (SPGR) sequence (repetition time: 8.35 ms; echo time: 3.27 ms; total acquisition time: 7 min; flip angle:  $12^\circ$ ; field of view: 24 cm; image matrix:  $512 \times 512$ , slice thickness: 1 mm, voxel size of  $0.47 \times 0.47 \times 1$  mm<sup>3</sup>, number of slices: 156 sagittal slices).

### VBM imaging

MRI data were analyzed by following the standard steps of optimized VBM in the SPM8 software (<http://www.fil.ion.ucl.ac.uk/spm/software/spm8/>). Specifically, all T1 images were corrected for inhomogeneity, registered using a linear affine plus nonlinear transformation, and segmented into GM, white matter (WM), and cerebrospinal fluid (CSF). The resulting GM volume images were modulated by scaling derived from nonlinear transformation matrices. Preprocessed images were then spatially smoothed with a Gaussian kernel (full width at half maximum=8 mm). Smoothed GM images were compared between the healthy control and MDD groups by using independent-samples t-tests (uncorrected,  $P=0.001$ ).

The optimized VBM toolbox is an extension of the “New Segment Toolbox” in SPM8, using a completely different segmentation approach. The segmentation approach is based on an adaptive Maximum A Posteriori (MAP) technique without the need for *a priori* information about tissue probabilities. The MAP estimation is adaptive in the sense that local variations of parameters (e.g., means and variance) are modeled as slowly varying spatial functions [42]. Additionally, the segmentation approach uses a Partial Volume Estimation (PVE) with a simplified mixed model of at most 2 tissue types [43]. This approach results in an estimation of the amount (or fraction) of each pure tissue type present in every voxel (as each single voxel, given its size, probably contains more than 1 tissue type) and thus provides a more accurate segmentation.

### fMRI scanning

Functional images were acquired using the same 3.0T GE Sigma scanner by using a circular polarized birdcage head coil. After a localization scan, the resting-state functional images were obtained with a gradient-recalled echo-planar imaging sequence.

**Table 1.** Demographic data of the MDD and healthy control groups.

No.	MDD group	Healthy control group	P
	12	15	
Sex (M/F)	4/8	5/10	
Age (mean (SD))	34.4±10.1	33.7±9.9	0.848
Education year (mean ±SD)	12.6±2.3	13.8±2.9	0.244
HAMD	35.9±1.3	2.2±1.2	<0.001

HAMD – scores of Hamilton Depression Rating Scale.

The parameters were as follows: repetition time (TR)=2000 ms, echo time (TE)=30 ms, field of view (FOV)=240×240 mm<sup>2</sup>, data matrix=64×64, flip angle (FA)=90°, 30 slices, slice thickness=5 mm, scanner time=6 min 50 s. Subjects lay supine and were asked to remain motionless, relax with their eyes closed, and without thinking.

### fMRI image pre-processing

Image preprocessing was conducted using the Data Processing Assistant for Resting-State fMRI (DPARSF, by YAN Chao-Gan, <http://www.restfmri.net>). The first 10 time points were discarded due to the instability of the initial MRI signal and adaptation of subjects to the circumstances, and the remaining 190 time points were used for analysis. As a first step, head motion corrections were performed. All participants should have no more than 1.5 mm maximum displacement in x, y, or z, and 1.5° of angular motion during the whole fMRI scan. Then, after the time-series were corrected, the fMRI images were normalized to the standard SPM8 echoplanar imaging template, resampling to 3×3×3 mm. As a last step, the normalized fMRI images were band-pass filtered (0.01<f<0.08 Hz) to reduce the low-frequency drift and physiological high-frequency respiratory and cardiac noise.

### ReHo analysis

ReHo analysis was performed for each subject by calculating Kendall's coefficient concordance (KCC) of time series of a given voxel with its nearest 26 neighboring voxels. The formula for calculating the KCC value was:

$$W = \frac{\sum (R_i)^2 - n(\bar{R})^2}{\frac{1}{12} K^2 (n^3 - n)}$$

where W is the KCC of a given voxel, ranging from 0 to 1; R<sub>i</sub> is the sum rank of the i<sup>th</sup> time point;  $\bar{R}$  is the mean of the R<sub>i</sub>'s; n is the number of ranks; K is the number of time series within a measured cluster (K=27, 1 given voxel plus the number

of its neighbors). The ReHo maps were then smoothed with a Gaussian kernel of 4 mm full-width at half-maximum.

### Statistics

Statistical analyses were carried out using SPSS 18.0 (SPSS Inc., Chicago, IL). Demographic data and HAMD scores were compared using the paired t-test. Differences were considered statistically significant if P<0.05.

## Results

### Baseline characteristics of the subjects

Demographic data and HAMD score of patients and controls are shown in Table 1. There was no significant difference in age and education (P>0.05), but HAMD score was highly significantly different (P<0.001) between the 2 groups. All patients scored 33 or higher (35.9±1.3) on the 24-item HAMD Rating Scale at baseline.

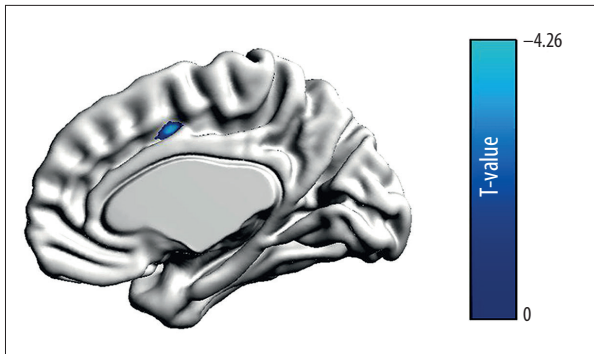
### Pre-ECT MRI data

Compared with normal controls, MRI data of the pre-ECT showed that GM volumes were decreased in the right cingulate gyrus (P=0.001, uncorrected, cluster size=142, MNI coordinates were x=15, y=5, z=43, T=4.26, Z=3.66, Figure 1), and no brain regions showed increased GM volume at the same threshold more than 10 clusters (P<0.001, uncorrected).

### Post-ECT MRI data

Before false discovery rate (FDR) correction, dozens of brain regions showed increased or decreased GM volume after the 8<sup>th</sup> ECT. After FDR correction, the most significant brain regions, the bilateral amygdala and hippocampus, showed an increase in GM after the 8<sup>th</sup> ECT. In addition, the comparison between the post-ECT8 and pre-ECT imaging revealed increased GM volume in bilateral amygdala and hippocampus (P<0.05,



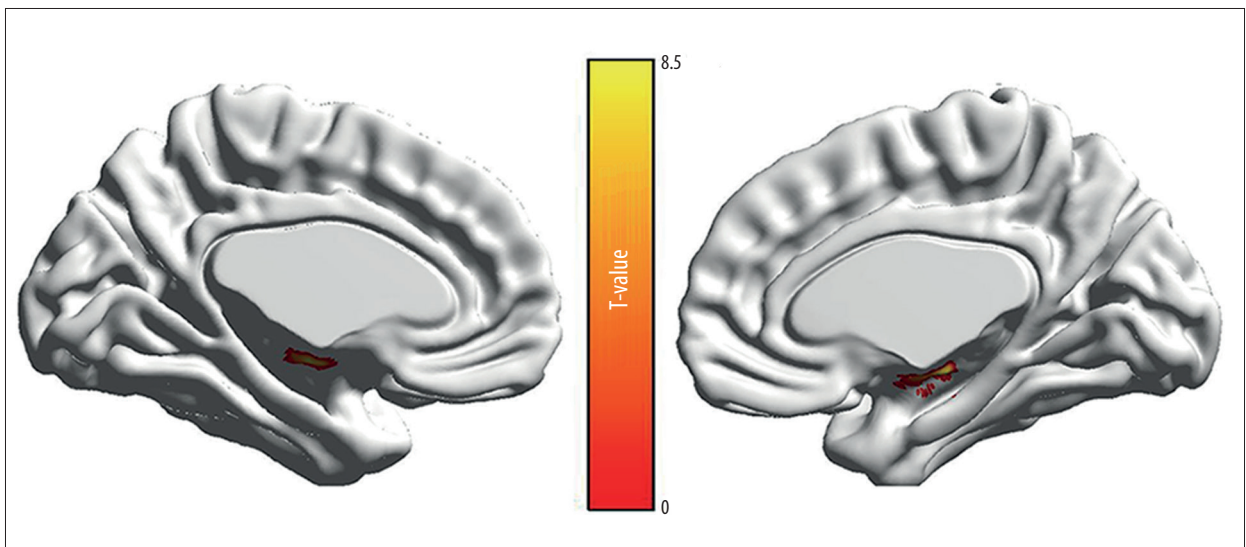


**Figure 1.** Differences in GM in the right cingulate gyrus between the healthy control and MDD groups.  $P=0.001$ , uncorrected, cluster size  $>10$ . T-score bar is shown at right.

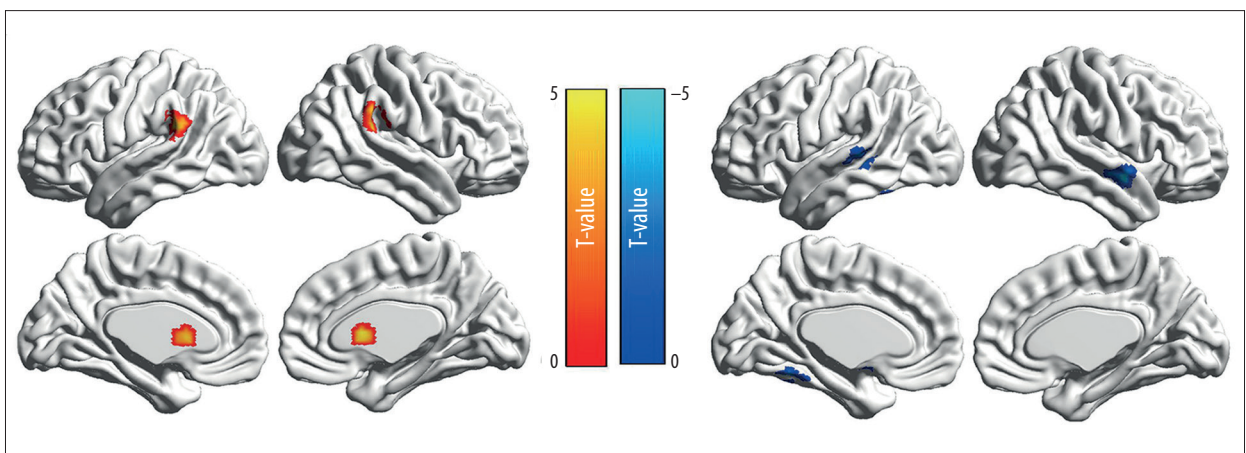
FDR corrected, cluster size  $>40$ , Figure 2). There was no significant decrease in GM volume between the post-ECT8 and pre-ECT imaging.

#### Pre-ECT ReHo data

ReHo maps of pre-ECT and post-ECT8 are shown in Figure 3. Compared with healthy controls, patients with MDD showed increased ReHo in the right caudate nucleus and bilateral inferior parietal lobule, and decreased ReHo in the right superior temporal gyrus, left medial temporal gyrus, left superior temporal gyrus, bilateral parietal cerebellar anterior lobe, left fusiform gyrus, left parahippocampal gyrus, left inferior corpus callosum gyrus, and right pons before treatment (Table 2).



**Figure 2.** Gray matter was increased post-ECT8 compared with pre-ECT with FDR correction. T-score bar is shown in the middle.



**Figure 3.** ReHo maps showing significant differences in brain activity of patients in the MDD group between pre-ECT and post-ECT8. T-score bars are shown in the middle.

**Table 2.** Increased ReHo regions and decreased ReHo regions in patients with MDD compared to controls before treatment.

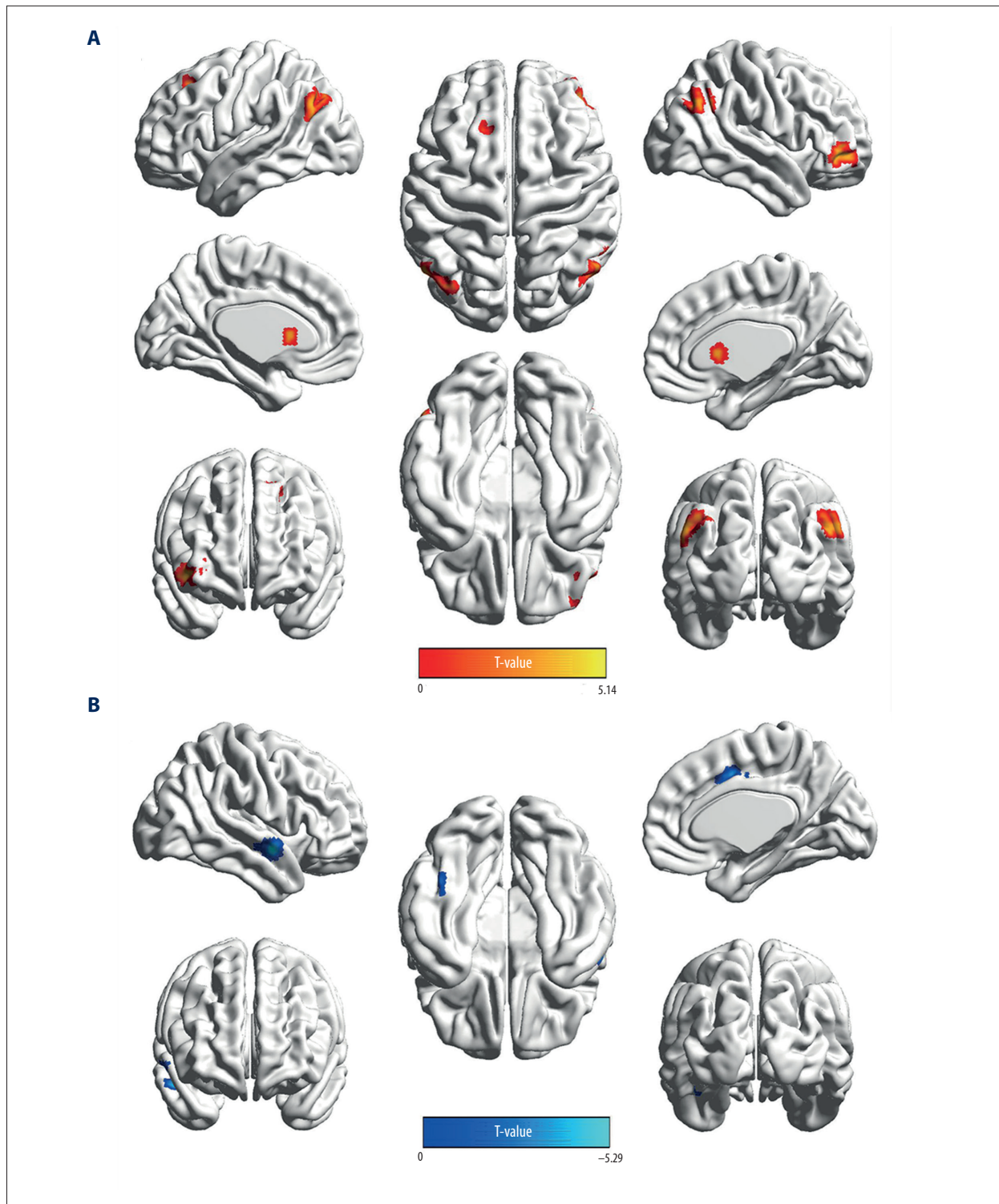
	Voxel	MNI coordinate (x, y, z)	Z value	Hemicerebrum (left/right)	Brain region	BA partition
Increased ReHo regions	27	3, 12, 9	4.42	Right	Caudate nucleus	
	30	60, -39, 21	3.91	Right	Inferior parietal lobule	40
	45	-57, -42, 27	4.49	Left	Inferior parietal lobule	40
	27	54, 0, -12	4.75	Right	Superior temporal gyrus	38
	31	-63, -33, 0	4.27	Left	Medial temporal gyrus	22
				Left	Superior temporal gyrus	
	31	-33, -54, -33	4.03	Left	Parietal cerebellar anterior lobe	
Decreased ReHo regions					Fusiform gyrus	37
	34	-12, -45, -30	3.83	Left	Parietal cerebellar anterior lobe	
	29	9, -57, -27	4.32	Right	Parietal cerebellar anterior lobe	
	37	-6, 0, -24	4.66	Left	Parahippocampal gyrus	34
					Inferior corpus callosum gyrus	
	80	6, -21, -30	4.95	Right	Pons	

FEW corrected, P<0.05. MDD – major depressive disorder; ReHo – regional homogeneity.

**Table 3.** Increased ReHo regions and decreased ReHo regions in patients with MDD compared to controls after 8 times of ECT treatment.

	Voxel	MNI coordinate (x, y, z)	Z value	Hemicerebrum (left/right)	Brain region	BA partition
Increased ReHo regions	41	42, 42, -3	4.68	Right	Middle frontal gyrus	
					Inferior frontal gyrus	
	37	6, 9, 9	4.03	Right	Caudate nucleus	
	53	-36, -78, 45	4.43	Left	Angular gyrus	39
					Precuneus	19
					Mediate frontal gyrus	
	46	57, -57, 36	4.10	Right	Supramaginal gyrus	40
					Angular gyrus	39
Decreased ReHo Regions	33	-18, 27, 48	5.14	Left	Superior frontal gyrus	8
					Mediate frontal gyrus	6
	40	-33, -57, -33	3.92	Left	Cerebellar anterior lobe	
	38	57, -3, -9	5.29	Right	Medial temporal gyrus	21
				Right	Superior temporal gyrus	
	21	12, 9, 42	5.06	Right	Cingulate gyrus	32

FEW corrected, P<0.05. MDD – major depressive disorder; ReHo – regional homogeneity.



**Figure 4.** ReHo maps showing significant differences in brain activity between the healthy control and MDD groups post-ECT8. **(A)** Compared with the healthy control group, the MDD group showed increased ReHo in the left superior frontal gyrus, left mediate frontal gyrus, right middle frontal gyrus, right inferior frontal gyrus, right caudate nucleus, bilateral angular gyrus, left precuneus, left medial temporal gyrus, and right supramarginal gyrus. **(B)** Compared with the healthy control group, the MDD group showed decreased ReHo in the right medial temporal gyrus, right superior temporal gyrus, right cingulate gyrus, and left anterior cerebellar lobe. T-score bars are shown below.



### Post-ECT ReHo data

As shown in Table 3, compared with healthy controls, MDD patients after 8 ECT treatments showed increased ReHo in the left superior frontal gyrus, left medial frontal gyrus, right middle frontal gyrus, right inferior frontal gyrus, right caudate nucleus, bilateral angular gyrus, left precuneus, left medial temporal gyrus, and right supramarginal gyrus (Figure 4A); and decreased ReHo in the right medial temporal gyrus, right superior temporal gyrus, right cingulate gyrus, and left anterior cerebellar lobe (Figure 4B).

### Discussion

This study longitudinally assessed the brain structural changes during the process of ECT treatment on MDD patients using an optimized VBM method. Firstly, GM volume was reduced in the right cingulate gyrus of patients with MDD compared with healthy control and pre-ECT groups without correction. Secondly, changes in GM volume were detected in the bilateral amygdala and hippocampus between pre-ECT and post-ECT8 after correction by FDR.

Similar to our results, a recent study showed that the right rostral-anterior cingulate volume was smaller in MDD patients compared with controls [44]. Another study found that both anterior cingulate gyri were smaller in women with depression by VBM [45]. Several studies have indicated that the cingulate gyrus plays an important role in MDD [46–48].

In previous studies it has been noted that there was a significant increase of cells and volumes after several courses of ECT. A recent study using structural MRI revealed that after ECT treatment, the volume of the hippocampus and amygdala were increased in treatment-refractory depression [49]. In this study, similar results were obtained in humans. A meta-analysis of related reports from 1985 to 2008 concluded that MDD is associated with amygdala volume, and that amygdala volume of patients who did not receive antidepressant treatment was significantly decreased [50]. In this study, results showed that ECT significantly increased GM voxel of the bilateral amygdala in the whole brain. Considering ECT as a kind of fast and effective treatment, the amygdala could be used as an important target in the treatment of MDD. Furthermore, reduced amygdala volume may be due to the reduction of amygdala astrocytes [51]. With the scanning of brain regions, distinct changes of voxels focused on hippocampus were observed, as well as the importance of the hippocampus during the treatment of ECT without the disturbance of bias point of researchers. Using VBM, the bilateral amygdala could determine, and the hippocampus was found to play an important role in, the treatment of ECT. This might bring us closer to the core region of action of ECT.

Peng et al. [52] reported decreased ReHo value in patients with MDD and the present study is consistent, at least in part, with these findings. Guo et al. [11,53] and Chen et al. [54] investigated the resting-state fMRI in patients with refractory depression and showed a changed ReHo value in the superior temporal gyrus and anterior cerebellum lobe. A previous study reported a tendency toward a decreased temporal lobe volume, which is an important region of the mood-regulating circuit, in patients with depression [55]. The superior temporal gyrus was reported to be associated with emotions and feelings of facial stimulation [56] and it plays an important role in recognition of facial emotion. Our study revealed a decreased ReHo value in the left fusiform gyrus in MDD patients compared with healthy controls. Fusiform gyrus correlates with facial expression [57], an important sign of individual emotion. Yao et al. [30] showed an abnormal function of the fusiform gyrus in MDD patients under resting-state. Previous investigations have shown fusiform gyrus dysfunction in a negative emotion regulating model [58]. Chan et al. [59] and Demaree et al. [60] reported that the posterior fusiform gyrus was associated with depression-related emotion information processing. The present study indicated an increase of the ReHo value in the right superior temporal gyrus and fusiform gyrus in MDD patients.

In the present study, 8 courses of ECT led to an increased ReHo value in the left middle temporal gyrus, while the ReHo value of spontaneous electric activity in the left fusiform gyrus remained unchanged. The right superior temporal gyrus showed a decreased ReHo value, suggesting a partial improvement after ECT treatment. The ReHo value in the left parahippocampal gyrus decreased in MDD patients, and the abnormality was not observed after 8 courses of ECT treatment. In a previous study, Suwa et al. [61] used positron emission tomography to compare the brain electric activity pre- and post-ECT; they found that the metabolism of the temporal lobe was significantly changed after ECT, suggesting that the temporal lobe might be an important target of ECT.

The present study strongly suggests that the ReHo value in the bilateral parietal cerebellar anterior lobe was decreased in patients with MDD. In recent years, several studies agreed that the cerebellum participates in the cognitive and emotional integrating process, and plays an important role in the identification of feelings and emotion information [62]. After using negative stimulation resting-state fMRI pre- and post-treatment by fluoxetine among patients with depression, Fu et al. [63] suggested that the improvement in depression symptoms corresponded to the activity of anterior cingulate cortex, ventral striatum, and cerebellum. After 8 courses of ECT, a decreased ReHo value was observed in the left anterior cerebellum lobe, while the ReHo value in the right anterior cerebellum lobe was without abnormal changes. ECT treatment



revealed a partial improvement of spontaneous electric activity in the cerebellum, suggesting that the improvement of depressant symptoms from ECT treatment was partially achieved by improving abnormal function activity in the cerebellum.

The results of the present study indicate that ECT can partially reverse the altered brain function and return different brain areas to normal. There are limited comparative investigations on brain function of post-ECT treatment. By using resting-state fMRI among elderly depression patients who were regularly treated with an antidepressant drug and had a clinically significant improvement in symptoms for at least 6 months, Yuan et al. [64] showed that abnormal brain activity persisted. Studies have found decreased orientation stimulation in the frontal lobe of elderly patients with depression in clinical recovery [65]. This may help explain the consistent abnormal brain activity in spite of clinical improvement in symptoms after ECT treatment. Whether the ECT treatment reverses the abnormal brain activity or creates a new activity level is not clear yet. However, ECT treatment may be involved in the limbic system-cortex-corpora striatum-globus pallidus-thalamus depression nerve pathology loop, in which most abnormal brain regions have been reversed, suggesting further research on the antidepressant mechanism of ECT treatment in the neural network.

This study had a number of limitations. The sample size was quite small, which may limit the representativeness of the patient population. Small ReHo changes (cluster size <100) might

have been missed and additional research using a larger population would be beneficial. Another limitation was the lack of patient follow-up. Future studies may include additional analysis months or years after the final course of ECT. In addition, ROI analyses were lacking, which could have provided more accurate associations between structural and functional changes in both MDD and mechanisms of ECT.

## Conclusions

The present study indicated that there were both structural and functional differences between the brains of MDD patients and healthy controls. In addition, after ECT, these structural and functional differences partly disappeared. ECT may have effects through regulating other brain regions to compensate for the original defects.

## Acknowledgements

We gratefully acknowledge the assistance of Nanyin Zhang for critical discussions and reading of the manuscript; Wei Deng for technical help with VBM analysis; and Fei Wu for help with MRI scanning. We also thank Yixiao Fu, Haitang Qiu, and Haixiang Liu for assistance with searching of literature.

## Conflict of interest

The authors declare that they have no conflict of interest.

## References:

1. Barlow DH: *Abnormal psychology: An Integrative Approach* (5th ed.). Belmont, CA, USA: Thomson Wadsworth, 2005; 248–49
2. UK ECT Review Group: Efficacy and safety of electroconvulsive therapy in depressive disorders: a systematic review and meta-analysis. *Lancet*, 2003; 361: 799–808
3. Shapira B, Lerer B: Speed of response to bilateral ECT: An examination of possible predictors in two controlled trials. *J ECT*, 1999; 15: 202–6
4. Husain MM, Rush AJ, Fink M et al: Speed of response and remission in major depressive disorder with acute electroconvulsive therapy (ECT): A Consortium for research in ECT (CORE) report. *J Clin Psychiatry*, 2004; 65: 485–91
5. Kho KH, Blansjaar BA, Vothknecht S et al: A study into predictors for the speed of response to electroconvulsive therapy. *J ECT*, 2004; 20: 154–59
6. Suzuki K, Ebina Y, Shindo T et al: Repeated electroconvulsive therapy courses improved chronic regional pain with depression caused by failed back syndrome. *Med Sci Monit*, 2009; 15: C577–79
7. Bolwig TG, Madsen TM: Electroconvulsive therapy in melancholia: The role of hippocampal neurogenesis. *Acta Psychiatr Scand Suppl*, 2007; 130–35
8. Madsen TM, Treschow A, Bengzon J et al: Increased neurogenesis in a model of electroconvulsive therapy. *Biol Psychiatry*, 2000; 47: 1043–49
9. Hellsten J, Wennstrom M, Mohapel P et al: Electroconvulsive seizures increase hippocampal neurogenesis after chronic corticosterone treatment. *Eur J Neurosci*, 2002; 16: 283–90
10. Segi-Nishida E, Warner-Schmidt JL, Duman RS: Electroconvulsive seizure and VEGF increase the proliferation of neural stem-like cells in rat hippocampus. *Proc Natl Acad Sci USA*, 2008; 105: 11352–57
11. Guo WB, Liu F, Chen JD et al: Abnormal neural activity of brain regions in treatment-resistant and treatment-sensitive major depressive disorder: A resting-state fMRI study. *J Psychiatr Res*, 2012; 46: 1366–73
12. Liu F, Guo W, Liu L et al: Abnormal amplitude low-frequency oscillations in medication-naive, first-episode patients with major depressive disorder: A resting-state fMRI study. *J Affect Disord*, 2013; 146: 401–6
13. Cheng YQ, Xu J, Chai P et al: Brain volume alteration and the correlations with the clinical characteristics in drug-naive first-episode MDD patients: A voxel-based morphometry study. *Neurosci Lett*, 2010; 480: 30–34
14. Ballmaier M, Kumar A, Thompson PM et al: Localizing gray matter deficits in late-onset depression using computational cortical pattern matching methods. *Am J Psychiatry*, 2004; 161: 2091–99
15. Vythilingam M, Vermetten E, Anderson GM et al: Hippocampal volume, memory, and cortisol status in major depressive disorder: effects of treatment. *Biol Psychiatry*, 2004; 56: 101–12
16. Monkul ES, Hatch JP, Nicoletti MA et al: Fronto-limbic brain structures in suicidal and non-suicidal female patients with major depressive disorder. *Mol Psychiatry*, 2007; 12: 360–66
17. Bouckaert F, De Winter FL, Emsell L et al: Grey matter volume increase following electroconvulsive therapy in patients with late life depression: A longitudinal MRI study. *J Psychiatry Neurosci*, 2016; 41: 105–14
18. Khaleel N, Ravindranath R, Sagar BK, Andrade C: Images in electroconvulsive therapy: Pilot impressions suggesting that ECT reduces excitatory synapses in the basolateral amygdala. *Indian J Psychiatry*, 2013; 55: 204–5
19. Nordanskog P, Dahlstrand U, Larsson MR et al: Increase in hippocampal volume after electroconvulsive therapy in patients with depression: A volumetric magnetic resonance imaging study. *J ECT*, 2010; 26: 62–67

20. Ende G, Braus DF, Walter S et al: The hippocampus in patients treated with electroconvulsive therapy: A proton magnetic resonance spectroscopic imaging study. *Arch Gen Psychiatry*, 2000; 57: 937-43
21. Ashburner J, Friston KJ: Voxel-based morphometry – the methods. *Neuroimage*, 2000; 11: 805-21
22. Roberts TP, Disbrow EA, Roberts HC, Rowley HA: Quantification and reproducibility of tracking cortical extent of activation by use of functional MR imaging and magnetoencephalography. *Am J Neuroradiol*, 2000; 21: 1377-87
23. Guo W, Hu M, Fan X et al: Decreased gray matter volume in the left middle temporal gyrus as a candidate biomarker for schizophrenia: a study of drug naive, first-episode schizophrenia patients and unaffected siblings. *Schizophr Res*, 2014; 159: 43-50
24. Gusnard DA, Raichle ME, Raichle ME: Searching for a baseline: functional imaging and the resting human brain. *Nat Rev Neurosci*, 2001; 2: 685-94
25. Zhang Z, Lu G, Zhong Y et al: fMRI study of mesial temporal lobe epilepsy using amplitude of low-frequency fluctuation analysis. *Hum Brain Mapp*, 2010; 31: 1851-61
26. Anand A, Li Y, Wang Y et al: Activity and connectivity of brain mood regulating circuit in depression: a functional magnetic resonance study. *Biol Psychiatry*, 2005; 57: 1079-88
27. Drevets WC, Price JL, Simpson JR Jr. et al: Subgenual prefrontal cortex abnormalities in mood disorders. *Nature*, 1997; 386: 824-27
28. Anand A, Shekhar A: Brain imaging studies in mood and anxiety disorders: Special emphasis on the amygdala. *Ann NY Acad Sci*, 2003; 985: 370-88
29. Siegle GJ, Steinhauer SR, Thase ME et al: Can't shake that feeling: event-related fMRI assessment of sustained amygdala activity in response to emotional information in depressed individuals. *Biol Psychiatry*, 2002; 51: 693-707
30. Yao Z, Wang L, Lu Q et al: Regional homogeneity in depression and its relationship with separate depressive symptom clusters: a resting-state fMRI study. *J Affect Disord*, 2009; 115: 430-38
31. Zang Y, Jiang T, Lu Y et al: Regional homogeneity approach to fMRI data analysis. *Neuroimage*, 2004; 22: 394-400
32. Logothetis NK, Pauls J, Augath M et al: Neurophysiological investigation of the basis of the fMRI signal. *Nature*, 2001; 412: 150-57
33. Wu QZ, Li DM, Kuang WH et al: Abnormal regional spontaneous neural activity in treatment-refractory depression revealed by resting-state fMRI. *Hum Brain Mapp*, 2011; 32: 1290-99
34. Wu T, Long X, Zang Y et al: Regional homogeneity changes in patients with Parkinson's disease. *Hum Brain Mapp*, 2009; 30: 1502-10
35. Paakki JJ, Rahko J, Long X et al: Alterations in regional homogeneity of resting-state brain activity in autism spectrum disorders. *Brain Res*, 2010; 1321: 169-79
36. Zuo XN, Xu T, Jiang L et al: Toward reliable characterization of functional homogeneity in the human brain: Preprocessing, scan duration, imaging resolution and computational space. *Neuroimage*, 2013; 65: 374-86
37. Zeng H, Pizarro R, Nair VA et al: Alterations in regional homogeneity of resting-state brain activity in mesial temporal lobe epilepsy. *Epilepsia*, 2013; 54: 658-66
38. Tang YL, Ji GJ, Yu Y et al: Altered regional homogeneity in rolandic epilepsy: A resting-state fMRI study. *Biomed Res Int*, 2014; 2014: 960395
39. Jiang S, Luo C, Liu Z et al: Altered local spontaneous brain activity in juvenile myoclonic epilepsy: a preliminary resting-state fMRI study. *Neural Plast*, 2016; 2016: 3547203
40. American Psychiatric Association. DSM-IV, Diagnostic and Statistical Manual of Mental Disorders. Washington DC: American Psychiatric Association, 1994
41. Hamilton M: Development of a rating scale for primary depressive illness. *Br J Soc Clin Psychol*, 1967; 6: 278-96
42. Rajapakse JC, Giedd JN, Rapoport JL: Statistical approach to segmentation of single-channel cerebral MR images. *IEEE Trans Med Imaging*, 1997; 16: 176-86
43. Tohka J, Zijdenbos A, Evans A: Fast and robust parameter estimation for statistical partial volume models in brain MRI. *Neuroimage*, 2004; 23: 84-97
44. Hoogenboom WS, Perlis RH, Smoller JW et al: Feasibility of studying brain morphology in major depressive disorder with structural magnetic resonance imaging and clinical data from the electronic medical record: A pilot study. *Psychiatry Res*, 2013; 211: 202-13
45. Hayakawa YK, Sasaki H, Takao H et al: Structural brain abnormalities in women with subclinical depression, as revealed by voxel-based morphometry and diffusion tensor imaging. *J Affect Disord*, 2013; 144: 263-68
46. Silva CB, Yasuda CL, D'Abreu A et al: Neuroanatomical correlates of depression in Friedreich's ataxia: A voxel-based morphometry study. *Cerebellum*, 2013; 12: 429-36
47. Niida A, Niida R, Matsuda H et al: Identification of atrophy of the subgenual anterior cingulate cortex, in particular the subcallosal area, as an effective auxiliary means of diagnosis for major depressive disorder. *Int J Gen Med*, 2012; 5: 667-74
48. Malykhin NV, Carter R, Hegadoren KM et al: Fronto-limbic volumetric changes in major depressive disorder. *J Affect Disord*, 2012; 136: 1104-13
49. Tendolkar I, van Beek M, van Oostrom I et al: Electroconvulsive therapy increases hippocampal and amygdala volume in therapy refractory depression: A longitudinal pilot study. *Psychiatry Res*, 2013; 214: 197-203
50. Hamilton JP, Siemer M, Gotlib IH: Amygdala volume in major depressive disorder: A meta-analysis of magnetic resonance imaging studies. *Mol Psychiatry*, 2008; 13: 993-1000
51. Althshuler LL, Abulseoud OA, Foland-Ross L et al: Amygdala astrocyte reduction in subjects with major depressive disorder but not bipolar disorder. *Bipolar Disord*, 2010; 12: 541-49
52. Peng DH, Jiang KD, Fang YR et al: Decreased regional homogeneity in major depression as revealed by resting-state functional magnetic resonance imaging. *Chin Med J (Engl)*, 2011; 124: 369-73
53. Guo WB, Sun XL, Liu L et al: Disrupted regional homogeneity in treatment-resistant depression: A resting-state fMRI study. *Prog Neuropsychopharmacol Biol Psychiatry*, 2011; 35: 1297-302
54. Chen JD, Liu F, Xun GL et al: Early and late onset, first-episode, treatment-naive depression: Same clinical symptoms, different regional neural activities. *J Affect Disord*, 2012; 143: 56-63
55. Caetano SC, Fonseca M, Hatch JP et al: Medial temporal lobe abnormalities in pediatric unipolar depression. *Neurosci Lett*, 2007; 427: 142-47
56. Radua J, Phillips ML, Russell T et al: Neural response to specific components of fearful faces in healthy and schizophrenic adults. *Neuroimage*, 2010; 49: 939-46
57. Kanwisher N, McDermott J, Chun MM: The fusiform face area: A module in human extrastriate cortex specialized for face perception. *J Neurosci*, 1997; 17: 4302-11
58. Beck AT: Cognitive therapy and the emotional disorders. Penguin, 1979
59. Chan SW, Norbury R, Goodwin GM, Harmer CJ: Risk for depression and neural responses to fearful facial expressions of emotion. *Br J Psychiatry*, 2009; 194: 139-45
60. Demaree HA, Pu J, Jesberger J et al: 5HTTLPR predicts left fusiform gyrus activation to positive emotional stimuli. *Magn Reson Imaging*, 2009; 27: 441-48
61. Suwa T, Namiki C, Takaya S et al: Corticolimbic balance shift of regional glucose metabolism in depressed patients treated with ECT. *J Affect Disord*, 2012; 136: 1039-46
62. Jiang T, He Y, Zang Y, Weng X: Modulation of functional connectivity during the resting state and the motor task. *Hum Brain Mapp*, 2004; 22: 63-71
63. Fu CH, Williams SC, Brammer MJ et al: Neural responses to happy facial expressions in major depression following antidepressant treatment. *Am J Psychiatry*, 2007; 164: 599-607
64. Yuan Y, Zhang Z, Bai F et al: Abnormal neural activity in the patients with remitted geriatric depression: A resting-state functional magnetic resonance imaging study. *J Affect Disord*, 2008; 111: 145-52
65. Wang L, Krishnan KR, Steffens DC et al: Depressive state- and disease-related alterations in neural responses to affective and executive challenges in geriatric depression. *Am J Psychiatry*, 2008; 165: 863-71