

# Skin Preservation in the Debridement of Necrotizing Fasciitis: A Demonstrative Case Report

Felwa A. AlMarshad, MBBS\*

Qutaiba N. M. Shah Mardan,  
MBBS†

Nehal A. Mahabbat, MBBS\*

Attiya Ijaz, MBBS\*

Rahaf Bashaweeh, MBBS‡

Mohamed Amir Mrad, MD,

FRCSC, FACS\*

Mohammad M. Al-Qattan, MBBS§

Fuad K. Hashem, MD\*

**Summary:** Necrotizing fasciitis (NF) is a rare yet potentially fatal soft-tissue, polymicrobial infection. Aggressive debridement of the fascia and overlying skin as well as antimicrobial coverage constitute the mainstay of management, often leaving large skin defects. However, we demonstrate in this paper a case of a young woman who developed NF after liposuction and was treated by fascial debridement with minimal skin excision. Skin preservation will reduce the morbidity and improve the final aesthetic outcome. (*Plast Reconstr Surg Glob Open* 2022;10:e4227; doi: [10.1097/GOX.0000000000004227](https://doi.org/10.1097/GOX.0000000000004227); Published online 6 April 2022.)

## INTRODUCTION

Necrotizing fasciitis (NF) is a term associated with a rapidly spreading, potentially fatal soft-tissue infection. Most commonly, NF is caused by group A streptococcus bacteria, where they invade the fascia and spread through its planes.<sup>1</sup> Fascial necrosis also leads to ischemia and eventually necrosis of the overlying skin. The standard of care has been aggressive repeated excision of the affected fascia and skin.<sup>1-3</sup>

In this article, we report on a patient with NF of the back following a liposuction procedure. Aggressive fascial debridement with relative preservation of the native skin formed the backbone of the treatment plan. This supports the argument against excising the relatively ischemic and cellulitic skin as long as it is viable.

## CASE PRESENTATION

A 23-year-old-woman, 2 years postsleeve gastrectomy for morbid obesity, underwent back liposuction and fat

grafting of bilateral hips at a cosmetic clinic. On the second postoperative day, she developed a high-grade fever with rigors and pain at the surgical site without local signs of infection. Although broad-spectrum intravenous (IV) antibiotics were started, her clinical status was deteriorating. Arriving at the emergency department at our institution, she had a high-grade fever (39.5°C), tachycardia (120/min), tachypnea (22/min), hypotension (90/50 mm Hg), and mild erythema around the right lower back liposuction incision, as shown in [Figure 1](#). On the premise of a strong suspicion of NF, she was taken to the theater for exploration.

After excising the erythematous patch of skin surrounding the incision site, 1.5 liters of foul-smelling serous fluid was drained from the back and right hip, as shown in [Figure 2](#). The skin was viable, while the entire fascia of the back was necrotic, extending from the interscapular area down to the left lower back and right buttock. Multiple horizontal drainage incisions were made over the right scapular border, below left scapula, right flank, over the right hip joint, lateral and medial right buttock, and the lower back. Through those incisions, the entire fascia of the back was exposed and the necrotic fascia was excised with preservation of the overlying skin. This was followed by triple-antibiotic pulse lavage wash and vacuum-assisted closure (VAC) dressing application with the foam applied at the multiple incisions.

The patient was admitted to the intensive care unit and placed on mechanical ventilation, nasogastric feeding tube, and paraenteral nutrition postoperatively. Empirical antibiotic therapy was initiated (piperacillin/tazobactam and vancomycin) then guided by culture and sensitivity reports, which showed that the serous fluid and fascia had harbored enterococcafecalis. More than 20 debridement procedures, all done through the existing incisions, were done. During the serial debridement, residual necrotic fascia and muscle were debrided. Only necrotic skin edges were debrided.

**Disclosure:** The authors have no financial interest to declare in relation to the content of this article.

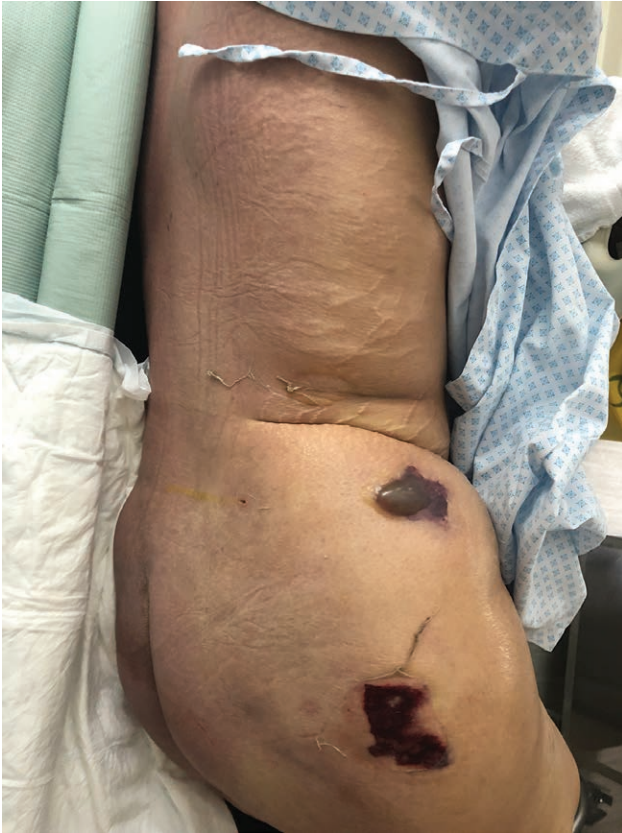From the \*Plastic and Reconstructive Surgery Section, Department of Surgery, King Faisal Specialist Hospital & Research Centre, Riyadh, Saudi Arabia; †ABAS Medical Centre, Riyadh, Saudi Arabia; ‡Orthopedic Surgery Department, King Abdulaziz University Hospital, Jeddah, Saudi Arabia; and §Plastic and Reconstructive Surgery Division, Department of Surgery, College of Medicine, King Saud University, Riyadh, Saudi Arabia.

Received for publication December 28, 2021; accepted February 2, 2022.

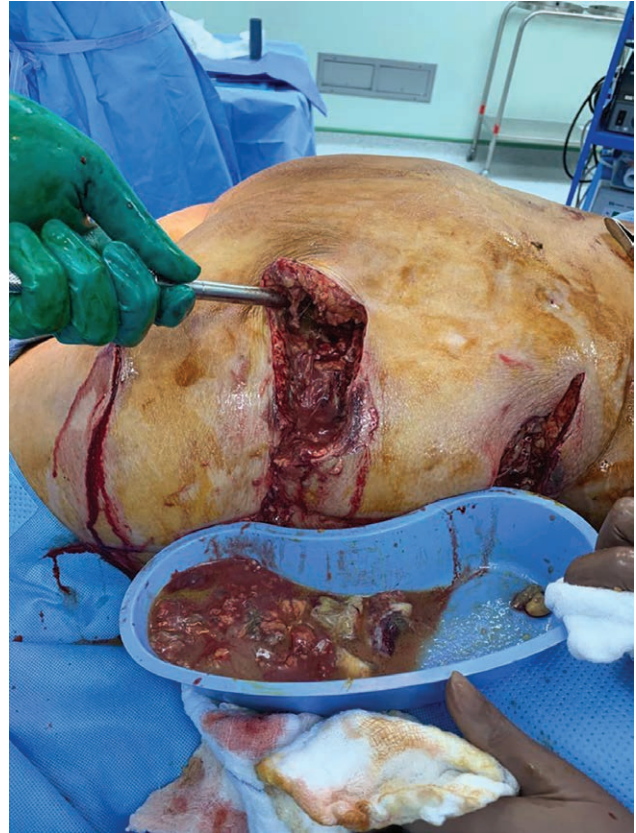
Drs AlMarshad and Shah Mardan are contributed equally to this work. This case report conforms to the Declaration of Helsinki.

Copyright © 2022 The Authors. Published by Wolters Kluwer Health, Inc. on behalf of The American Society of Plastic Surgeons. This is an open-access article distributed under the terms of the [Creative Commons Attribution-Non Commercial-No Derivatives License 4.0 \(CCBY-NC-ND\)](https://creativecommons.org/licenses/by-nc-nd/4.0/), where it is permissible to download and share the work provided it is properly cited. The work cannot be changed in any way or used commercially without permission from the journal.

DOI: [10.1097/GOX.0000000000004227](https://doi.org/10.1097/GOX.0000000000004227)



**Fig. 1.** Photograph showing the patient's condition preoperatively. Note the subtlety of the infection signs being limited to erythema and a small bullous.



**Fig. 2.** Photograph was taken during the first session of debridement, showing the necrotized tissue and diluted pus, due to copious irrigation.

VAC was used with each debridement. Furthermore, with the addition of repeated sessions of hyperbaric oxygen therapy, the condition of the patient and wound has drastically improved, negative cultures were eventually obtained, and healthy granulation tissue was seen under the viable large skin defect. Closure of the wound was done in four stages, two days apart each. In every stage, the granulation tissue was debrided and serial quilting sutures were applied with polyglecaprone 2-0, connecting the subcutaneous tissue with the underlying muscle. VAC was also applied to help adhere the skin graft to the underlying bed. Most of the skin defects were then closed and split-thickness skin graft was applied to the remaining bare areas.

One year later, the patient underwent staged scar revision procedures, with excision of the split-thickness skin graft with direct closure via skin mobilization. There was no need for tissue expansion. The patient demonstrated an excellent cosmetic outcome on 2-month follow-up visit (Figs. 3 and 4).

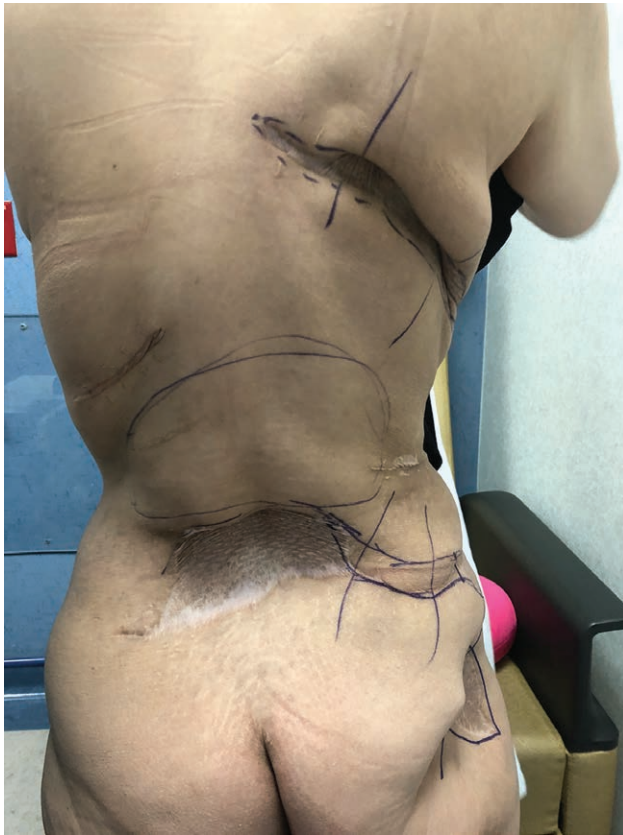## DISCUSSION

The infection in NF starts in the fascia, but then extends to the overlying skin and underlying muscle; unless treated promptly and aggressively, it is usually fatal.<sup>1</sup> The multiple surgical debridement sessions of the infected fascia and the overlying skin excision usually results in

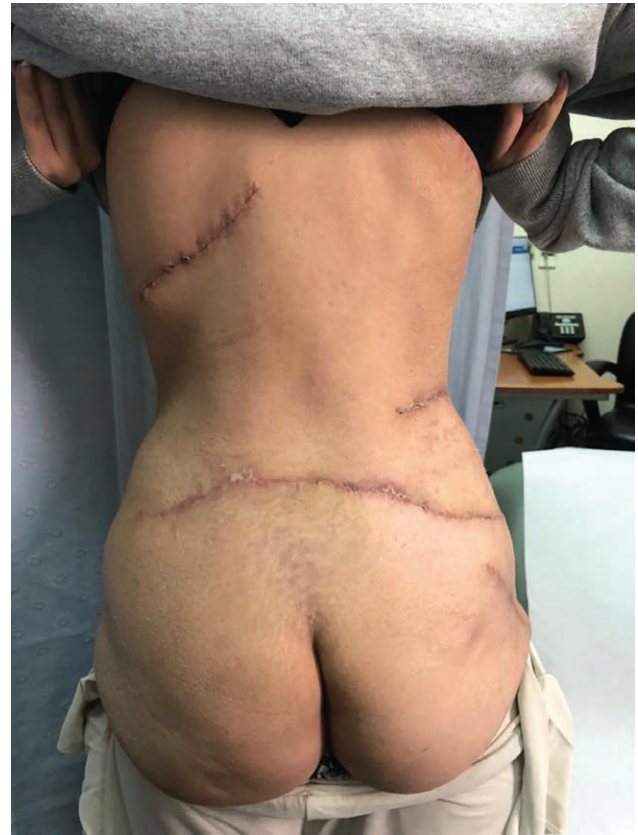large wounds and a poor final cosmetic outcome. Our case demonstrates that fascial excision with preservation of the relatively ischemic and cellulitic overlying skin is feasible. Obviously, any necrotic skin should be excised, but eventually the skin preservation will reduce the areas that will require skin grafting.

We revised the literature and found a similar case of NF with large skin flap reservation.<sup>4</sup> The patient was a 55-year-old man who developed NF of the buttock extending to the flank following an ischiorectal abscess. Although our case and the referenced case had demonstrated the concept and the possibility of skin preservation, there is a major difference in the access to the fascia. The first case raised a single skin flap and that was only possible because the area of NF was limited. However, in our case the area involving NF was very extensive and raising a single skin flap for access would likely result in skin necrosis of the raised flap. We demonstrate for the first time in the literature, access through multiple incisions is possible and probably safer in major NF involvement of a large anatomical area.<sup>4</sup>

VAC played an imperative role in facilitating the healing in our case. It has been well-documented that managing large wounds and cavities using VAC is superior to conventional modalities of wound care. Considered as a cutting-edge modality in wound care, VAC functions by creating negative pressure within the wound to approximate the edges. Also, it facilitates the removal of interstitial



**Fig. 3.** This photograph was taken more than 1.5 years from the skin grafting. As demonstrated, the plan was to excise the scars and skin graft, reapproximate as much as possible, and place a tissue expander in case primary closure was inapplicable.



**Fig. 4.** This photograph was taken 2 months after the primary closure of all previous scars and grafted areas. It demonstrates excellent cosmetic outcome.

fluid which increases blood flow to the wound, decreases the edema, and promotes healing.<sup>5</sup>

In addition to the VAC, sessions of hyperbaric oxygen therapy (HBOT) were used. The rationale behind using HBOT was to increase oxygen diffusion into the tissue as well as to reduce tissue swelling that occurs with inflammation, thus promoting angiogenesis that results in a faster healing process.<sup>6</sup> Moreover, HBOT creates a bacteria-free environment by preventing the growth of anaerobic bacteria, and by replenishing neutrophils stores that were previously depleted due to the tissue hypoxia. Last, as it aids in demarcating the viable area from the necrotized one, HBOT decreases the need for unnecessary tissue debridement, minimizing the overall tissue loss.<sup>6</sup> As native skin sacrifice was minimal, apart from the area on the lower right back, the reconstructive plan was direct closure or placement of tissue expanders; thankfully, direct closure was possible a year from the incident.

### CONCLUSIONS

Although extremely uncustomary, NF could be the catastrophic byproduct of the seemingly successful liposuction. Its impact may range from permanent disfigurement to mortality if not treated promptly and aggressively, usually at the cost of cosmesis. This case report provides a detailed description of a lady with NF who was treated in a minimal

manner that facilitated reconstruction later. This was only possible in the presence of adjuncts such as HBOT, VAC, and perhaps, most importantly, veterancy and expertise.

**Fuad K. Hashem, MD**

Plastic and Reconstructive Surgery Section  
Department of Surgery  
King Faisal Specialist Hospital & Research Centre  
P.O. Box 3354  
Riyadh 11211, Saudi Arabia  
E-mail: [Fuadkhashem@gmail.com](mailto:Fuadkhashem@gmail.com)

### REFERENCES

1. Misiakos EP, Bagias G, Papadopoulos I, et al. Early diagnosis and surgical treatment for necrotizing fasciitis: a multicenter study. *Front Surg*. 2017;4.
2. Shimizu T, Tokuda Y. Necrotizing fasciitis. *Intern Med*. 2010;49:1051–1057.
3. McHenry CR, Piotrowski JJ, Petrinic D, et al. Determinants of mortality for necrotizing soft-tissue infections. *Ann Surg*. 1995;221:558–63; discussion 563.
4. Perry TL, Phillip Heyse R, Little A, Johnson M. Large flap preservation in a patient with extensive necrotizing fasciitis: is vertical transmission of infection directly proportional to centrifugal spread of disease? *Wounds Compend Clin Res Pract*. 2010;22:146–150.
5. Yadav S, Rawal G, Baxi M. Vacuum assisted closure technique: a short review. *Pan Afr Med J*. 2017;28:246.
6. Leach RM, Rees PJ, Wilmshurst P. Hyperbaric oxygen therapy. *BMJ*. 1998;317:1140–1143.