

Case Report

Non-Specific Onset of Pulmonary AdenocarcinomaKAMAL CONSTANTIN KAMAL¹, LIGIA FLOREA¹, DIANA KAMAL²,
DRAGOS OVIDIU ALEXANDRU³, ADINA MARIA KAMAL⁴¹Department of Family Medicine, University of Medicine and Pharmacy of Craiova, Romania²Elga Clinic & University of Medicine and Pharmacy of Craiova, Romania³Department of Medical Informatics and Biostatistics,
University of Medicine and Pharmacy of Craiova, Romania⁴Department of Clinical Nursing-Internal Medicine,
University of Medicine and Pharmacy of Craiova, Romania

ABSTRACT: Skin metastases are rarely found in lung cancer compared to other types of neoplasia. Of the types of lung cancer that can have skin metastases, the most common one is adenocarcinoma. Pulmonary cancer metastasizing to the skin has poor prognosis, usually the survival rate of the patients is 4-6 months. We present the case of a 59-year-old woman, smoker, high blood pressure, dyslipidemia, with two skin erythematous-nodular lesions, incompletely delimited, with a diameter of 4-5cm, in the left arm (1/3 medio-external) and left latero-thoracic (near IV intercostal space) area, discovered during a regular medical examination at her family doctor's practice. After multiple clinical and paraclinical investigations, almost 3 months after the initial presentation, the patient was diagnosed with stage IV pulmonary adenocarcinoma with supra and subdiaphragmatic lymph-node metastases, soft tissue metastases, liver metastases and breast metastases. Oncological treatment was initiated, but the patient's progression was unfavorable, her passing occurring 6 months after being diagnosed.

KEYWORDS: Lung adenocarcinoma, skin lesions, metastases

Introduction

Lung cancer is the second type of neoplasia as incidence in the United States, after prostate cancer in men and breast cancer in women and is first globally. In 2012, 1.8 million new cases were reported globally, accounting for 13% of the total number of newly diagnosed malignancies [1]. The highest rate of pulmonary cancers is found in industrialized countries, North America and Europe. The predilection age is between 50-70 years of age, pathology being more common in men than in women [1].

Pulmonary neoplasms with non-small cell types represent 85% of the lung cancers diagnosed in the US. Lung adenocarcinoma along with squamous cell carcinoma and large cell carcinoma are the three types of lung cancer classified as non-small cell types lung cancers [1,2]. At the time of diagnosis, 20% of patients have tumors located at the pulmonary level, 25% have regional metastases and 55% are distant metastases [2].

Cutaneous, subcutaneous metastases as well as regional lymph node metastases are not common in lung cancer, but increased incidence of this type of neoplasia also increased the incidence of skin manifestations [3]. For non-small cell adenocarcinomas, the percentage of patients in whom cutaneous metastases have been described varies between 1 and 12%.

The most common areas where cutaneous metastases have been described are in the anterior thorax, abdomen, cervical region and scalp [3,4].

Case Presentation

We present the case of a retired 59-year-old woman from the urban area who presented at the family doctor's office for health assessment and the release of her monthly medical prescription, previously diagnosed with grade 2 hypertension, ischemic chronic hypertensive cardiopathy, mixed dyslipidemia, fatty liver, peripheral lower limb ischemia, bilateral knee osteoarthritis and type 1 osteoporosis. The patient had the following complaints: headache, arthralgia, myalgia, lower limb paresthesia.

Written consent was obtained from the family members of the deceased patient. All information presented in this paper is in accordance with General Data Protection Regulation (GDPR) laws.

Her family history was not significant, from her personal physiological history we retained two births, multiple abortions (on request), and menopause at the age of 48. The patient was a smoker for 20 years old, 10 cigarettes/day and alcohol-consuming in moderate amounts over the past 2-3 years.

After the examination we could describe the following: suffering facies, well-represented

abdominal-pelvic fatty tissue, bilateral axillary micro-poly-adenopathy, crackling at mobilization of the bilateral knee joints, reduced pulse at peripheral arteries, hepatomegaly. After measuring the physiological curves, we found that the patient was afebrile (36.9 degrees Celsius), blood pressure 140/80mm Hg, heart rate of 103bpm and a BMI of 28,5.

At the left arm exam (1/3 medio-external) and left-thoracic area (near intercostal space IV) there were two incompletely delimited ertitemato-nodular lesions with a diameter of 4-5cm, mobile on the superficial and deep planes, painful on palpation, the patient stated that these lesions appeared 7-10 days ago.

The family doctor recommended performing usual bloodwork and referred the patient for a surgical consult, with the diagnosis of referral-superinfected lipoma. The patient refused to perform a new set of laboratory tests on the grounds that they were performed only 3 months before presenting to the family doctor and the results did not reveal anything pathological, accepted the referral for the surgeon who confirmed the diagnosis of superinfected lipoma and recommended 10-day oral antibiotic treatment.

After the treatment, the patient returned to the family doctor, he found the previously described ertitemato-nodular formations with a slightly improved clinical appearance compared to the first consultation. In the hope that she will change her mind, her family physician completed a referral note indicating the following laboratory tests (HLG, VSH, blood glucose, urea, creatinine, uric acid, urine summary exam, TGO, TGP, lipidogram, serum protein electrophoresis, TQ) and to perform an abdominal ultrasound.

After 17 days, the patient returned with the result of the laboratory tests showing only these modified values: Leucocytes=12000/mmc, Granulocytes=71%, VSH=55mm/1h, 90mm/2h, Cholesterol=258mg/288mg/dl, LDL Cholesterol =158mg/dl, Alpha 2 globulin=17.74%.

Based on non-specific inflammatory markers (VSH, leukocytes, α 2 globulins) a lymphoproliferative syndrome was suspected, and the patient was referred to the hematologist. After about 30 days the patient returned with the diagnosis of the lymphoproliferative syndrome diagnosed by the hematologist.

Due to persistent skin lesions and changes in laboratory values, the family doctor directed the patient to another physician, this time an internal medicine physician for an "in extenso"

assessment. The patient was examined by an internal medicine doctor and he asked for a new hematological consult, and a biopsy of the iliac crest and medulogram. As a result, the diagnosis of lymphoproliferative syndrome was invalidated.

Internal medicine further recommended performing an abdominal-pelvic and soft tissue ultrasound along with a thoraco-abdominal CT scan.

The result of CT scan revealed: pulmonary tissue mass of approximately 40/38mm in the apical segment (Fig.1), necrotic anterior mediastinum, supraclavicular and axillary adenopathies, (Fig.2), 4.1cm mass located on in the antero-lateral thorax, necrotic liver mass 3.3cm in diameter (Fig.3). Non-homogeneous secondary haematogenic determinations, in the adrenal glands (Fig.4). In the lumbar paravertebral muscles, non-homogeneous tissue masses 8.1cm in diameter right and 3.8cm left without secondary bone determinations, without fluid in the peritoneal cavity. The breast ultrasound revealed nodular, hypoechoic formations of 2.5cm, 2.3cm, 2cm, polycyclic contour, hyper vascularized.

A biopsy of the thoracic tumor was recommended and performed, histopathological examination revealed: an encapsulated mass with massive malignant cellular proliferations, sometimes with intracytoplasmic inclusions, with frequent atypical mitosis and necrosis sites. The immunohistochemical examination of the formation with the following markers: CK7, TTF1, VIM, CEA, S100, CD20, CD45RO, revealed the histopathological diagnosis of lymph node metastases of a non-small cell lung carcinoma.

The complete diagnosis after almost 3 months of the first presentation was stage IV lung adenocarcinoma with supra and subdiaphragmatic node metastases, soft tissue metastases, liver metastases and right breast metastases.

The patient was referred to an oncologist, who, with the approval of the National Oncology Commission initiated treatment with Avastin. However, the patient's progression was unfavorable, with exitus at 6 months after initial diagnosis.

The particularity of the case: the existence of a discrepancy between the clinical condition of the patient and the severity of the diagnosis, as well as the detection of non-specific skin lesions which proved to be cutaneous metastases of a lung adenocarcinoma.

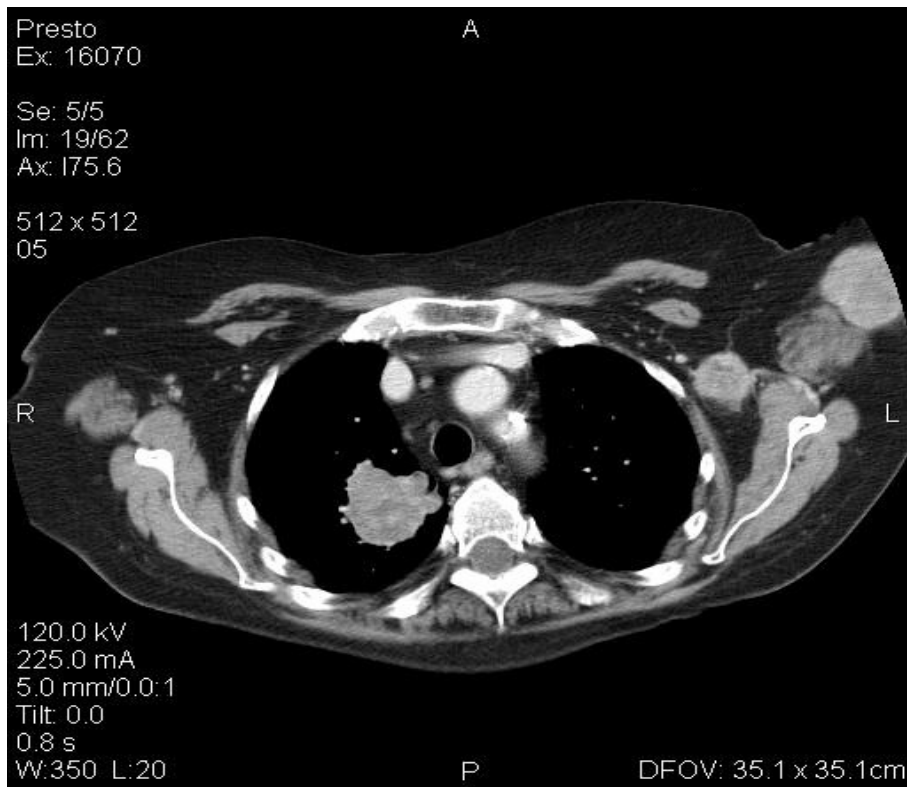


Fig.1. Postcontrast CT, axial section, pulmonary tissue mass, right apical segment, non-homogeneous, 40/38 mm diameter

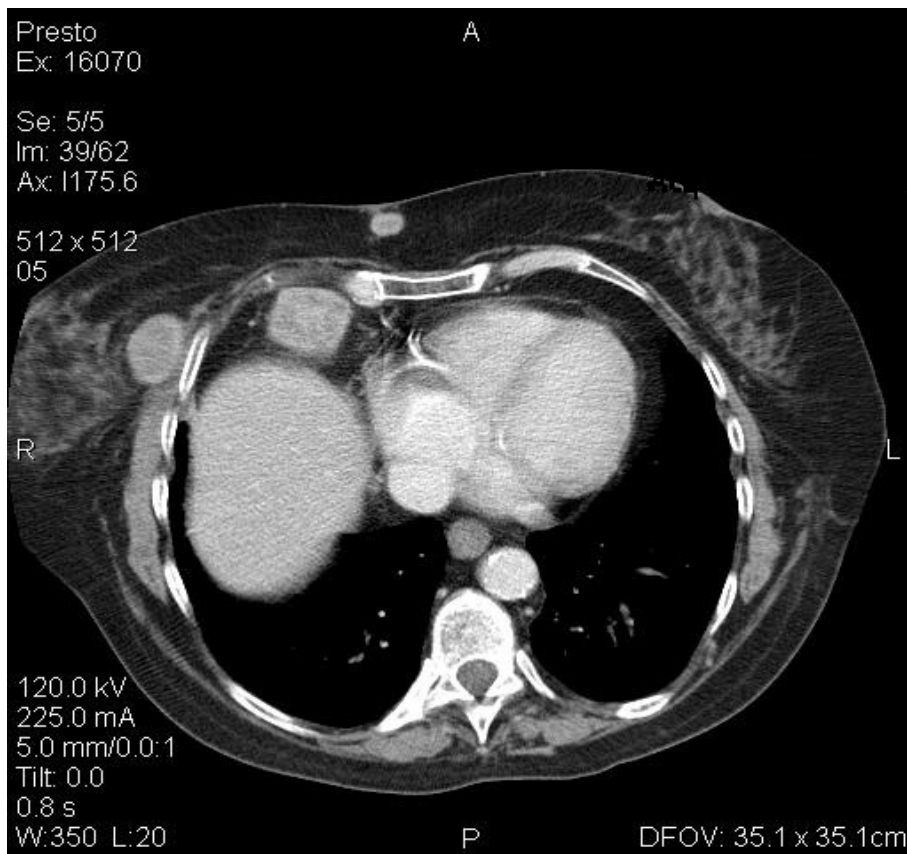


Fig.2. Postcontrast CT, axial section, secondary lymphogenic determinations, left axillar, right breast and inter-mammary chain

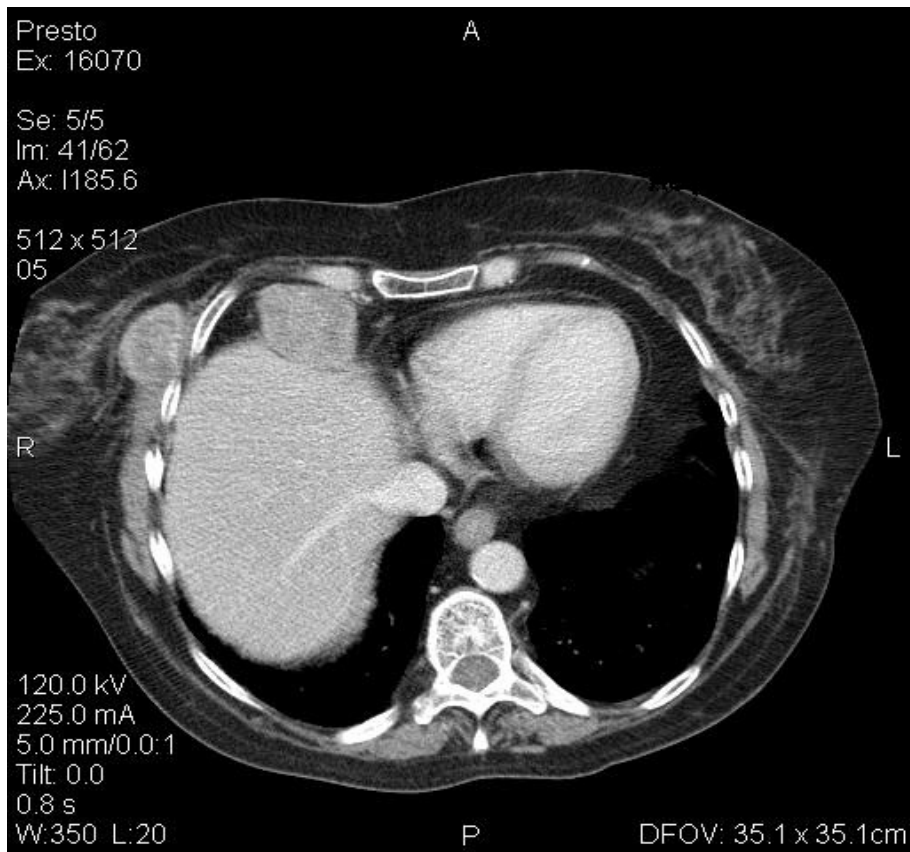


Fig.3. Postcontrast CT, axial section, necrotic liver mass, 3.3cm diameter

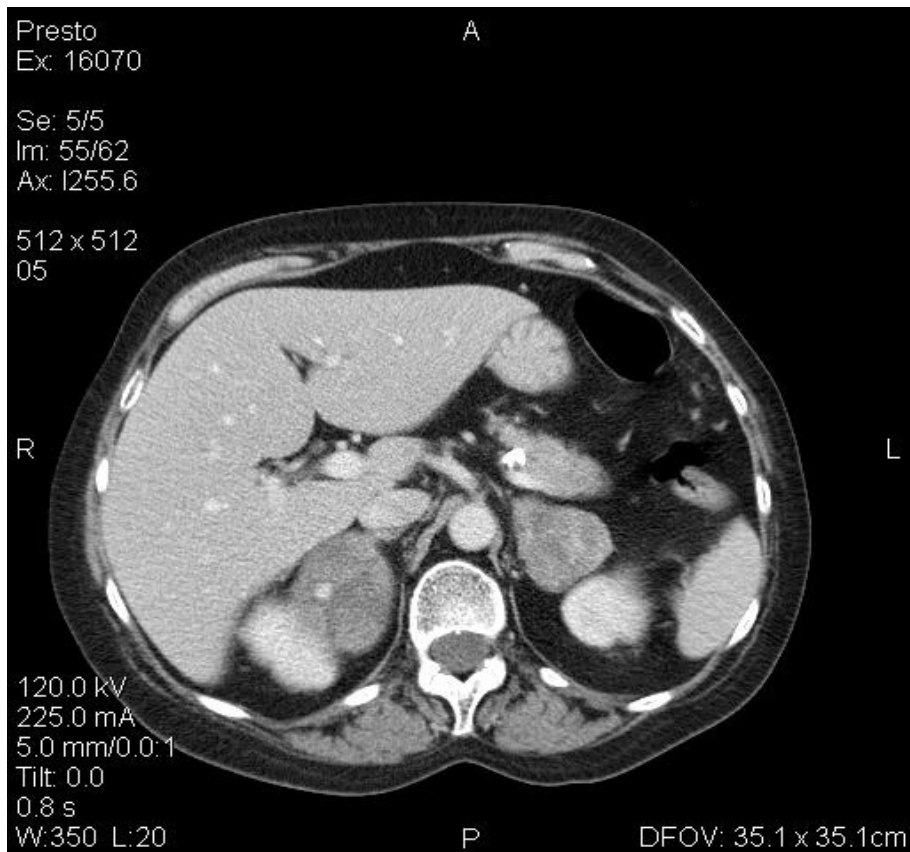


Fig.4. Postcontrast CT, axial section, non-homogeneous secondary haematogenic determinations, in the adrenal glands

Discussions

Due to the increase in the prevalence of lung cancer, there is an increase in the number of cases in which skin, subcutaneous or superficial lymph nodes metastases appear [4].

Cutaneous metastases are less common in lung cancer compared to other types of cancer [5].

The incidence of cutaneous metastases varies between 1 and 12% in patients diagnosed with different types of lung cancer [4-6].

There are studies in which cutaneous metastases are found in 24% of patients diagnosed with lung cancer [7].

The examination of the skin during the standard clinical examination plays a particularly important role in the detection of some types of internal organs neoplasia. Early diagnosis increases the chances of survival of patients by establishing cancer treatment as quickly as possible [8].

In the objective examination of the patient presented, two left-hand (1/3 medio-external) and left-thoracic (near IV intercostal sphincter) two formations, incompletely delimited, with a diameter of 4-5cm, mobile on superficial and deep planes, painful palpation. Cutaneous metastases are located in the anterior chest region, abdominal wall, neck, and scalp. Rarely, these types of lesions are encountered in the flanks or lower and upper limbs [4].

All types of lung cancer can metastasize to the skin, and the lesions can have multiple aspects [6,9].

In general, skin lesions have nodular aspects, are single or multiple, with a diameter of 1 to 5cm [5], may be mobile or fixed to superficial and deep planes, often painless [6].

The erythematous skin lesions detected in our patient's left arm (1/3 medio-external) and left latero-thoracic (near IV intercostal spine) did not give up on antibiotic treatment, their appearance being very little changed after performing it. Sometimes skin lesions take the appearance of an area of persistent erythema that can be observed for months and that does not disappear in topical or systemic treatment [10].

In patients who have been described, such injuries have disappeared just a few days after excision of the primary tumor found in the lung [10].

Any skin lesion should be investigated with a biopsy and subject to histological and immunohistochemical examination, especially in

patients presenting risk factors for developing a neoplasia [11,12].

The immunohistochemical examination of our patient's lesions with the following markers: CK7, TTF1, VIM, CEA, S100, CD20, CD45RO, revealed that it was a non-small cell lung cancer lymph node metastases".

Immunohistochemical markers are very important for the primary tumor, when clinical and paraclinical data are conclusive. Of these, the most useful in highlighting pulmonary neoplasia are TTF (adenocarcinoma transcription factor) specific for adenocarcinoma, bronchoalveolar carcinoma and small cell carcinoma, as well as CK7 and CK20 with high specificity in the detection of adenocarcinomas and bronchoalveolar carcinomas [4,13].

Cutaneous metastases are less common in lung cancer compared to other types of cancer [5].

The incidence of cutaneous metastases varies between 1 and 12% in patients diagnosed with different types of lung cancer [4-6].

There are studies in which cutaneous metastases are found in 24% of patients diagnosed with lung cancer [7].

The complete diagnosis with which the patient returns the family doctor about 3 months after the first presentation is stage IV lung adenocarcinoma with supra-and subdiaphragmatic lymph node metastases, soft tissue metastases, liver metastases and right breast metastases.

In patients diagnosed with lung cancer with cutaneous metastases, it was observed that other types of primary tumor metastases in the internal organs and in the mammary gland already existed or were discovered [4-6,14].

The occurrence of cutaneous metastases is usually reported within 5-6 months of lung tumor diagnosis. In 20-60% of cases, cutaneous metastases occur prior to the discovery of pulmonary neoplasia [4].

Primary lung tumors can also be detected one year after cutaneous metastases [12].

Among the types of lung cancer that metastasize to the skin, the most frequent is adenocarcinoma [14], followed by squamous cell carcinoma, small cell carcinoma, the latter frequency being large cell carcinomas [4].

In patients with cutaneous metastases, treatment is usually surgical, accompanied by chemotherapy and/or radiotherapy. If other types of metastases coexist in these patients, elective treatment is chemotherapy [6].

The patient's progression was severe with exitus after 6 months from the moment of diagnosis. Lung cancer metastasizing to the skin has a poor prognosis, as seen in particular in advanced stages of the disease, the patient usually has a survival rate of 4-6 months [4-7,14,15].

Conclusions

Patients with risk factors such as smokers who experience persistent skin lesions should be referred in order to perform detailed clinical and paraclinical investigations.

Pulmonary neoplasms accompanied by cutaneous metastases have a particularly severe prognosis and death typically occurs within approximately 6 months of diagnosis.

References

1. Ferlay J, Soerjomataram I, Dikshit R, Eser S, Mathers C, Rebelo M, Parkin M, Forman D, Bray F. Cancer incidence and mortality worldwide: Sources, methods and major patterns in GLOBOCAN 2012, 2015, 136(5):E359-E386.
2. Siegel RL, Miller KD, Jemal A. Cancer Statistics, 2018. *CA Cancer J Clin*, 2018, 68(1):7-30.
3. Edwards BK, Brown ML, Wingo PA, Howe HL, Ward E, Ries LA, Schrag D, Jamison PM, Jemal A, Wu XC, Friedman C, Harlan L, Warren J, Anderson RN, Pickle LW. Annual report to the nation on the status of cancer, 1975-2002, featuring population-based trends in cancer treatment. *J Natl Cancer Inst*, 2005, 97(19):1407-1427.
4. Bhattarai B, Schmidt MF, Ghosh M, Ray AS, Manhas S, Oke V, Agu CC, Basunia MR, Enriquez D, Quist J, Bianchi C, Hans R, Kandel S. Lung Cancer with skin and breast metastases: a case report and literature review. *Case Reports in Pulmonology*, 2015, 2015:136970.
5. Hidaka T, Ishii Y, Kitamura S. Clinical features of skin metastases from lung cancer. *Internal Medicine*, 1996, 35 (6):459-462.
6. Mollet TW, Garcia CA, Koester G. Skin metastases from lung cancer. *Dermatol Online J*, 2009, 15(5):1-5.
7. Molina Garrido MJ, Mora Rufete A, Guillen Ponce C, Macia Escalante S, Carrato Mena A. Skin metastases as first manifestation of lung cancer. *Clin Transl Oncol*, 2006, 8(8):616-617.
8. Abreu Velez AM, Howard MS. Diagnosis and treatment of cutaneous paraneoplastic disorders. *Dermatol Ther*, 2010, 23(6):662-675.
9. Sabir S, James WD, Schuchter LM. Cutaneous manifestations of cancer. *Curr Opin Oncol*, 1999, 11(2):139-144.
10. Takada N, Kusuhara N, Yanase N, Abe T, Tomita T. Lung cancer accompanied by erythema. *Intern Med*, 1992, 31(6):770-773.
11. Ambrogi V, Nofroni I, Tonini G, Mineo TC. Skin metastases in lung cancer: analysis of a 10-year experience. *Oncology Reports*, 2001, 8(1):57-61.
12. Lomholt H, Thestrup-Pedersen K. Paraneoplastic skin manifestations of lung cancer. *Acta Derm Venereol*, 2000, 80(3):200-202.
13. Capelozzi VL. Role of immunohistochemistry in the diagnosis of lung cancer. *J Bras Pneumol*, 2009, 35(4):375-382.
14. Dhambri S, Zendah I, Ayadi-Kaddour A, Adouni O, El Mezni F. Cutaneous metastases of lung carcinoma: a retrospective study of 12 cases. *J Eur Acad Dermatol Venereol*, 2011, 25(6):722-726.
15. Glisic A, Subramanian V. Cutaneous manifestation of a primary lung cancer. *Journal of the American Osteopathic College of Dermatology*, 2010, 18(1):13-17.

Corresponding Author: Diana Kamal, University of medicine and Pharmacy of Craiova, Elga Clinic, Str. Mihai Eminescu Nr. 32, 200131 Craiova, Romania, e-mail: dianakamal84@gmail.com