



Original Article

Infrared thermography mapping plus neuronavigation target location in an eloquent area cavernoma resection

Enrique de Font-Réaulx¹, Ramón López López², Luis Guillermo Díaz López³

Departments of ¹Neurosurgery and ³Anesthesiology, Centro Médico ABC, ²Department of Neurosurgery, High Specialty Medical Unit, La Raza Hospital, Mexican Social Security Institute, Mexico City, México.

E-mail: *Enrique de Font-Réaulx - defontreaulx@hotmail.com; Ramón López López - dr_ramonzl@hotmail.com; Luis Guillermo Díaz López - luisdiazl@hotmail.com



***Corresponding author:**

Enrique de Font-Réaulx,
Department of Neurosurgery,
Centro Médico ABC,
Mexico City, México.

defontreaulx@hotmail.com

Received : 30 July 19

Accepted : 26 February 20

Published : 13 March 2020

DOI

10.25259/SNI_435_2019

Quick Response Code:



ABSTRACT

Background: Safety and efficacy are irrefutable goals in neurosurgery.

Methods: We performed a subcortical cavernoma resection in an eloquent area, where we recorded and compared the maximal and minimal brain temperature measured by an infrared thermographic camera and thermometer with the neuronavigation (NN) target location and real anatomical lesion location.

Results: The hottest cortical point correlated to the subcortical cavernoma location. The NN located the target at 10 mm away from the hottest point.

Conclusion: More studies are needed to better understand the thermic radiation of the brain in health and in disease, but we believe that evaluating brain temperature, it could be possible to improve accuracy in neurosurgery and generate more knowledge about brain metabolism *in vivo*.

Keywords: Brain shift, Brain temperature, Cavernoma, Eloquent area, Infrared thermography mapping, Neuronavigation

INTRODUCTION

Accuracy in neurosurgery is mandatory. Neuronavigation (NN) systems are useful surgical guiding systems, but they have well known limitations. In many surgical scenarios, NN can misguide to false locations mainly due to the brain shift phenomenon and deformation.^[2,6,8,12,15] To perform safer and more efficient surgeries, particularly in surgery in eloquent areas, it is necessary to add *in vivo* information to increase the accuracy in locating surgical targets (computed tomography [CT], brain mapping, magnetic resonance [MR], ultrasound, and trans-operative fluorescence angiography, among others).

Cavernomas make up approximately 8–15% of all intracranial vascular malformations, and the most common presenting symptom is seizures.^[13] They can be located near the cortical surface in silent regions or in more challenging subcortical locations near eloquent areas.

Since the first documented inflammation description by Aulus Cornelius Celsus (25 AC–50 AD) in *De Medicina*, it is known that inflammation causes hyperthermia. The thermic radiation evaluation of the brain could be useful trans-operative information, as thermographic cameras,

This is an open-access article distributed under the terms of the Creative Commons Attribution-Non Commercial-Share Alike 4.0 License, which allows others to remix, tweak, and build upon the work non-commercially, as long as the author is credited and the new creations are licensed under the identical terms.

©2020 Published by Scientific Scholar on behalf of Surgical Neurology International

thermometers, and qualitative thermosensitive materials can measure brain metabolism by its caloric radiation. They have been used for studying the brain temperature in different pathophysiological processes^[11] and they allow for real-time evaluation of cerebral blood flow in vascular neurosurgery.^[7,14] Neoplasms and normal tissue produce and transfer heat in a different manner due to a decreased metabolic rate of the tissues surrounding and superimposed by the perilesional edema and low tumor microvessel density due to concomitant ischemia.^[10] Glial tumors are hypothermic and brain metastases are hyperthermic in comparison with healthy brain tissue, and infrared thermography mapping (ITM) can improve the accuracy of their resection.^[3] ITM in neurosurgery has been used with good results to monitor cerebral blood flow after the resection of an arteriovenous malformation, to observe patency of bypass and to prevent irreversible damage due to ischemia during surgery, in temporary occlusion of brain arteries, among other scenarios.^[1,5,7,9,10,14,16] Intraoperative IT is becoming a promising new real-time diagnostic method because it is non-invasive, radiation free, avoids exposing the patient to drugs or contrast media and it has no known side effects.

MATERIALS AND METHODS

Clinical Presentation

A right-handed 22-year-old male described progressive anomia, aphasia, and agraphia for the past 2 years, with 2–5 min episodes of acute worsening of symptoms presented in average every 2 weeks. He was treated with a short course of valproate acid without improvement under the supervision of another physician. He is the product of a twin normoevolutive pregnancy. During the physical examination, a non-fluent agrammatism, anomia, and a subtle right hemiparesis were documented. A TC showed a subcortical hyperdense lesion of 2 cm × 1.6 cm × 1.5 cm in the left supramarginal gyrus region. A recent electroencephalogram was normal.

RESULTS

Description of the procedure and results

Under entropy-monitored general intravenous anesthesia, we performed a conventional frontoparietotemporal left craniotomy guided by NN (Medtronic® optical neuronavigation system). Anesthetic profundity measured by entropy was 46, inspired fraction of oxygen was 60%, oxygen saturation was 100%, hemoglobin (14.3 g), hematocrit (42%), and carbon dioxide (32.3) by arterial blood gas. Corporal temperature was 35.2°C and the operating room temperature was 20°C, with a relative humidity of 40% during the ITM. Immediately after the dura incision, we performed a panoramic ITM of the exposed brain surface

using a professional handheld thermal imaging camera that combines the functions of surface temperature and real-time thermal imaging that can turn a thermal image into a visible image [Figure 1] with the center of the record over the supramarginal gyrus. It evaluates the different thermal gradients of the brain and it can also blend the visible and infrared images (Kmoon Handheld thermal imaging camera, temperature range –20–+300°C, measuring accuracy ±2% or ±2°C). Immediately after taking the panoramic ITM photograph, we placed a sterile acetate grid with coordinates to record the cortical temperature using an infrared pointer thermometer (Floureon –50–+380°C). Cortical temperature went from 23.8°C to 33.9°C, where the hottest point was in the supramarginal gyrus [Table 1].

Using the NN, we located the shortest cortex entry zone to the lesion [Figure 2]. Using a trans-sulcal approach, we began the white matter dissection, realizing that the lesion was located about 10 mm toward the vertex and the resection was completed [Figure 3]. The closure was closed with standard techniques and materials. The patient was discharged on the 5th postoperative day with a similar preoperative documented aphasia and anomia, without any added morbidity. The

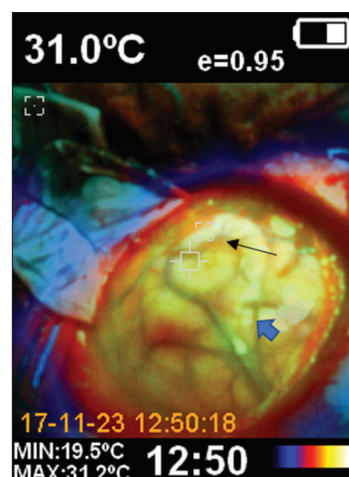


Figure 1: Panoramic thermographic photograph of the craniotomy, where the left frontal, parietal, and occipital lobes are exposed. The black arrow shows the hottest point of the exposed brain cortex, located in the supramarginal gyrus. The blue arrow shows the intraparietal sulcus.

Table 1: ITM recordings using the sterile acetate grid with coordinates. The hottest point (coordinate B1) was in the supramarginal gyrus. Each color has an interval of 2.5°C.

D0=32.7	D1=33.7	D2=30.1	D3=29.4	D4=30.8	
C0=33.5	C1=33.8	C2=30.9	C3=28.9	C4=29.2	
B0=31.9	B1=33.9	B2=33.2	B3=28.6	B4=30.5	
A0=26.1	A1=29.1	A2=29.1	A3=27.6	A4=23.8	
■ 33.9,	■ 31.5–33.8,	■ 29.0–31.4,	■ 26.5–28.9,	■ 23.9–26.4,	■ 23.8

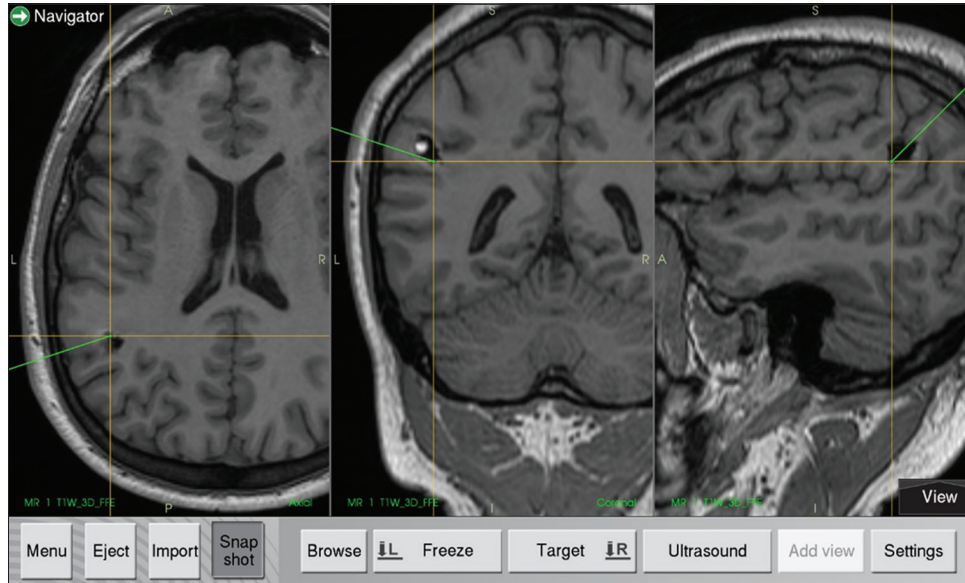

Figure 2: Neuronavigation location of the target.

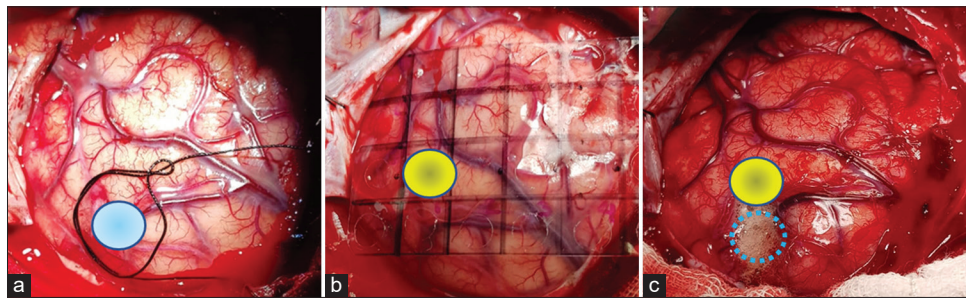


Figure 3: (a) Neuronavigation system localization of the target (blue circle); (b) Grid placement for the pointer thermographic recording where the yellow circle represents the hottest thermographic recording [coordinate B1 of Table 1] over the supramarginal gyrus; (c) A trans-sulcal access was performed in the point where the neuronavigation system located the lesion (dotted blue circle). The yellow circle represents the real subcortical localization of the cavernous angioma. The proximity of the hottest thermographic recording to the real localization of the lesion is evident.

speech difficulties were absent 3 months after the surgery and the patient has no focal language seizures.

DISCUSSION

Watson *et al.* observed that changes in blood temperature are related to changes in brain blood flow, whereas cortical brain temperature is determined by cerebral blood flow-metabolism coupling and the infrared image could be sufficiently sensitive to detect ischemia.^[3,9] Arterial blood and core temperatures are higher than that of the exposed surface of the brain since they descend due to evaporation and exposure to the environment. Therefore, local microvascular blood flow self-regulation of the brain can be used for monitoring thermal contrast with ITM of the cerebral cortex during surgery. Gorbach *et al.* showed immediate and significant temperature decrease in the artery distal to the occlusion and the tissue perfused by

it.^[3,5] Intra-operative surveillance using thermography in neurosurgery has been described in the resection of tumors and in the monitoring of patency of bypass in arteriovenous malformations, in which it demonstrated adequate correlation compared with such conventional methods as postoperative CT, MR imaging (MRI), Doppler and angiography, and its potential use for 2D-3D image fusion with preoperative MRI.^[4] ITM is a safe, efficient, and real-time non-invasive method that requires no manipulation of the tissues nor does it require the use of contrasts or filters.

Based on the previously described evidence that establishes the efficacy of ITM for detecting even subtle blood flow changes, we describe a case where a subcortical cavernoma below the supramarginal gyrus was the surgical target. The NN system located an entry point that was approximately 10 mm misplaced due to the brain shift, as was demonstrated later during the surgery. Before the trans-sulcal approach

was performed, using a thermographic camera and thermographic thermometer, we detected a hotter cortical point (difference in temperature between the hottest and coldest cortical recording was 10.1°C) in the supramarginal gyrus surface at approximately 4 mm dorsal to the shortest cortical distance to the reallocation of the cavernoma. Two different technologies acted together to improve the target location accuracy in this case. The patient stayed within stable physiological hemodynamic parameters during the surgical procedure to maintain cerebral self-regulation.

CONCLUSION

More studies are needed to understand and predict the thermic behavior of the brain in physiological and in different pathological conditions, to incorporate temperature measurement devices, such as thermographic thermometers, cameras, or qualitative thermographic devices in daily neurosurgical procedures, but we believe that this is a promising avenue to explore. It could be useful to incorporate more than one device to improve target location accuracy in neurosurgery.

Declaration of patient consent

Patient's consent not required as patients identity is not disclosed or compromised.

Financial support and sponsorship

Nil.

Conflicts of interest

There are no conflicts of interest.

REFERENCES

- de Font-Réaulx Rojas E, Martínez Ochoa EE, López López R, López Díaz LG. Infrared thermography brain mapping surveillance in vascular neurosurgery for anterior communicating artery aneurysm clipping. *Surg Neurol Int* 2018;9:188.
- Fan X, Roberts DW, Schaewe TJ, Ji S, Holton LH, Simon DA, *et al.* Intraoperative image updating for brain shift following dural opening. *J Neurosurg* 2017;126:1924-33.
- Gorbach AM, Heiss J, Kufta C, Sato S, Fedio P, Kammerer WA, *et al.* Intraoperative infrared functional imaging of human brain. *Ann Neurol* 2003;54:297-309.
- Hoffmann N, Weidner F, Urban P, Meyer T, Schnabel C, Radev Y, *et al.* Framework for 2D-3D image fusion of infrared thermography with preoperative MRI. *Biomed Tech (Berl)* 2017;62:599-607.
- Hollmach J, Hoffmann N, Schnabel C, Küchler S, Sobottka S, Kirsch M, *et al.* Highly sensitive time-resolved thermography and multivariate image analysis of the cerebral cortex for intrasurgical diagnostics. *Ther Diagn* 2013;8565:1605-7422.
- Keles GE, Lamborn KR, Berger MS. Coregistration accuracy and detection of brain shift using intraoperative sononavigation during resection of hemispheric tumors. *Neurosurgery* 2003;53:556-62.
- Mery F. Tecnología y neurocirugía. *Rev Chil Neuro Psiquiat* 2010;48:173-4.
- Nabavi A, Black PM, Gering DT, Westin CF, Mehta V, Pergolizzi RS Jr., *et al.* Serial intraoperative magnetic resonance imaging of brain shift. *Neurosurgery* 2001;48:787-97.
- Nakagawa A, Fujimura M, Arafune T, Sakuma I, Tominaga T. Intraoperative infrared brain surface blood flow monitoring during superficial temporal artery-middle cerebral artery anastomosis in patients with childhood moyamoya disease. *Childs Nerv Syst* 2008;24:1299-305.
- Naydenov E, Minkin K, Penkov M, Nachev S, Stummer W. Infrared thermography in surgery of newly diagnosed glioblastoma multiforme: A technical case report. *Case Rep Oncol* 2017;10:350-5.
- Neves EB, Vilaça-Alves J, Rosa C, Reis VM. Thermography in neurologic practice. *Open Neurol J* 2015;9:24-7.
- Nimsky C, Ganslandt O, Cerny S, Hastreiter P, Greiner G, Fahlbusch R. Quantification of, visualization of, and compensation for brain shift using intraoperative magnetic resonance imaging. *Neurosurgery* 2000;47:1070-9.
- Pamias-Portalatin E, Duran IS, Ebot J, Bojaxhi E, Tatum W, Quiñones-Hinojosa A. Awake-craniotomy for cavernoma resection. *Neurosurg Focus* 2018;45:V3.
- Raabe A, Nakaji P, Beck J, Kim LJ, Hsu FP, Kamerman JD, *et al.* Prospective evaluation of surgical microscope-integrated intraoperative near-infrared indocyanine green videoangiography during aneurysm surgery. *J Neurosurg* 2005;103:982-9.
- Roberts DW, Hartov A, Kennedy FE, Miga MI, Paulsen KD. Intraoperative brain shift and deformation: A quantitative analysis of cortical displacement in 28 cases. *Neurosurgery* 1998;43:749-58.
- Watson JC, Gorbach AM, Pluta RM, Rak R, Heiss JD, Oldfield EH. Real-time detection of vascular occlusion and reperfusion of the brain during surgery by using infrared imaging. *J Neurosurg* 2002;96:918-23.

How to cite this article: de Font-Réaulx E, López López R, Díaz López LG. Infrared thermography mapping plus neuronavigation target location in an eloquent area cavernoma resection. *Surg Neurol Int* 2020;11:44.