

Giant hepatic metastasis in a patient with coin-like small cell lung carcinoma incidentally diagnosed at autopsy

A case report

Decebal Fodor, MD, PhD^a, Simona Gurzu, MD, PhD^{a,b,c,*}, Anca Otilia Contac, MD^c, Ioan Jung, MD, PhD^a

Abstract

Rationale: Encephalopathy is a rare complication of hepatic metastases. In this paper we present a case of a patient with lung cancer and metastatic-related giant hepatomegaly.

Patient concerns: A 78-year-old previously healthy male was admitted in the Emergency room in hepatic coma.

Diagnoses: The abdominal CT scan examination revealed a huge liver filled with solid nodules.

Interventions: No interventions were performed.

Outcomes: The patient died at few hours after hospitalization. The autopsy showed a 6.5 kilograms liver with several whitish metastatic nodules and an occult prostate adenocarcinoma. The hilum of both lungs was free of tumor and a 10 mm white nodule was identified surrounding a small bronchus. No peripheral nodules were macroscopically identified. Under microscope, cluster of small cells were observed encasing a small bronchus with multiple minute coin-shaped subpleural foci. A massive intrapulmonary angiolymphatic invasion and metastases from small cell carcinoma in liver, lymph nodes and iliac crest bone marrow were also diagnosed.

Lessons: This case highlights the difficulty of diagnosis of aggressive lung carcinomas and the necessity of checking for metachronous tumors. The encephalopathy might be the result of metastatic damage of the liver parenchyma combined with the paraneoplastic effect of the tumor cells. Few than 25 cases of SCLCs with diffuse liver metastases and fulminant liver failure were reported to December 2016. This is the first reported case with a synchronous prostate cancer and a “coin-like” aspect of the SCLC.

Abbreviations: CT = computed tomography, SCLC = small cell lung carcinoma.

Keywords: bone, encephalopathy, liver, prostate, small cell carcinoma

1. Introduction

Small cell lung carcinoma (SCLC) is a common malignant tumor that is usually diagnosed in heavy smokers as a central tumor mass. The main symptoms of patients are respiratory disorders or a wide variety of paraneoplastic syndromes that usually include endocrine disorders (Cushing disease, Addison’s syndrome, and hypoglycemia), hematological disturbances (pancytopenia, myelodysplastic syndrome, and coagulopathy), or neurological syndromes (encephalomyelopathy, cerebellar degeneration, opsoclonus myoclonus ataxia, Eaton–Lambert myastenic syndrome, and acute Guillain–Barre syndrome)^[1–3].

In this paper, we present an unusual case of SCLC with fulminant behavior diagnosed in a patient with occult adenocarcinoma of the prostate. The particularities of the case are also its incidental diagnosis at autopsy, the small shape of the primary tumor and the huge metastatic liver, presence of the “coin-like” aspect (microscopic foci below pleura), and presence of the rapidly progressive encephalopathy. Only 18 cases of SCLCs with diffuse liver metastases and fulminant liver failure have been published between 1979 and 2015.^[4] No one of these cases showed a “coin-like” aspect even a synchronous tumor.

2. Case presentation

A 78-year-old previously healthy male heavy smoker presented at the Emergency Department with generalized jaundice (sclera and skin), ascites, and hepatic coma. The relatives declared that he was known to have a urinary bladder carcinoma that was diagnosed at a routine control performed 3 months before but no medical papers to prove this diagnosis were shown. They also mentioned a 2-month history of progressive jaundice, somnolence, and temporary loss of consciousness. No weight loss or other clinical signs were mentioned. No previously viral hepatitis or drug excess was reported. No family history of cancer was declared.

At the present admission, the abdominal CT scan showed marked hepatomegaly with multiple small nodules (2–10 mm in diameter) that was supposed to be hepatic metastases from the bladder carcinoma. The thoracic x-ray showed a bilateral bronchopneumonia without abnormal opacities. The patient died with hepatic encephalopathy at 7 hours after admission.

Editor: Jian Liu.

The authors have no funding and conflicts of interest to disclose.

^a Department of Pathology, ^b Research Center of University of Medicine and Pharmacy, ^c Department of Pathology, Clinical County Emergency Hospital, Tirgu-Mures, Romania.

* Correspondence: Simona Gurzu, Department of Pathology, University of Medicine and Pharmacy, Tirgu Mures, Romania (e-mail: simonagurzu@yahoo.com).

Copyright © 2017 the Author(s). Published by Wolters Kluwer Health, Inc. This is an open access article distributed under the Creative Commons Attribution-No Derivatives License 4.0, which allows for redistribution, commercial and non-commercial, as long as it is passed along unchanged and in whole, with credit to the author.

Medicine (2017) 96:11(e6366)

Received: 29 December 2016 / Received in final form: 14 February 2017 /

Accepted: 21 February 2017

<http://dx.doi.org/10.1097/MD.00000000000006366>

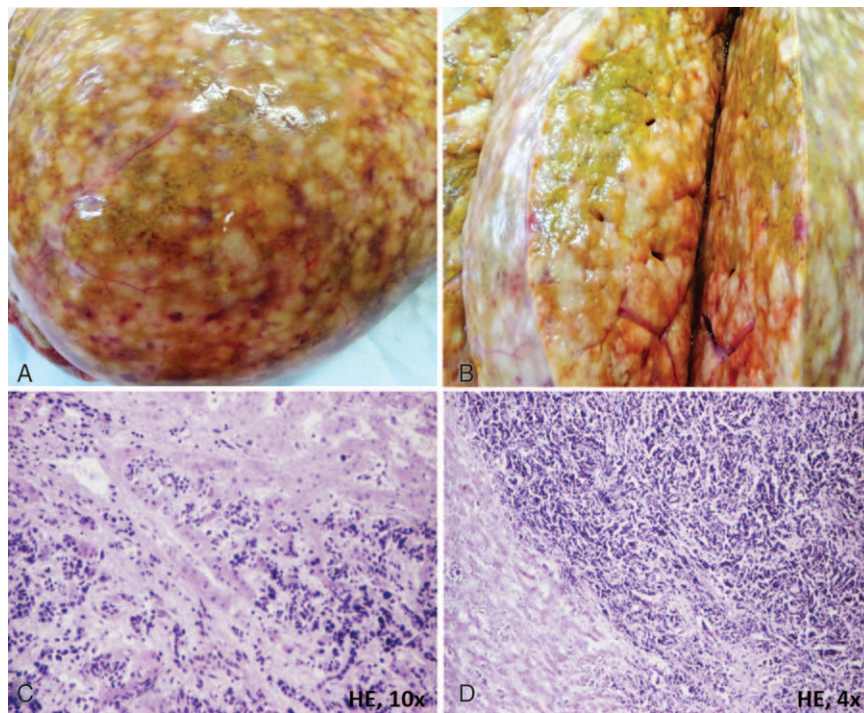


Figure 1. In a patient with fulminant liver failure, the autopsy revealed a diffuse metastatic hepatomegaly (A) with varying sized metastatic nodules (B). The tumor cells infiltrate the sinusoids (C) and replace the hepatic parenchyma (D).

Prior to the autopsy, signed informed consent of the relatives was obtained for the case publication. Being about a case report, no Ethical Committee approval was necessary. At autopsy, the macroscopic examination showed a huge liver (6.5 kg) with widely distributed white nodules of varying sizes (Fig. 1). The urinary bladder was not modified, but a $30 \times 30 \times 50$ mm prostate nodule with infiltrative aspect was observed (Fig. 2). The bilateral bronchopneumonia was confirmed, without any central tumor mass. A 10-mm white nodule was identified encasing a small bronchus from the middle lobe of the right lung, without peripheral nodules (Fig. 3). Except for moderate edema, no other brain lesions were identified. The other organs did not show modifications.

The tissues were fixed in 10% neutral formalin and embedded in paraffin together with iliac crest bone grafting. Microscopic examination of the prostate showed a

3+3 Gleason's grade 2 occult adenocarcinoma (Fig. 2). Clusters and sheets of small round cells were seen in the liver parenchyma (Fig. 1) and the lymph nodes from the hepatic hilum. Examination of the lung parenchyma showed a peribronchial SCLC with multiple tumor emboli in both veins and lymphatic vessels and multiple "coin-shaped" tumor nodules of 1 to 2 mm in diameter below the pleura (Fig. 3). The small round tumor cells were also seen in bone marrow from the iliac crest bone (Fig. 3). No brain metastases have been detected.

Based on the macro- and microscopic features and clinical picture, the final diagnosis was "peribronchial and coin-like peripheral SCLC with massive angiolymphatic invasion and metastases in the lymph nodes, liver and bone, associated with encephalopathy and synchronous occult adenocarcinoma of the prostate."

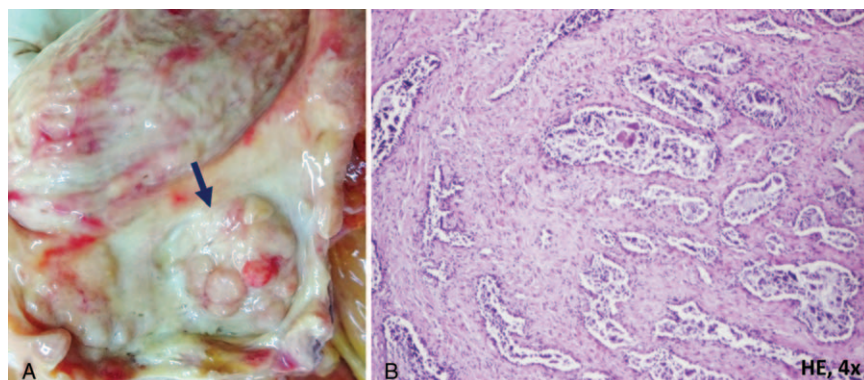


Figure 2. The aspect of occult prostate carcinoma.

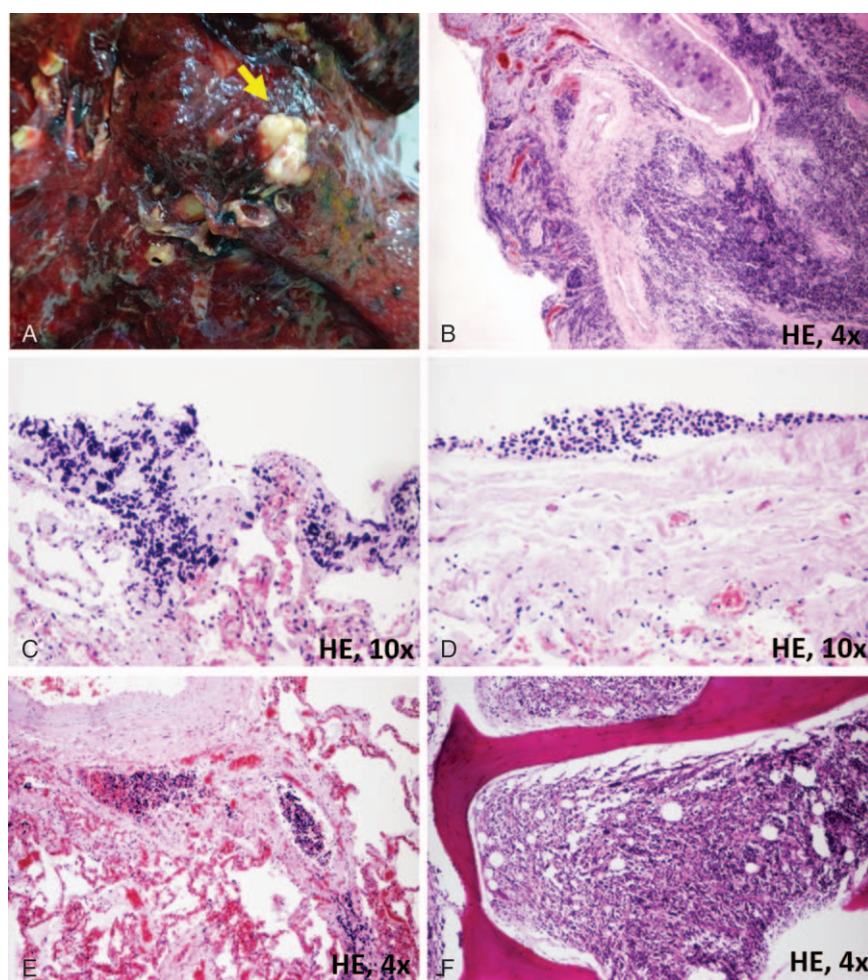


Figure 3. The small cell lung carcinoma is displayed as an intra- and peribronchial encasing tumor (A B) with microscopic coin-like peripheral foci (C, D). Massive angiolymphatic invasion (E) and metastases in the bone marrow of the iliac crest (F) are noted.

3. Discussion

In patients with synchronous tumors, identification of the metastatic origin is difficult to be done and should be based on both clinicopathological and microscopic examination. In the present case, the previously supposed bladder carcinoma increases the difficulty of diagnosis. The differential diagnosis between primary liver cancer and a metastatic tumor was not difficult to be done due to the classic histologic aspect of the SCLC cells that invaded the liver sinusoids. SCLC cannot be histologically confused with a hepatocellular carcinoma or a cholangiocarcinoma. Moreover, the tumor cells origin in the peribronchial tissue was clearly seen under the microscope (Fig. 3). Regarding the possible origin of the metastatic cells in the prostate, it was eliminated based on the histological aspect. The metastasis was composed of small cells, whereas the prostate tumor was an adenocarcinoma.

SCLC frequently metastasizes to bone and brain, the adrenal and liver being on the third place of location of the pulmonary metastases.^[4,5] Unusual metastases have been reported in skin, kidney, and thyroid gland.^[5] Although liver metastases from SCLCs are relatively frequent, diffuse metastatic hepatomegaly from a small tumor is rarely reported.^[4,6] The nodules can be identified during CT-scan, but in other cases, the diffuse aspect or

presence of nodules below 2cm in diameter can mimic a cirrhosis and the metastases are under-recognized until autopsy.^[4,6] In our case, the liver weighted 6.5 kg. In the other 18 reported cases, the weight ranged between 1 and 3.5 kg.^[6] In two of the cases, the metastases were diagnosed prior to death based on a transjugular liver biopsy^[4] or on the CT-scan exam,^[7] similar to our case.

Fulminant hepatic failure with encephalopathy is defined as the encephalopathy that is installed within 8 weeks of the onset of hepatic-related symptoms in a patient with no prior evidence of liver disease.^[6,7] It is usually related with viral hepatitis or drugs toxicity and is an unusual presentation for a patient with SCLC without brain metastases.^[6,7] Although the liver is the commonest metastatic site, only 7% of the patients with liver metastases develop a hepatic coma.^[6] In patients with diffuse involvement of the liver parenchyma, the improper diagnosis and improper therapy with steroids can accelerate the tumor aggressive behavior.^[6] A correct diagnosis can improve the prognosis, a dramatic response to the combined chemotherapeutic regimen with carboplatin, etoposide, and amrubicin being shown in one of the recent cases.^[7] However, the survival time of these patients ranges between 1 day and 6 months, with a median time of 7 days after hospital admission.^[4-8] Based on this interval,

hyperacute (<7 days) and acute (7–28 days) liver failure is considered.^[9]

In the present case, the encephalopathy was the result of massive malignant invasion and replacement of the liver parenchyma by tumor cells.^[4] The main conclusion of the paper is that a metastatic involvement of the liver should be considered in any patient with fulminant hepatic failure and hepatomegaly.

References

- [1] Raspotnig M, Vedeler C, Storstein A. Paraneoplastic neurological syndromes in lung cancer patients with or without onconeural antibodies. *J Neurol Sci* 2014;348:S0022–510X. 00710-00712.
- [2] Jung I, Gurzu S, Balasa R, et al. A coin-like peripheral small cell lung carcinoma associated with acute paraneoplastic axonal Guillain-Barre-like syndrome. *Medicine (Baltimore)* 2015;94:e910.
- [3] Kanaji N, Watanabe N, Kita N, et al. Paraneoplastic syndromes associated with lung cancer. *World J Clin Oncol* 2014;5:197–223.
- [4] Mishima S, Snozaki Y, Mikami S, et al. Diffuse liver metastasis of small-cell lung cancer presenting as acute liver failure and diagnosed by transjugular liver biopsy: a rare case in whom nodular lesions were detected by enhanced CT examination. *Case Rep Gastroenterol* 2015;9:81–7.
- [5] Can AS, Koksak G. Thyroid metastasis from small cell lung carcinoma: a case report and review of the literature. *J Med Case Rep* 2015;9:231.
- [6] Miyaaki H, Ichikawa T, Taura N, et al. Diffuse liver metastasis of small cell lung cancer causing marked hepatomegaly and fulminant hepatic failure. *Intern Med* 2010;49:1383–6.
- [7] Kaira K, Takise A, Watanabe R, et al. Fulminant hepatic failure resulting from small-cell lung cancer and dramatic response of chemotherapy. *World J Gastroenterol* 2006;12:2466–8.
- [8] Alexopoulou A, Koskinas J, Deutsch M, et al. Acute liver failure as the initial manifestation of hepatic infiltration by a solid tumor: report of 5 cases and review of the literature. *Tumori* 2006;92:354–7.
- [9] Lo AA, Lo EC, Li H, et al. Unique morphologic and clinical features of liver predominant/primary small cell carcinoma— autopsy and biopsy case series. *Ann Diagn Pathol* 2014;18:151–6.