

## Exudative retinal detachment following strabismus surgery in Sturge–Weber syndrome

Yu Cheol Kim, Se Yeop Lee, Kwang Soo Kim

A 15-year-old boy with Sturge–Weber syndrome underwent strabismus surgery (oculus sinister [OS]) for the treatment of exotropia. The patient's visual acuity (OS) decreased to hand motion 10 days after the surgery. One month after the surgery, the patient's visual acuity decreased to light perception, and a fundus examination showed total exudative retinal detachment (OS).

**Key words:** Retinal detachment, strabismus, Sturge–Weber syndrome

Sturge–Weber syndrome (SWS) has ocular complications such as glaucoma, diffuse choroidal hemangioma, and buphthalmos. Diffuse choroidal hemangioma can lead to an exudative retinal detachment (ERD) and it may be triggered by glaucoma surgeries such as trabeculectomy and deep sclerotomy.<sup>[1,2]</sup> We report the case of a patient with SWS and diffuse choroidal hemangioma who underwent uneventful strabismus surgery by an experienced surgeon; however, he suffered the complications of ERD.

### Case Report

A 15-year-old boy with SWS underwent recession of the lateral rectus muscle (oculus sinister [OS], 7.7 mm), resection of the medial rectus muscle (OS, 6.0 mm) and infratransposition of the horizontal muscle with 1/4 tendon width (OS) for

the treatment of 30 prism-diopter sensory exotropia. The patient had port-wine stains (hemangioma) on the left side of his upper lid and forehead [Fig. 1a] and angiomatous lesions involving the left occipito-temporo-parietal area. The patient had laser therapy for the treatment of the port-wine stains on his skin. Six years before the surgery, choroidal hemangioma and optic disc cupping enlargement were both identified on a fundus examination (OS) [Fig. 1b], and latanoprost ophthalmic solution (Xalatan®, Pfizer Inc. NY, USA) was applied to the afflicted left eye. The patient's preoperative best corrected visual acuity (BCVA) was 1.0 (+0.50 diopter sphere/−0.50 diopter cylinder ×180°) and 0.125 (−0.5 diopter sphere/−2.25 diopter cylinder ×180°) oculus dexter and OS, respectively. The BCVA (OS) decreased to hand motion 10 days after the surgery. One month after the surgery, the BCVA decreased to light perception; a slit lamp and fundus examination showed total ERD (OS) [Fig. 2a]. B-scan ultrasonography revealed ERD with a huge dome-shaped choroidal hemangioma [Fig. 2b].

Pars plana vitrectomy (PPV) with internal drainage of the subretinal fluid (SRF), fluid-gas exchange, endolaser photocoagulation, intravitreal bevacizumab injection and silicone oil tamponade was performed. Eight days after the PPV, the BCVA was finger count 10 cm and some SRF on the macula remained.

### Discussion

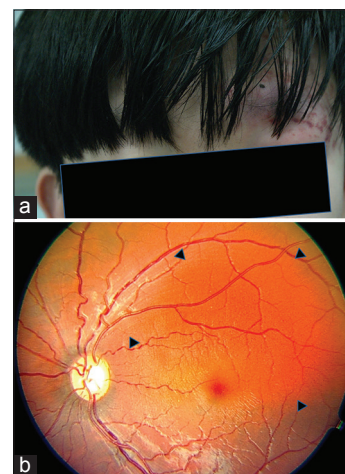
Diffuse choroidal hemangioma can develop into a severe ERD, which can be induced by glaucoma surgery.<sup>[1,3,4]</sup> A sudden

Access this article online	
Quick Response Code:	Website: www.ijo.in
	DOI: 10.4103/0301-4738.162641

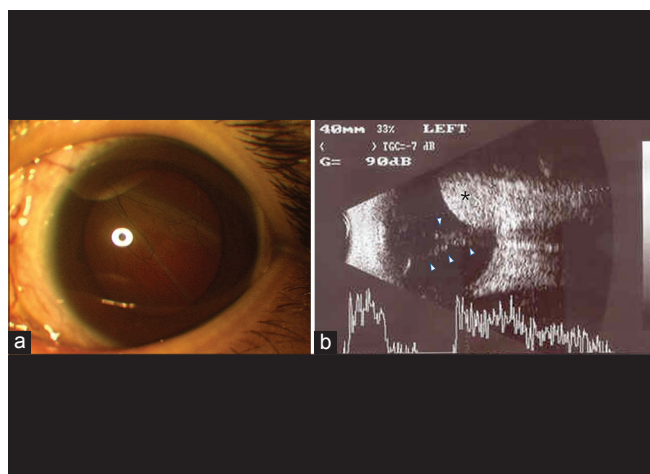
Department of Ophthalmology, Dongsan Medical Center, Keimyung University School of Medicine, Daegu, Republic of Korea

**Correspondence to:** Prof. Yu Cheol Kim, Department of Ophthalmology, Dongsan Medical Center, Keimyung University School of Medicine, #56, Dalseong-ro, Jung-gu, Daegu 700-712, Republic of Korea. E-mail: eyedr@dsmc.or.kr

Manuscript received: 03.01.15; Revision accepted: 15.06.15



**Figure 1:** Preoperative findings. (a) Port wine stains on the left upper eyelid and forehead (postlaser treatment), (b) Choroidal hemangioma (tomato-catsup fundus, arrow heads) in fundus photograph



**Figure 2:** Postoperative findings. (a) Severe exudative retinal detachment (ERD) is seen behind the lens, (b) A and B scan ultrasonography shows ERD (arrow heads) and a diffuse and thick choroidal hemangioma with high internal reflectivity (asterix)

decompression of the globe during or after surgeries is thought to be the possible mechanism of ERD induction after ocular surgeries. To avoid the sudden drop in the intraocular pressure (IOP), nonpenetrating glaucoma surgery, such as deep sclerotomy is recommended in patients with SWS or choroidal hemangioma.<sup>[5]</sup> However, ERD following deep sclerotomy in SWS has also been reported.<sup>[2]</sup>

In the present case, ERD developed following strabismus surgery, and the ERD is presumed to have developed before the first follow-up because the BCVA at postoperative day 7 (the first follow-up after the strabismus surgery) was decreased to hand motion. This case shows that strabismus surgery can induce ERD in the patient with SWS and diffuse choroidal hemangioma, even though it does not penetrate the eyeball and does not decrease the IOP suddenly. It suggests that, without the sudden IOP drop, stimulation to the choroidal hemangioma such as manipulation of an eyeball or moderate

change of IOP can induce ERD in some cases with SWS and diffuse choroidal hemangioma.

In filtering surgery, preoperative screening for choroidal hemangioma in SWS has been advocated, although there is a controversy regarding the need for posterior sclerotomy to prevent the intraoperative or postoperative choroidal hemorrhage or ERD.<sup>[4,6]</sup> If surgical manipulation of the eyeball or diffuse hemangioma might be a stimulus to induce ERD, as in the present case, prophylactic posterior sclerotomy could be another trigger.

We could not find previous reports of ERD following strabismus surgery in SWS in a computerized search utilizing PubMed. Therefore, we report the case of ERD as a complication of strabismus surgery in SWS and further study is warranted to confirm that the screening for choroidal hemangioma before strabismus surgery in SWS should be recommended.

## References

1. Bellows AR, Chylack LT Jr, Epstein DL, Hutchinson BT. Choroidal effusion during glaucoma surgery in patients with prominent episcleral vessels. *Arch Ophthalmol* 1979;97:493-7.
2. Taherian K, Anand N. Exudative retinal detachment following deep sclerectomy in Sturge-Weber syndrome. *Eye (Lond)* 2007;21:842-3.
3. Chavala SH, Williamson JF. Bilateral exudative retinal detachments in Sturge-Weber syndrome. *Lancet* 2013;382:259.
4. Mandal AK, Gupta N. Patients with Sturge-Weber syndrome. *Ophthalmology* 2004;111:606.
5. Rebolleda G, Muñoz-Negrete FJ. Nonpenetrating deep sclerectomy for Sturge-Weber syndrome. *Ophthalmology* 2001;108:2152-3.
6. Eibschitz-Tsimhoni M, Lichter PR, Del Monte MA, Archer SM, Musch DC, Schertzer RM, *et al.* Assessing the need for posterior sclerotomy at the time of filtering surgery in patients with Sturge-Weber syndrome. *Ophthalmology* 2003;110:1361-3.

**Cite this article as:** Kim YC, Lee SY, Kim KS. Exudative retinal detachment following strabismus surgery in Sturge-Weber syndrome. *Indian J Ophthalmol* 2015;63:554-5.

**Source of Support:** Nil. **Conflict of Interest:** None declared.