



Endoscopic radiofrequency ablation for palliative treatment of hilar cholangiocarcinoma

Pedro Pereira, MD, Ana L. Santos, MD, Rui Morais, MD, Filipe Vilas-Boas, MD, Eduardo Rodrigues-Pinto, MD, João Santos-Antunes, Guilherme Macedo, MD, PhD

Background and Aims: Recent data support a role for endoscopic radiofrequency ablation (RFA) in unresectable cholangiocarcinoma by improving stent patency and overall survival.

Methods: We describe 3 patients with inoperable cholangiocarcinoma with jaundice and cholestasis who were recommended palliative chemotherapy. They underwent endoscopic retrograde cholangiopancreatography with single-operator cholangioscope and intraductal RFA.

Results: The procedures were performed without adverse events in all patients, with clinical and analytical improvement 1 month later.

Conclusions: RFA is a promising and safe palliative treatment in patients with unresectable cholangiocarcinoma. (VideoGIE 2021;6:195-8.)

The majority of hilar malignant biliary strictures are cholangiocarcinoma (CCA) related. This entity presents at diagnosis with a higher rate of unresectability; thus, palliative treatment is often required. Endoscopic palliation with ERCP-guided biliary stent placement has an important role in patients with cholestasis, jaundice, and pruritus.¹ However, biliary drainage is limited by tumor ingrowth and/or biliary stasis, which causes stent occlusion and the need for repeat ERCP and biliary stent replacement.² Recent studies have demonstrated that ERCP-guided radiofrequency ablation (RFA) has a role in the palliative approach to CCA, namely in terms of improved stent patency and better functional status and quality of life compared with stent placement alone.³

CLINICAL CASES

We describe 3 patients with a diagnosis of perihilar CCA who underwent endoscopic RFA with palliative intent. The first patient was a 58-year-old woman with a Bismuth type-IV tumor with vascular invasion, for which systemic chemotherapy was recommended. Because of the worsening of jaundice and cholestasis, ERCP with a single-operator cholangioscope (Spyglass DS II, Boston Scientific) was performed, confirming the presence of a hilar stricture with irregular dilated blood vessels—“tumor vessels” with involvement of the right and left hepatic duct (Fig. 1A)—and visual impression of malignancy. The second patient, a 72-year-old-man with a Bismuth type-I Klatskin tumor,

was considered inoperable because of comorbidities and was recommended systemic chemotherapy; cholangioscopy was performed because of worsening jaundice and confirmed a stricture at the level of the common hepatic duct (Fig. 2A). The last patient was a 53-year-old man with an unresectable Bismuth type-IV cholangiocarcinoma who was recommended palliative chemotherapy. ERCP with a single-operator cholangioscope was performed because of jaundice and pruritus and confirmed a hilar stricture with “tumor vessels” extending to the right and left intrahepatic ducts (Fig. 3).

Intraductal RFA (Habib EndoHPB bipolar radiofrequency catheter, Boston Scientific) was performed in all patients (electrosurgical generator: ERBE 200D, power: 10W, effect 8, energy for 45 seconds × 2 cycles) after insertion of the radiofrequency probe along a guidewire. Before treatment, the location and extent of the stricture was documented on fluoroscopy and cholangioscopy (Fig. 4). No dilatation was needed to obtain access for the cholangioscope. RFA was repeated until all of the stricture was treated. The efficacy of ablation and exclusion of adverse events (AEs) was based on cholangioscopy findings (Figs. 1B and 2B). In the first 2 patients, uncovered self-expandable metal stents (Wallflex 8 mm and 10 and 12 cm) were placed in a transpapillary position, with the proximal flange in the left intrahepatic duct. In the third patient, bilateral drainage was performed with 2 uncovered self-expandable metal stents (Wallflex 8 mm and 12 cm). All procedures were performed with the patient under general anesthesia with propofol.

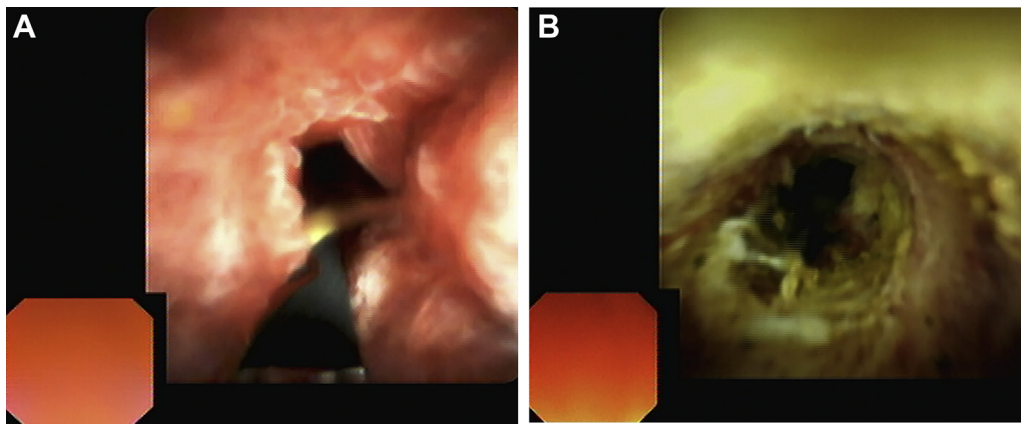


Figure 1. **A**, Cholangioscopic image revealing a stricture at the hepatic confluence in patient 1 (Bismuth type IV cholangiocarcinoma). **B**, Cholangioscopic image showing visual findings of the stricture after radiofrequency ablation in patient 1.

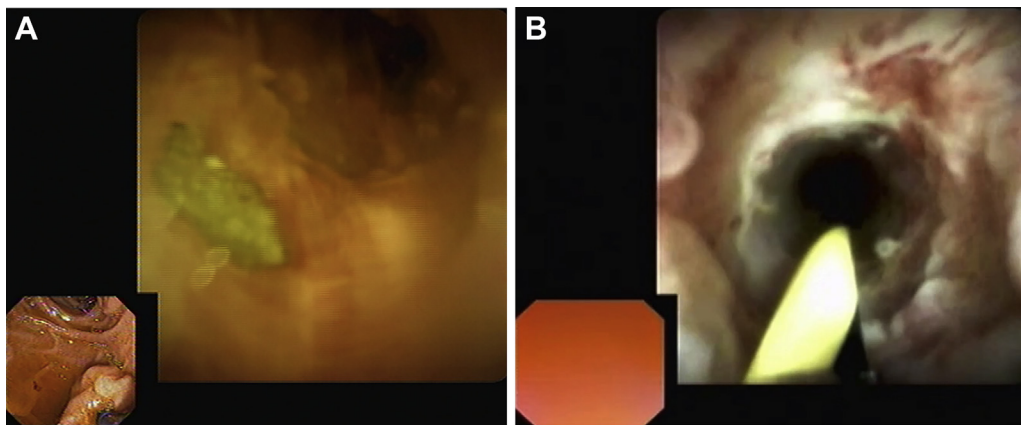


Figure 2. **A**, Cholangioscopic image revealing a hilar stricture in patient 2 (Bismuth type I cholangiocarcinoma). **B**, Cholangioscopic image showing hilar stricture after radiofrequency ablation in patient 2.

No AEs occurred, and all patients were discharged home. Re-evaluation at 1 month showed clinical and analytical improvement (Table 1). The first and second patients died 13 and 5 months after RFA, respectively. The third patient remained alive 13 months after RFA and presented with cholangitis, with no AEs, 5 months after the procedure.

CONCLUSIONS

Early diagnosis of extrahepatic CCA is difficult, not only because of its special anatomical location but also because of its occult onset, with rates of resectability at diagnosis of only 20% to 30%.³ Endoscopic biliary drainage remains the main palliative treatment in these types of malignancies, allowing symptom control. However, because of the continuous tumor growth, reobstruction of the stent and recurrence of jaundice is common.⁴

RFA is extensively used in many solid organ malignancies as a local ablative therapy.⁵ RFA allows tissue necrosis by the emission of heat energy via a bipolar probe with high-frequency alternating current, inducing necrosis of tumor cells and controlling tumor regrowth. The 2 electrode rings of the bipolar RFA probe allow cylindrical ablation with 25 mm of length between the distal and proximal electrode margins. In our cases, RFA was performed with a power of 10W for 90 seconds, divided in 2 periods of 45 seconds; after each period, the electrode was kept at the ablation site for 1 minute to allow cooling of the probe to prevent damage to the surrounding tissue.

The impact of RFA in survival and stent patency in extrahepatic CCA remained unclear for some time. In 2017, Yang et al³ reported a reduction in postoperative bilirubin levels at week 2 in the RFA plus stent group compared with stent alone, suggesting rapid relief of jaundice and a longer time of stent patency. Moreover,

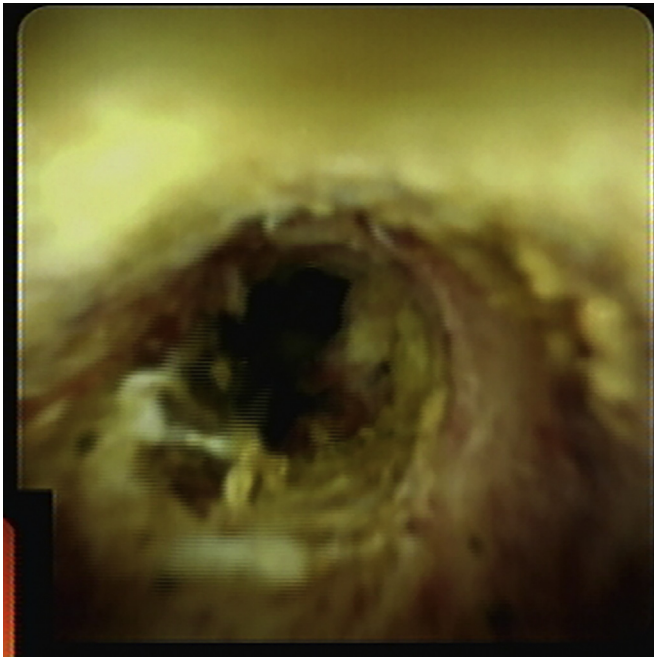


Figure 3. Cholangioscopic image revealing a hilar stricture in patient 3 (Bismuth type IV cholangiocarcinoma).

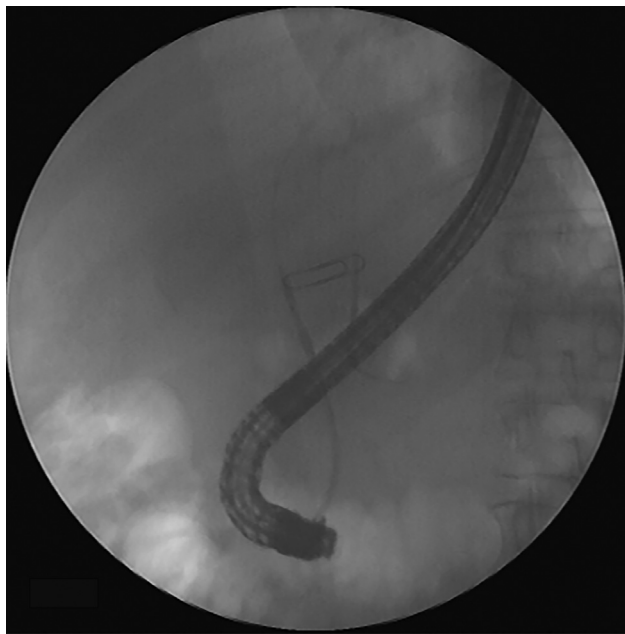


Figure 4. Fluoroscopic image with placement of a metal clip to help locate stricture ends and guide radiofrequency ablation.

survival was higher at 9, 12, and 15 months, suggesting that RFA therapy can prolong survival of patients with extrahepatic CCA.³

Endoscopic RFA seems to be safe (6% rate of AEs), with no incremental risk of AEs when compared with stent placement only. Moreover, no serious AEs were

TABLE 1. Bilirubin evolution before, immediately after, and 1 month after radiofrequency ablation

	Before RFA (mg/dL)	After RFA (mg/dL)	1 month later (mg/dL)
Case 1	1.39	1.23	0.38
Case 2	17.39	13.60	10.59
Case 3	7.52	5.52	1.29

reported in either group, such as perforations or procedure-related death.⁵ In 2016, Wang et al⁶ reported prolonged stent patency, both with plastic and metal stents, with no significant differences between stents. In our 3 cases, after RFA, biliary drainage was maintained by self-expandable metal stent placement because of longer patency and less need of reintervention compared with plastic stents. Recent data suggest that, in Bismuth II-IV CCA, bilateral stent placement may be preferable over unilateral because it is associated with a decrease in the reintervention rate without increasing the complication rate.⁷ This point was taken into account in our cases, as we can see in case 3; however, in case 2, bilateral stent placement was not technically possible.

Our case series highlights the role of RFA as a possible adjunct in palliative treatment of hilar CCA, with improvement of cholestasis and symptom relief. The ease of use and the possibility of repeating the procedure make intraductal RFA a promising treatment modality for patients with unresectable CCA. Moreover, no AEs were reported in our cases, demonstrating the safety of the procedure (Video 1, available online at www.giejournal.org).

DISCLOSURE

All authors disclosed no financial relationships.

Abbreviations: AE, adverse event; CCA, colangiocarcinoma; RFA, radiofrequency ablation.

REFERENCES

- Dorrell R, Pawa S, Pawa R. Endoscopic management of malignant biliary stricture. *Diagnostics (Basel)* 2020;10:390.
- Yang J, Wang J, Zhou H, et al. Endoscopic radiofrequency ablation plus a novel oral 5-fluorouracil compound versus radiofrequency ablation alone for unresectable extrahepatic cholangiocarcinoma. *Gastrointest Endosc* 2020;92:1204-12.e1.
- Yang J, Wang J, Zhou H, et al. Efficacy and safety of endoscopic radiofrequency ablation for unresectable extrahepatic cholangiocarcinoma: a randomized trial. *Endoscopy* 2018;50:751-60.
- Mönkemüller K, Popa D, Wilcox CM. Endoscopic treatment options for cholangiocarcinomas. *Expert Rev Anticancer Ther* 2014;14:407-18.

5. Feng Q, Chi Y, Liu Y, et al. Efficacy and safety of percutaneous radiofrequency ablation versus surgical resection for small hepatocellular carcinoma: a meta-analysis of 23 studies. *J Cancer Res Clin Oncol* 2015;141:1-9.
6. Wang F, Li Q, Zhang X, et al. Endoscopic radiofrequency ablation for malignant biliary strictures. *Exp Ther Med* 2016;11:2484-8.
7. Ashat M, Arora S, Klair JS, et al. Bilateral vs unilateral placement of metal stents for inoperable highgrade hilar biliary strictures: a systemic review and meta-analysis. *World J Gastroenterol* 2019;25:5210-9.

Gastroenterology Department, Centro Hospitalar São João, Porto, Portugal.

Copyright © 2021 American Society for Gastrointestinal Endoscopy. Published by Elsevier Inc. This is an open access article under the CC BY-NC-ND license (<http://creativecommons.org/licenses/by-nc-nd/4.0/>).

<https://doi.org/10.1016/j.vgie.2020.12.009>

Endoscopedia

Endoscopedia has a new look! Check out the redesign of the official blog of *GIE* and *VideoGIE*. Keep up with the latest news and article discussions and post your comments or questions to *VideoGIE* authors. Visit us at www.endoscopedia.com.